

Pediatrics

Spinal lipoma associated with urethral duplication

Luiz G. Freitas Filho*, Carolina S. Martins, José Carnevale, Francisco Kanasiro, Luiz J. Budib

Department of Urology, Hospital Santa Marcelina, Brazil



ARTICLE INFO

Keywords:

Bulbar urethra
Cobb's collar
Congenital strictures
Chronic renal failure

Introduction

Urethral duplication is a rare anomaly with varied clinical manifestations such as urinary tract infections, serous discharge from sinus, outflow obstruction and urinary incontinence.

A spinal cord lipoma is fat within the normally positioned spinal cord without any skin or bony abnormalities. Most commonly these rare lesions are usually present at birth with an obvious lumbosacral mass. Spinal cord compression can cause numbness and tingling, weakness, difficulty, incontinence and stiffness of the extremities.

We describe an interesting case of spinal lipoma associated with urethral duplication.

Material and methods

Case report

FSA, male, born on March 22, 2000, second born-dizygotic twin. At two months he presented with a urinary tract infection. He had no cutaneous signs of spinal dysraphism and neurological examination was normal. He had perineal dermatitis, and his diaper was constantly wet with urine, although the mother had seen normal streams of urine. Ultrasonography examination showed a horseshoe kidney, normal bladder and ureters. Voiding cystourethrography showed failure of lumbosacral vertebrae fusion, normal bladder capacity and absence of vesicoureteral reflux. DMSA - Tc^{99m} and DTPA - Tc^{99m} scintigraphies were normal. Magnetic Resonance (Fig. 1) revealed a lumbar lipoma with signs of tethered cord. Urodynamic examination was normal. The incontinence was first attributed to the presence of lumbar lipoma and the child was maintained on a prophylactic Cephalexin basis and prepared for a neurosurgical procedure. At one year of age he had another

voiding cystourethrography that revealed urethral duplication (Fig. 2). The patient then underwent a surgical procedure to have his urethral duplication corrected; the more ventral urethra whose spongy body was not so developed and that ran into a severe stenotic meatus in the glans, was resected (Fig. 3). Currently, eighteen years after the procedure the child is continent and voiding with a normal stream.

Comment

Urethral duplication is an extremely rare congenital disease in which one of the urethras is normal and the other one is considered an accessory urethra. Both urethras are usually aligned at a sagittal level, one above the other, with a lumen closer to normal in the ventral urethra as compared to the dorsal urethra that is, as a rule, hypoplastic.¹ The patients may present with urinary tract infection, incontinence, dribbling, outflow obstruction, a double or split stream, or they can be asymptomatic.¹

Spinal lipomas are congenital lesions usually present at birth with an obvious lumbosacral mass.² The optimal treatment of asymptomatic patients with spinal lipomas remains uncertain. Many authors advocate early prophylactic surgery, based on the idea that this can provide improved outcomes.^{3,4} The lipoma forms a bridge between the local neural tissue and the spinal level and most pediatric neurosurgeons presume it to be of inevitable neurological deterioration.⁵

The uncommon combination of a spinal cord lipoma free of any cutaneous component, and urethral duplication in the same patient led us to take the urinary incontinence, proven to be caused by the urethral duplication, for a sign of the presence of the lipoma, and the patient almost underwent a neurosurgical procedure, which indication is not always clear.² Although the urethras have a meatus opening at different sites in the glans, the patient presented a single stream through the

* Corresponding author. Rua Batista Cepelos 87 - ap 61, 04109-120, São Paulo, Brazil.

E-mail addresses: luizfreitasepm@gmail.com, luizfreitasf@hotmail.com (L.G. Freitas Filho), carolmartins38@yahoo.com.br (C.S. Martins), carnevalejose@hotmail.com (J. Carnevale), fkana10@gmail.com (F. Kanasiro), lj.budib@uol.com.br (L.J. Budib).

<https://doi.org/10.1016/j.eucr.2018.04.002>

Received 21 March 2018; Accepted 3 April 2018

Available online 06 April 2018

2214-4420/ © 2018 The Authors. Published by Elsevier Inc. This is an open access article under the CC BY-NC-ND license (<http://creativecommons.org/licenses/by-nc-nd/4.0/>).

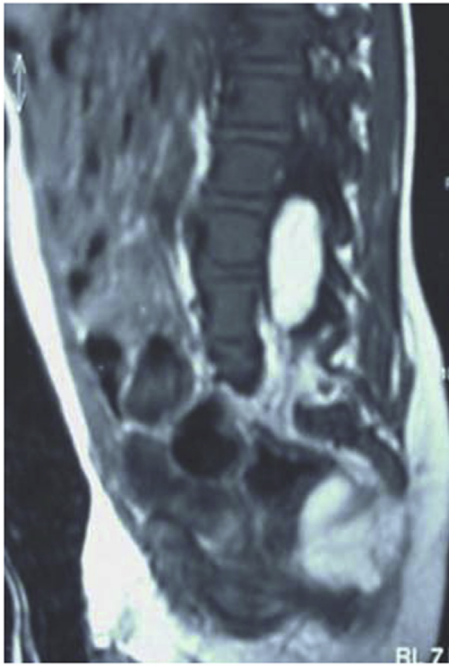


Fig. 1. Mid-sagittal T1-weighted image of a intradural lipoma.

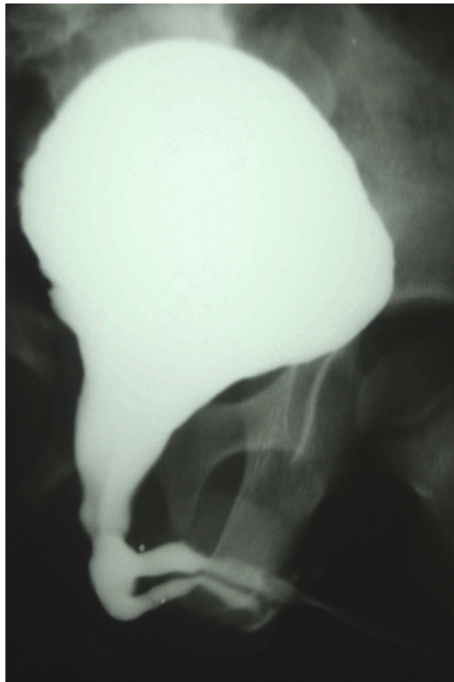


Fig. 2. VCUG showing duplication of the urethra.

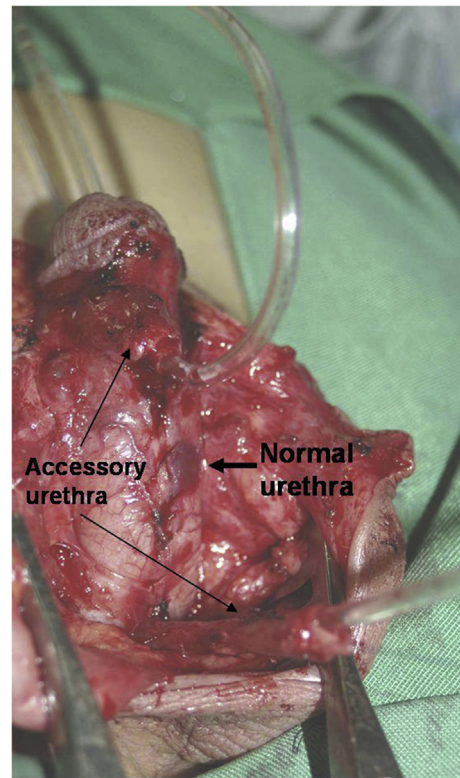


Fig. 3. Division of the accessory urethra which was resected.

normal urethra, which was not the ventral one, and dribbling through the accessory urethra. The surgical procedure performed involved resection of the accessory urethra. Currently, eighteen years after the procedure, the patient is fully continent for urine without any symptoms of spinal cord lipoma.

References

1. Glassberg KI, Horowitz M. Urethral valve and other anomalies of the male urethra. In: Belman AB, King LR, Kramer SA, eds. *Clinical Pediatric Urology*. London: Martin Dunitz; 2002:939–940.
2. Kulkarni AV, Pierre-Kahn A, Zerah M. Conservative management of asymptomatic spinal lipomas of the conus. *Neurosurgery*. 2004;54:868–875.
3. Chapman PH, Davis KR. Surgical treatment of spinal lipomas in childhood. *Pediatr Neurosurg*. 1993;19:267–275.
4. Cochrane DD, Finley C, Kestle J, Steinbok P - the patterns of late deterioration in patients with transitional lipomyelomeningocele. *Eur J Pediatr Surg*. 2000;10(Suppl1):13–17.
5. Dorward NL, Scatliff JH, Hayward RD. – Congenital lumbosacral lipomas: pitfalls in analyzing the results of prophylactic surgery. *Child's Nerv Syst*. 2002;18:326–332.