

# All India Ophthalmological Society members survey results: Cataract surgery antibiotic prophylaxis current practice pattern 2017

*Prafulla Kumar Maharana, Jay K Chhablani<sup>1</sup>, Tara Prasad Das<sup>1</sup>, Atul Kumar, Namrata Sharma*

**Purpose:** The purpose of this article is to document the current practice pattern of Indian ophthalmologists for antibiotic prophylaxis in cataract surgery to prevent endophthalmitis. **Methods:** Fifteen structured questions were sent online to all ophthalmologists registered with the All India Ophthalmological Society. The questionnaire was divided into three main categories of prophylaxis – preoperative, intraoperative, and postoperative. A web-based anonymous survey was conducted, and a unique response link allowed completing the survey only once. We compared the results with a similar 2014 survey among the members of the American Society of Cataract and Refractive Surgeons (ASCRS). **Results:** The response was received from 30.2% ( $n = 4292/14,170$ ) ophthalmologists. The results were as follows: all respondents do not prepare the eye with 5% povidone-iodine (83% of them use povidone iodine), majority (90%) use topical antibiotic both pre- and post-operatively, 46% use subconjunctival antibiotic at the end of surgery, and 40% use intracameral antibiotic (46% of them in high-risk patients only). Moxifloxacin was the preferred antibiotic for topical and intracameral use. Comparison with the 2014 ASCRS survey results showed a similarity in decision for pre- and post-operative antibiotics and intracameral antibiotic but dissimilarity in the choice of intracameral antibiotic and decision for subconjunctival antibiotic. **Conclusion:** The antibiotic prophylaxis practice by the Indian ophthalmologists is not too dissimilar from the practice in North American Ophthalmologists (ASCRS) though all ophthalmologists in India must be nudged to preoperative preparation of the eye with povidone-iodine and discontinue the practice of postoperative subconjunctival and systemic antibiotic.

**Key words:** Antibiotic prophylaxis, cataract, endophthalmitis, moxifloxacin

Cataract accounts for 62% of blindness in India.<sup>[1]</sup> Cataract extraction with intraocular lens implantation is the most commonly performed surgical procedure worldwide. Over 6.48 million of cataract surgeries were performed in India in 2016–2017.<sup>[1]</sup> Endophthalmitis is a dreaded complication after any intraocular surgery, and because of sheer numbers, it is seen more often after cataract surgery. With better understanding of the pathology and microbiology of endophthalmitis and targeted prophylaxis, the incidence of postcataract surgery endophthalmitis has significantly reduced to <0.1% all over the world. The reported rates of postcataract surgery culture-positive endophthalmitis in India are between 0.02% and 0.09%.<sup>[2-7]</sup> The evidence-based cares to prevent postcataract surgery endophthalmitis are preparation of skin with 10% and the eye with 5% povidone-iodine and intracameral antibiotic (cefuroxime).<sup>[8-10]</sup> Other measures frequently used in the clinical practice are preoperative topical and systemic antibiotics, intraoperative irrigating fluid with antibiotics, and subconjunctival antibiotic injection at the end of the surgery. Many practicing ophthalmologists resort to these measures despite lack of robust evidence.

Dr. Rajendra Prasad Centre for Ophthalmic Sciences, All India Institute of Medical Sciences, New Delhi, <sup>1</sup>Srimati Kanuri Santhamma Centre for Vitreoretinal Disease, L V Prasad Eye Institute, Hyderabad, Telangana, India

**Correspondence to:** Prof. Namrata Sharma, Room-482, 4<sup>th</sup> Floor, Dr. Rajendra Prasad Centre for Ophthalmic Sciences, All India Institute of Medical Sciences, New Delhi - 110 029, India. E-mail: namrata.sharma@gmail.com

**Manuscript received:** 06.01.18; **Revision accepted:** 26.03.18

## Access this article online

### Website:

www.ijo.in

### DOI:

10.4103/ijo.IJO\_1336\_17

## Quick Response Code:



To understand the current practice pattern in postcataract surgery endophthalmitis prophylaxis, a web-based survey was done among the members of the All India Ophthalmological Society (AIOS). This manuscript is based on the outcomes of this survey.

## Methods

We conducted a questionnaire-based cross-sectional study among the members of the AIOS. Fifteen questions were e-mailed to all prospective participants. The participants are required to submit their responses through a web-based system.

The questionnaire was designed based on the review of literature done on the previous studies published in the same domain. The face validity of the questionnaire was established by a group of six ophthalmologists from three tertiary care institutes. The questionnaire-included questions as mentioned in Table 1 were pilot tested among

This is an open access journal, and articles are distributed under the terms of the Creative Commons Attribution-NonCommercial-ShareAlike 4.0 License, which allows others to remix, tweak, and build upon the work non-commercially, as long as appropriate credit is given and the new creations are licensed under the identical terms.

**For reprints contact:** reprints@medknow.com

**Cite this article as:** Maharana PK, Chhablani JK, Das TP, Kumar A, Sharma N. All India Ophthalmological Society members survey results: Cataract surgery antibiotic prophylaxis current practice pattern 2017. Indian J Ophthalmol 2018;66:820-4.

**Table 1: Cataract surgery - antibiotic prophylaxis questionnaire**

Preoperative antibiotic	
1. Do you use prophylactic topical antibiotics before cataract surgery	Yes No Other
2. What is your preferred topical antibiotic before cataract surgery	Ciprofloxacin Moxifloxacin Gatifloxacin Other
3. When do you start topical antibiotics before cataract surgery	Never 3 days before 1 day before Other
Intraoperative antibiotic	
1. Do you use intracameral antibiotics during cataract surgery	Yes No Other
2. Do you use antibiotics in irrigating solution during cataract surgery	Yes No Other
3. When do you use intracameral antibiotics	In all cases In high-risk cases including systemic risk as well as longer surgery duration Other
4. What is your preferred intracameral antibiotic if needed to be used	Cefuroxime Moxifloxacin Vancomycin Other
5. Since when you have been using intracameral antibiotics	Last 6 months Last 2 years Never used Other
6. Do you administer any antibiotic at the end of the surgery	No Subconjunctival antibiotic injections Collagen shield soaked in antibiotic Other
7. Do you use povidone-iodine eye drops before the cataract surgery	Yes No Other

**Table 1: Contd...**

Postoperative antibiotic	
1. Do you patch the eye after cataract surgery	Yes No Other
2. Do you use oral antibiotic in regards to cataract surgery	Yes, preoperatively Yes, postoperatively No Other
3. Do you use any topical antibiotics after cataract surgery	Yes No Other
4. What is your preferred topical antibiotic after cataract surgery	Ciprofloxacin Moxifloxacin Gatifloxacin Other
5. For how long do you prescribe topical antibiotics after cataract surgery	1 week 4 weeks 6 weeks Other

30 patients, who had proficiency in English language and revised in accordance with the findings of the pilot study. The web-based anonymous survey results were collected and analyzed. The questionnaire was divided into three main categories of prophylaxis – preoperative, intraoperative, and postoperative [Table 1]. A unique response link allowed completing the survey only once.

## Results

The questionnaire was completed by 30.2% of ophthalmologists ( $n = 4292/14,170$ ) registered with the AIOS. This included all spectrums of ophthalmologists – solo and group practice, practicing in rural and urban areas, and working in public and private sectors.

### Preoperative topical antibiotic (total responses 4198)

A vast majority (90%) of respondents use preoperative topical antibiotic; 73.2% use moxifloxacin; 44.5% use 1-day prior and 44.2% use 3-day before cataract surgery; rest 1.3% use depending upon the case [Fig. 1].

### Preoperative povidone-iodine preparation (out of 4154 responses)

The practice of 5% povidone-iodine preparation of the eye and skin around the eye is not universal; only 83.8% routinely use povidone-iodine to prepare the eye before surgery.

### Intraoperative antibiotic (total responses 4163)

Less than half, i.e., 40%, of the respondents use intracameral antibiotic after cataract surgery. Out of these, 36.6% use in all cases and 46.2% use in high-risk cases only while the rest used occasionally.

Contd...

### Preferred intracameral antibiotic (3716 responses)

Intracameral moxifloxacin is the choice in 78% of surgeons who chose to give intracameral antibiotic followed by gatifloxacin [Fig. 2].

In response to the question – do you administer any antibiotic at the end of the surgery? (total 3,974 responses), nearly half, i.e. 46%, of respondents said that they administer subconjunctival antibiotic injection at the end of cataract surgery (we do not know how many of them also give intracameral antibiotic injection).

### Oral antibiotic (total response 4166 in response to the question – do you use oral antibiotic in regard to cataract surgery?)

A small group of ophthalmologists, i.e., 13.6%, use oral antibiotic routinely before cataract surgery, and 44.3% of respondents prescribe oral antibiotic after cataract surgery (We do not know how many prescribe both pre- and post-operative oral antibiotic).

### Postoperative antibiotic (total responses 4162)

Postoperative topical antibiotic is prescribed by 94.4% respondents; 78.8% prefer topical moxifloxacin and 15.3% prefer topical gatifloxacin; 18% respondents use topical antibiotic for 6 weeks, 40.6% use for 4 weeks, and 31.8% use for 1 week [Fig. 3].

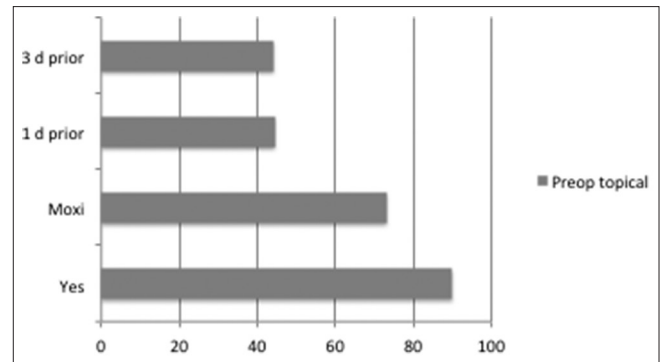
### Eye patching (In response to the question – do you patch the eye after cataract surgery? total responses 4158)

Postoperatively, eye patch was advised routinely by 73% of the respondents and 23.6% of the respondents do not patch the eye. Rest the respondents patch the eye only if the surgery is done under peribulbar block. Patching was advised for 4–6 h by most of the respondents.

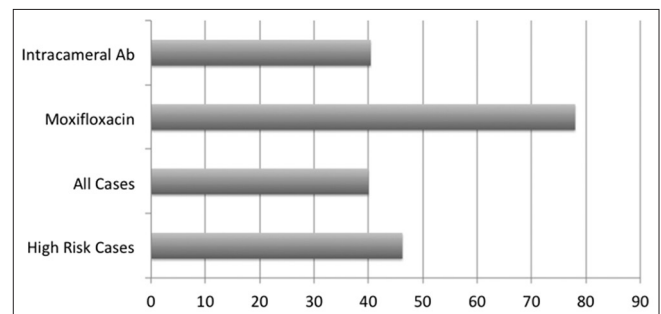
We compared this survey results with the 2014 survey of American Society of Cataract and Refractive Surgery (ASCRS) members [Table 2].<sup>[11]</sup> While all the questions were not asked in both the surveys, the major differences were in the choice of intracameral antibiotic (moxifloxacin preferred in India) and Indian-specific practices of postoperative subconjunctival antibiotic injection, longer duration of postoperative antibiotic use, and use of systemic antibiotics.

## Discussion

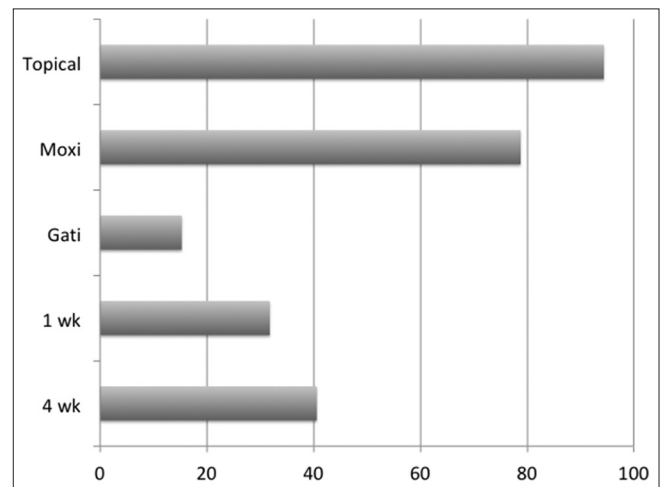
Cataract surgery-associated infections are not uncommon, but fortunately rare. There are three elements in any postoperative infection – the health personnel element, the surgical supply element, and the patient element. Any postoperative infection prolongs the hospital stay, induces long-term disabilities, and adds high cost to the patients and the health care system. These misfortunes could be avoided by adopting safe practices at all levels – adequate preparation of health-care personnel, securing supply from quality manufactures, and preparation of the patient and the surgical site. Some of the recommended practices for health-care personnel by the World Health Organization include hand hygiene, use of gloves, and surgical pause.<sup>[12]</sup> The most important patient-related factor in preventing endophthalmitis after exclusion of patients with untreated external eye diseases and lacrimal sac infection is the preparation of the eye with antiseptics such as 5% povidone-iodine. Ciulla *et al.* weighted various



**Figure 1:** Precataract surgery topical antibiotic practice: 90% prescribe topical antibiotics; 73.2% prefer moxifloxacin; 44.5% ophthalmologists use a day before surgery, and 44.2% prefer to use 3 days before surgery



**Figure 2:** Intracameral antibiotic practice: 40% use intracameral antibiotic at the end of cataract surgery; 46.2% of them use only in high-risk patients; 78% prefer moxifloxacin



**Figure 3:** Postcataract surgery topical antibiotic practice: 94.4% prescribe topical antibiotics; 78.8% prefer moxifloxacin; 15.3% prefer gatifloxacin; 40.6% ophthalmologists prescribe for 4 weeks, and 31.8% prescribe for 1 week

measures (such as pre- and post-operative topical and systemic antibiotics, subconjunctival antibiotic) and confirmed that only antiseptic preparation of the eye with povidone-iodine reached Level II evidence.<sup>[9]</sup> The recent suggestion of intracameral cefuroxime 1 mg at the end of cataract surgery after a multicenter trial in Europe reaches Level I evidence.<sup>[10]</sup>

**Table 2: Comparison of postcataract surgery endophthalmitis prevention practice pattern of American Society of Cataract and Refractive Surgery and All India Ophthalmological Society members**

Practice	Specific	ASCRS 2014% (n=1147)	AIOS 2017% (n=4292)
Preoperative preparation with 5% povidone-iodine		-	83.8%
Preoperative topical antibiotic		85.0	90.0
	Gatifloxacin or Moxifloxacin	60.0	Moxi: 74.5 Gati: 15.3
	3 days before surgery	48.0	44.9
	1 day before surgery	32.0	44.2
Intracameral antibiotic		50.0	40.0
	Cefuroxime	26.0	7.8
	Moxifloxacin	33.0	78.0
	Vancomycin	22.0	14.2
	Intracameral routine	-	36.6
	Intracameral High risk	-	46.2
	For last 2 years	-	40.4
	For last 6 months	-	19.7
Antibiotic at the end of surgery	Subconjunctival	8.0	46.0
Postoperative topical antibiotic		97.0	94.4
	1 week or less	72.0	31.8
	Several weeks	21.0	58.6
Perioperative systematic antibiotic		-	57.9
	Preoperative	-	13.6
	Postoperative	-	44.3

ASCRS: American Society of Cataract and Refractive Surgery, AIOS: All India Ophthalmological Society, Gati: Gatifloxacin, Moxi: Moxifloxacin

Following the European Cataract and Refractive Surgeons (ESCRS) study recommendation (2007), there are three publications from India on the use of intracameral antibiotic. Sharma *et al.* compared 7000 plus patients each with and without intracameral cefuroxime. They did not find a statistical difference in the incidence of both clinical- and culture-proven endophthalmitis, and the odds of infection when not using intracameral cefuroxime was 1.42.<sup>[7]</sup> This study did not recommend routine use of intracameral cefuroxime; rather it recommended using in high-risk patients only. HariPriya *et al.* used intracameral moxifloxacin and showed its efficacy in reducing the incidence of endophthalmitis in a large number of patients and in all forms of cataract surgery.<sup>[13,14]</sup> These studies recommended routine use of intracameral moxifloxacin in all types of cataract surgery including posterior capsular dehiscence.

The AIOS survey in the fall of 2017 was conducted 2½ decades after recommendation for povidone-iodine preparation of the surgical site, 1 decade after the ESCRS multicenter study suggesting intracameral cefuroxime, and 1 year after the Indian study suggesting intracameral moxifloxacin.

These published studies and recommendations have differentially influenced the practice pattern of Indian ophthalmologists. This is demonstrated by the fact that only 83% of respondents prepare the surgical site with povidone-iodine, 90% of respondents use preoperative antibiotic, <40% of respondents routinely use intracameral antibiotic (and 46.2% of them only in high-risk patients), and 94% respondents use postoperative antibiotic.

Three striking differences from the 2014 ASCRS members practice were (1) the choice of antibiotic – moxifloxacin both

for topical application and intracameral injection whenever it was given, (2) the practice of subconjunctival injection at conclusion of cataract surgery, and (3) postoperative systemic antibiotics by close to half of the respondents. The choice of moxifloxacin could be explained by the fact that it has a better coverage than cefuroxime particularly against Gram-negative organism and the fact that at least a quarter of infection is caused by Gram-negative bacteria in India.<sup>[15]</sup> The other factor in the choice of intracameral use could be its availability as a solution and does not require to be reconstituted like cefuroxime; in the ASCRS, 49% of respondents would not give intracameral injection for fear of compounding risk.<sup>[11]</sup> The practice of subconjunctival injection by 46% of respondents and practice of postoperative systemic antibiotics by 44.3% of respondents do not have any scientific basis. The similarity between the 2014 ASCRS members practice was in the use of intracameral antibiotic at the end of the cataract surgery – 50% of the ASCRS member respondents and 40% of AIOS respondents. This is despite the fact that the ASCRS and AIOS surveys were done 7 years and 10 years after the ESCRS study recommendation, respectively. The other interesting fact was that 40.4% of the respondents are using intracameral antibiotic only for last 2 years and 19.7% are the neo-converts in the past 6 months. Nearly half, i.e., 46%, of the intracameral antibiotic users in the AIOS respondents would use it only in high-risk patients. While the survey questionnaire did not identify the “high-risk” patients, we presume that they would include posterior capsular break during surgery, anterior vitrectomy during surgery, prolonged surgery (>40 min), difficult surgery (excessive iris manipulation), corneal surface disorders, elderly individuals (>80 years), and immunocompromised people. The most surprising finding was that preparation of

the eye and surrounding skin with 5% povidone-iodine is still not a universal practice among the Indian ophthalmologists.

## Conclusion

The practice of Indian ophthalmologists in the prevention of endophthalmitis after cataract surgery does not always conform to the evidence-based standard of care. It is felt necessary to impart the need for povidone-iodine preparation of the eye and reduce the health system cost by not practicing subconjunctival antibiotic injection and postoperative systemic antibiotics. We also anticipate an increase in the use of intracameral antibiotic, and of the two, cefuroxime and moxifloxacin, the latter would be increasingly used in India. This is the first of its kind survey of AIOS members and if repeated a few years later would record the changing trend in practice pattern of Indian ophthalmologists, and firm conclusions based on the current study may not be appropriate. The real world data will be very useful in the future program planning.

## Financial support and sponsorship

Nil.

## Conflicts of interest

There are no conflicts of interest.

## References

1. Available from: <http://www.npcb.nic.in>. [Last accessed on 2017 Dec 21].
2. Jambulingam M, Parameswaran SK, Lysa S, Selvaraj M, Madhavan HN. A study on the incidence, microbiological analysis and investigations on the source of infection of postoperative infectious endophthalmitis in a tertiary care ophthalmic hospital: An 8-year study. *Indian J Ophthalmol* 2010;58:297-302.
3. Das T, Hussain A, Naduvilath T, Sharma S, Jalali S, Majji AB, *et al*. Case control analyses of acute endophthalmitis after cataract surgery in South India associated with technique, patient care, and socioeconomic status. *J Ophthalmol* 2012;2012:298459.
4. Ravindran RD, Venkatesh R, Chang DF, Sengupta S, Gyatsho J, Talwar B, *et al*. Incidence of post-cataract endophthalmitis at Aravind eye hospital: Outcomes of more than 42,000 consecutive cases using standardized sterilization and prophylaxis protocols. *J Cataract Refract Surg* 2009;35:629-36.
5. Lalitha P, Rajagopalan J, Prakash K, Ramasamy K, Prajna NV, Srinivasan M, *et al*. Postcataract endophthalmitis in South India incidence and outcome. *Ophthalmology* 2005;112:1884-9.
6. HariPriya A, Chang DF, Reena M, Shekhar M. Complication rates of phacoemulsification and manual small-incision cataract surgery at Aravind Eye Hospital. *J Cataract Refract Surg* 2012;38:1360-9.
7. Sharma S, Sahu SK, Dhillon V, Das S, Rath S. Reevaluating intracameral cefuroxime as a prophylaxis against endophthalmitis after cataract surgery in India. *J Cataract Refract Surg* 2015;41:393-9.
8. Speaker MG, Menikoff JA. Prophylaxis of endophthalmitis with topical povidone-iodine. *Ophthalmology* 1991;98:1769-75.
9. Ciulla TA, Starr MB, Masket S. Bacterial endophthalmitis prophylaxis for cataract surgery: An evidence-based update. *Ophthalmology* 2002;109:13-24.
10. Endophthalmitis Study Group, European Society of Cataract and Refractive Surgeons. Prophylaxis of postoperative endophthalmitis following cataract surgery: Results of the ESCRS multicenter study and identification of risk factors. *J Cataract Refract Surg* 2007;33:978-88.
11. Chang DF, Braga-Mele R, Henderson BA, Mamalis N, Vasavada A; ASCRS Cataract Clinical Committee. Antibiotic prophylaxis of postoperative endophthalmitis after cataract surgery: Results of the 2014 ASCRS member survey. *J Cataract Refract Surg* 2015;41:1300-5.
12. World Health Organization. WHO Guidelines for Safe Surgery 2009. World Health Organization; 2009. Available from: <http://www.who.int/gpsc>. [Last accessed on 2017 Dec 21].
13. HariPriya A, Chang DF, Namburur S, Smita A, Ravindran RD. Efficacy of intracameral moxifloxacin endophthalmitis prophylaxis at Aravind eye hospital. *Ophthalmology* 2016;123:302-8.
14. HariPriya A, Chang DF, Ravindran RD. Endophthalmitis reduction with intracameral moxifloxacin prophylaxis: Analysis of 600 000 surgeries. *Ophthalmology* 2017;124:768-75.
15. Das T. Redefining evidence in the management of acute post-cataract surgery endophthalmitis in India – The 2014 Adenwalla Oration, All India Ophthalmological Society. *Indian J Ophthalmol* 2017;65:1403-6.