



Short-Term Outcomes of the First in Vivo Gene Therapy for RPE65-Mediated Retinitis Pigmentosa

Jay Jiyong Kwak¹, Hae Rang Kim², and Suk Ho Byeon¹

¹Institute of Vision Research, Department of Ophthalmology, Yonsei University College of Medicine, Seoul;

²Department of Ophthalmology, CHA Bundang Medical Center, CHA University School of Medicine, Seongnam, Korea.

Here, we report early treatment outcomes of gene therapy for early onset retinitis pigmentosa (RP) (Leber congenital amaurosis) associated with biallelic *RPE65* mutation in a 30-year-old female patient. Initially, her visual acuity (VA) was 20/200, and her visual field (VF) was severely constricted to the center in the left eye. Her electroretinography showed nearly extinct signals. Full-field stimulus threshold test (FST) revealed diminished dark-adapted light sensitivity. Voretigene neparvovec-rzyl (VN) is the first in vivo viral gene therapy agent to be approved. At 3 months after subretinal injection of VN in the left eye, VA, VF, and FST showed sustained improvement. She did not exhibit any signs of adverse effects from the treatment. Gene therapy for RP proved to be an effective and safe treatment in an advanced case of *RPE65*-associated early onset RP.

Key Words: Retinitis pigmentosa, leber congenital amaurosis, hereditary eye disease, gene therapy

INTRODUCTION

Inherited retinal diseases (IRDs) refer to a large group of clinically and genetically heterogeneous disorders characterized by photoreceptor degeneration or dysfunction.¹ *RPE65*-mediated retinal dystrophy is one type of IRD in which mutation of the *RPE65* gene leads to inhibition of RPE65 all-*trans*-retinyl isomerase activity, thereby leading to decreased levels of rhodopsin and eventually to photoreceptor and retinal pigment epithelium (RPE) cell loss.^{2,3} Early symptoms include night blindness and nystagmus, with progressive deterioration in visual acuity (VA) and visual field (VF). Disease onset ranges from congenital to late adulthood.^{3,4}

Gene therapy is a new treatment option for IRD patients. Adeno-associated viral (AAV) vectors represent the most prom-

ising approach for IRDs as they lack pathogenicity, exhibit minimal immunogenicity, and mediate sustained levels of transgenic expression.^{3,5} As retinal cell degeneration is irreversible, vector efficacy depends on the number of viable cells available, as well as the ability to reach target cells effectively.^{3,5} Voretigene neparvovec-rzyl (VN; brand name Luxturna[®], Spark Therapeutics Inc, Philadelphia, PA, USA) is the first approved recombinant AAV vector-based gene therapy designed to deliver a functioning copy of the human *RPE65* gene into viable RPE cells via a single subretinal injection, providing the potential to restore visual cycle.³ We report the clinical outcomes of a patient who was treated with VN. Written informed consent was obtained from the patient.

CASE REPORT

A 30-year-old female patient visited our clinic for progressive vision loss. She first presented to us at age 2 with low vision. There was no known ocular disease in her family except for her younger brother who complained of low vision. The patient underwent vitrectomy for macular holes in her right eye at age 27. Preoperative best-corrected visual acuities (BCVAs) were 20/500 in the right eye and 20/200 in the left eye. Dilated fundus examination revealed salt-and-pepper mottling (Fig. 1A-1 and B-1). Her bilateral VF was severely constricted (Fig.

Received: February 15, 2022 **Revised:** March 29, 2022

Accepted: March 30, 2022

Corresponding author: Suk Ho Byeon, MD, PhD, Department of Ophthalmology, Yonsei University College of Medicine, 50-1 Yonsei-ro, Seodaemun-gu, Seoul 03722, Korea.

Tel: 82-2-2228-3583, Fax: 82-2-312-0541, E-mail: shbyeon@yuhs.ac

•The authors have no potential conflicts of interest to disclose.

© Copyright: Yonsei University College of Medicine 2022

This is an Open Access article distributed under the terms of the Creative Commons Attribution Non-Commercial License (<https://creativecommons.org/licenses/by-nc/4.0>) which permits unrestricted non-commercial use, distribution, and reproduction in any medium, provided the original work is properly cited.

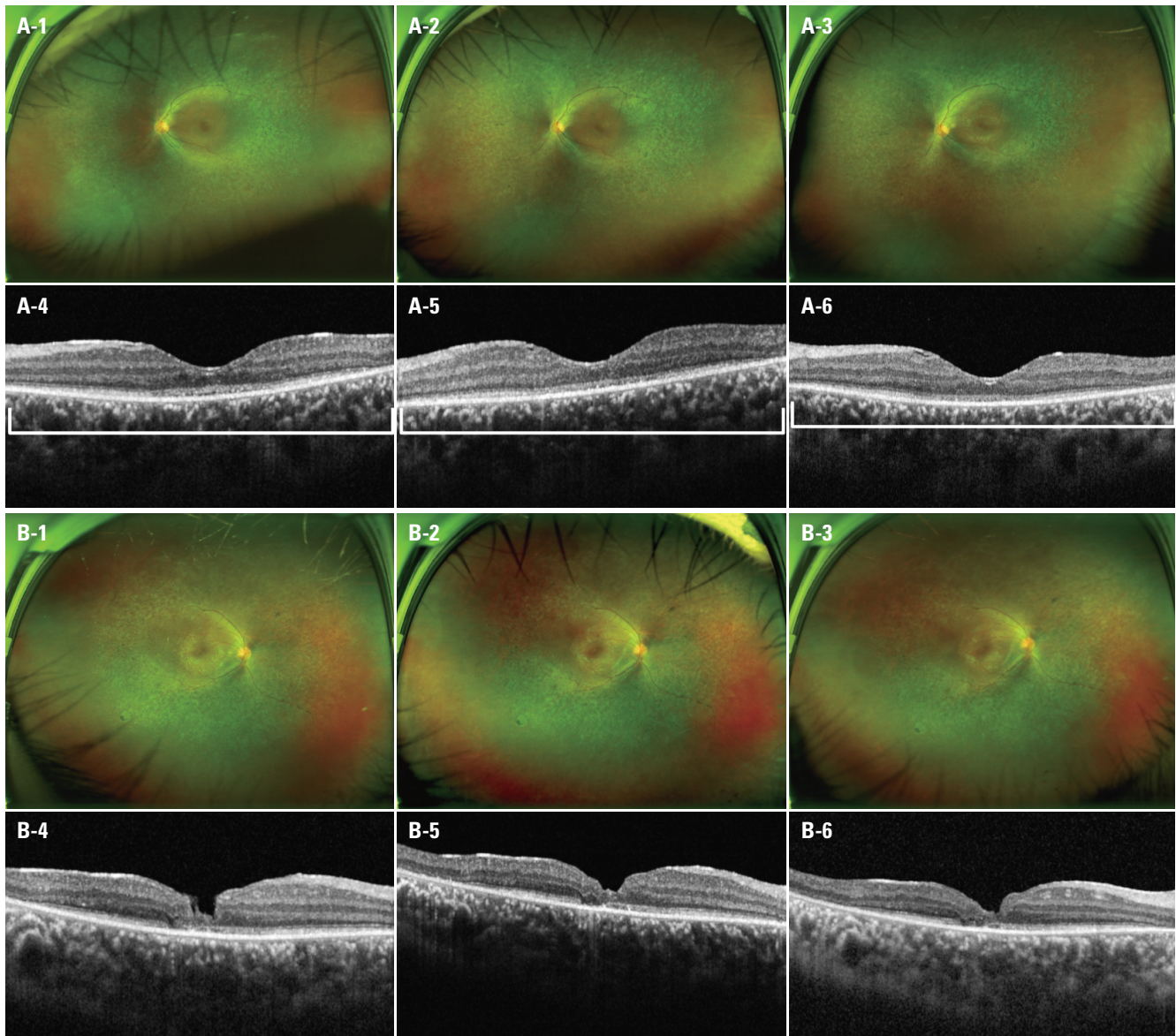


Fig. 1. Wide fundus images of the left eye before gene therapy (A-1), 1 month after treatment (A-2), and 3 months after treatment (A-3). Optical coherence tomography (OCT) scans of the fovea in the left eye before gene therapy (A-4), 1 month after treatment (A-5), and 3 months after treatment (A-6). Increased foveal reflex is noted in fundus images with time. OCT images show more definite foveal outer retinal layers with time (square brackets). Wide fundus images of the right eye at baseline (B-1), 1 month (B-2), and 3 months (B-3). OCT images of the right eye at baseline (B-4), 1 month (B-5), and 3 months (B-6).

2A-1, A-4, B-1, and B-4). Spectral-domain optical coherence tomography (OCT) revealed outer retinal and RPE atrophy (Fig. 1A-4 and B-4). Preoperative full-field stimulus threshold test (FST) for her left eye showed -3.13 dB for white signals. Genetic testing identified c.1543C>T and c.1067dupA biallelic compound heterozygote mutations in the *RPE65* gene.⁶⁻⁹

Three days before injection, the patient was given oral corticosteroids (40 mg/day) in order to counteract any potential immunization effects of the viral vector and transgene.¹⁰ The active substance and solvent of VN were stored at a temperature below -65°C and thawed at the time of use. The preparation of VN took place aseptically. Under general anesthesia, 25-gauge pars planar vitrectomy was performed on the left eye. After a core vit-

rectomy and induction of posterior vitreous detachment, we injected VN subretinally, superonasal and inferonasal to the fovea, with a 41-gauge cannula, resulting in two blebs (Fig. 3).

As early as 1 month after treatment, the patient noted subjective improvement in central vision of her left eye though BCVA (20/400) did not show improvement. BCVA in her left eye improved to 20/100 at 3 months. For her right eye, BCVA at 1 and 3 months remained at 20/500. Humphrey and Goldmann VF tests revealed improved central VF at 1 and 3 months in her left eye (Fig. 2A-2, A-3, A-5, and A-6), but not in the right eye (Fig. 2B-2, B-3, B-5, and B-6). Based on results from worsening Humphrey VF and stationary BCVA in her right eye, we concluded that that Goldmann VF at 3 months for her right

eye was not taken accurately. VF index (VFI) in the left eye increased from 9% preoperatively to 10% and 11% at 1 and 3 months, respectively. VFI in the right eye decreased from 10% preoperatively to 8% and 5% at 1 and 3 months. Though wide

fundus photographs of the left eye did not show noticeable changes, compared to her right eye, during the 3 months of follow up (Fig. 1A-2, A-3, B-2, and B-3), her OCT scans of the left eye showed more distinct photoreceptor inner segment/outer

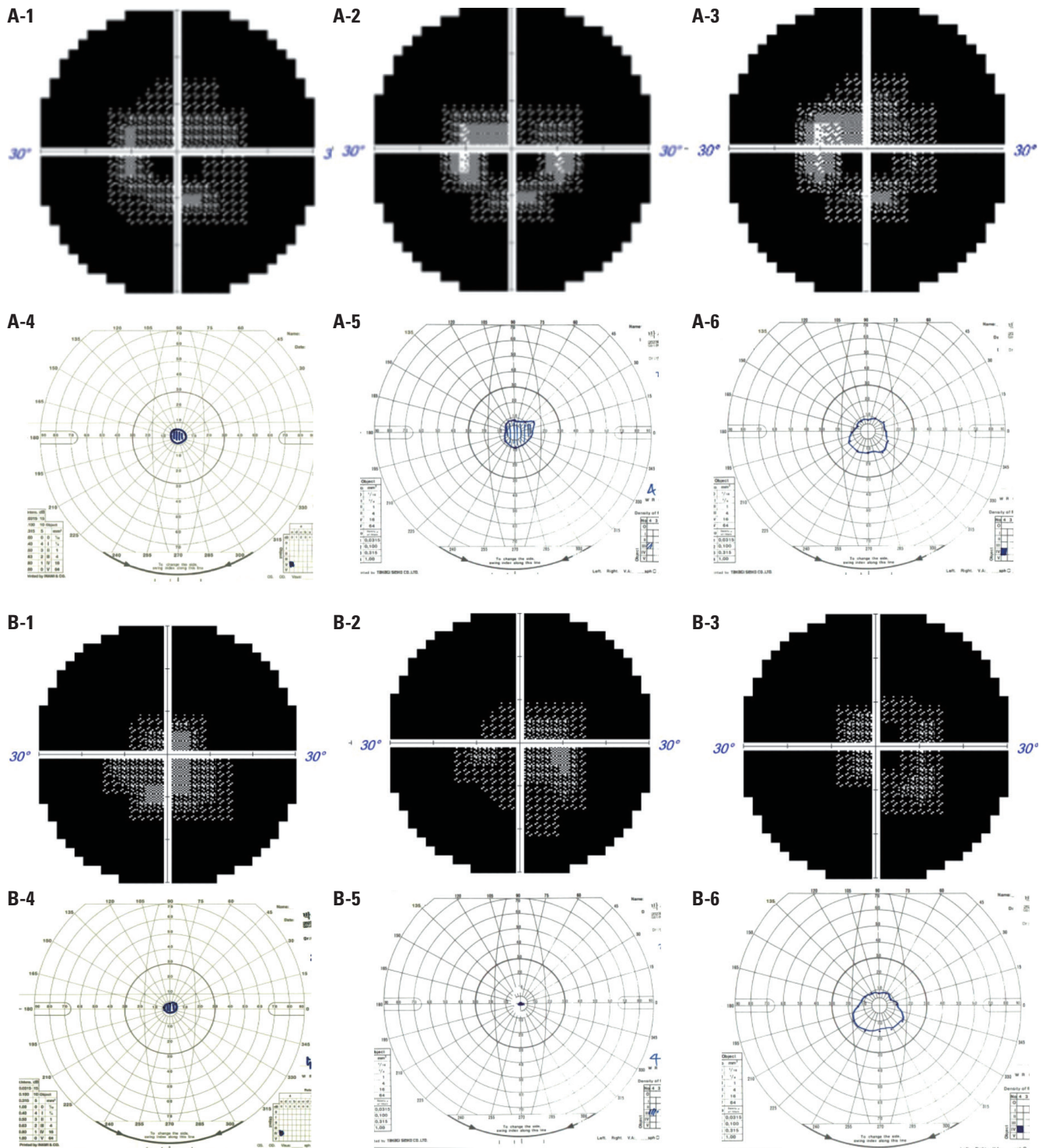


Fig. 2. Humphrey visual field (VF) tests of the left eye before gene therapy (A-1), 1 month after treatment (A-2), and 3 months after treatment (A-3). Goldmann VF tests of the left eye before gene therapy (A-4), 1 month after treatment (A-5), and 3 months after treatment (A-6). Both tests show that the patient's central VF improved with time after treatment. Humphrey VF tests of the right eye at baseline (B-1), 1 month (B-2), and 3 months (B-3). Goldmann VF tests of the right eye at baseline (B-4), 1 month (B-5), and 3 months (B-6).

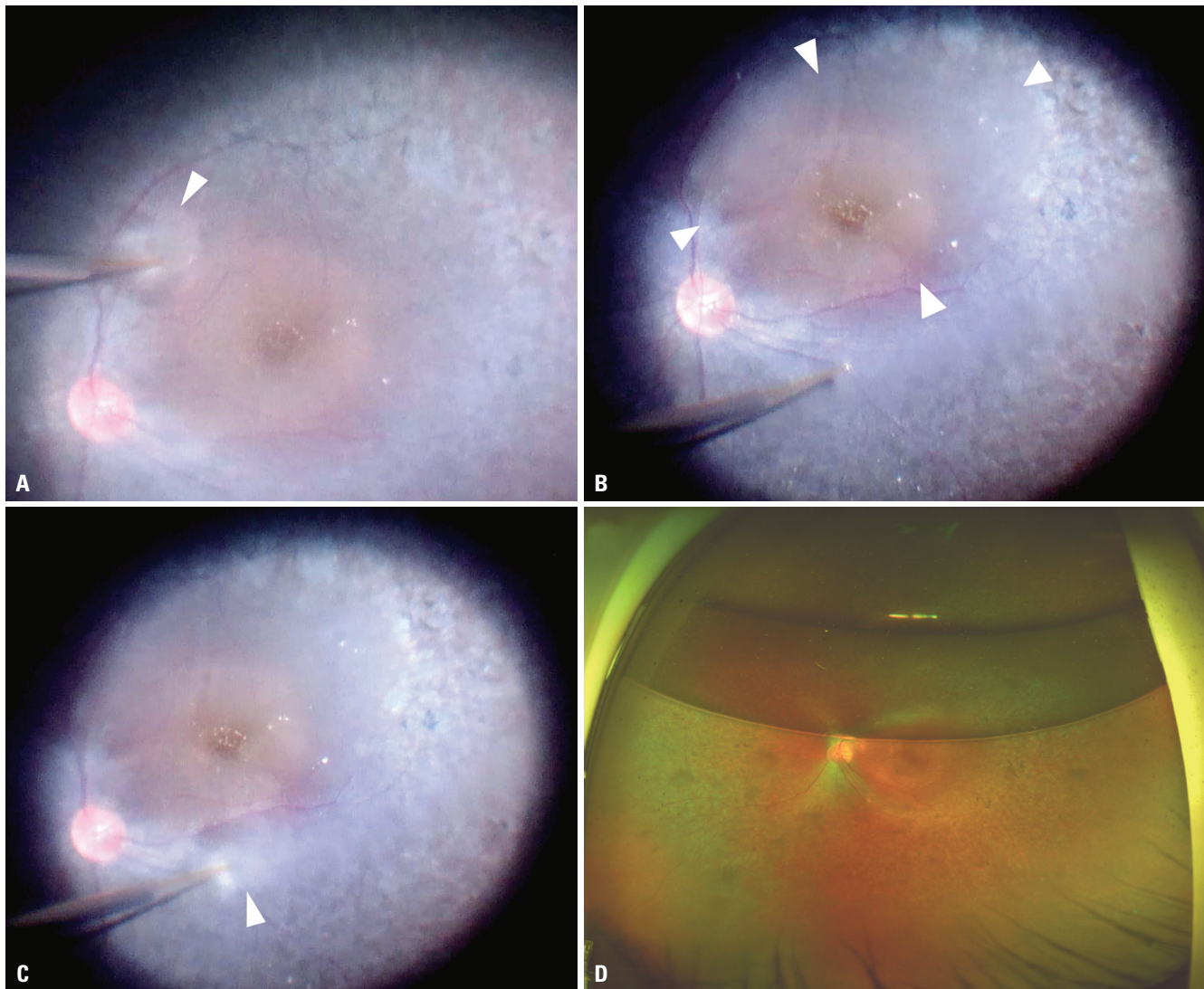


Fig. 3. Intraoperative images of subretinal injection blebs. Formation of the bleb at the superonasal fovea (A), complete formation of the superonasal bleb (B), formation of the bleb at the inferonasal fovea (C). Blebs were no longer observed as early as postoperative day 3 (D). Blebs are marked with white arrowheads.

segment junction line up to 3 months, compared to her right eye (Fig. 1A-5, A-6, B-5, and B-6). FST results for white signals improved to -23.4 and -29.8 dB at 1 and 3 months, respectively. The patient did not show any signs of adverse effects, including, intraocular inflammation, macular hole, and retinal detachment (Fig. 1A-2 and A-3).

DISCUSSION

VN is the first and so far the only gene therapy for IRDs. Unlike other treatments, such as nutritional supplement for macular degeneration, VN is a durable therapy tantamount to cure of *RPE65*-mediated early onset RP [Leber congenital amaurosis (LCA)]. The longstanding efficacy of VN is derived from the fact that the therapeutic gene is incorporated into the cell nucleus as a stable extragenic episome, designed to be expressed

constitutively.¹¹

RPE65-mediated early onset retinitis pigmentosa (RP) (LCA) is known to cause night blindness, substantial loss of vision, and progressive VF loss during the first three decades of life.^{6,12} Patients over age 30 suffer from near-total blindness.^{13,14} At age 9, this patient showed severe rod-cone dysfunction on electroretinography with peripheral retinal pigmentary change. By age 15, her peripheral VF was substantially constricted. At age 30, BCVA was 20/200, and VF was severely constricted in her left eye, indicating advanced stage. The indication for VN is that the patient must have viable retinal cells, with retinal thickness at the posterior pole greater than 100 μm . Despite being at an advanced stage, the patient was considered appropriate to undergo VN because the outer retina was preserved and retinal thickness at the posterior pole was 141 μm . We decided to treat only her left eye as her right eye had been treated with macular hole operation, which would have drastically

reduced the efficacy of VN. After treatment, the patient showed improvement in VF and FST at 1 month, which continued to improve at 3 months. Drastic improvement in BCVA may have been limited due to the fact that BCVA is a measure of foveal, cone-mediated function and that BCVA was not the primary target of the intervention in this rod-mediated disease.¹⁴ Moreover, our patient already showed signs of advanced disease. Previous reports have indicated that young children with better VA and a relatively preserved outer retinal layer show the greatest improvement, compared to adults.^{15,16} The patient in this study experienced visual improvement that cannot be simply measured by BCVA or VF tests. She claimed that she is now able to see objects clearly and to walk independently at night.

One limitation of AAV vectors include their limited packaging capacity. Treatment of IRDs caused by mutations in genes whose coding sequence exceeds 5 kb require dual AAV vectors or other vectors with larger packing capacity.⁵ In addition, due to the rarity of the disease, large-scale, long-term follow-up results are limited. However, recent reports have shown that VN improved visual function up to 3 to 5 years.^{17,18}

We report the post-treatment outcomes of VN in *RPE65*-mediated early onset RP. With careful patient selection, VN is an effective therapy that leads to improvement in visual and anatomical outcomes in *RPE65*-mediated early onset RP (LCA) within months. Continued long-term observation is planned.

ACKNOWLEDGEMENTS

This work was supported by a National Research Foundation of Korea (NRF) grant funded by the Korea government (Ministry of Science and ICT) (No. 2019R1A2C2086729).

AUTHOR CONTRIBUTIONS

Conceptualization: Jay Jiyong Kwak and Suk Ho Byeon. **Data curation:** all authors. **Formal analysis:** all authors. **Funding acquisition:** Suk Ho Byeon. **Investigation:** Jay Jiyong Kwak and Suk Ho Byeon. **Methodology:** Suk Ho Byeon. **Project administration:** Suk Ho Byeon. **Resources:** Suk Ho Byeon. **Software:** all authors. **Supervision:** Suk Ho Byeon. **Validation:** Suk Ho Byeon. **Visualization:** all authors. **Writing—original draft:** Jay Jiyong Kwak and Suk Ho Byeon. **Writing—review & editing:** Jay Jiyong Kwak and Suk Ho Byeon. **Approval of final manuscript:** all authors.

ORCID iDs

Jay Jiyong Kwak <https://orcid.org/0000-0002-7738-9136>
 Hae Rang Kim <https://orcid.org/0000-0003-3226-6148>
 Suk Ho Byeon <https://orcid.org/0000-0001-8101-0830>

REFERENCES

1. Georgiou M, Fujinami K, Michaelides M. Inherited retinal diseases: therapeutics, clinical trials and end points—A review. *Clin Exp*

- Ophthalmol* 2021;49:270-88.
- Travis GH, Golczak M, Moise AR, Palczewski K. Diseases caused by defects in the visual cycle: retinoids as potential therapeutic agents. *Annu Rev Pharmacol Toxicol* 2007;47:469-512.
 - Kang C, Scott LJ. Voretigene neparovec: a review in RPE65 mutation-associated inherited retinal dystrophy. *Mol Diagn Ther* 2020;24:487-95.
 - Astuti GD, Bertelsen M, Preising MN, Ajmal M, Lorenz B, Faradz SM, et al. Comprehensive genotyping reveals RPE65 as the most frequently mutated gene in Leber congenital amaurosis in Denmark. *Eur J Hum Genet* 2016;24:1071-9.
 - Ziccardi L, Cordeddu V, Gaddini L, Matteucci A, Parravano M, Malchiodi-Albedi F, et al. Gene therapy in retinal dystrophies. *Int J Mol Sci* 2019;20:5722.
 - Lopez-Rodriguez R, Lantero E, Blanco-Kelly F, Avila-Fernandez A, Martin Merida I, Del Pozo-Valero M, et al. RPE65-related retinal dystrophy: mutational and phenotypic spectrum in 45 affected patients. *Exp Eye Res* 2021;212:108761.
 - Hull S, Holder GE, Robson AG, Mukherjee R, Michaelides M, Webster AR, et al. Preserved visual function in retinal dystrophy due to hypomorphic RPE65 mutations. *Br J Ophthalmol* 2016;100:1499-505.
 - Katagiri S, Hosono K, Hayashi T, Kurata K, Mizobuchi K, Matsuura T, et al. Early onset flecked retinal dystrophy associated with new compound heterozygous RPE65 variants. *Mol Vis* 2018;24:286-96.
 - Kondo H, Qin M, Mizota A, Kondo M, Hayashi H, Hayashi K, et al. A homozygosity-based search for mutations in patients with autosomal recessive retinitis pigmentosa, using microsatellite markers. *Invest Ophthalmol Vis Sci* 2004;45:4433-9.
 - Maguire AM, Bennett J, Aleman EM, Leroy BP, Aleman TS. Clinical perspective: treating RPE65-associated retinal dystrophy. *Mol Ther* 2021;29:442-63.
 - Ciulla TA, Hussain RM, Berrocal AM, Nagiel A. Voretigene neparovec-rzyl for treatment of RPE65-mediated inherited retinal diseases: a model for ocular gene therapy development. *Expert Opin Biol Ther* 2020;20:565-78.
 - Gu SM, Thompson DA, Srikumari CR, Lorenz B, Finckh U, Nicoletti A, et al. Mutations in RPE65 cause autosomal recessive childhood-onset severe retinal dystrophy. *Nat Genet* 1997;17:194-7.
 - Chung DC, Bertelsen M, Lorenz B, Pennesi ME, Leroy BP, Hamel CP, et al. The natural history of inherited retinal dystrophy due to biallelic mutations in the RPE65 gene. *Am J Ophthalmol* 2019;199:58-70.
 - Russell S, Bennett J, Wellman JA, Chung DC, Yu ZF, Tillman A, et al. Efficacy and safety of voretigene neparovec (AAV2-hRPE65v2) in patients with RPE65-mediated inherited retinal dystrophy: a randomised, controlled, open-label, phase 3 trial. *Lancet* 2017;390:849-60.
 - Maguire AM, High KA, Auricchio A, Wright JE, Pierce EA, Testa F, et al. Age-dependent effects of RPE65 gene therapy for Leber's congenital amaurosis: a phase 1 dose-escalation trial. *Lancet* 2009;374:1597-605.
 - Weleber RG, Pennesi ME, Wilson DJ, Kaushal S, Erker LR, Jensen L, et al. Results at 2 years after gene therapy for RPE65-deficient Leber congenital amaurosis and severe early-childhood-onset retinal dystrophy. *Ophthalmology* 2016;123:1606-20.
 - Maguire AM, Russell S, Chung DC, Yu ZF, Tillman A, Drack AV, et al. Durability of voretigene neparovec for biallelic RPE65-mediated inherited retinal disease: phase 3 results at 3 and 4 years. *Ophthalmology* 2021;128:1460-8.
 - Bennett J, Russell SR, High KA, Drack AV, Yu ZF, Chung DC, et al. Five-year post-injection results of the phase 3 trial of voretigene neparovec-rzyl in biallelic RPE65 mutation-associated inherited retinal disease. *Investig Ophthalmol Vis Sci* 2021;62:3540.