

Received: 2016.06.29
Accepted: 2016.08.03
Published: 2016.11.08

Airway Obstruction Secondary to Emphysematous Epiglottitis: A Case Report

Authors' Contribution:
Study Design A
Data Collection B
Statistical Analysis C
Data Interpretation D
Manuscript Preparation E
Literature Search F
Funds Collection G

EF 1 **Marc R. Rohrbach**
E 2 **Sepehr Shabani**
E 1 **Aaron Wieland**

1 Division of Otolaryngology-Head & Neck Surgery, Department of Surgery, School of Medicine and Public Health, University of Wisconsin, Madison, WI, U.S.A.
2 School of Medicine and Public Health, University of Wisconsin, Madison, WI, U.S.A.

Corresponding Author: Marc R. Rohrbach, e-mail: MRohrbach@uwhealth.org
Conflict of interest: None declared

Patient: Male, 59
Final Diagnosis: Emphysematous epiglottitis
Symptoms: Dysphonia •odynophagia • sore throat
Medication: —
Clinical Procedure: Direct laryngoscopy with incision and drainage of abscess
Specialty: Otolaryngology





Objective: Rare disease
Background: Despite a shift in the epidemiology of epiglottitis following the introduction of the *Haemophilus influenzae* type B vaccine, acute infectious epiglottitis continues to be a relatively common and potentially life-threatening infection in adults. Epiglottitis complicated by abscess is rare, and emphysematous abscess is even less common. Early diagnosis and intervention is paramount in reducing morbidity and mortality. Although case reports exist, photographic depiction of this complication is not readily available.

Case Report: We present the case of a 59-year-old male with rapidly progressive emphysematous epiglottitis managed with awake fiber optic intubation followed by incision, drainage, and antibiotic therapy. Early recognition and intervention in this patient led to complete resolution of the infection, with no long-term sequelae.

Conclusions: Clinicians should be familiar with the radiographic and endoscopic findings which support an emphysematous abscess, as well as the treatment and airway management concerns in such cases.

MeSH Keywords: Airway Obstruction • Epiglottitis • Otolaryngology

Full-text PDF: <http://www.amjcaserep.com/abstract/index/idArt/900334>

 787  —  3  4



Background

Acute infectious epiglottitis is a rapidly progressive and potentially fatal infection of the upper respiratory tract. Historically, this condition was most commonly seen in children, resulting from *Haemophilus influenzae* infections. Following the introduction of the *Haemophilus influenzae* type B vaccine, there has been a shift in the etiology and epidemiology of epiglottitis, with a rise in adult infections [1,2]. Epiglottitic abscess formation is a rare complication of epiglottitis [1]. Epiglottitis complicated by emphysematous abscess formation has been reported even less frequently, and is not well described [3]. Here, we present a case of an otherwise healthy male patient with emphysematous epiglottitis necessitating awake fiber optic intubation and surgical drainage.

Case Report

A 59-year-old Caucasian male presented to the emergency department (ED) with a one day history of odynophagia and dysphagia with rapid progression to dysphonia and inability to swallow his oral secretions. He reported having intermittent fevers at home, along with fatigue and a productive cough, but denied any breathing difficulties or stridor. The patient had a long history of smoking, but was otherwise healthy. In the ED, he was afebrile, hypertensive and tachycardic, with a muffled voice quality and productive cough, but no stridor. Physical examination revealed only tender bilateral cervical lymphadenopathy and pain near the hyoid. Laboratory workup was remarkable for a leukocytosis of 20.2 k/uL with 91% neutrophils. A computed tomography (CT) scan with intravenous (IV) contrast

of the neck was performed and was significant for a markedly enlarged epiglottis secondary to submucosal emphysema along the lingual surface (Figure 1). These changes resulted in marked narrowing of the supraglottic airway with sparing of the glottic and subglottic airway. Inflammatory changes also involved the floor of the mouth, oropharynx and hypopharynx, with multiple small abscesses noted within the left ventral floor of mouth and right palatine tonsil.

Flexible fiber optic laryngoscopy revealed significant pooling of secretions and a diffusely swollen epiglottis, with moderate edema of the remainder of the supraglottis (Figure 2). The vocal cords had normal mobility and were not edematous. The patient was taken to the operating room urgently and underwent awake trans-nasal fiber optic intubation followed by direct laryngoscopy with biopsy and abscess drainage. Although purulence was encountered, unfortunately no cultures were sent for evaluation. Following decompression of the epiglottis, the trans-nasal tube was exchanged for trans-oral size six cuffed endotracheal tube and the patient was left intubated, but breathing spontaneously, and admitted to the Intensive Care Unit (ICU). He was treated with IV ampicillin/sulbactam 1.5 grams (1 gram ampicillin plus 0.5 gram sulbactam) every six hours, and IV dexamethasone at 6 mg every six hours. He underwent bedside direct laryngoscopy in the ICU approximately 36 hours after his abscess drainage, and this revealed improvement in his supraglottic edema. He was successfully extubated shortly thereafter, the steroids were discontinued, and he was transitioned to oral amoxicillin/clavulanic acid, 800/114 mg twice daily. He was discharged on postoperative day three with an additional ten days of amoxicillin/clavulanic acid, 800/114 mg twice daily. He was fully recovered when

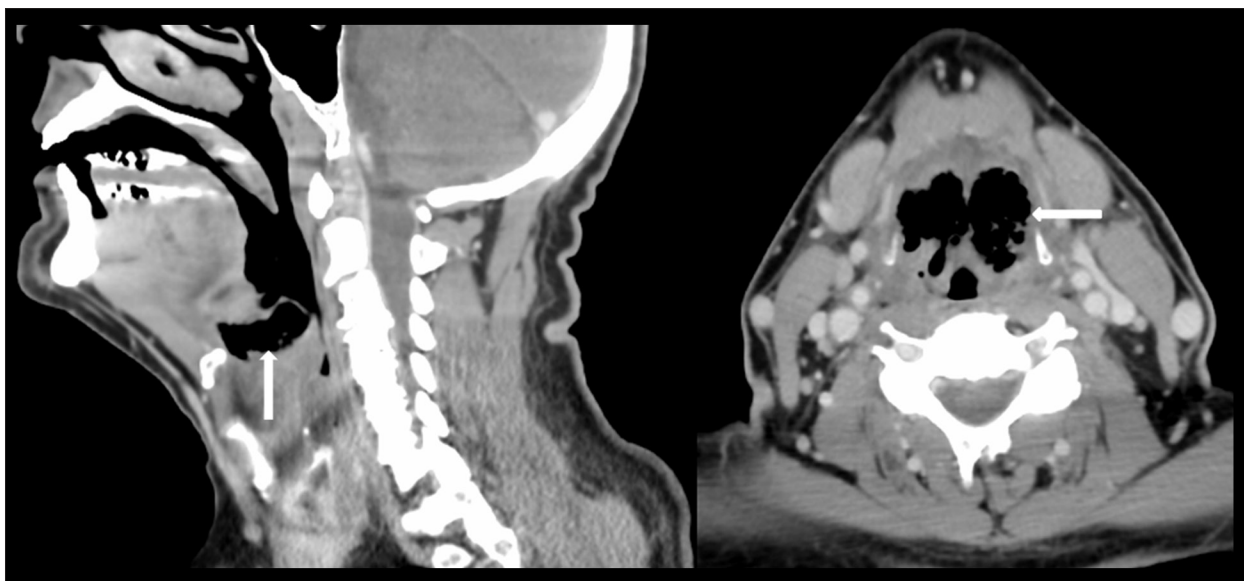

Figure 1. Contrasted CT of the neck showing submucosal emphysema (arrows) of the lingual surface of the epiglottis in sagittal and axial planes.

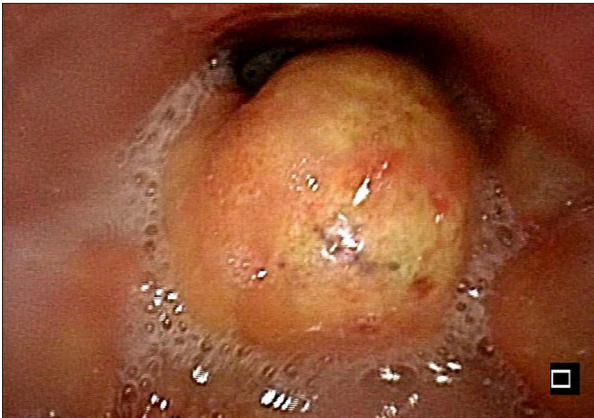


Figure 2. Endoscopic examination showing the epiglottis at the time of diagnosis.

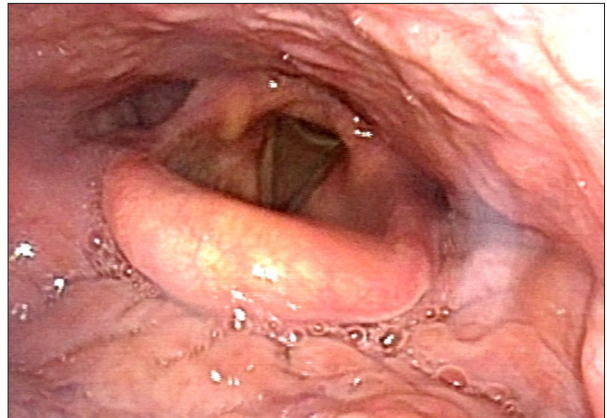


Figure 3. Endoscopic examination showing the epiglottis after resolution of infection.

seen in our clinic three weeks later, and flexible laryngoscopy confirmed complete resolution (Figure 3). Final pathology showed reactive squamous mucosa with acute inflammation and abscess formation.

Discussion

Acute epiglottitis in adults remains a serious and potentially life threatening illness. Despite the decline of *Haemophilus influenzae B* infections, other common pathogens in epiglottitis now include *Streptococcus pneumoniae*, β -hemolytic streptococci, and *Staphylococcus aureus* [4]. Epiglottic abscesses most commonly involve streptococcus or are polymicrobial [4]. Epiglottic abscess formation is rare and emphysematous epiglottitis is even less common. It has been hypothesized that epiglottic abscesses are more likely to form in adults rather than the pediatric population because the larger adult larynx tolerates more inflammation prior to airway compromise, allowing sufficient time for coalescence [4]. Cases with submucosal emphysema may be more rapidly progressive due to the additional mass effect of trapped air. Abscess formation

complicates airway management and also requires drainage. In this case, the bulbous nature of the epiglottis necessitated awake fiber optic intubation to avoid further airway compromise with sedation or supine positioning. Loss of tone and supine positioning may lead to a ball valve mechanism, with complete airway obstruction, and an inability to deliver positive pressure ventilation. In such cases, the neck may also need to be prepped for tracheotomy. Drainage should always take place after the airway has been secured. Mortality in cases of epiglottic abscess can be significantly decreased through early detection and initiation of broad spectrum antibiotic therapy, with transfer to the operating room for airway management and drainage when indicated.

Conclusions

Clinicians should be familiar with the endoscopic and radiologic findings which support an emphysematous epiglottic abscess, as well as the treatment and airway management concerns that arise in such cases.

References:

1. Hsieh JK, Phelan MP, Wu G: Epiglottic abscess. *Am J Emerg Med*, 2015; 33(5): 734.e5-7
2. Shah RK, Stocks C: Epiglottitis in the United States: National trends, variances, prognosis, and management. *Laryngoscope*, 2010; 120(6): 1256-62
3. Chang HW, Lin WJ, Hu SY: Acute epiglottitis complicating an emphysematous abscess. *CJEM*, 2013; 15(3): 184-85
4. Stack BC Jr, Ridley MB: Epiglottic abscess. *Indian J Otolaryngol Head Neck Surg*, 1995; 17(3): 263-65