



A serious adverse surgical event

Management of suspected HSV-1 keratitis in a donor cornea

Rebecca Kaye · Bernhard Steger · Jern Y. Chen · Vito Romano

Received: 17 September 2016 / Accepted: 16 December 2016 / Published online: 30 January 2017
© The Author(s) 2017. This article is available at SpringerLink with Open Access.

Summary

Purpose To describe the management of a serious adverse event in a patient undergoing penetrating keratoplasty (PK).

Case report A 68-year-old man underwent PK for an aphakic bullous keratopathy following previous complicated cataract surgery. He had no past history of herpetic disease. Storage of the corneoscleral disc in the transport bottle precluded microscopic examination. After placement of the trephined donor cornea on the open eye of the recipient, a large dendritiform geographic ulcer was noted on the donor cornea. A replacement cornea was used after changing potentially contaminated instruments. Intravenous antiviral treatment was commenced intraoperatively to reduce the risk of infection to the central nervous system. Postoperatively, oral and topical antiviral treatment was commenced and 6 months following surgery the patient developed a geographic corneal ulcer at the graft host interface.

Conclusion Containers to transport corneoscleral discs should enable microscopic examination by the surgeon prior to use. High dose systemic antivirals may reduce the risk of herpetic disease involving the posterior segment of the eye and neuroretina in the aphakic eye and spread to the central nervous system.

Keywords Herpes Simplex (HSV) · Keratitis · Donor · Recipient · Corneal Transplant

Schweres unerwünschtes Operationsereignis: Management einer vermuteten HSV-1-Keratitis in einer Spenderhornhaut

Zusammenfassung

Zweck Beschreibung des Managements eines unerwünschten Ereignisses bei einem Patienten, der eine penetrierende Keratoplastik (PK) erhielt.

Fallbericht Ein 68-jähriger männlicher Patient unterzog sich einer PK aufgrund einer aphaken bullösen Keropathie nach einer früheren komplizierten Kataraktoperation. Er hatte keine Vorgeschichte einer Herpeserkrankung. Aufgrund der Aufbewahrung der korneoskleralen Scheibe in der Transportflasche war eine mikroskopische Untersuchung nicht möglich. Nach dem Einbringen der präparierten Spenderhornhaut in das offene Auge des Empfängers wurde ein großes dendritisches (geographisches) Ulkus auf der Spenderhornhaut festgestellt. Es wurde eine Ersatzhornhaut verwendet, nachdem die potenziell kontaminierten Instrumente ausgetauscht worden waren. Intraoperativ wurde eine intravenöse antivirale Behandlung begonnen, um das Risiko einer Infektion des Zentralnervensystems zu reduzieren. Postoperativ wurde mit der oralen und topischen antiviralen Therapie begonnen. Sechs Monate nach der Operation entwickelte der Patient ein geographisches Hornhautulkus an der Grenzfläche von Transplantat und Wirtsgewebe.

Schlussfolgerung Behältnisse zum Transport von korneoskleralen Scheiben sollten vor deren Verwendung eine mikroskopische Untersuchung durch den Operateur erlauben. Hoch dosierte systemische antivirale Medikamente könnten das Risiko einer herpetischen Erkrankung reduzieren, die das hintere Augensegment

J. Y. Chen
Department of Corneal and External Eye Diseases, St. Paul's Eye Unit, Royal Liverpool University Hospital, Liverpool, UK

B. Steger · V. Romano
Department of Eye and Vision Science, University of Liverpool, Liverpool, UK

R. Kaye (✉)
Department of Eye and Vision Science, University Hospital Southampton, Tremona Road, Southampton, SO16 6YD, UK
Rebecca.kaye@uhs.nhs.uk

sowie die Neuroretina im phakischen Auge betreffen und eine Ausbreitung auf das Zentralnervensystem nach sich ziehen kann.

Schlüsselwörter Herpes Simplex (HSV) · Keratitis · Spender · Empfänger · Hornhauttransplantation

Introduction

Herpes simplex keratitis (HSK) is one of the major causes of corneal inflammation and corneal blindness, rated just second to trauma in most developed countries [1–3]. Clinical reports support the possible transmission of herpes simplex virus type 1 (HSV-1) via donor corneas and its role in graft failure [4]. Cleator et al. reported a case of primary graft failure due to presumed donor-to-host transmission of HSV following organ culture in a patient who underwent a penetrating keratoplasty for keratoconus [5]. It has also been reported that the HSV-1 may remain viable in stored corneal tissue at 4° [6]. There are reports of post-keratoplasty HSV-1 infection in patients with no history of an herpetic infection [7, 8] and evidence of donor-to-host transmission of the virus has also been demonstrated in animal studies. In rabbits, latently infected donor tissue can induce HSV-1 infection in naive recipients after penetrating keratoplasty [9]. HSV-1 inoculation in the anterior chamber of one eye has been shown to lead to the spread of virus to the brain, contralateral optic nerve and then posterior segment of contralateral eye [10, 11]. We report a case of clinically suspected HSK in the donor cornea following organ culture and subsequently in the recipient following penetrating keratoplasty and the perioperative management to reduce the infection risk and development of disease of the central nervous system.

Case report

A 68-year-old man underwent penetrating keratoplasty for aphakic bullous keratopathy and corneal

scarring. He had no history of herpetic disease. The donor cornea originated from a 71-year-old female who died due to chronic pulmonary disease. The time interval between death and transfer of the corneoscleral button into organ culture medium was 36 h. The endothelial count was 2400cell/mm² with mild polymegathism and pleomorphism. A 8.5 mm Hessberg–Barron trephine was used to prepare the donor cornea and a 8 mm trephine for the recipient. After placement of the donor onto the aphakic eye a large dendritic-geographic epithelial ulcer was noted (Fig. 1). The graft was removed, all surgical instruments were changed and the surgical staff regowned. Fortunately, a second donor corneoscleral disc was available, which was then used to complete the operation instead of resuturing the patient's own cornea back into place. The second donor originated from a 69-year-old male who died from a myocardial infarction. The time interval between death and transfer of the corneoscleral button into organ culture medium was 40 h. The endothelial count was 2600cell/mm² with some variation in cell size and shape.

Perioperative intravenous aciclovir was administered intravenously (5 mg/kg). Postoperatively, the patient was commenced on systemic and local antiviral therapy for 1 week (valaciclovir 1 g three times a day, acyclovir ointment five times per day) and local antibiotic treatment (chloramphenicol four times a day). Topical steroids were withheld for 48 h. At 1 week the graft was clear and had re-epithelialized. Long term prophylactic acyclovir 400 mg twice a day was commenced but 6 months later the patient developed a geographic corneal ulcer involving the graft-host interface (Fig. 2) with keratic precipitates and corneal oedema (central corneal thickness 710 µm). The patient was treated with acyclovir 400 mg and topical aciclovir both five times a day for 2 weeks with resolution of the ulcer and residual scarring. Although the patient had HSV IgG serum antibodies, evidence of HSV-1 DNA was not detected in the first donor




Fig. 1 Dendritic-geographic epithelial ulcer on the donor tissue

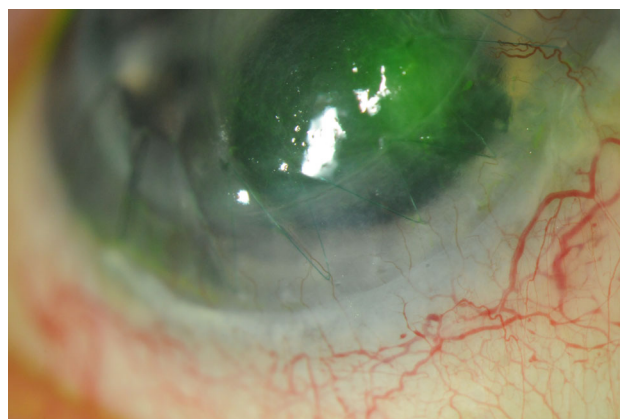

Fig. 2 Geographic corneal ulcer involving the graft-host interface

cornea or following sampling of the corneal ulcer via PCR and culture methods.

Discussion

The potential transmission of HSV-1 from donor to host has been recognized by clinical and laboratory studies [12–14]. Viral particles have been found in keratocytes and endothelial cells [15] of corneal grafts with postoperative keratitis. HSV-1 is known to induce endothelial cell necrosis during organ culture, consistent with reports of postoperative keratitis [5, 16]. A rate of 1.2 per 1000 person-years has been reported for newly acquired herpetic keratitis in the early postoperative period [12]. Borderie et al. reported that HSV-1 was responsible for 3 out of 4 primary graft failures among 586 consecutive grafts performed [17]. Evidence of HSV-1 has been found in 10% of patients with diseased corneas with no history of HSK undergoing corneal transplantation [16] and also in cell pellets obtained from donor cornea culture medium in (%) (3 out of 80) donor corneas [18, 19]. Currently, however, screening assays are not undertaken by eye banks to identify HSV-1 in the donor cornea or medium during storage.

We describe a case of clinically suspected HSK in the donor cornea and subsequently in the recipient. Biswas et al. [20] described the development of primary graft failure and ulcerative keratitis in two patients, respectively [20]. Similar to our patient, they suggested transmission of HSV-1 through organ-cultured corneal graft in two patients in spite of negative results of PCR performed on both recipient corneas, based on the presence of endothelial cell necrosis in the fellow donor cornea in one of the cases. In the presented case HSV-1 originating from the host cannot be ruled out as the source of the described viral keratitis, but is deemed highly unlikely given the absence of previous herpetic disease. Although we were not able to isolate HSV-1 either from the donor or host, the clinical appearances were typical in both the donor and host. Intraoperative and perioperative antiviral treatment may have prevented potential intraocular spread to the posterior segment as described by Atherton and Streilein [10, 11] following anterior chamber inoculation and subsequent disease of the central nervous system in a similar mechanism to oronasal and vomeronasal spread [21–23]. This case highlights the issue of being able to adequately examine the donor corneoscleral disc prior to use. Adequate biomicroscopic visualization of the donor cornea is not possible in the storage transport containers currently used for organ cultured corneas. This problem could be addressed by redesigning the transport chamber used for organ cultured corneas, or the use of hypothermic transport containers, which allow assessment of donor tissue by slit lamp biomicroscopy or the operating microscope before use [24].

Open access funding provided by University of Southampton.

Compliance with ethical guidelines

Conflict of interest R. Kaye, B. Steger, J.Y. Chen, and V. Romano declare that they have no competing interests.

Ethical standards Informed consent was obtained from the patient.

Open Access This article is distributed under the terms of the Creative Commons Attribution 4.0 International License (<http://creativecommons.org/licenses/by/4.0/>), which permits unrestricted use, distribution, and reproduction in any medium, provided you give appropriate credit to the original author(s) and the source, provide a link to the Creative Commons license, and indicate if changes were made.

References

1. Kaye S, Choudhary A. Herpes simplex keratitis. *Prog Retin Eye Res.* 2006;25:355–80.
2. Kaye SB, Baker K, Bonshek R, et al. Human herpesviruses in the cornea. *Br J Ophthalmol.* 2000;84:563–71.
3. Xu F, Schillinger JA, Sternberg MR, et al. Seroprevalence and coinfection with herpes simplex virus type 1 and type 2 in the United States, 1988–1994. *J Infect Dis.* 2002;185:1019–24.
4. Cockerham GC, Krafft AE, McLean IW. Herpes simplex virus in primary graft failure. *Arch Ophthalmol.* 1997;115:586–9.
5. Cleator GM, Klapper PE, Dennett C, et al. Corneal donor infection by herpes simplex virus: herpes simplex virus DNA in donor corneas. *Cornea.* 1994;13:294–304.
6. Neufeld MV, Steinemann TL, Merin LM, et al. Identification of a herpes simplex virus-induced dendrite in an eye-bank donor cornea. *Cornea.* 1999;18:489–92.
7. Mannis MJ, Plotnik RD, Schwab IR, et al. Herpes simplex dendritic keratitis after keratoplasty. *Am J Ophthalmol.* 1991;111:480–4.
8. Salisbury JD, Berkowitz RA, Gebhardt BM, et al. Herpesvirus infection of cornea allografts. *Ophthalmic Surg.* 1984;15:406–8.
9. Zheng X, Marquart ME, Loustch JM, et al. HSV-1 migration in latently infected and naive rabbits after penetrating keratoplasty. *Invest Ophthalmol Vis Sci.* 1999;40:2490–7.
10. Atherton SS, Streilein JW. Two waves of virus following anterior chamber inoculation of HSV-1. *Invest Ophthalmol Vis Sci.* 1987;28:571–9.
11. Atherton SS, Streilein JW. Two waves of virus following anterior chamber inoculation of HSV-1. *Ocul Immunol Inflamm.* 1987;2007(15):195–204.
12. Remeijer L, Doornenbal P, Geerards AJ, et al. Newly acquired herpes simplex virus keratitis after penetrating keratoplasty. *Ophthalmology.* 1997;104:648–52.
13. Laycock KA, Lee SF, Stulting RD, et al. Herpes simplex virus type 1 transcription is not detectable in quiescent human stromal keratitis by in situ hybridization. *Invest Ophthalmol Vis Sci.* 1993;34:285–92.
14. Cantin EM, Chen J, McNeill J, et al. Detection of herpes simplex virus DNA sequences in corneal transplant recipients by polymerase chain reaction assays. *Curr Eye Res.* 1991;10(Suppl):15–21.
15. Holbach LM, Asano N, Naumann GO. Infection of the corneal endothelium in herpes simplex keratitis. *Am J Ophthalmol.* 1998;126:592–4.
16. Tullo AB, Marcyniuk B, Bonshek R, et al. Herpes virus in a corneal donor. *Eye (Lond).* 1990;4(Pt 5):766–7.

17. Borderie VM, Meritet JF, Chaumeil C, et al. Culture-proven herpetic keratitis after penetrating keratoplasty in patients with no previous history of herpes disease. *Cornea*. 2004;23:118–24.
18. Kaye SB, Lynas C, Patterson A, et al. Evidence for herpes simplex viral latency in the human cornea. *Br J Ophthalmol*. 1991;75:195–200.
19. Morris DJ, Cleator GM, Klapper PE, et al. Detection of herpes simplex virus DNA in donor cornea culture medium by polymerase chain reaction. *Br J Ophthalmol*. 1996;80:654–7.
20. Biswas S, Suresh P, Bonshek RE, et al. Graft failure in human donor corneas due to transmission of herpes simplex virus. *Br J Ophthalmol*. 2000;84:701–5.
21. Kennedy PG, Chaudhuri A. Herpes simplex encephalitis. *J Neurol Neurosurg Psychiatr*. 2002;73:237–8.
22. Gaber TA, Eshiett M. Resolution of psychiatric symptoms secondary to herpes simplex encephalitis. *J Neurol Neurosurg Psychiatr*. 2003;74:1164, author reply 1164.
23. Mori I, Goshima F, Ito H, et al. The vomeronasal chemosensory system as a route of neuroinvasion by herpes simplex virus. *Virology*. 2005;334:51–8.
24. Merin LM, Brown ME, Howdeshell LL. Darkfield biomicrography of eye bank donor corneas. *Cornea*. 2001;20:210–3.