

A Case Report of a Patient with Spontaneously Resolving Unruptured Uterine Artery Pseudoaneurysm after Surgery for Miscarriage during the Early Stages of Pregnancy Using Manual Vacuum Aspiration

Toshiyuki Kakinuma^{1,2*}, Kaoru Kakinuma^{1,2}, Yoshimasa Kawarai¹, Tomoyuki Ohta³, Michitaka Ohwada², Hirokazu Tanaka², Kaoru Yanagida¹

Departments of ¹Obstetrics and Gynecology and ³Radiology, International University of Health and Welfare Hospital, ²Center for Human Reproduction, International University of Health and Welfare Hospital, Nasushiobara, Tochigi, Japan

Abstract

Uterine artery pseudoaneurysms are caused by damage to blood vessel walls from iatrogenic changes including cesarean section or cervical dilatation and uterine curettage. Manual vacuum aspiration (MVA) is becoming increasingly popular from the perspective of reducing the risk of endometrial injury. This is a case report of a 33-year-old primigravida female patient diagnosed with an unruptured uterine artery pseudoaneurysm that spontaneously resolved after surgery for miscarriage using MVA. The patient experienced a miscarriage at 10 weeks and 0 days of gestation and underwent surgery using MVA. Fourteen days after surgery, the patient was diagnosed with a uterine artery pseudoaneurysm by transvaginal ultrasound tomography and contrast computed tomography of the pelvic region. The patient received elective follow-up and was found to be completely thrombosed 2 months after surgery. MVA for miscarriage may cause uterine artery pseudoaneurysms. Elective therapy may be an option for unruptured uterine artery pseudoaneurysms.

Keywords: Abortion, abortion techniques, first trimester, manual vacuum aspiration, pseudoaneurysm

INTRODUCTION

Uterine artery pseudoaneurysms are complications arising from intrauterine arterial wall rupture, resulting in organized wall formation around an extravascular hematoma, which can be fatal if hemorrhage occurs after rupturing. This condition often occurs postpartum or after uterine surgery.^[1] Recently, the number of reports on uterine artery pseudoaneurysm has increased.

The World Health Organization recommends vacuum aspiration for miscarriages in the early stages of pregnancy and abortion surgery, especially to prevent endometrial injury risks.^[2] This is a case report of a patient diagnosed

with an unruptured pseudoaneurysm that spontaneously resolved after surgery for miscarriage using manual vacuum aspiration (MVA).

CASE REPORT

Herein, the patient was a 33-year-old female experiencing her first pregnancy with no prior deliveries and no significant medical or family history. The pregnancy was established through freeze-thaw embryo transfer in the hormone

Address for correspondence: Prof. Toshiyuki Kakinuma, Department of Obstetrics and Gynecology, International University of Health and Welfare Hospital, Kakinuma 537-3, Iguchi, Nasushiobara, Tochigi 329-2763, Japan.
E-mail: tokakinuma@gmail.com

Article History:

Submitted: 18-Mar-2020

Revised: 02-Feb-2021

Accepted: 25-Mar-2021

Published: 14-Feb-2022

Access this article online

Quick Response Code:



Website:
www.e-gmit.com

DOI:
10.4103/GMIT.GMIT_33_20

This is an open access journal, and articles are distributed under the terms of the Creative Commons Attribution-NonCommercial-ShareAlike 4.0 License, which allows others to remix, tweak, and build upon the work non-commercially, as long as appropriate credit is given and the new creations are licensed under the identical terms.

For reprints contact: WKHLRPMedknow_reprints@wolterskluwer.com

How to cite this article: Kakinuma T, Kakinuma K, Kawarai Y, Ohta T, Ohwada M, Tanaka H, *et al.* A Case Report of a Patient with Spontaneously Resolving Unruptured Uterine Artery Pseudoaneurysm after Surgery for Miscarriage during the Early Stages of Pregnancy Using Manual Vacuum Aspiration. *Gynecol Minim Invasive Ther* 2022;11:54-6.

replenishment cycle for primary infertility. The patient was admitted to our institution at 9 weeks and 6 days of gestation with missed abortion. At 10 weeks and 0 days of gestation, cervical dilatation and uterine curettage was performed using MVA (Women's Health Japan K.K., Tokyo) with a paracervical block. The postoperative course was uneventful, and the patient was discharged on the same day. Fourteen days after surgery, transvaginal ultrasound tomography revealed a 30-mm hypointense area in the right uterine horn and color Doppler imaging revealed blood flow [Figure 1]. Pelvic computed tomography (CT) showed a 30-mm contrast-enhanced mass in the right uterine horn [Figure 2a], and CT angiography revealed a pseudoaneurysm receiving blood from the right uterine artery [Figure 2b]. No notable symptoms such as genital bleeding or abdominal pain were observed. After receiving an explanation about the risks associated with ruptured uterine pseudoaneurysms, the patient opted to undergo elective therapy and was scheduled for outpatient follow-up. Two months after the surgery, a decreasing trend in the pseudoaneurysm size and complete thrombosis were observed, and blood flow to the uterine artery pseudoaneurysm stopped. Menstruation resumed promptly thereafter, and infertility treatments are ongoing. No recurrences of uterine artery pseudoaneurysm have been observed. This patient gave written informed consent for the procedure and for study participation after proper explanation of the risks and benefits of the procedure. This study was approved by the Ethics Committee of International University of Health and Welfare Hospital (13-B-323, November 22, 2018).

DISCUSSION

MVA began with Harvey Karman's development of a small, flexible cannula for use with a syringe in 1961 followed by Ipas's development of MVA in 1973. MVA can be performed without the need for curettes during surgery, and it can prevent Asherman syndrome caused by endometrial injury

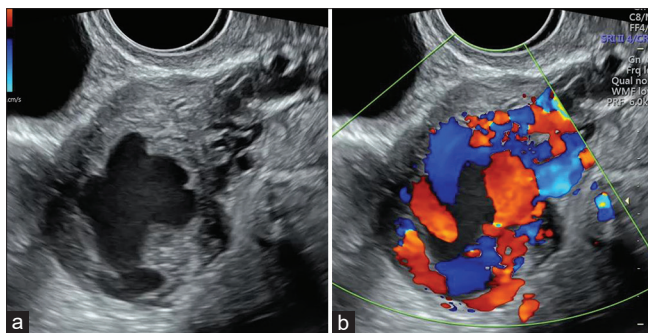


Figure 1: Transvaginal ultrasound (a: B-mode image, b: color Doppler image, 14 days after the surgery). (a) A 30-mm pulsatile mass was found in the right uterine horn. (b) A mosaic-like blood flow signal was observed in the mass

and endometrial thinning.^[3] In Japan, an MVA kit (Women's MVA system MVA kit, Women's Health Japan) was approved in October 2015 and its use is becoming more widespread; the efficacy and safety of this MVA kit for miscarriages in the early stages of pregnancy have been reported previously.^[4]

Uterine artery pseudoaneurysms are often caused by vascular injury associated with postpartum and surgery in the uterus and are believed to be primarily iatrogenic. However, there are no reports on uterine artery pseudoaneurysm in surgeries for miscarriage in the early stages of pregnancy using MVA; thus, postoperative follow-up for this complication is necessary for the future because MVA use for miscarriage is expected to increase owing to its potential for reducing endometrial injury.

Uterine artery pseudoaneurysm diagnosis should be made while patients are asymptomatic as ruptures can lead to fatal hemorrhage. Ultrasound and color Doppler imaging are useful for uterine artery pseudoaneurysms diagnosis as pulsatile blood flow moving in a spiral toward the hypoechoic image of the hematoma is observed in the uterus. If there is a possibility of this complication, it is important to perform a confirmation using color Doppler imaging.^[5] Contrast-enhanced CT is helpful in diagnosing uterine artery pseudoaneurysms as contrast media accumulates in the region of the uterine artery, and if the aneurysm has already ruptured, leakage of contrast medium into the surrounding area would be observed.^[6]

Uterine artery embolization (UAE) is used to treat this complication in most patients if genital hemorrhage is observed, and the efficacy of this treatment strategy has been reported.^[1,7,8] Postoperative fever is the most common complication associated with UAE, pain, endometritis, intrauterine adhesion,

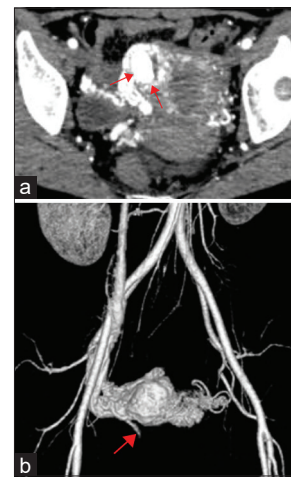


Figure 2: Pelvic contrast computed tomography. (a) A 30-mm contrast-enhanced mass was found in the right uterine horn. (b) A uterine pseudoaneurysm was found to be present in the main draining artery of the right uterine artery. Donation of blood from the right ovarian artery and the left uterine artery was also suspected

uterine necrosis, and ovarian hypofunction. The incidence of complications associated with this treatment is 6%–9%, including complications associated with angiographic procedures.^[9] Although postoperative fertility is relatively good, there are significantly higher rates of miscarriage, postpartum hemorrhage, preterm birth, and abnormal presentation, and intrauterine growth retardation in patients who become pregnant after UAE. Therefore, perinatal care is necessary in cases wherein pregnancy occurs after UAE.^[10]

There are two contrasting opinions if the patient is asymptomatic: UAE should be performed prophylactically or a watch-and-wait approach. Asymptomatic uterine artery pseudoaneurysms may spontaneously resolve, whereas the rupture of uterine artery pseudoaneurysms leads to major bleeding. At present, there is no method to discriminate between whether uterine pseudoaneurysms will rupture; treatment strategy for unruptured uterine artery pseudoaneurysms is an issue that needs to be examined in the future. There is a need to assess the treatment strategy for each patient using the medical resources at each site, including data on the trends in changes in size of the uterine artery pseudoaneurysm, and feasibility of emergency UAE during bleeding.

Thus, when utilizing MVA for miscarriage during the early stages of pregnancy, which is becoming increasingly prevalent owing to its potential for reducing endometrial injury, treatment strategies should consider the occurrence of uterine artery pseudoaneurysms. In patients diagnosed with unruptured uterine artery pseudoaneurysms, a strategy of watchful waiting for spontaneous resolution under strict follow-up can be a treatment option.

Ethical approval

This study was approved by IRB in The Ethics Committee of International University of Health and Welfare Hospital (approved number: 13-B-323).

Declaration of patient consent

The authors certify that they have obtained all appropriate patient consent forms. In the form, the patient has given her

consent for her images and other clinical information to be reported in the journal. The patient understands that name and initials will not be published and due efforts will be made to conceal identity, but anonymity cannot be guaranteed.

Financial support and sponsorship

Nil.

Conflicts of interest

There are no conflicts of interest.

REFERENCES

1. Wan AY, Shin JH, Yoon HK, Ko GY, Park S, Seong NJ, *et al.* Post-operative hemorrhage after myomectomy: Safety and efficacy of transcatheter uterine artery embolization. *Korean J Radiol* 2014;15:356-63.
2. World Health Organization, Department of Reproductive Health and Research. Safe abortion: Technical and Policy Guidance for Health Systems, Second edition; 2012. Available from: http://www.who.int/reproductivehealth/publications/unsafe_abortion/9789241548434/en/. [Last accessed on 2019 Oct 09].
3. Westendorp IC, Ankum WM, Mol BW, Vonk J. Prevalence of Asherman's syndrome after secondary removal of placental remnants or a repeat curettage for incomplete abortion. *Hum Reprod* 1998;13:3347-50.
4. Kakinuma T, Kakinuma K, Sakamoto Y, Kawarai Y, Saito K, Ihara M, *et al.* Safety and efficacy of manual vacuum suction compared with conventional dilatation and sharp curettage and electric vacuum aspiration in surgical treatment of miscarriage: A randomized controlled trial. *BMC Pregnancy Childbirth* 2020;20:695.
5. Diwan RV, Brennan JN, Selim MA, McGrew TL, Rashad FA, Rustia MU, *et al.* Sonographic diagnosis of arteriovenous malformation of the uterus and pelvis. *J Clin Ultrasound* 1983;11:295-8.
6. Isono W, Tsutsumi R, Wada-Hiraike O, Fujimoto A, Osuga Y, Yano T, *et al.* Uterine artery pseudoaneurysm after cesarean section: Case report and literature review. *J Minim Invasive Gynecol* 2010;17:687-91.
7. Takeda A, Koike W, Imoto S, Nakamura H. Conservative management of uterine artery pseudoaneurysm after laparoscopic-assisted myomectomy and subsequent pregnancy outcome: Case series and review of the literature. *Eur J Obstet Gynecol Reprod Biol* 2014;182:146-53.
8. Ito N, Natimatsu Y, Tsukada J, Sato A, Hasegawa I, Lin BL. Two cases of postmyomectomy pseudoaneurysm treated by transarterial embolization. *Cardiovasc Intervent Radiol* 2013;36:1681-5.
9. Vegas G, Illescas T, Muñoz M, Pérez-Piñar A. Selective pelvic arterial embolization in the management of obstetric hemorrhage. *Eur J Obstet Gynecol Reprod Biol* 2006;127:68-72.
10. Goldberg J, Pereira L, Berghella V. Pregnancy after uterine artery embolization. *Obstet Gynecol* 2002;100:869-72.