



Minimally Invasive Radiologic Uretero-calycostomy; a salvage procedure for late transplant rejection ureter necrosis

Erich K. Lang¹

¹ Department of Radiology, Tulane School Medicine, New Orleans, LA, USA

Uretero-calycostomy is a time-honored procedure that has primarily been advocated for the management of failed pyeloplasties associated with long segment upper ureter strictures (1-3). We have expanded this concept to serve as salvage procedure in patients with necrosis of the transplant ureter as consequence of late rejection.

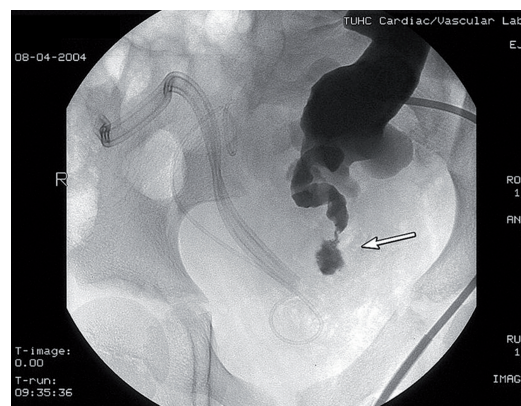
After satisfactory function of a cadaver transplant kidney for 4 years, this 36-year old female presented in the emergency room with evidence of rapidly progressing renal failure. Examination revealed 3+ edema of lower extremities, orthopnea, chest X ray bilateral pleural effusions, and laboratory findings: creatinine 14, BUN 52, K 4.8, urine output 240mL/qd, ultrasonogram showing hydronephrosis of the right transplant kidney.

A percutaneous antegrade nephro-ureterogram demonstrated hydronephrosis of the right transplant kidney and strictures as well as ulcerated segments of the right transplant ureter (Figure-1). Necrosis of the transplant ureter as sequel of late rejection was suggested.

Conservative management by percutaneous antegrade stent placement, anti-microbial therapy and corticosteroids failed to improve condition of the ureter (Figure-2). The uretero-neocystostomy dehiscid and a urinoma formed at the uretero-neocystostomy site.

Small bowel interposition to re-establish drainage or replacement of the transplant kidney by a new transplant were considered as remedial actions (4-6).

Figure 1- PA view: A percutaneous antegrade nephro-ureterogram demonstrates stenosis and ulcerations (arrow) in the dilated segment of the right transplant ureter. A double "J" stent is seen in the left transplant ureter, likewise an attempt to foster healing of this ulcerated ureter.

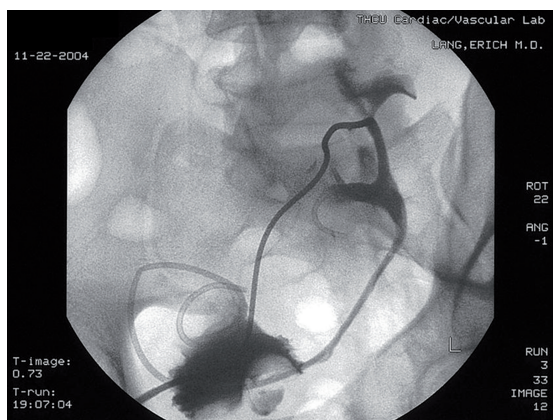


Avascular necrosis of ureter

Considering the dismal condition of the transplant ureter, we decided to modify the uretero-calycostomy procedure, by creating a fistula to the native right ureter, which was available since the native right kidney had been retained for erythropoietin production. Most importantly, the native ureter was not at risk of rejection.

A rigid ureteroscope was advanced under fluoroscopic guidance into the right native ureter, displacing the same toward the dilated superior hydrocalyx, which was then accessed by an 18 gauge needle advanced via the ureteroscope

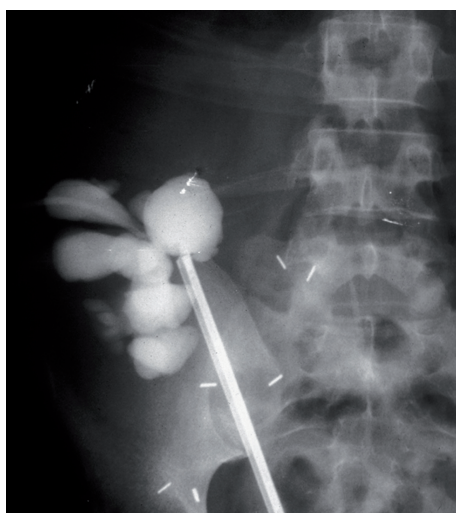
Figure 2 - PA view: A stent has been seated via antegrade percutaneous approach from the transplant kidney pelvis into the bladder. The nephrostomy (arrow) is maintained to ensure ready access.



Double J stent seated and percutaneous nephrostomy seated

(Figure-3). A stiff Amplatz guide wire was then introduced into the kidney pelvis, over which a double “J” stent was placed, maintaining drainage from the kidney into the bladder (7) (Figure-4). The stent was maintained in position for 12 weeks. A solid fistula (uretero-calycostomy fistula) between calyx and native ureter resulted. Urine

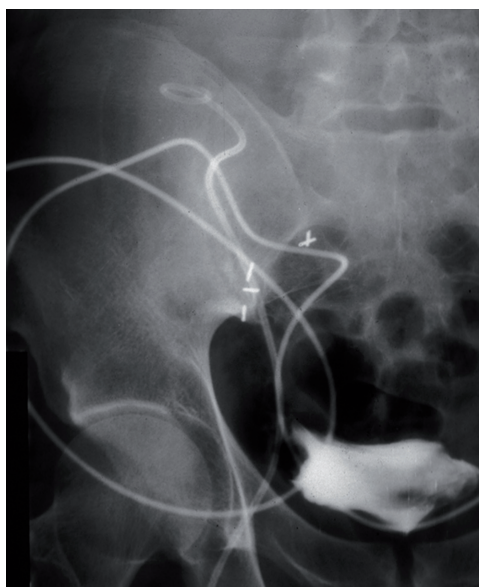
Figure 3 - AP view: A rigid ureteroscope has been advanced in the native ureter under fluoroscopic guidance close to the dilated hydrocalyx of the right transplant kidney. The pelvis is accessed by needle-puncture through the ureteroscope and a guide wire introduced.



output of the transplant kidney stabilized; creatinine dropped to 2.6 in 4 weeks and remained stable at a level of 1.4 – 1.8 over the next 7 year follow-up, as did BUN at levels of 18 - 24.

Percutaneous radiologic antegrade uretero-neocalycostomy is recommended as a minimally invasive intervention that can manage the complex problem of ureter necrosis in otherwise well -functioning transplant kidneys.

Figure 4 - AP view: A double “J” stent from transplant kidney pelvis to bladder has been seated over the guide wire in the native ureter. The nephrostomy has been maintained as safety measure to ensure ready access.



REFERENCES

1. Neuwirt K, Implantation of the ureter into lower calyx of renal pelvis. VII congeries de la societe international d’Urologie 1947;2:253-55.
2. Matlaga BR, Shah OD, Singh D, Strem SB, Assimos DG. Ureterocalycostomy: a contemporary experience. Urology. 2005;65:42-4.
3. Gite VA, Siddiqui AK, Bote SM, Patil SR, Kandi AJ, Nikose JV. Ureterocalycostomy - final resort in the management of secondary pelvi-ureteric junction obstruction: our experience. Int Braz J Urol. 2016;42:501-6.
4. Gomez-Gomez E, Malde S, Spilotros M, Shah PJ, J Greenwell T, Ockrim JL. A tertiary ex-perience of ileal-ureter substitution: Contemporary indications and outcomes. Scand J Urol. 2016;50:192-9.

5. Wolters HH, Palmes D, Krieglstein CF, Suwelack B, Hertle L, Senninger N, et al. Recons-truction of ureteral necrosis in kidney transplantation using an ileum interposition. *Transplant Proc.* 2006;38:691-2.
6. Furtwängler A, el Saman A, Pisarski P, Frankenschmidt A, Kirste G, Hopt UT. Temporary small bowel interposition for urinary drainage after partial necrosis of the renal graft pelvis following living related renal donation. *Transplant Proc.* 2003;35:944-5.
7. Lang EK. Percutaneous ureterocystostomy and ureteroneocystostomy. *AJR Am J Roentge-nol.* 1988;150:1065-8.

Correspondence address:

Erich K. Lang, MD,
Department Radiology
SUNY Downstate Medical School
450 Clarkson Av., Brooklyn
New York 11203, USA
E-mail: eklang@bellsouth.net

ARTICLE INFO

Int Braz J Urol. 2017; 43: 776-8

Submitted for publication:
July 01, 2016

Accepted after revision:
December 11, 2016

Published as Ahead of Print:
February 22, 2017