

Available online at [www.sciencedirect.com](http://www.sciencedirect.com)

ScienceDirect

journal homepage: [www.elsevier.com/locate/radcr](http://www.elsevier.com/locate/radcr)

## Case Report

# Multiple renal capillary hemangiomas in a patient with end-stage renal disease

Thanh-Lan Bui, MA<sup>a</sup>, Justin Glavis-Bloom, MD<sup>a</sup>, Hanna K. Liu, MD<sup>a</sup>, Alexander Ushinsky, MD<sup>a</sup>, Sami Souccar, MD<sup>b</sup>, Ifegwu O. Ibe, MD<sup>b</sup>, Ali Sasani, BS<sup>a</sup>, Roozbeh Houshyar, MD<sup>a,\*</sup>

<sup>a</sup> Department of Radiological Sciences, University of California Irvine, Orange, CA, USA

<sup>b</sup> Department of Pathology, University of California Irvine, Orange, CA, USA

## ARTICLE INFO

## Article history:

Received 19 February 2019

Accepted 25 March 2019

Available online 3 April 2019

## Keywords:

Renal capillary hemangioma

End-stage renal disease

## ABSTRACT

Renal capillary hemangiomas are rare and benign vascular tumors which are typically incidentally discovered on imaging. Surgical excision is often performed, as imaging appearance is similar to malignant lesions. Renal hemangiomas are typically solitary and unilateral. We present a rare case of multiple renal capillary hemangiomas in a patient with end-stage renal disease. Two hemangiomas were detected on imaging and 2 smaller hemangiomas were detected upon pathological evaluation, suggesting there may be a wider prevalence of smaller, radiographically-occult renal hemangiomas.

© 2019 The Authors. Published by Elsevier Inc. on behalf of University of Washington.

This is an open access article under the CC BY-NC-ND license.

(<http://creativecommons.org/licenses/by-nc-nd/4.0/>)

## Introduction

Renal capillary hemangiomas are rare, often underrecognized, benign vascular tumors [1]. In small case series, these lesions have been associated with other diseases including end-stage renal disease, acquired cystic kidney disease, polycythemia, and renal cell carcinoma [2–6]. Patients may present with abdominal pain and hematuria, but are more commonly asymptomatic. Therefore, these tumors are often initially discovered incidentally on imaging. Renal hemangiomas pose diagnostic and clinical dilemmas because of similar radiologic characteristics to other lesions including renal cell carcinoma and angiosarcoma. Surgical excision is often indicated due to the

similar appearance to malignant lesions or in cases of significant symptoms such as hemorrhage [7–9]. Definitive diagnosis is based on pathology demonstrating aggregates of capillary-sized vascular channels with CD31+ endothelial cells [1,6]. We present a rare case of multiple renal capillary hemangiomas in a patient with end-stage renal disease.

## Case presentation

A 23-year-old male with end-stage renal disease secondary to C1q-positive focal segmental glomerulosclerosis on hemodialysis was referred for complete abdominal

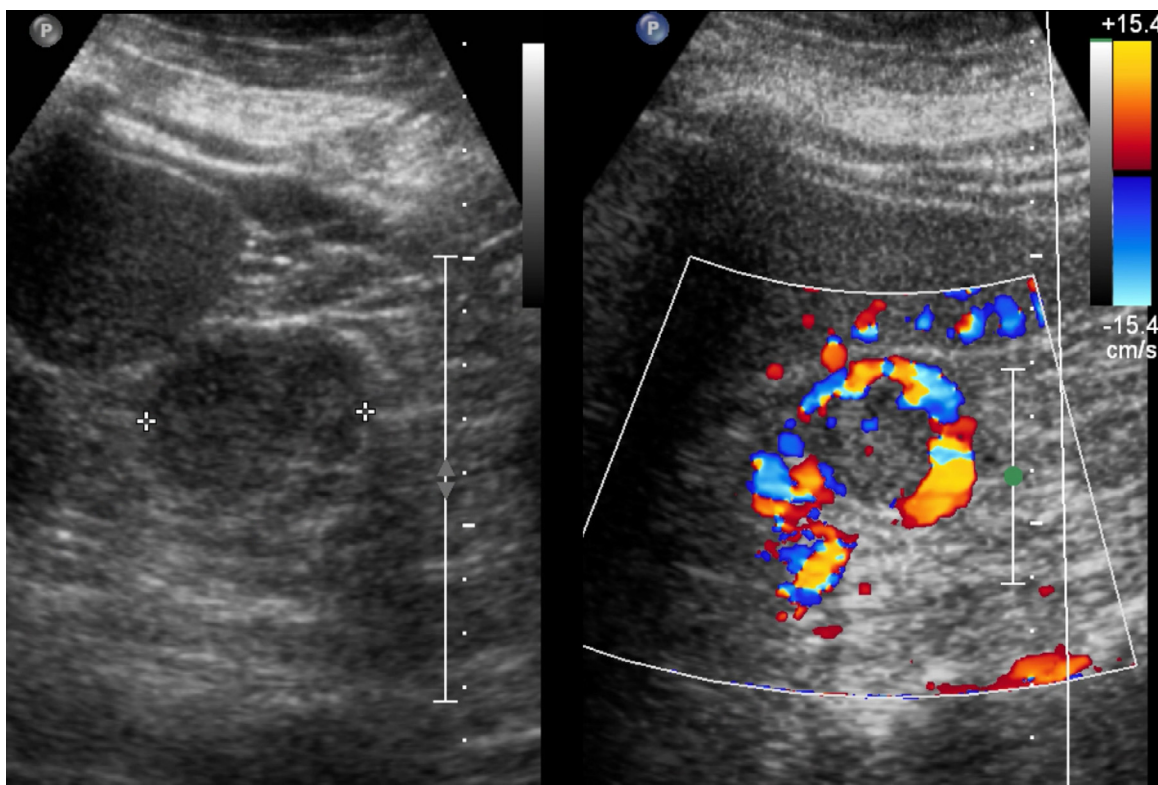
Declarations of interest: None.

\* Corresponding author.

E-mail address: [rhoushya@uci.edu](mailto:rhoushya@uci.edu) (R. Houshyar).

<https://doi.org/10.1016/j.radcr.2019.03.027>

1930-0433/© 2019 The Authors. Published by Elsevier Inc. on behalf of University of Washington. This is an open access article under the CC BY-NC-ND license. (<http://creativecommons.org/licenses/by-nc-nd/4.0/>)



**Fig. 1 – Ultrasound images of the left kidney without and with Doppler demonstrate a 4.0 cm isoechoic mass at the left mid-lower pole with peripheral Doppler flow.**

ultrasound for renal pretransplant evaluation. He reported no abdominal pain or hematuria at prior clinical visits. His laboratory studies were only remarkable for longstanding anemia (Hgb 11.5 g/dL) and thrombocytopenia ( $111 \times 10^3$  per  $\mu\text{L}$ ), with no red blood cells on urinalysis. Ultrasound demonstrated a  $3.3 \times 2.9 \times 4.0$  cm isoechoic mass with prominent peripheral flow in the mid-lower zone of the left kidney (Fig. 1).

A subsequent computed tomography examination with and without intravenous contrast demonstrated bilateral atrophic kidneys with 2 cortical-based lesions within the left kidney measuring up to 2.1 cm at the upper pole and 3.0 cm at the midzone. These lesions demonstrated noncontrast hypoattenuation (Fig. 2), arterial enhancement (Fig. 3), and central hypoattenuating areas that persisted on portal venous phase (Fig. 4), which raised concern for malignancy. After extensive discussion, the patient wished to defer biopsy and proceed with radical nephrectomy. The patient underwent an uncomplicated laparoscopic left radical nephrectomy and adjacent lymphadenectomy.

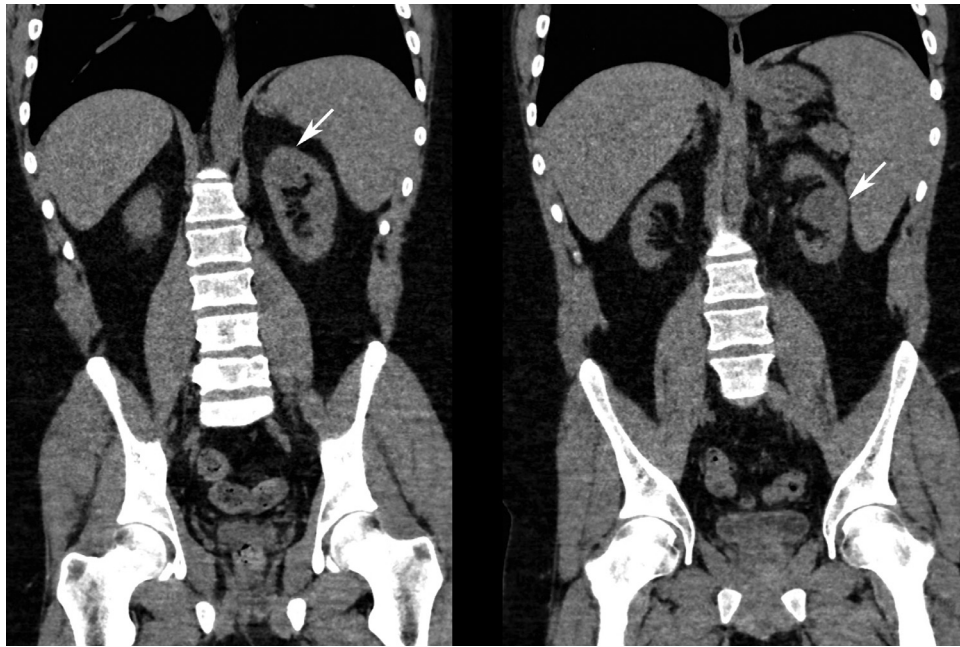Surgical pathology demonstrated findings consistent with end-stage renal disease and 4 masses: in the mid-pole measuring up to 2.3 cm and located 3.2 cm from the renal vein, 4.2 cm from the urethral margin, and 0.4 cm from the cortex margin; at the lower pole measuring up to 1.1 cm and located 4.4 cm from the renal vein margin, 6.4 cm from the urethral margin, and 0.8 cm from the cortex margin; and 2 masses in

the upper pole measuring up to 1.9 cm and 0.6 cm. The masses demonstrated characteristic histopathological features of benign capillary hemangioma (Fig. 5). There was no evidence of malignancy. At 3 month follow-up, the patient is doing well.

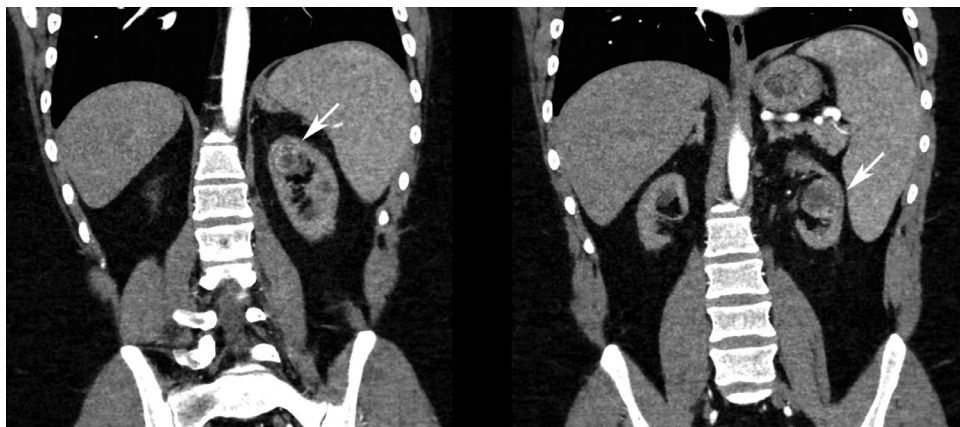## Discussion

Renal hemangiomas are exceptionally rare, with approximately 200 previously reported cases [1]. Renal hemangiomas are typically solitary and unilateral [6,8]. However, in our case, 2 hemangiomas were detected on imaging, and 2 additional smaller peri-centimeter and sub-centimeter hemangiomas were detected only on pathological evaluation. These findings suggest there may be a wider prevalence of smaller, radiographically-occult renal hemangiomas. Previous studies have reported similarly radiographically occult hemangiomas in patients with ESRDs [1,6]. This may suggest that the tumor may be more common than previously considered. Further research is needed to characterize the relationship between capillary hemangiomas and ESRD.

Renal hemangiomas present a clinical challenge, as differentiating them from malignant lesions is nearly impossible clinically and radiographically. It is especially challenging in ESRD patients because kidneys with chronic damage have



**Fig. 2 – Noncontrast coronal CT images demonstrate hypoattenuating lesions in the left kidney upper pole and midzone.**



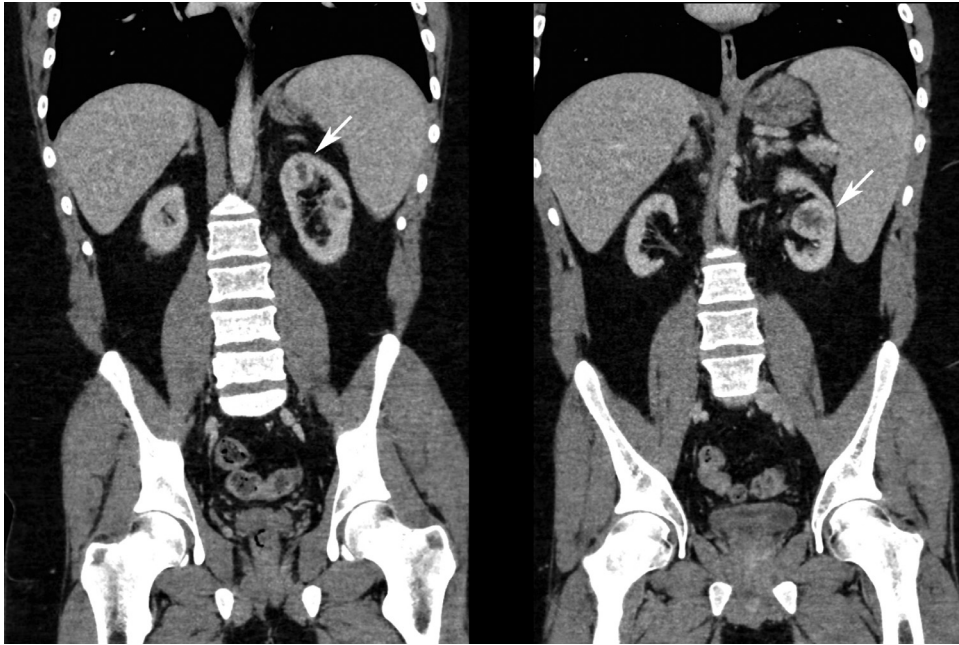**Fig. 3 – Arterial phase contrast-enhanced coronal CT images demonstrate enhancing lesions in the left kidney upper pole and midzone with central hypoattenuating areas.**

a propensity to develop both benign vascular tumors and epithelial neoplasms [1]. Currently, imaging does little to alleviate the challenge. Ultrasound findings are nonspecific and do not aid in distinguishing renal hemangiomas from other tumors. It has been suggested that central hypoattenuation on computed tomography, which was present in our case, may indicate hemangioma as a differential consideration [5]. Given the lack of definitive imaging characteristics, biopsy or excision is necessary for final diagnosis. Our patient

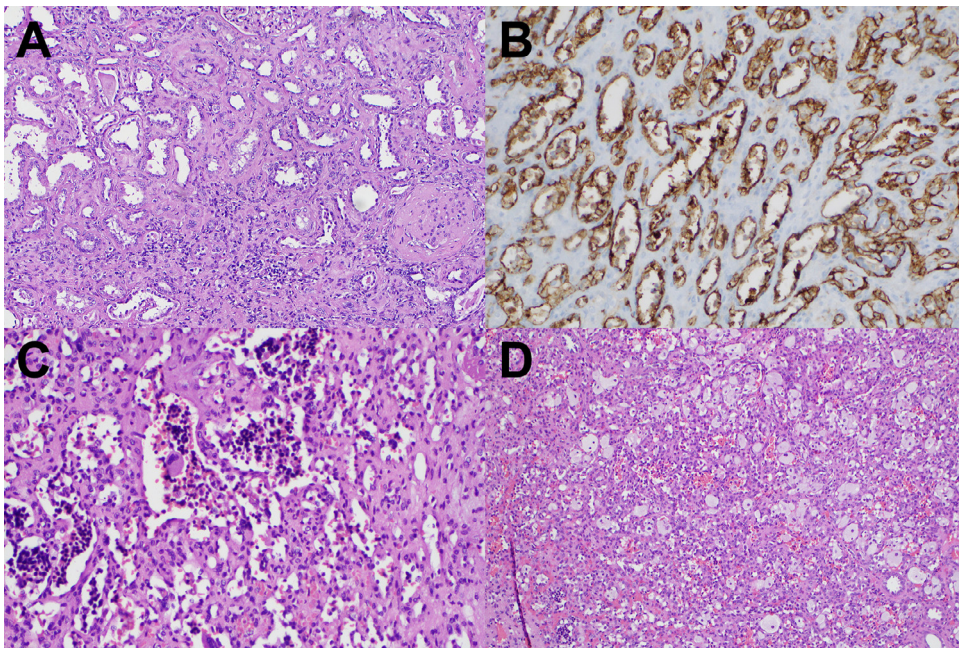
opted for radical nephrectomy given the presence of ESRD, planned renal transplant, and desire for definitive treatment of possible malignancy,

Further research is needed to explore the prevalence, associations, and radiographic characteristics of renal hemangiomas. In the interim, the possibility of a benign renal hemangioma should be considered in patients with vascular renal lesions, and counseling and treatment decisions made accordingly.





**Fig. 4** – Portal venous phase contrast-enhanced coronal CT images demonstrate enhancing lesions in the left kidney upper pole and midzone with central hypoattenuating areas.



**Fig. 5** – Histopathology demonstrates findings of end-stage renal disease including tubular thyroidization on hematoxylin and eosin staining (A), vascular prominence with CD31-positivity on immunohistochemical staining (B), characteristic appearance of hemangioma with associated foamy histiocytes on hematoxylin and eosin staining on high power (C), and low power magnification (D).

---

## Supplementary materials

Supplementary material associated with this article can be found, in the online version, at doi:[10.1016/j.radcr.2019.03.027](https://doi.org/10.1016/j.radcr.2019.03.027).

---

## REFERENCES

- [1] Büttner M, Kufer V, Brunner K, Hartmann A, Amann K, Agaimy A. Benign mesenchymal tumours and tumour-like lesions in end-stage renal disease. *Histopathology* 2013;62:229–36.
- [2] Lee HS, Koh BH, Kim JW, et al. Radiologic findings of renal hemangioma: report of three cases. *Korean J. Radiol* 2000;1:60–3.
- [3] Brown JG, Folpe AL, Rao P, Lazar AJ, Paner GP, Gupta R, et al. Primary vascular tumors and tumor-like lesions of the kidney: a clinicopathologic analysis of 25 cases. *Am J Surg Pathol* 2010;34:942–9.
- [4] Leak BJ, Javidan J, Dagher R. A rare case of renal hemangioma presenting as polycythemia. *Urology* 2001;57:975.
- [5] Beamer M, Love M, Ghasemian S. Renal capillary haemangioma associated with renal cell carcinoma and polycythaemia in acquired cystic disease. *BMJ Case Rep* 2017;2017:975iv–v. bcr-2017-220936.
- [6] Kryvenko ON, Haley SL, Smith SC, Shen SS, Paluru S, Gupta NS, et al. Haemangiomas in kidneys with end-stage renal disease: a novel clinicopathological association. *Histopathology* 2014;65:309–18.
- [7] Mehta V, Ananthanarayanan V, Antic T, Krausz T, Milner J, Venkataraman G, et al. Primary benign vascular tumors and tumorlike lesions of the kidney: a clinicopathologic analysis of 15 cases. *Virchows Arch* 2012;461:669–76.
- [8] Vasquez E, Aulivola B, Picken M, Milner J. Capillary hemangioma masquerading as a renal artery pseudoaneurysm. *Urology*, 79; 2012. p. 987–9.
- [9] Oikawa M, Hatakeyama S, Hamano I, Tanaka T, Tanaka Y, Narita T, et al. Capillary hemangioma in renal hilum; a case report. *Hinyokika Kiyo* 2014;60:33–7.