

# Glycogenic hepatopathy as an unusual etiology of deranged liver function in a patient with type 1 diabetes

## A case report

David TW Lui, MBBS, Yu-Cho Woo, MBChB, Wing-Sun Chow, MBBS, Chi-Ho Lee, MBBS, Alan CH Lee, MBBS, Eunice KH Leung, MBBS, Kathryn CB Tan, MD, Karen SL Lam, MD, Joanne KY Lam, MBBS\*

### Abstract

**Rationale:** Deranged liver function is a common finding among patients with diabetes mellitus. We report a case of liver biopsy-proven glycogenic hepatopathy (GH) in a patient with long-standing poorly controlled type 1 diabetes (DM1), presented with recurrent transaminitis.

**Patient concerns:** A 28-year-old Chinese woman was noted to have deranged liver function with transaminases elevated to more than 15 times the upper limit of normal.

**Diagnosis:** She had underlying long-standing poorly controlled DM1. Blood tests including hepatitis serology and autoimmune panel were negative. Liver biopsy confirmed the diagnosis of GH, showing an increase in glycogen deposition with intact liver parenchymal architecture, and no inflammation or significant fibrosis.

**Interventions:** Her glycemic control was optimized.

**Outcomes:** Her transaminase levels normalized upon subsequent follow-up with improved glycemic control.

**Lessons:** GH is suspected when transaminase flare occurs in patients with poorly controlled DM1, usually with exaggerated hemoglobin A1c levels, especially after drug-induced, viral, autoimmune and metabolic liver diseases are excluded. The gold standard of diagnosis is liver biopsy. When diagnosis of GH is ascertained, the mainstay of treatment is to optimize glycemic control. Typically, the transaminases may become normal within days to months after improvement of glycemic control. Compared to non-alcoholic fatty liver disease, GH is associated with favorable prognosis and runs a benign course, making this differentiation clinically important.

**Abbreviations:** ALT = alanine aminotransferase, AST = aspartate aminotransferase, DM1 = type 1 diabetes, GH = glycogenic hepatopathy, HbA1c = haemoglobin A1c, NAFLD = non-alcoholic fatty liver disease, NR = normal range, ULN = upper limit of normal.

**Keywords:** diabetes mellitus type 1, glycogenic hepatopathy, liver function tests, non-alcoholic fatty liver disease

## 1. Introduction

Deranged liver function is commonly encountered in patients with diabetes. While non-alcoholic fatty liver disease (NAFLD) is

more common, glycogenic hepatopathy (GH) should be considered as a differential diagnosis, especially in patients with poorly controlled type 1 diabetes (DM1). GH remains under-recognized,<sup>[1-4]</sup> so that only around 50 adult cases of GH have been reported to date,<sup>[1]</sup> and only 1 case reported among Chinese.<sup>[5]</sup> GH is characterized by an asymptomatic elevation in transaminases, typically in the form of transaminase flare, and hepatomegaly,<sup>[2,4,6]</sup> and is mostly found in patients with long-standing poorly controlled DM1.<sup>[1,4]</sup> Accurate diagnosis of GH is crucial as GH is shown to resolve following improvement in glycemic control,<sup>[7]</sup> and diagnosis of which presents an important opportunity for clinicians to motivate these patients to achieve and maintain better glycemic control. Despite attempts of developing non-invasive diagnostic modalities,<sup>[8]</sup> current gold standard of diagnostic modality is still liver biopsy.<sup>[4]</sup> Unlike NAFLD, GH usually does not progress to cirrhosis,<sup>[9]</sup> a distinct difference in prognosis. However, GH has been reported to show varying degree of fibrosis, mostly mild degree,<sup>[3,10-12]</sup> the significance of which remains uncertain. Currently available literature on GH lacks Fibroscan data,<sup>[13]</sup> and focuses more on the short-term correlation between improved glycemic control with improved transaminase levels.<sup>[14]</sup> Therefore, we report a patient with long-standing poorly controlled DM1 presented

Editor: N/A.

Informed written consent was obtained from the patient for publication of this case report and accompanying images.

The authors have no conflicts of interest to disclose.

Department of Medicine, University of Hong Kong, Queen Mary Hospital, Hong Kong.

\* Correspondence: Joanne KY Lam, Department of Medicine, University of Hong Kong, Queen Mary Hospital, Pokfulam Road, Hong Kong (e-mail: kyjoanne414@yahoo.com.hk).

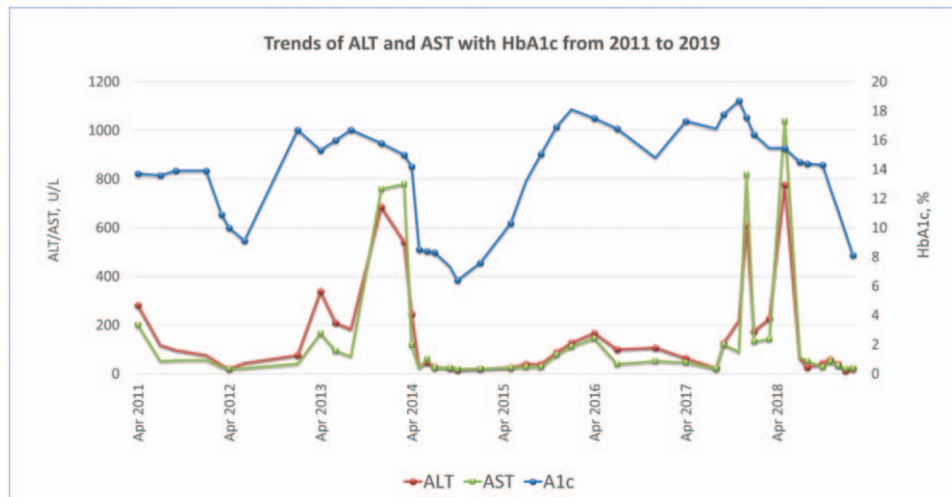
Copyright © 2019 the Author(s). Published by Wolters Kluwer Health, Inc. This is an open access article distributed under the terms of the Creative Commons Attribution-Non Commercial-No Derivatives License 4.0 (CCBY-NC-ND), where it is permissible to download and share the work provided it is properly cited. The work cannot be changed in any way or used commercially without permission from the journal.

Medicine (2019) 98:17(e15296)

Received: 25 November 2018 / Received in final form: 14 March 2019 /

Accepted: 25 March 2019

<http://dx.doi.org/10.1097/MD.00000000000015296>



**Figure 1.** Trends of alanine aminotransferase (ALT) and aspartate aminotransferase (AST) with HbA1c from 2011 to 2019.

with recurrent episodes of transaminitis mimicking acute hepatitis on 8 years of follow-up, Fibroscan results suggestive of borderline fibrosis, and subsequent liver biopsy confirming the diagnosis of GH almost 5 years after of the first transaminase flare, highlighting the problem of under-recognition and delay in diagnosis.

## 2. Case report

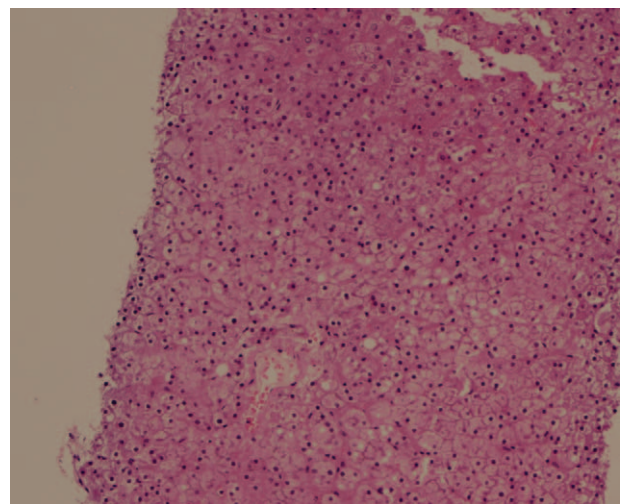
We report a 28-year-old woman with DM1 diagnosed since age of 3, all along on basal-bolus insulin therapy. Her DM1 was all along poorly controlled with hemoglobin A1c (HbA1c) ranging between 10% and 14%, complicated with triopathy and repeated hospitalizations for diabetic ketoacidosis and severe hypoglycemia. During follow-up in November 2017, she was noted to have transaminases elevated close to 10 times the upper limit of normal (ULN), thus admitted for further investigations. Before admission, her HbA1c progressively rose from 13.2% in July 2015 to 18.7% in November 2017. She was even admitted once in April 2017 for diabetic ketoacidosis due to omission of insulin. Ultrasonography of hepatobiliary system showed a prominent liver and a 1.3cm hepatic hemangioma only. Serological testing for hepatitis A, B, C, and E was negative. As liver function subsequently improved, she was discharged and monitored on an outpatient basis. However, her liver function tests worsened in December 2017 and she was admitted again for monitoring and further assessment. At that time, her liver function tests showed bilirubin 5  $\mu\text{mol/L}$  (normal range [NR]: 4–23), alkaline phosphatase 183U/L (NR: 32–93), alanine aminotransferase (ALT) 612U/L (NR: 7–36), aspartate aminotransferase (AST) 819U/L (NR: 14–30), gamma-glutamyltransferase 134U/L (NR:  $\leq 35$ ), and normal albumin. Anti-nuclear antibody titre was 1/80, anti-smooth muscle antibody was weakly positive (vessels pattern), anti-mitochondria antibody was negative, serum for protein electrophoresis showed no monoclonal band. Serum ceruloplasmin was not low. Fibroscan in December 2017 revealed controlled attenuation parameter of 260dB/m (suggestive of moderate steatosis)<sup>[15]</sup> and fibrosis score 8.9 kPa (suggestive of borderline fibrosis)<sup>[16]</sup> Review of the past trend of transaminase and

HbA1c levels in her adulthood revealed an apparent temporal correlation. (Fig. 1)

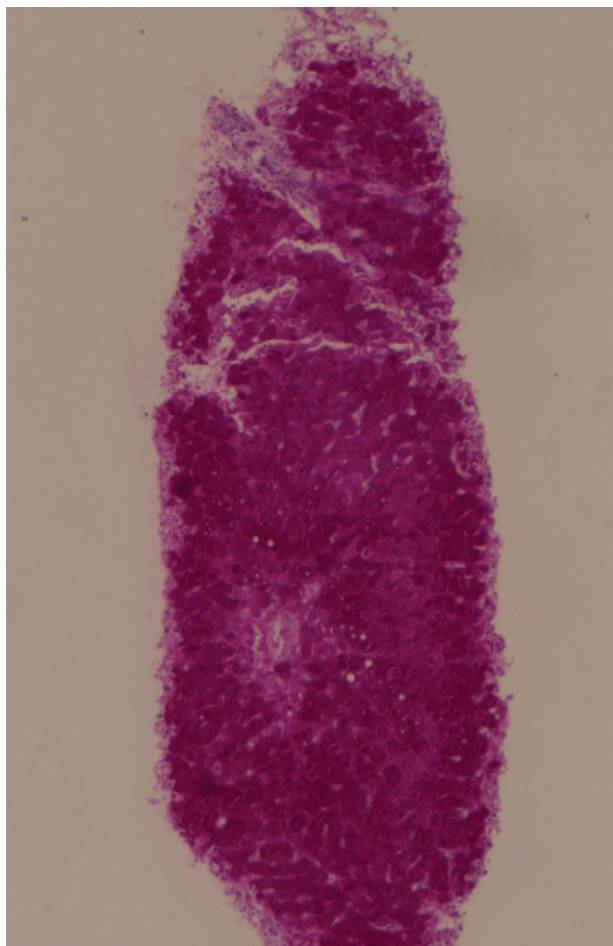
Ultrasound-guided liver biopsy was performed in March 2018 which showed an increase in glycogen deposition on Periodic-Acid Schiff stain and diastase, confirming the diagnosis of GH. The architecture of liver parenchyma was intact and there was no inflammation or significant fibrosis (Figs. 2–4). The diagnosis of GH was ascertained based on:

1. the compatible clinical presentation of long-standing poorly controlled DM1 with transaminase flare;
2. the histological features fulfilling the diagnostic criteria of GH; and
3. exclusion of alternative diagnoses by extensive laboratory investigations.

She was reinforced on the importance of adherence to insulin therapy, and her glycemic control improved with adjustment of

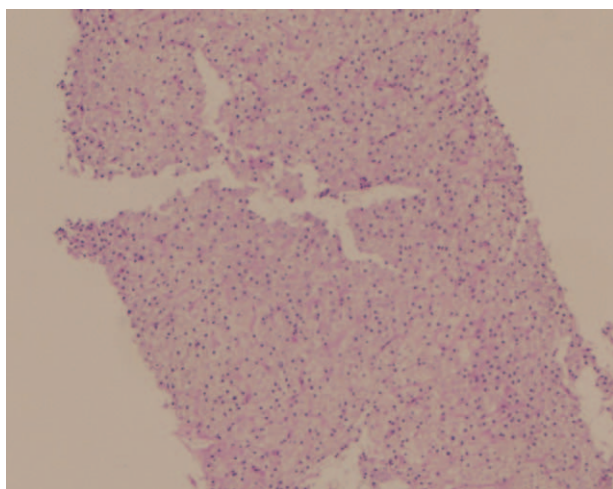


**Figure 2.** Haematoxylin and Eosin stain of the liver biopsy specimen showed enlarged hepatocyte with cytoplasmic pallor with reddish pink globule consistent with glycogen accumulation, and prominent glycogenated nuclei.



**Figure 3.** Abundant cytoplasmic glycogen deposits stained by Periodic-Acid Schiff stain.

insulin dosage. Her liver function was closely monitored upon follow-up. Her transaminases have normalized since July 2018, while her HbA1c gradually improved from 16.4% in January



**Figure 4.** Diastase removed the stained glycogen leaving empty looking cytoplasm and nuclei.

2018, 14.5% in July 2018, to latest HbA1c of 8.1% in February 2019. In retrospect, the transaminase flare in late 2013 was compatible with GH as well. Thus, the definitive diagnosis was made 5 years later.

### 3. Discussion

Elevated transaminases are commonly encountered in patients with diabetes. NAFLD is a much more common diagnosis compared to GH. However, it is important to differentiate between the 2 entities as NAFLD can progress to advanced liver disease, whereas GH runs a benign clinical course.<sup>[1]</sup> Mauriac syndrome, a full-blown syndrome of GH, initially described in the 1930s among pediatric patients with brittle diabetes, hepatomegaly, Cushingoid features, and poor growth and development, is now rarely seen. GH is the unified term to describe the hepatocyte glycogen overload without extrahepatic features of Mauriac syndrome, which better reflects non-inflammatory pathologic findings.<sup>[12]</sup>

The exact prevalence and incidence of GH remain unknown. It is predominantly seen in pediatric population and young adults, with poorly controlled DM1, and occasionally type 2 diabetes.<sup>[1,17]</sup> A recent review of cases of GH revealed slight female predominance.<sup>[4]</sup> Risk factors for GH included poorly controlled DM1 and history of diabetic ketoacidosis.<sup>[11]</sup>

Pathogenesis of GH is still not fully understood. One of the essential elements is the wide fluctuations in glycemia and insulin.<sup>[3]</sup> The most accepted theory is that insulin and excess glucose activates glycogen synthase phosphatase into activated glycogen synthase, an enzyme required for the conversion of glucose-1-phosphate to glycogen, which in turn promotes glycogen formation and storage in the liver and blocks glycogenolysis, increasing hepatic glycogen stores during hyperglycemia. The insulin administered as the main treatment for hyperglycemia further drives glycogen synthesis and inhibits gluconeogenesis and glycogenolysis, leading to increasing hepatocyte glycogen stores. The glycogen overload gives rise to hepatomegaly.<sup>[1-4,11]</sup>

Clinically, patients with GH may be asymptomatic, present with symptoms of acute hepatitis or acute hyperglycemia, or with tender hepatomegaly without splenomegaly.<sup>[1,4]</sup> In a recent review of cases of GH, abnormalities in liver function test are found to be predominantly transaminase elevation, bilirubin is only elevated in 15% of cases up to 43  $\mu\text{mol/L}$ , and prothrombin time is normal in all cases.<sup>[11]</sup>

GH is suspected when transaminase flare occurs in patients with long-standing poorly controlled DM1, usually with exaggerated HbA1c levels, especially after drug-induced, viral, autoimmune and metabolic liver diseases are excluded.<sup>[2,4,18]</sup> Serologic testing mainly excludes other causes of hepatomegaly and chronic hepatitis, as DM1 is associated with autoimmune disorders.

Non-invasive imaging does not help to reach the definitive diagnosis of GH, but some radiological features may be suggestive.<sup>[4]</sup> On computed tomography, the bright liver compared to spleen on pre-contrast image may suggest GH rather than NAFLD.<sup>[19]</sup> On gradient dual-echo magnetic resonance imaging, signal drop between T1 in-phase and out-of-phase suggests intrahepatic fat storage, more consistent with NAFLD.<sup>[20]</sup> Fibroscan, a non-invasive method of measuring liver elastography, is mainly performed for evidence of fibrosis where no or minimal fibrosis is expected in GH.<sup>[1,13]</sup>



The gold standard of diagnosis is liver biopsy.<sup>[4]</sup> The histological features of GH are:

1. marked glycogen accumulation resulting in pale, swollen hepatocytes;
2. no or mild fatty change;
3. no or minimal inflammation;
4. no or minimal spotty lobular necrosis; and
5. intact architecture with no significant fibrosis.<sup>[4]</sup>

The mainstay of treatment of GH is optimization of glycemic control with subcutaneous insulin.<sup>[1,2,4]</sup> Typically, the transaminases may normalize within days to months upon optimization of glycemic control.<sup>[1,2,4,5]</sup> GH is usually reported to run a benign course and be associated with favorable prognosis.<sup>[4]</sup> None of the patients developed long-term sequelae of liver disease secondary to glycogen accumulation.<sup>[10,11]</sup> However, GH has also been reported to be associated with varying degree of fibrosis, mostly mild,<sup>[3,10–12]</sup> significance of which merits further studies. More reports on data of Fibroscan in patients with GH may be useful on long-term follow up to study the significance of fibrosis in GH.

Here we have reported a young Chinese woman with long-standing poorly controlled DM1 presented with recurrent transaminase flare, Fibroscan suggestive of borderline fibrosis, subsequently diagnosed to have GH by liver biopsy. In contrast to the existing literature, we have described a long-term correlation between glycemic control and liver function, demonstrating the issue of under-recognition of this clinical entity and the delay in diagnosis. In addition, we have reported the Fibroscan result of our patient, lacking in previous reports. Fibroscan is a non-invasive assessment of the degree of fibrosis in GH, and may be useful to study the significance of fibrosis in GH in the long run.

#### 4. Conclusion

Deranged liver function is a commonly encountered problem in patients with diabetes. GH is suspected when transaminase flare occurs in patients with poorly controlled DM1, usually with exaggerated HbA1c levels, especially after drug-induced, viral, autoimmune and metabolic liver diseases are excluded. Liver biopsy remains the gold standard of diagnosis of GH. GH is associated with favorable prognosis and runs a benign course, which makes the differentiation from NAFLD clinically important. Diagnosis of GH also presents an opportunity for clinicians to discuss with patients on optimization of glycemic control, as the deranged liver function in GH is reversible upon improved glycemic control. Further data on Fibroscan may be valuable to study the prognostic significance of fibrosis in GH.

#### Author contributions

**Conceptualization:** David TW Lui, Yu-Cho Woo, Wing-Sun Chow, Chi-ho Lee, Alan CH Lee, Eunice KH Leung, Kathryn CB Tan, Karen SL Lam, Joanne KY Lam.

**Investigation:** David TW Lui, Yu-Cho Woo, Wing-Sun Chow, Chi-ho Lee, Alan CH Lee, Eunice KH Leung, Kathryn CB Tan, Karen SL Lam, Joanne KY Lam.

**Supervision:** Yu-Cho Woo, Wing-Sun Chow, Chi-ho Lee, Alan CH Lee, Kathryn CB Tan, Karen SL Lam, Joanne KY Lam.

**Writing – original draft:** David TW Lui.

**Writing – review & editing:** David TW Lui, Yu-Cho Woo, Wing-Sun Chow, Chi-ho Lee, Alan CH Lee, Eunice KH Leung, Kathryn CB Tan, Karen SL Lam, Joanne KY Lam.

#### References

- [1] Sherigar JM, Castro J, De , et al. Glycogenic hepatopathy: a narrative review. *World J Hepatol* 2018;10:172–85.
- [2] Abboud W, Abdulla S, Al Zaabi M, et al. Young man with hepatomegaly: a case of glycogenic hepatopathy. *Case Rep Hepatol* 2018;2018:6037530. doi:10.1155/2018/6037530.
- [3] Sherigar JM, Darouichi Y, Guss D, et al. An unusual presentation of glycogenic hepatopathy with bridging fibrosis. *ACG Case Rep J* 2018;5:e31. doi:10.14309/crj.2018.31.
- [4] Khoury J, Zohar Y, Shehadeh N, et al. Glycogenic hepatopathy. *Hepatobiliary Pancreat Dis Int* 2018;17:113–8.
- [5] Chen Z-Y, Liu Y-P, Zhou D-J. Hepatobiliary and pancreatic: glycogenic hepatopathy in a patient with poorly controlled diabetes mellitus mimics a hepatic neoplasm. *J Gastroenterol Hepatol* 2019;34:632.
- [6] Imtiaz KE, Healy C, Sharif S, et al. Glycogenic hepatopathy in type 1 diabetes: an underrecognized condition. *Diabetes Care* 2013;36:e6–7.
- [7] Hudacko RM, Manoukian AV, Schneider SH, et al. Clinical resolution of glycogenic hepatopathy following improved glycemic control. *J Diabetes Complicat* 2008;22:329–30.
- [8] Morton A. Is it possible to distinguish between glycogenic hepatopathy and non-alcoholic fatty liver disease without liver biopsy? *Intern Med J* 2016;46:1232. doi:10.1111/imj.12928.
- [9] Satyarengga M, Zubatov Y, Frances S, et al. Hepatopathy glycogenic: a complication of uncontrolled diabetes. *AACE Clin Case Rep* 2017;3:e255–9.
- [10] Ikarashi Y, Kogiso T, Hashimoto E, et al. Four cases of type 1 diabetes mellitus showing sharp serum transaminase increases and hepatomegaly due to glycogenic hepatopathy. *Hepatol Res* 2017;47:E201–9.
- [11] Mukewar S, Sharma A, Lackore KA, et al. Clinical, biochemical, and histopathology features of patients with glycogenic hepatopathy. *Clin Gastroenterol Hepatol* 2017;15:927–33.
- [12] Torbenson M, Chen Y-Y, Brunt E, et al. Glycogenic hepatopathy: an underrecognized hepatic complication of diabetes mellitus. *Am J Surg Pathol* 2006;30:508–13.
- [13] Saxena P, Turner I, McIndoe R. Education and imaging. hepatobiliary and pancreatic: glycogenic hepatopathy: a reversible condition. *J Gastroenterol Hepatol* 2010;25:646. doi:10.1111/j.1440-1746.2010.06178.x.
- [14] Cha JH, Ra SH, Park YM, et al. Three cases of glycogenic hepatopathy mimicking acute and relapsing hepatitis in type I diabetes mellitus. *Clin Mol Hepatol* 2013;19:421–5.
- [15] Sasso M, Beaugrand M, de Ledinghen V, et al. Controlled attenuation parameter (CAP): a novel VCTE guided ultrasonic attenuation measurement for the evaluation of hepatic steatosis: preliminary study and validation in a cohort of patients with chronic liver disease from various causes. *Ultrasound Med Biol* 2010;36:1825–35.
- [16] Wong VW-S, Vergniol J, Wong GL-H, et al. Diagnosis of fibrosis and cirrhosis using liver stiffness measurement in nonalcoholic fatty liver disease. *Hepatology* 2010;51:454–62.
- [17] Umpaichitra V. Unusual glycogenic hepatopathy causing abnormal liver enzymes in a morbidly obese adolescent with well-controlled type 2 diabetes: resolved after A1c was normalized by metformin. *Clin Obes* 2016;6:281–4.
- [18] Messeri S, Messerini L, Vizzutti F, et al. Glycogenic hepatopathy associated with type 1 diabetes mellitus as a cause of recurrent liver damage. *Ann Hepatol* 2012;11:554–8.
- [19] Sweetser S, Kraichely RE. The bright liver of glycogenic hepatopathy. *Hepatology* 2010;51:711–2.
- [20] Saikusa M, Yatsuga S, Tonan T, et al. Glycogenic hepatopathy and non-alcoholic fatty liver disease in type 1 diabetes patients. *Pediatr Int* 2013;55:806–7.