



Case report

Lumbosacral polyradiculitis associated with brucellosis

Fatemeh Sadat Mahdavi^a, Nahid Abbasi Khoshsirat^{b,*}, Atossa Madanipour^a^a Student Research Committee, Alborz University of Medical Sciences, Karaj, Iran^b Clinical Research Development Unit Shahid Rajaei, Educational & Medical Center, Alborz University of Medical Sciences, Karaj, Iran

ARTICLE INFO

Article history:

Received 7 October 2020

Received in revised form 9 December 2020

Accepted 13 December 2020

Keywords:

Brucellosis
Neurobrucellosis
Polyradiculitis
Paraparesis

ABSTRACT

Introduction: Brucellosis is a bacterial disease caused by different species of *Brucella*. Neurobrucellosis is one of the complications of brucellosis and polyradiculopathy is an uncommon manifestation.

Case report: In this article we report a 29-year-old male patient diagnosed with neurobrucellosis who presented with subacute lower limbs weakness and inability to walk in the last 50 days. The patient declared usage of non-pasteurized dairy products in his past medical history. Diagnosis was confirmed by the LP of CSF and serological tests. Although PCR for *Brucella* was negative, Wright, Coombs Wright and 2ME tests were reported positive in both CSF and serum. MRI and EMG were also performed that highlighted polyradiculopathy. After six months treatment, complete clinical recovery along with elimination of nerve root enhancement in MRI by injection in the lumbosacral region was seen.

Conclusion: Neurobrucellosis is a serious manifestation of Brucellosis that can have many side effects. Therefore, clinicians must pay attention to the neurological manifestations of this disease, but also reduce the effects of this disease by accelerating the start of treatment.

© 2020 The Authors. Published by Elsevier Ltd. This is an open access article under the CC BY-NC-ND license (<http://creativecommons.org/licenses/by-nc-nd/4.0/>).

Introduction

Brucellae are gram-negative coccoid rods that have "fine sand" microscope appearance. These very small bacteria are the brucellosis pathogens. Neurobrucellosis is a rare type of brucellosis. This focal complication is a nervous system involvement that can be seen in all stages of the disease [1]. This uncommon presentation of brucellosis is a zoonotic disease caused by genus *Brucella* [2]. It is known as global distribution, but it is more prevalent in limited countries in term of standardizing domestic animal health programs and available treatment sources [3]. It is also an endemic infection in Iran. Organisms of *Brucella* are mostly transferred by non-pasteurized dairy products and therefore more likely to occur during rural trips or related occupations [4,5]. The long duration of the disease brings harmful damage to human and livestock. Lack of necessary facilities in areas with higher prevalence increases the damage. According to the high rate of the economic burden imposed on patients beside several problems created for the country, especially in the fields of economic, its prevention and treatment should be a priority [6].

The most common and primitive clinical brucellosis signs are headache, fever and muscle and joint pain. Some other general

symptoms are sweating, low back pain, weight loss, fatigue, loss of appetite, vomiting and amenorrhea. In addition, there are several neurologic symptoms for this infection which the most significant items to name are confusion, blurred vision, loss of hearing, incontinence, meningoencephalitis, myelitis, peripheral neuritis, cranial neuropathies and psychiatric manifestations [7]. The rarest one among previously mentioned manifestations is peripheral neuritis [8].

The diagnosis results obtained from one of the following criteria are efficient confirmations to hospitalized patients: 1. Clinical observation of signs and symptoms considered for neurobrucellosis, 2. *Brucella* species and/or anti-*Brucella* antibodies existence in cerebrospinal fluid (CSF), 3. The existence of lymphocytosis beside increase of protein, and decrease of glucose levels in CSF, and 4. Diagnostic findings in cranial magnetic resonance imaging or CT [2].

Neurobrucellosis is known as a curable disease. The outcome that is recorded through the treated cases, presented appropriate results [4,9]. The remarkable point to notice is that the length of treatment is under the influence of the patient's condition, but sequelae could be removed or controlled by early diagnosis and treatment [10,11]. Here we report a 29-year-old male diagnosed with neurobrucellosis.

Case report

A 29-year-old male complaining of subacute lower limbs weakness and inability to walk was referred to our hospital 50 days

* Corresponding author.

E-mail addresses: fatemehsadatmahdavi@yahoo.com (F.S. Mahdavi), nahid.a.kh1384@gmail.com (N. Abbasi Khoshsirat).

before hospitalization. He was also complainant of low back pain in the second place. The weakness of the lower limbs in the form of subacute paraparesis was obvious, but there was no sphincter disorder. No fever was documented at the time of the patient's visit. There was no pain in the patient's head and visual or auditory disturbances have not been reported.

He had previously been hospitalized in another medical center, but no diagnosis has been made. Myelitis was reported as a differential diagnosis due to similar clinical features. Therapeutic plasma exchange was used as a treatment, but no response to the treatment was seen. History of local dairy consumption by him and his family in about 8 months ago was also mentioned. Apart from this, he has no history of other illnesses.

Initial examination of the patient presented that the symmetrical weakness of the lower limbs was $\frac{3}{5}$, reduced reflexes were seen in the lower limbs and down plantar, and stance and gate inability. Other neurological examinations were normal. During the clinical examination absence of lymphadenopathy confirmed and no localized pain over the spinal column was detected. In addition, there were no neurological or psychiatric problems. The hands were not weakened and there was no impairment in swallowing and breathing. It should also be noted that sweating and body aches were not recorded at the time of admission. Based on the examination, with particular attention to the occurrence of subacute paraparesis and the history of local dairy consumption in the recent past, neuro-brucellosis was reviewed as a differential diagnosis.

Serological tests such as serum and CSF infections, cytological tests to diagnose malignancy and rule out metastasis meningitis, multiplex PCR test (CMV, TB, HSV1 AND HSV2, Brucella) of CSF, HBS, HIV, anti HCV and vasculitis tests (ANA, RF, SSA, SSB, dsDNA, C-ANCA and P-ANCA, ASA, Antiphospholipid antibody and Anti-cardiolipin antibody) were all reported negative. CRP and RPR were negative and ESR was within the normal range. Noticing that the PCR result was reported negative in CSF, but the presented numbers were in the positive range.

Vasculitis related tests, as well as infectious diseases in serum and CSF tests, were performed for the patient. 2ME, Wright and Coombs Wright tests were reported positively in both serum and CSF. The results showed 1/40 for the 2ME test, 1/80 for the Wright test and 1/160 for the Coombs Wright test. Results were similar in the serum.

Spinal MRI in the lumbosacral region revealed decreased lordosis of the lumbar spine, mild disc bulging at L4-L5 and L5-S1 and diffuse cauda equina and nerve root enhancement (Figs. 1 and 2). There was no evidence of canal stenosis. Guillain Barre syndrome and other inflammatory conditions such as spinal meningitis was included in the differential diagnosis. MRI of the upper spine and brain was normal. CT scans of the lungs, abdomen and pelvis were reported normal as well. Electromyography showed a normal SNAP and a decrease in CMAP amplitude of the lower limbs with the neurological change process of the lower limb's muscles suggesting acute anterior horn cell disease or polyradiculopathy. This imaging process has been done due to rule out paraneoplastic syndrome because of the similar symptoms for malignancy.

The patient underwent LP three times, according to the Fluid Biochemistry and Fluid count of the CSF analysis for the first time the following results were obtained; 45 for glucose, 150 for protein, and 22 for LDH. This analyze also reported 102 for WBC (Lymph: 96 – Poly: 6), and 0 for RBC. Besides, the colour was reported as colourless with a clear appearance and no bacteria were detected. To confirm the diagnosis, LP was performed for the second time that the results were similar to the first CSF analysis.

Tests for Wright and 2ME in the patient's wife and his 5-year-old child with a history of local dairy products consumption 8 months

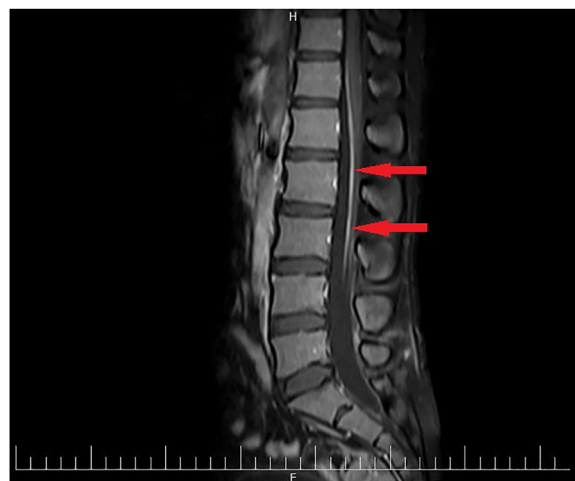


Fig. 1. T1-weighted sagittal MRI with contrast view of the lumbosacral region. Arrows show roots enhancement in the lumbosacral region of the spine.

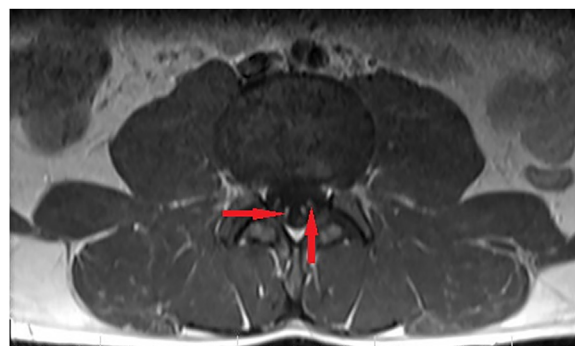

Fig. 2. T1-weighted axial MRI with contrast view of the lumbosacral region in which root enhancements are pointed with arrows.

ago were positive too. But they have shown no neurological symptoms.

With the diagnosis of neuro-brucellosis, treatment began with injectable ceftriaxone, ciprofloxacin, and doxycycline and after a few weeks, the LP was repeated, indicating that protein and WBC were significantly reduced in CSF as the WBC was decreased to 50 and protein was decreased to 12 (Glucose had an increase to 68).

According to articles and findings doxycycline, rifampicin, ceftriaxone, trimethoprim-sulfamethoxazole, ciprofloxacin and streptomycin are some of the pharmaceuticals that appeared effectively during the treatment process. Ceftriaxone, ciprofloxacin, and doxycycline were prescribed for this case, given that at least three drugs must be used to treat this disease.

Finally, the patient was discharged with a month continuation of injectable ceftriaxone, along with oral ciprofloxacin, and doxycycline. During a visit after one month that the patient was released, subacute paraparesis was turned to the ability to walk without assistance. Complete clinical recovery beside elimination of nerve root enhancement in MRI by injection in the lumbosacral region was seen after the duration of treatment. Serology test result related to 6 months after the start of the treatment showed $\frac{1}{40}$ for Wright and Coombs Wright test and $\frac{1}{20}$ for 2ME test that both results showed an improvement. Muscle strength also reached $\frac{5}{5}$. The patients' family underwent the routine treatment of brucellosis and achieved complete recovery as well.

Discussion

The organism of this infection, intracellular gram-negative bacteria called *Brucella*, was first recognized by Sir David Bruce who was a member of Army Medical Services [11,12]. Spleen, livers, and kidneys tissue extracted from autopsy material of a fatal case of Malta fever on the island of Malta provided the first possibility of this bacteria isolation [8,11]. Fever and headache were the first clinical manifestations of the disease, and both central nervous system (CNS) and peripheral nervous system (PNS) involvement counted as a serious complication in the course of the disease [7]. It should also be noted that clinical presentation is completely heterogeneous [12,13].

Neurobrucellosis has a variety of presentations and may be misdiagnosed with many other diseases such as syphilis, tuberculosis and Behcet's syndrome. Our clinical manifestations can be acute toxic manifestations such as toxic febrile that is prevalent in neuro-brucellosis, meningitis, radiculopathy, transverse myelitis, encephalitis, brain abscess, meningovascular, cerebral infarct, neurites and myelopathy [3,14–17].

The prevalence of brucellosis is widespread in the world, but most cases are found in the Mediterranean Basin, the Arabian Peninsula, the Indian subcontinent and parts of Central and South America. The average results of a 4-year study in Iran showed that the highest prevalence was in the western mountainous areas of the country (112.4 out of 100000) and the lowest was in Isfahan (2.5 out of 100000) [18]. It should also be noted that different prevalence rates have been reported in different articles but can be between 5 and 7% [19]. In our case, there was an environmental conflict in the legs for the patient.

The most common manifestation of neuro-brucellosis is meningitis or meningoencephalitis [20]. Polyradiculopathy, which was also observed in our case, is less common among the manifestations of this disease [21]. Due to the fact that immunological mechanisms with direct invasion cause demyelination in the white areas of the brain, spinal cord and peripheral nerves, it can be said that the peripheral manifestations of this event are environmental myelopathy, radiculopathy or polyradiculopathy, which involves the legs more than the hands [7]. The involvement of legs was also occurred in our case.

Typical changes in cerebrospinal fluid that have been detected through the LP including the presence of lymphocyte, an increase of protein and decrease of glucose are confirmations for neuro-brucellosis [22]. In the patient we examined, the first LP showed 96 for lymph, 150 for protein, and 45 for glucose, which all showed the same mentioned changes and these LP results testified to the claim that the case had neuro-brucellosis.

In this article, we reported a case of neuro-brucellosis in a 29-year-old male with clinical manifestations of subacute paraparesis along with obvious lower limbs weakness. One of the important things that helped us diagnose this disease was paying attention to the patient's job, diet and culture. It was finally confirmed that the disease was caused by the consumption of non-pasteurized local dairy products, which was indicated in the description taken from the patient.

Our achievement, in this case, was related to the relationship between the patient's complaints and the history of consuming unpasteurized dairy products with the new manifestations of the disease which was chronic neurological disorders especially is lower parts. We had done LP several times to monitor the patient's condition carefully.

In this case, the complex of changes in EMG, MRI and LP represented lumbar roots involvement or polyradiculopathy which is a rare complication of *Brucella*. Roots enhancement was a very useful point that was noticed from the MRI results. Also, electromyography showed involvement of the peripheral nervous

system similar to the neuron motor disease that was remarkable. Another interesting point about this case was the positive tests of Wright and 2ME in the patient's wife and his child, who also consumed local dairy products.

Treatment with doxycycline, rifampin, trimethoprim, sulfamethoxazole, streptomycin, or ceftriaxone is recommended for more than two months. In our case, due to the drug resistance in the area, ceftriaxone, doxycycline and ciprofloxacin were prescribed, and 6 months after receiving the drug, we saw the patient's recovery [2].

Neurobrucellosis is a serious manifestation of Brucellosis that can have many side effects. Since our country is considered an endemic geographical location for brucellosis, we must pay attention to the neurological manifestations of this disease, but also reduce the effects of this disease by accelerating the start of treatment.

Author contribution

FSM contributed in design of the study, acquisition of data, and drafting the article and approved the final version of the manuscript for submission.

NAK contributed in study design, writing the paper and review and edited the final version of the paper.

AM contributed in data gathering and drafting the main article, and final approval of the submission.

Consent section

Written informed consent was obtained from the patient for publication of this case report and accompanying images. A copy of the written consent is available for review by the Editor-in-Chief of this journal on request.

Funding

None.

CRediT authorship contribution statement

Fatemeh Sadat Mahdavi: Conceptualization, Methodology, Investigation, Writing - original draft, Writing - review & editing. **Nahid Abbasi Khoshsirat:** Conceptualization, Validation, Writing - original draft, Writing - review & editing, Supervision. **Atossa Madanipour:** Investigation, Writing - original draft.

Declaration of Competing Interest

The authors report no declarations of interest.

References

- [1] Abbasi F, Korooni S, Turgut AT. *Brucella* Polyradiculoneuritis. Neurobrucellosis. Springer; 2016. p. 129–33.
- [2] Guven T, Ugurlu K, Ergonul O, Celikbas AK, Gok SE, Comoglu S, et al. Neurobrucellosis: clinical and diagnostic features. Clin Infect Dis 2013;56(10):1407–12.
- [3] Dreshaj S, Shala N, Dreshaj G, Ramadani N, Ponosheci A. Clinical manifestations in 82 neurobrucellosis patients from Kosovo. Mater Sociomed 2016;28(6):408.
- [4] Ceran N, Turkoglu R, Erdem I, Inan A, Engin D, Tireli H, et al. Neurobrucellosis: clinical, diagnostic, therapeutic features and outcome. Unusual clinical presentations in an endemic region. Braz J Infect Dis 2011;15(1):52–9.
- [5] Hassouneh L, Quadri S, Pichilingue-Reto P, Chaisavaneeyakorn S, Cutrell JB, Wetzel DM, editors. et al. An outbreak of brucellosis: an adult and pediatric case series. Open forum infectious diseases. Oxford University Press US; 2019.
- [6] Chomel BB. Control and prevention of emerging zoonoses. J Vet Med Educ 2003;30(2):145–7.
- [7] Haji AAM, Rasoulnezhad M, Jafari S, Hasibi M, Soudbakhsh A. Clinical and laboratory findings in neurobrucellosis: review of 31 cases. 2008.

- [8] Gul HC, Erdem H, Bek S. Overview of neurobrucellosis: a pooled analysis of 187 cases. *Int J Infect Dis* 2009;13(6) e339-e43.
- [9] Asadipooya K, Dehghanian A, Omrani GHR, Abbasi F. Short-course treatment in neurobrucellosis: a study in Iran. *Neurol India* 2011;59(1):101.
- [10] Sahakyan G. Clinical manifestations of neurobrucellosis: the importance of diagnosis at early stages.(P4. 173). AAN Enterprises; 2015.
- [11] Zhao S, Cheng Y, Liao Y, Zhang Z, Yin X, Shi S. Treatment efficacy and risk factors of neurobrucellosis. *Med Sci Monit Int Med J Exp Clin Res* 2016;22:1005.
- [12] Yaghoobi MH, Siroos B, Foroumandi M, Gharabaghi MA. Tricky brucellosis. *Case Rep* 2013 2013:bcr2013009522.
- [13] Tan S, Davis C. David Bruce (1855–1931): discoverer of brucellosis. 2011.
- [14] Karsen H, Akdeniz H, Kasim Karahocagil M, Irmak H, Sünnetçioğlu M. Toxic-febrile neurobrucellosis, clinical findings and outcome of treatment of four cases based on our experience. *Scand J Infect Dis* 2007;39(11–12):990–5.
- [15] Lemnouer A, Frikh M, Maleb A, Ahizoune A, Bourazza A, Elouennass M. Brucellosis: A cause of meningitis not to neglect. *IDCases* 2017;10:97–9.
- [16] Yilmaz S, Avcu G, Beyazal M, Arslan M. A rare cause of seizures: brucellar brain abscess. *Braz J Infect Dis* 2016;20(3):310–1.
- [17] Ay S, Tur BS, Kutlay Ş. Cerebral infarct due to meningovascular neurobrucellosis: a case report. *Int J Infect Dis* 2010;14: e202-e4.
- [18] Dastjerdi MZ, Nobari RF, Ramazanpour J. Epidemiological features of human brucellosis in central Iran, 2006–2011. *Public Health* 2012;126(12):1058–62.
- [19] Raina S, Sharma A, Sharma R, Bhardwaj A. Neurobrucellosis: a case report from himachal pradesh, India, and review of the literature. *Case Rep Infect Dis* 2016;2016:.
- [20] Tuncel D, Uçmak H, Gokce M, Utku U. Neurobrucellosis. *Eur J Gen Med* 2008;5(4):245–8.
- [21] Al-Sous MW, Bohlega S, Al-Kawi M, McLean D, Ghaus S. Polyradiculopathy. A rare complication of neurobrucellosis. *Neurosciences* 2003;8(1):46–9.
- [22] Jiao L-D, Chu C-B, Kumar CJ, Cui J, Wang X-L, Wu L-Y, et al. Clinical and laboratory findings of nonacute neurobrucellosis. *Chin Med J* 2015;128(13):1831.