

# The value of sestamibi single-photon emission computed tomography/computed tomography in differentiating and staging renal cell carcinomas: A systematic review

Abdalla Ali Deb<sup>a</sup>, Ayman Agag<sup>b</sup>, Naufal Naushad<sup>c</sup>, Rajbabu Krishnamoorthy<sup>d</sup>, Hosam Serag<sup>e,\*</sup>

<sup>a</sup>Department of Urology, Aberdeen Royal Infirmary, Aberdeen, UK; <sup>b</sup>Department of Urology, Frimley Park Hospital, Camberely, UK;

<sup>c</sup>Department of Urology, Wythenshawe Hospital, Manchester University NHS Foundation Trust, Manchester, UK; <sup>d</sup>Department of Urology, Guthrie Corning Hospital, Corning, New York, USA; <sup>e</sup>Department of Urology, University Hospitals Birmingham, Birmingham, UK

## Abstract

Misdiagnosis of benign renal neoplasms can lead to unnecessary surgical resections, which increases the risk of other morbidities and mortality. Therefore, it is crucial to find a diagnostic modality for differentiation between benign and malignant renal masses. In the current study, we summarized published pieces of evidence concerning the use of technetium-99m (<sup>99m</sup>Tc)-sestamibi single-photon emission computed tomography/computed tomography (SPECT/CT) as a promising diagnostic nuclear imaging modality for the differentiation of renal neoplasms. The study was conducted according to the Preferred Reporting Items for Systematic Reviews and Meta-Analyses statement for Systematic Reviews and Meta-Analyses. We conducted a systematic electronic database search for suitable studies from inception till February 20, 2020 in 9 databases. The risk of bias was assessed for the included studies using the Quality Assessment of Diagnostic Accuracy Studies-2 tool. We identified 9373 records after exclusion of 8978 duplicates using EndNote software. Title and abstract screening resulted in 761 records for further full-text screening. Finally, four studies were included with total sample size of 80 patients. The overall risk of bias was low to moderate. The results of all the included studies supported using <sup>99m</sup>Tc-sestamibi SPECT/CT for the differentiation between benign and malignant renal neoplasms. The use of <sup>99m</sup>Tc-sestamibi SPECT/CT could be a rapid, less invasive, promising diagnostic modality for histological diagnosis and staging of renal neoplasm, as well as monitoring post-therapy tumor's response. However, more studies with large sample sizes are essential to confirm the reliability and accuracy of this modality for usage.

**Keywords:** <sup>99m</sup>Tc-sestamibi; Angiomyolipoma; Oncocytoma; Renal cell carcinoma; Systematic review

## 1. Introduction

Up to 3.3% of newly diagnosed cancers are renal tumors; they are considered the seventh most common malignancies. Renal cell carcinoma (RCC) represents 90%–95% of renal neoplasms. In 2006, the estimated financial burden for RCC was about 1.6 billion dollars.<sup>[1]</sup> Benign renal neoplasms represent about 10%–20% of all renal neoplasms and include hybrid oncocytic/chromophobe tumor (HOCT), oncocytoma, and angiomyolipoma.<sup>[2]</sup>

Benign renal neoplasms can be misdiagnosed as malignant with conventional imaging modalities, for example, contrast X-ray, computed tomography (CT), or magnetic resonance imaging

(MRI), particularly with the increasing incidence of tiny renal masses detection associated with frequent use of cross-sectional imaging. The misdiagnosis of benign renal neoplasm can lead to unnecessary surgical resections, which increase the risk of other morbidities (ie, operative/postoperative complications, and renal failure) and mortality. In the United States, the estimated worthless renal benign masses resections were about 5600 annually.<sup>[3]</sup> Therefore, it was crucial to find a diagnostic modality for differentiation between benign and malignant renal masses.

Gormley and colleagues were first to introduce technetium-99m (<sup>99m</sup>Tc)-sestamibi for differentiating benign from malignant renal neoplasms in 1996. This new modality of imaging was based on the concept of attraction between positively charged <sup>99m</sup>Tc-sestamibi and negatively charged mitochondrial membrane potential.<sup>[3,4]</sup> In fact, oncocytoma contains numerous mitochondria, while RCC is characterized by scarce and distorted mitochondria. Consequently, the benign tumor oncocytoma has a higher affinity for <sup>99m</sup>Tc-sestamibi uptake more than RCC. Thus, the use of sestamibi single-photon emission computed tomography/X-ray computed tomography (SPECT/CT) could assist in differentiating and staging RCC.

In the current study, we summarized published pieces of evidence that were retrieved through systemic steps of search, related to the use of <sup>99m</sup>Tc-sestamibi SPECT/CT as a promising

\* Corresponding Author: Hosam Serag, Department of Urology, University Hospitals Birmingham, Birmingham, B15 2GW, UK. E-mail address: [hosam.serag@uhb.nhs.uk](mailto:hosam.serag@uhb.nhs.uk) (H. Serag).

Current Urology, (2022) 16, 32–37

Received February 21, 2021; Accepted March 2, 2021.

<http://dx.doi.org/10.1097/CU9.0000000000000089>

Copyright © 2022 The Authors. Published by Wolters Kluwer Health, Inc. This is an open access article distributed under the terms of the Creative Commons Attribution-Non Commercial-No Derivatives License 4.0 (CCBY-NC-ND), where it is permissible to download and share the work provided it is properly cited. The work cannot be changed in any way or used commercially without permission from the journal.

diagnostic nuclear imaging modality. This modality could provide a swifter and less invasive method for identifying and grading variable histological types of renal tumors.

## 2. Methods

### 2.1. Criteria for considering studies for this review

Relevant observational studies were included which evaluated the diagnostic accuracy of <sup>99m</sup>Tc-sestamibi SPECT/CT for renal oncocytomas compared to other renal neoplasms, with the standard test being pathologic diagnosis. Papers were excluded if there were one of the following criteria: i) in vitro or animal studies; ii) data duplication, overlapping or unreliably extracted or incomplete data; iii) articles available only as abstracts, reviews, thesis, books, conference papers, case reports or case series, editorials, author responses, letters, and comments.

### 2.2. Search strategy and study selection

The study process was conducted following the accepted methodology recommendations of the PRISMA checklist for systematic review and meta-analysis, where registration of the protocol is not mandated.<sup>[5]</sup> We conducted a systematic electronic database search for suitable studies from inception till February 20, 2020 in 9 databases including Google Scholar, System for Information on Grey Literature in Europe, Scopus, Web of Science, PubMed, Virtual Health Library, ClinicalTrials.gov, metaRegister of Controlled Trials, and The WHO International Clinical Trials Registry Platform databases using the following search term: (“SPECT” OR “CT” OR “computed tomography”) AND (carcinoma, renal cell [MeSH Terms]). Missed relevant papers were collected via manual search trials in Google Scholar and references of the included papers.<sup>[6]</sup>

There were no restrictions on study design, year of publication, country, or language. Three independent reviewers screened titles and abstracts for selecting eligible papers. Further full-text screening was performed to ensure the inclusion of relevant papers in our systematic review. Any disagreement was resolved by discussion and consulting the senior member when necessary.

### 2.3. Data extraction

Two authors designed the extraction sheet on Microsoft Excel file by pilot extraction of at least 3 papers. Three reviewers independently extracted data from the included studies using the excel sheet. The fourth reviewer checked the accuracy of the extracted data. All the disagreements and discrepancies were resolved by discussion and consultation with a senior member when necessary.

### 2.4. Quality assessment

Three independent reviewers evaluated the risk of bias in the included studies. The Quality Assessment of Diagnostic Accuracy Studies-2 tool was used to assess the quality of individual studies through the evaluation of four domains: patient selection, index test, reference test, and flow and timing.<sup>[7]</sup> Any discrepancy between the reviewers was solved by discussion.

## 3. Results

### 3.1. Search results

We identified 9373 records after excluding 8978 duplicates by using EndNote software. Title and abstract screening resulted in 761 records for further full-text screening, which yielded 4 eligible papers for inclusion in our study. No papers were added

after performing manual search trials. Finally, we included four studies<sup>[2,3,8,9]</sup> for this systematic review (Fig. 1).

### 3.2. Basic characteristics of the included studies

There were 4 observational studies: 2 American,<sup>[2,8]</sup> 1 Swedish,<sup>[9]</sup> and 1 German.<sup>[3]</sup> The total sample size was 80 patients as the data of the same cohort of patients was used for analysis in 2 studies.<sup>[2,8]</sup> All studies were single-center and prospective in design. Two readers (nuclear medicine physicians) for the results of <sup>99m</sup>Tc-sestamibi SPECT/CT results were included in all the studies. Histopathological examination was performed on resected kidney in 2 studies,<sup>[2,8]</sup> while either biopsy or resected kidney were used for histopathological examination in the other 2 studies.<sup>[3,9]</sup> The basic characteristics of the included patients and the technique for <sup>99m</sup>Tc-sestamibi SPECT/CT are summarized in Tables 1 and 2.

### 3.3. Study outcomes

Rowe and colleagues<sup>[3]</sup> published a prospective study in 2015 in Germany. The study included 6 patients (3 with oncocytoma and 3 with RCC). They reported that all 3 oncocytomas (as diagnosed by histopathological examination) showed obvious <sup>99m</sup>Tc-sestamibi SPECT/CT uptake similar to or above that of the background normal renal parenchyma. On the other hand, RCCs demonstrated marked photopenia compared to the background normal renal parenchyma. However, the sample size was small, and no quantitative analysis of the relative uptake values was provided by the authors. In addition, the selection criteria of patients were not clear, blinding of readers or histopathologists was not stated, and the study did not include all histologic variants of RCC.

Gorin and colleagues<sup>[8]</sup> published a prospective study in 2016 which was carried out in the United States and included 50 patients with a solid clinical T1 renal mass to assess the diagnostic performance of <sup>99m</sup>Tc-sestamibi SPECT/CT for renal oncocytomas. All patients underwent imaging with <sup>99m</sup>Tc-sestamibi SPECT/CT before surgical resection. Afterwards, preoperative SPECT/CT scans were reviewed and compared with the results of centrally reviewed surgical pathology data. The pathology reports indicated that 6/50 (12%) tumors were renal oncocytomas, 2/60 (4%) were HOCTs, 1/60 (2%) was angiomyolipoma, and all the remaining tumors were RCCs (82%). They found that <sup>99m</sup>Tc-sestamibi SPECT/CT correctly identified 5/6 (83.3%) oncocytomas and 2/2 (100%) HOCTs, with an overall sensitivity of 87.5% (95% CI [confidence interval]=47.4%–99.7%). False positive results were found in only 2 chromophobe RCCs tumors, with a specificity of 95.2% (95% CI=83.8%–99.4%). They identified a cut-off value for relative uptake (0.6) to correctly classify tumors. There was nearly perfect inter- and intra-reader agreement (*k* values: 0.93–1.00), with only 1 (2%) tumor requiring reconciliation at the intrareader level. The limitations of this study included the relatively small sample size and patient selection was not specified whether it was consecutive or randomized.

Sheikhabahaei and colleagues<sup>[2]</sup> conducted a modified secondary analysis of the cohort of Gorin et al.<sup>[8]</sup> The secondary analysis was published in 2017 and included 48 patients with clinical stage T1 solid renal masses. All patients underwent a <sup>99m</sup>Tc-MIBI SPECT/CT before partial or radical nephrectomy. Two blinded readers had to score their confidence in classifying masses using conventional radiography at first (CT in 35 and MRI in 13 patients, performed within 8 weeks before <sup>99m</sup>Tc-MIBI SPECT/CT), then for a second time after adding the <sup>99m</sup>Tc-MIBI SPECT/

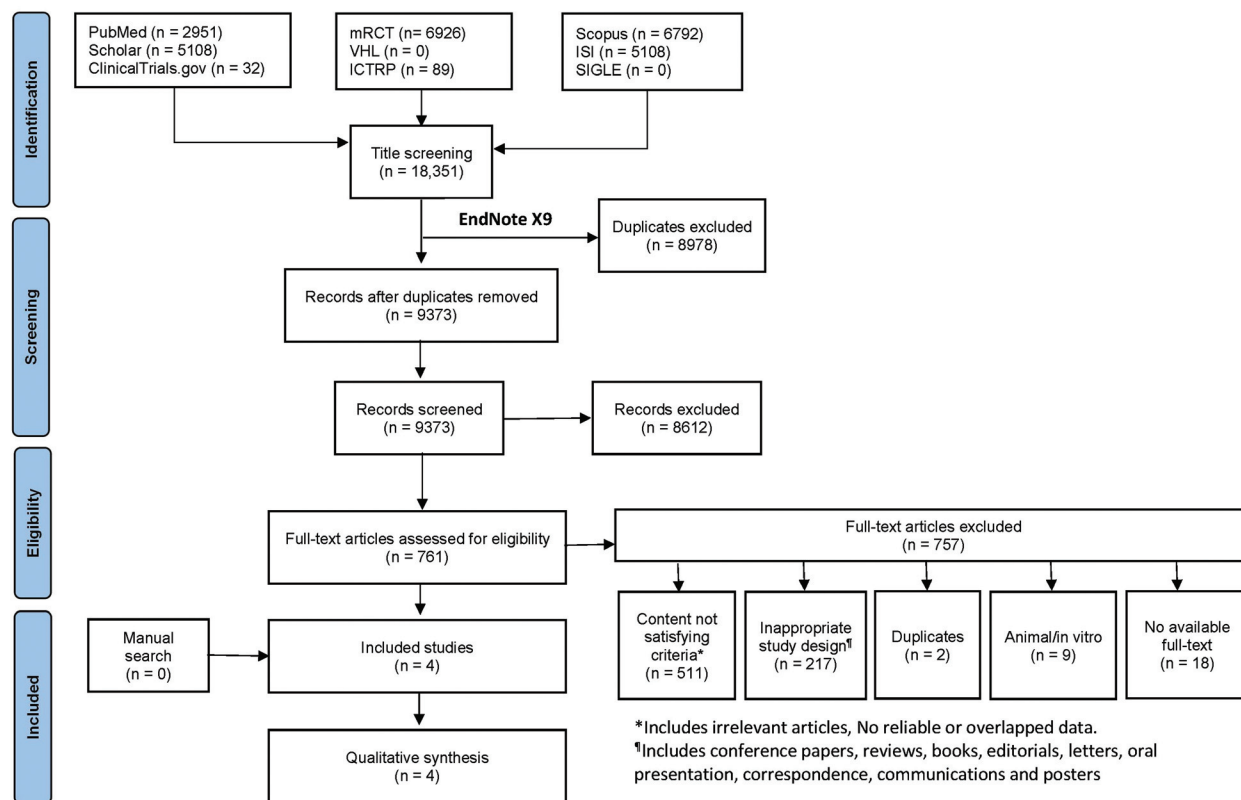


Figure 1. PRISMA flow-chart for strategy of search and its results.

CT uptake results. They reported that the inter-reader agreement was slight using conventional radiography ( $k=0.12$ ), but significantly increased to reach almost perfect agreement ( $k=0.8$ ) after adding  $^{99m}\text{Tc}$ -MIBI SPECT/CT uptake results. Addition of  $^{99m}\text{Tc}$ -MIBI SPECT/CT helped to identify 7/9 (77.8%) benign renal masses. Two patients with angiomyolipoma ( $n=1$ ) and oncocytoma ( $n=1$ ) were mistakenly classified as RCC, while 2 chromophobe RCCs were incorrectly classified as benign. Conventional imaging with added  $^{99m}\text{Tc}$ -MIBI SPECT/CT outperformed conventional imaging alone as the areas under the receiver operating characteristic (ROC) curve were 0.60 for CT/MRI (95% CI=0.37–0.82;  $p=0.36$ ) and 0.85 for  $^{99m}\text{Tc}$ -MIBI SPECT/CT (95% CI=0.69–1.00,  $p=0.001$ ). There was a statistically significant difference between the 2 ROC curves ( $p=0.03$ ). Although the findings of this study are encouraging, it is limited by the same limitations of Gorin et al.<sup>[8]</sup>

Tzortzakakis and colleagues<sup>[9]</sup> conducted a nonrandomized prospective study in Sweden that was published in 2017 and included 24 patients with 31 T1 solid renal tumors (4 patients had multiple bilateral renal lesions). Exclusion criteria included T2+ tumors, tumors >7 cm in maximum diameter, and presence of metastatic disease. Patients with renal impairment were not excluded.  $^{99m}\text{Tc}$ -sestamibi SPECT/CT imaging took place 4 days prior to surgery.  $^{99m}\text{Tc}$ -sestamibi SPECT/CT imaging identified correctly 11/12 oncocytomas and 14/19 malignant neoplasms. However, it identified incorrectly 1/12 oncocytomas and 5/19 malignant neoplasms (3 hybrid oncocytoma-chromophobe RCC, 1 angiomyolipoma, and 1 papillary RCC).

The results of  $^{99m}\text{Tc}$ -sestamibi SPECT/CT, with sensitivity and specificity, are summarized in Table 3. Some studies did not state

directly the sensitivity and specificity of the diagnostic performance of  $^{99m}\text{Tc}$ -sestamibi SPECT/CT but the authors of this systematic review calculated these measures from the counts of true and false positive and negative results.

### 3.4. Assessment of risk of bias in the included studies

The risk of bias was assessed using the Quality Assessment of Diagnostic Accuracy Studies-2 tool for each of the included studies. The risk of bias in patient selection was high in the study by Rowe et al.<sup>[3]</sup> as the eligibility criteria were not defined, uncertain in the studies by Gorin et al.<sup>[8]</sup> and Sheikhabaei et al.,<sup>[2]</sup> and low in the study by Tzortzakakis et al.<sup>[9]</sup> The risk of bias as regards the conduction of the index test ( $^{99m}\text{Tc}$ -sestamibi SPECT/CT) was low in all studies. The risk of bias as regards the reference standard (histopathological examination) was high in the studies by Gorin et al.<sup>[8]</sup> and Tzortzakakis et al.<sup>[9]</sup> due to the inclusion of biopsy in some cases instead of surgical pathology, the risk was uncertain in the study by Rowe et al.<sup>[3]</sup> as blinding of pathologists to the results of index test was not reported. Flow and timing of included patients in the individual studies carried uncertain risk of bias in all studies except for that by Tzortzakakis et al.<sup>[9]</sup> as the interval between  $^{99m}\text{Tc}$ -sestamibi SPECT/CT and surgical pathology was not clearly defined. There were no applicability concerns (low risk) in the 4 studies (Fig. 2). Examination of the overall risk of bias across the 4 studies revealed low risk in the domain of index test (100%), uncertainty in the domains of reference standard (25%), patient selection (50%), and flow and timing (75%), while high risk of bias in patient selection and reference standard represented 25% and 50%, respectively (Fig. 3).

**Table 1**

**Characteristics of the included studies.**

Country	Study	Total population	Age	Male (%)	Tumor diameter (cm)	Histologic type n (%)
Germany	Rowe et al. (2015)	6	Mean ± SD (range) = 59.3 ± 17.2 (38–78)	83.3%	Mean ± SD (range) = 4.1 ± 1.5 (2.5–6.2)	Oncocytoma 3 (50%) Clear cell RCC 1 (16.7%) Unclassified RCC 1 (16.7%) Xp11 translocation 1 (16.7%)
USA	Gorin et al. (2016)	50	Median (range) = 61.8 (53.2–70.8)	74%	Median (range) = 3.0 (2.2–4.8)	Oncocytoma 6 (12%) HOCT 2 (4%) Clear cell RCC 26 (52%) Papillary RCC 8 (16%) Chromophobe RCC 4 (8%) Clear cell papillary RCC 2 (4%) Unclassified RCC 1 (2%) Angiomyolipoma 1 (2%)
USA	Sheikhbahaei et al. (2017)	48	Median (range) = 59 (40–81)	72.9	Mean (IQR) = 2.95 (2.20–4.55)	Oncocytoma 6 (12.5%) HOCT 2 (4.2%) Angioliipoma 1 (2.0%) Clear cell RCC 25 (52.1%) Papillary RCC 7 (14.6%) Clear cell papillary RCC 2 (4.2%) Unclassified RCC 1 (2.0%) Chromophobe RCC 4 (8.4%)
Sweden	Tzortzakakis et al. (2017)	24	–	–	–	Oncocytomas 12 (39%) Oncocytoma & chromophobe RCC 3 (10%) Angiomyolipoma 1 (3%) Clear cell RCC 7 (23%) Papillary RCCs 3 (10%) Chromophobe RCC 2 (6%) Chromophobe and papillary RCC 1 (3%) Metanephric adenoma 1 (3%) Lymphoma 1 (3%)

HOCT = hybrid oncocytic/chromophobe tumor; IQR = interquartile range; RCC = renal cell carcinoma; SD = standard deviation.

## 4. Discussion

### 4.1. Summary of the main results

This systematic review was carried out to synthesize the existing evidence as regards the diagnostic accuracy of <sup>99m</sup>Tc-sestamibi SPECT/CT for renal oncocytomas compared to other renal neoplasms, with the standard test being pathologic diagnosis.

After vigorous searching of the scientific databases, 4 studies were identified,<sup>[2,3,8,9]</sup> which were related to the review question. The 4 studies included relatively small sample size. The technique of <sup>99m</sup>Tc-sestamibi SPECT/CT was almost the same across the 4 studies.

The results of all the included studies supported using <sup>99m</sup>Tc-sestamibi SPECT/CT for the differentiation between benign (HOCT, oncocytoma, and angiomyolipoma) and malignant (RCC) renal neoplasms.<sup>[2,3,8,9]</sup> Gorin et al.<sup>[8]</sup> reported high sensitivity and higher specificity for <sup>99m</sup>Tc-sestamibi SPECT/CT

diagnostic test, which suggests the potential use of this test for both ruling-out and confirming diagnoses. The results of Tzortzakakis et al.<sup>[9]</sup> showed higher sensitivity and lower specificity than those reported by Gorin et al.<sup>[8]</sup> This difference may be attributed to variations in the frequencies of histologic variants of renal neoplasms included in each study.

The results of Sheikhbahaei et al.<sup>[2]</sup> also demonstrated the benefit of adding <sup>99m</sup>Tc-sestamibi SPECT/CT to conventional radiography and how the confidence of readers in diagnosing renal neoplasms was markedly boosted. The area under the ROC curve was significantly increased by 25% from 0.60 with conventional radiography alone to 0.85 after adding <sup>99m</sup>Tc-sestamibi SPECT/CT.

It has been reported that the uptake of <sup>99m</sup>Tc-sestamibi differs widely across the various types of renal neoplasms.<sup>[3,4,8,9]</sup> Two mechanisms were hypothesized to explain for variability in the uptake of <sup>99m</sup>Tc-sestamibi. The first mechanism relates this

**Table 2**

**Characteristics of <sup>99m</sup>Tc-sestamibi SPECT/CT technique in the included studies.**

Study	SPECT/CT brand	Dose (MBq)	Timing of SPECT/CT postinjection (min)
Rowe et al. (2015)	Siemens Symbia16-slice SPECT/CT	925	75
Gorin et al. (2016)	Siemens Symbia16-slice SPECT/CT	925	75
Sheikhbahaei et al. (2017)	Siemens Symbia16-slice SPECT/CT	925	75
Tzortzakakis et al. (2017)	Siemens Symbia16-slice SPECT/CT	925 ± 25	60–90

MBq = megabecquerels; SPECT/CT = single-photon emission computed tomography/computed tomography.



**Table 3**  
<sup>99m</sup>Tc-sestamibi single-photon emission computed tomography/computed tomography in comparison with histopathology.

Study	True positive	False positive	True negative	False negative	Sensitivity	Specificity	Cut-off value
Rowe et al. (2015)	3/3	–	3/3	–	–	–	–
Gorin et al. (2016)	7/9	2/41	40/41	2/9	77.8% (95% CI=40.0%–97.2%)	95.1% (95% CI=83.5%–99.4%)	0.6
Sheikhbahaei et al. (2017)	7/9	2/39	37/39	2/9	77.8% (95% CI=40.0%–97.2%)	94.9% (95% CI=82.7%–99.4%)	–
Tzortzakakis et al. (2017)	11/12	5/19	14/19	1/12	91.7% (95% CI=61.5%–99.8%)	73.7% (95% CI=48.8%–90.9%)	–

CI = confidence interval.

variability to mitochondria, suggesting an attraction between positively charged <sup>99m</sup>Tc-sestamibi and negatively charged transmembrane potential of the mitochondria. As benign renal neoplasms contain a higher number of mitochondria compared to RCC,<sup>[10,11]</sup> the uptake of <sup>99m</sup>Tc-sestamibi is expected to be higher in benign neoplasms.

The second mechanism proposes that RCC cells possess multidrug resistance efflux pump which pumps out <sup>99m</sup>Tc-sestamibi, similar to the mechanism of resistance of RCC to chemotherapy through which RCC cells extrude chemotherapy out of cells. This efflux pump is absent in benign tumors, and thus, it has a higher affinity to <sup>99m</sup>Tc-sestamibi.<sup>[12–14]</sup>

False-positive results of <sup>99m</sup>Tc-sestamibi SPECT/CT were detected in 2 patients with chromophobe RCCs<sup>[8]</sup> and 1 patient with papillary RCC,<sup>[9]</sup> which were identified as benign lesions due to the elevated uptake of the radiotracer. However, chromophobe RCC is a subtype of RCC that has an indolent clinical course for which active surveillance is recommended if the tumor is small in size.<sup>[15]</sup> Chromophobe RCC was not reported to metastasize and thus may not require surgical intervention.<sup>[16–18]</sup> Therefore, the false positive identification of chromophobe RCC as benign does not affect the clinical practicality of the test, as management will not differ greatly by the test results. As for papillary RCC, Tzortzakakis et al.<sup>[9]</sup> reported that 1 out of 3 lesions showed slight uptake of sestamibi. This finding warrants the need for quantitative measurement of the relative uptake of the radiotracer as dependence on visual assessment only may yield false positive results, subjecting patients to delayed or inadequate treatment. The value of quantitative measurement of sestamibi uptake is also emphasized by the finding reported by

Rowe et al.<sup>[3]</sup> that uptake values varied widely even among imaged oncocytomas.

Angiomyolipoma was reported in 1 patient in 2 cohorts.<sup>[8,9]</sup> The tumor was sestamibi-negative in the study by Gorin et al.,<sup>[8]</sup> but sestamibi-positive in the study by Tzortzakakis et al.<sup>[9]</sup> Studies with larger sample size and various renal neoplasm subtypes are required to elucidate the radiotracer uptake by angiomyolipoma, which is a benign tumor.

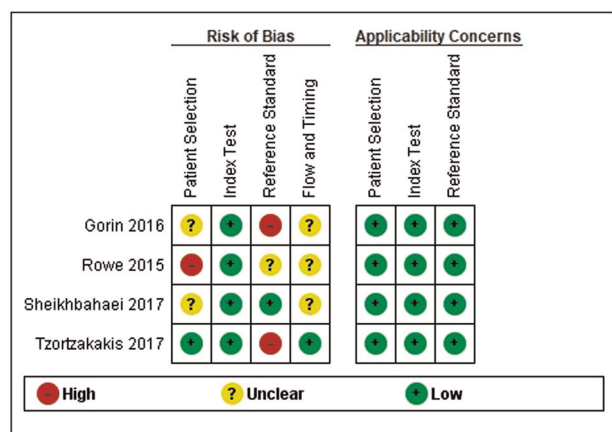
**4.2. Overall completeness, applicability, and of quality of the evidence**

The guidelines of the American Urological Association<sup>[19]</sup> recommend complete surgical excision for the treatment of solid clinical T1 renal masses. Optional treatments include thermal ablation and active surveillance, but these treatment options expose the patients to oncologic risks.<sup>[19]</sup> Accordingly, the current practice considers that all solid renal masses should be treated as potentially malignant,<sup>[20]</sup> while active surveillance could be applied only in small lesions (<1 cm) and if patients have limited life expectancy.<sup>[19,21]</sup>

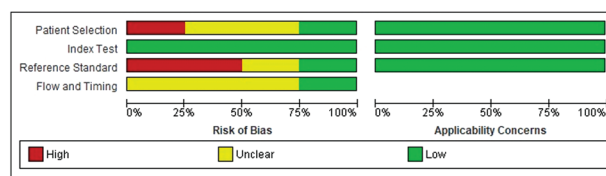
This approach may result in overtreatment and exposes patients with benign lesions to the risks of unnecessary surgery. Therefore, there is a need for the development of a test to identify benign lesions or those with indolent clinical course and to rule out malignant lesions with aggressive course.

Currently, the definitive reliable test to differentiate between benign and malignant lesions is surgical pathology. Unfortunately, the results of a meta-analysis indicated that 14% of renal biopsies in RCC are nondiagnostic.<sup>[22]</sup>

The results of the included studies in this systematic review are promising. The sensitivity and specificity of sestamibi uptake by benign renal lesions are high. However, the quality of evidence from these studies is downgraded by their small sample size and risk of selection bias. The limitations of individual studies were outlined under the assessment of the risk of bias section. Moreover, the lack of quantitative assessment of radiotracer uptake may result in false positive results as malignant lesions are wrongly diagnosed as benign, thus subjecting patients to undertreatment.



**Figure 2.** Risk of bias and applicability concerns summary for each included study.



**Figure 3.** Risk of bias and applicability concerns graph across included studies.

### 4.3. Implications for practice, policy, and future research

Imaging study with <sup>99m</sup>Tc-sestamibi SPECT/CT may provide a rapid, less invasive, promising, diagnostic test to identify patients with benign renal lesions, to avoid the risks of unnecessary major surgery. However, more studies with large sample sizes are required to confirm the reliability and accuracy of this imaging modality before incorporating it into clinical practice. Future studies should include patients with various histologic subtypes of renal lesions. In addition, quantitative assessment of <sup>99m</sup>Tc-sestamibi uptake by each histologic variant is required.

### Acknowledgments

None.

### Statement of ethics

Not applicable.

### Conflict of interest statement

The authors declare no conflicts of interest.

### Funding source

None.

### Author contributions

All authors contributed equally in this study.

### References

- [1] Wong MCS, Goggins WB, Yip BHK, et al. Incidence and mortality of kidney cancer: Temporal patterns and global trends in 39 countries. *Sci Rep* 2017;7(1):15698.
- [2] Sheikhabaehi S, Jones CS, Porter KK, et al. Defining the added value of <sup>99m</sup>Tc-MIBI SPECT/CT to conventional cross-sectional imaging in the characterization of enhancing solid renal masses. *Clin Nucl Med* 2017;42(4):e188–e193.
- [3] Rowe SP, Gorin MA, Gordetsky J, et al. Initial experience using <sup>99m</sup>Tc-MIBI SPECT/CT for the differentiation of oncocytoma from renal cell carcinoma. *Clin Nucl Med* 2015;40:309–313.
- [4] Gormley TS, Van Every MJ, Moreno AJ. Renal oncocytoma: Preoperative diagnosis using technetium <sup>99m</sup> sestamibi imaging. *Urology* 1996;48(1):33–39.
- [5] Liberati A, Altman DG, Tetzlaff J, et al. The PRISMA statement for reporting systematic reviews and meta-analyses of studies that evaluate health care interventions: Explanation and elaboration. *PLoS Med* 2009;6(7):e1000100.
- [6] Vassar M, Atakpo P, Kash MJ. Manual search approaches used by systematic reviewers in dermatology. *J Med Libr Assoc* 2016;104(4):302–304.

- [7] Whiting PF, Rutjes AW, Westwood ME, et al. QUADAS-2: A revised tool for the quality assessment of diagnostic accuracy studies. *Ann Intern Med* 2011;155(8):529–536.
- [8] Gorin MA, Rowe SP, Baras AS, et al. Prospective evaluation of (<sup>99m</sup>Tc-sestamibi SPECT/CT for the diagnosis of renal oncocytomas and hybrid oncocytic/chromophobe tumors. *Eur Urol* 2016;69(3):413–416.
- [9] Tzortzakakis A, Gustafsson O, Karlsson M, Ekström-Ehn L, Ghaffarpour R, Axelsson R. Visual evaluation and differentiation of renal oncocytomas from renal cell carcinomas by means of (<sup>99m</sup>Tc-sestamibi SPECT/CT. *EJNMMI Res* 2017;7(1):29.
- [10] Johnson NB, Johnson MM, Selig MK, Nielsen GP. Use of electron microscopy in core biopsy diagnosis of oncocytic renal tumors. *Ultrastruct Pathol* 2010;34(4):189–194.
- [11] Krishnan B, Truong LD. Renal epithelial neoplasms: The diagnostic implications of electron microscopic study in 55 cases. *Hum Pathol* 2002;33(1):68–79.
- [12] Rochlitz CF, Lobeck H, Peter S, et al. Multiple drug resistance gene expression in human renal cell cancer is associated with the histologic subtype. *Cancer* 1992;69(12):2993–2998.
- [13] Tobe SW, Noble-Topham SE, Andrulis IL, Hartwick RW, Skorecki KL, Warner E. Expression of the multiple drug resistance gene in human renal cell carcinoma depends on tumor histology, grade, and stage. *Clin Cancer Res* 1995;1(12):1611–1615.
- [14] Hendrikse NH, Franssen EJ, van der Graaf WT, et al. <sup>99m</sup>Tc-sestamibi is a substrate for P-glycoprotein and the multidrug resistance-associated protein. *Br J Cancer* 1998;77(3):353–358.
- [15] Halverson SJ, Kunju LP, Bhalla R, et al. Accuracy of determining small renal mass management with risk stratified biopsies: Confirmation by final pathology. *J Urol* 2013;189(2):441–446.
- [16] Pierorazio PM, Johnson MH, Ball MW, et al. Five-year analysis of a multi-institutional prospective clinical trial of delayed intervention and surveillance for small renal masses: The DISSRM registry. *Eur Urol* 2015;68(3):408–415.
- [17] Smaldone MC, Kutikov A, Egleston BL, et al. Small renal masses progressing to metastases under active surveillance: A systematic review and pooled analysis. *Cancer* 2012;118(4):997–1006.
- [18] Petersson F, Gatalica Z, Grossmann P, et al. Sporadic hybrid oncocytic/chromophobe tumor of the kidney: A clinicopathologic, histomorphologic, immunohistochemical, ultrastructural, and molecular cytogenetic study of 14 cases. *Virchows Arch* 2010;456(4):355–365.
- [19] Campbell SC, Novick AC, Beldegrun A, et al. Guideline for management of the clinical T1 renal mass. *J Urol* 2009;182(4):1271–1279.
- [20] Silverman SG, Israel GM, Herts BR, Richie JP. Management of the incidental renal mass. *Radiology* 2008;249(1):16–31.
- [21] Smaldone MC, Corcoran AT, Uzzo RG. Active surveillance of small renal masses. *Nat Rev Urol* 2013;10:266–274.
- [22] Patel HD, Johnson MH, Pierorazio PM, et al. Diagnostic accuracy and risks of biopsy in the diagnosis of a renal mass suspicious for localized renal cell carcinoma: Systematic review of the literature. *J Urol* 2016;195(5):1340–1347.

---

**How to cite this article:** Deb AA, Agag A, Naushad N, Krishnamoorthy R, Serag H. The value of sestamibi single-photon emission computed tomography/computed tomography in differentiating and staging renal cell carcinomas: A systematic review. *Curr Urol* 2022;16(1):32–37. doi: 10.1097/CU9.000000000000089