

Spontaneous Hepaticoduodenal and Choledochoduodenal Fistula Mimicking Duodenal Ulcer Perforation, a Very Rare Complication of Transarterial Chemoembolization

Varayu Prachayakul^a Pitulak Aswakul^b

^aSiriraj Gastrointestinal Endoscopy Center, Division of Gastroenterology, Department of Internal Medicine, Siriraj Hospital, Faculty of Medicine, Mahidol University, and ^bLiver and Digestive Institute, Samitivej Sukhumvit Hospital, Bangkok, Thailand

Key Words

Hepaticoduodenal fistula · Choledochoduodenal fistula · Fistula · Transarterial chemoembolization · Complications

Abstract

Spontaneous bilo-enteric fistula is a rare complication following surgery or some therapeutic interventions such as transarterial chemoembolization (TACE). The present case was a young man, a known case of chronic hepatitis B with multiple recurrent hepatocellular carcinoma, who presented with clinical sepsis and jaundice. Computed tomography showed dilated proximal left intrahepatic ducts which suspected anastomotic stricture. He underwent endoscopic retrograde cholangiopancreatography, but the endoscopic view showed a deep ulcer covered by yellowish debris tissue. After re-evaluation it was found to be hepaticoduodenotomy and choledochoduodenostomy tracts. In the present case the fistula was suspected to be related to a previous TACE procedure.

© 2015 S. Karger AG, Basel

Introduction

Hepatocellular carcinoma (HCC) is a leading liver-related cancer worldwide accounting for more than 600,000 cases every year; there is variation of the incidence of HCC with a

higher incidence in Eastern Asia and sub-Saharan Africa. There are many known risk factors associated with the development of HCC, such as chronic hepatitis B and C infection, cirrhosis, nonalcoholic steatohepatitis and hereditary hemochromatosis [1]. The curative treatments for HCC are surgery such as hepatectomy or liver transplantation and local ablative treatments such as radiofrequency ablation or percutaneous ethanol injection. However, unfortunately only 20–30% of patients are suitable for this treatment. In case of unresectable HCC, the alternative treatments are transarterial chemoembolization (TACE) with or without systemic chemotherapy, whereas patients with terminal-stage disease receive only supportive treatment [2]. TACE is a standard treatment for patient with unresectable HCC without systemic metastases and has been reported to prolong survival and to control the symptoms of HCC. TACE is performed by injection of anti-cancer drugs such as doxorubicin, epirubicin, cisplatin or miriplatin and iodinated oil (Lipiodol Ultra-Fluide, Laboratoires Guerber, Aulnay-sous-Bois, France) into the hepatic artery followed by the administration of the embolic agents. The most common adverse events after TACE are nausea and vomiting, post-embolization syndrome, bleeding or transient hepatic impairment [3, 4]. The rare complications reported are duodenal perforation or hepatic abscess [5], post-embolization hepatic rupture [6], necrotizing pancreatitis [7], spinal cord injury [8], cerebral embolism [9, 10], tumor lysis syndrome [11] or spontaneous bilo-enteric fistula [12, 13].

Here, we reported a rare case of spontaneous hepaticoduodenal and choledochoduodenal fistula following TACE. Written informed consent was obtained from the patient for publication of this case report and any accompanying images. A copy of the written consent form is available for review from the editor of this journal.

Case Presentation

The patient was a 34-year-old gentleman, a known case of chronic hepatitis B with multifocal HCC who underwent right lobe hepatectomy with cholecystectomy 4 years ago. He had recurrent HCC at segment III and caudate lobe, thus he underwent three TACE procedures followed by wide caudate lobe resection couple years before. In this episode he presented with jaundice, high-grade fever and severe abdominal pain for 3 days. His blood works showed leukocytosis with neutrophilia. Liver chemistry showed hyperbilirubinemia which total/direct bilirubin 12.9/11.2 mg/dl (reference 0.2–1.0 mg/dl), aspartate transaminase and alanine transaminase were 75 and 53 U/l (reference 0–38 U/l), and alkaline phosphatase was 209 U/l (reference 39–117 U/l). Computed tomography showed a 6-mm common bile duct with mild left intrahepatic duct dilatation. Proximal left intrahepatic duct stricture was suspected; therefore, he was scheduled for endoscopic retrograde cholangiopancreatography and biliary drainage.

The patient was positioned in the left lateral decubitus position and sedated using intravenous propofol under full anesthetic monitoring. After duodenal intubation with a duodenoscope, a large duodenal ulcer was seen in the duodenal bulb, so the scope was changed to be standard gastroscope. The endoscopic view showed a 1.5–2.0-cm duodenal ulcer covered by yellowish debris tissue. After carefully checking the ulcer, two openings were seen at the ulcer base (fig. 1) with whitish epithelial lining of the larger one, therefore a 0.035-inch guidewire was passed through these two nonsurgical openings (fig. 2) followed by contrast injection. The authors found that one of the openings was a choledochoduodenal fistula and the other one a hepaticoduodenal fistula (fig. 3). After revision of his surgical procedures, no surgical bypass was performed at all in this particular patient. The authors hypothesized that these fistulas were spontaneously created and might be the consequence of TACE pro-

cedures which had caused ischemia and necrosis of the liver. The obstructive jaundice was due to the obstruction of the openings by food particles and a strictured bile duct at segments II and III, so two plastic stents (10 Fr, 7 cm) were inserted with good bile flow (fig. 4). The patient was followed up a month later. He was doing well and his liver chemistries were normal.

Discussion

Spontaneous bilo-enteric fistula is a very rare complications following some treatment interventions, the most common cause being surgery. There are only few case reports regarding this condition as an adverse events from severe inflammatory process such as acute pancreatitis or TACE [12–15]. The principle of TACE is tumor ischemia that occurs from blocking of the arterial blood supply of the liver tumor combined with chemotherapy administered directly into the tumor. However, the normal liver tissue and adjacent organs can be affected by unintentional proximal artery embolization that leads to uncommon complications such as duodenal perforation or acute pancreatitis. In the present case, the fistulas might not only have been caused by repetitive TACE procedures, but also by altered anatomy from repetitive liver resections. In general, the definitive treatment of fistulas is surgical correction, but in this particular case, this might not have been possible because of inflammation and fibrosis of the surrounding tissue.

Leaving the fistula tracts opened might be an appropriate treatment strategy. Nevertheless, this patient still developed acute cholangitis that was complicated by obstruction of the fistula openings by food particles and proximal segmental bile duct stricture. Therefore, the authors planned for long-term biliary stenting in this patient. Finally, highly selective TACE is essential to prevent ischemia-related complications.

Author Contributions

V. Prachayakul developed the concept. V. Prachayakul and P. Aswakul wrote and revised the paper for important intellectual content. Both authors read and approved the final manuscript.

Disclosure Statement

The authors have no conflicts of interest or financial ties to disclose.

References

- 1 Goh LY, Leow AH, Goh KL: Observations on the epidemiology of gastrointestinal and liver cancers in the Asia-Pacific region. *J Dig Dis* 2014;15:463–468.
- 2 Fong ZV, Tanabe KK: The clinical management of hepatocellular carcinoma in the United States, Europe, and Asia: a comprehensive and evidence-based comparison and review. *Cancer* 2014;120:2824–2838.
- 3 Dai QS, Gu HL, Ye S, Zhang YJ, Lin XJ, Lau WY, Peng ZW, Chen MS: Transarterial chemoembolization vs. conservative treatment for unresectable infiltrating hepatocellular carcinoma: a retrospective comparative study. *Mol Clin Oncol* 2014;2:1047–1054.

- 4 Cohen MJ, Bloom AI, Barak O, Klimov A, Nesher T, Shouval D, Levi I, Shibolet O: Trans-arterial chemo-embolization is safe and effective for very elderly patients with hepatocellular carcinoma. *World J Gastroenterol* 2013;19:2521–2528.
- 5 Xia J, Ren Z, Ye S, Sharma D, Lin Z, Gan Y, Chen Y, Ge N, Ma Z, Wu Z, Fan J, Qin L, Zhou X, Tang Z, Yang B: Study of severe and rare complications of transarterial chemoembolization (TACE) for liver cancer. *Eur J Radiol* 2006;59:407–412.
- 6 Jia Z, Tian F, Jiang G: Ruptured hepatic carcinoma after transcatheter arterial chemoembolization. *Curr Ther Res Clin Exp* 2013;74:41–43.
- 7 Bae SI, Yeon JE, Lee JM, Kim JH, Lee HJ, Lee SJ, Suh SJ, Yoon EL, Kim HR, Byun KS, Seo TS: A case of necrotizing pancreatitis subsequent to transcatheter arterial chemoembolization in a patient with hepatocellular carcinoma. *Clin Mol Hepatol* 2012;18:321–325.
- 8 Jia ZZ, Tian F, Jiang GM: Cerebral lipiodol embolism after transarterial chemoembolization for hepatic carcinoma: a case report. *World J Gastroenterol* 2012;18:4069–4070.
- 9 Kumar R, Hassan SM, Faiq SM, Abbas Z, Luck NH: Thalamic and midbrain infarct during transarterial chemoembolization of hepatocellular carcinoma. *J Pak Med Assoc* 2012;62:295–297.
- 10 Tufail K, Araya V, Azhar A, Hertzog D, Khanmoradi K, Ortiz J: Paraparesis caused by transarterial chemoembolization: a case report. *World J Hepatol* 2010;2:289–291.
- 11 Wang K, Chen Z: Acute tumor lysis syndrome after transarterial chemoembolization for well-differentiated hepatocellular carcinoma with neuroendocrine features. *Onkologie* 2010;33:532–535.
- 12 Wang CY, Leung SW, Wang JH, Yu PC, Wang CC: Delayed spontaneous hepatogastric fistula formation following transcatheter arterial embolisation and radiotherapy for hepatocellular carcinoma. *Br J Radiol* 2009;82:e105–e107.
- 13 Park YH, Kang SH, Kim SU, Kim do Y, Park JY, Ahn SH, Han KH, Chon CY: A case of hepaticoduodenal fistula development after transarterial chemoembolization in patient with hepatocellular carcinoma. *Korean J Gastroenterol* 2011;58:149–152.
- 14 Brandes G, Schennetten M: Spontaneous choledochoduodenostomy in gallbladder carcinoma with pancreatitis. *Arztl Wochensh* 1954;9:1173–1175.
- 15 Pua U, Merkle EM: Case report. Spontaneous cholecystocolic fistula and locoregional liver tumour ablation: a cautionary tale. *Br J Radiol* 2011;84:e243–e245.

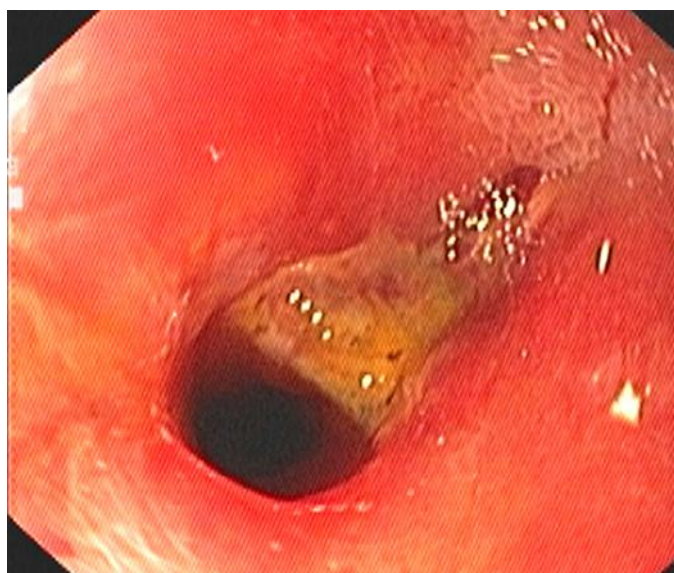

Fig. 1. A 2.0-cm duodenal ulcer covered by yellowish debris tissue with two openings at the ulcer base.

Prachyakul and Aswakul: Spontaneous Hepaticoduodenal and Choledochoduodenal
Fistula Mimicking Duodenal Ulcer Perforation, a Very Rare Complication of TACE

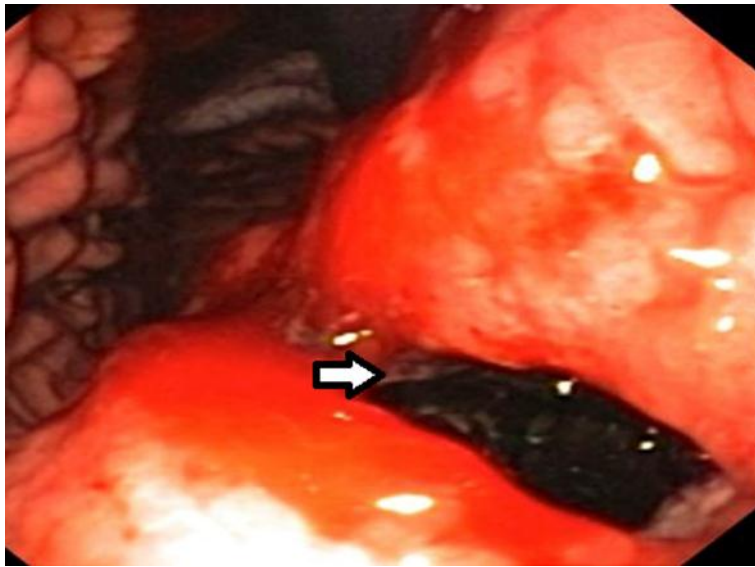


Fig. 2. The guidewire was passed through one of the two openings.

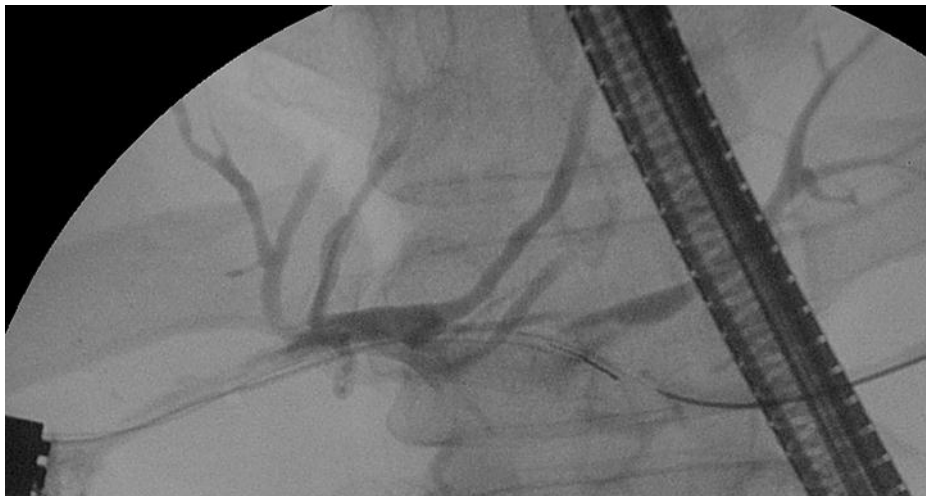


Fig. 3. One of the openings was a hepaticoduodenal fistula.

Prachyakul and Aswakul: Spontaneous Hepaticoduodenal and Choledochoduodenal
Fistula Mimicking Duodenal Ulcer Perforation, a Very Rare Complication of TACE

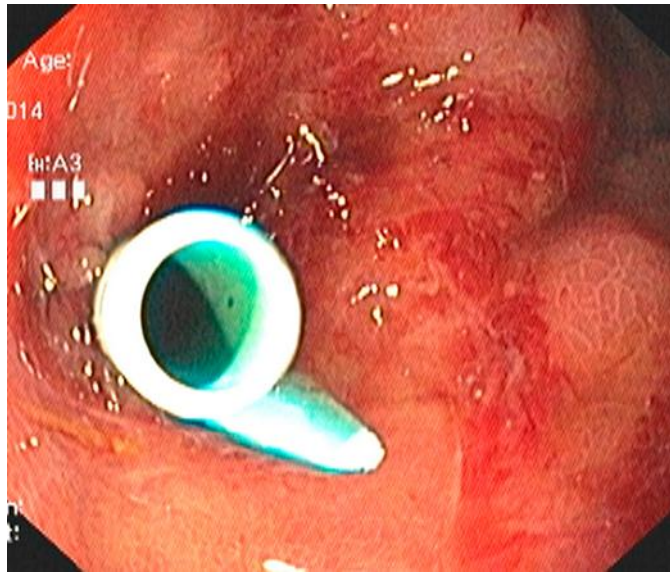


Fig. 4. A plastic stent (10 Fr, 7 cm) was inserted into the left intrahepatic duct.