

Temporal Bone Measurements; A Comparison Between Rendered Spiral CT and Surgery

Jahanbakhsh Hashemi¹; Mohsen Rajati^{2,*}; Lida Rezayani¹; Aria Bahadori¹

¹Department of Radiology, Faculty of Medicine, Emam Reza Hospital, Mashhad University of Medical Sciences, Mashhad, Iran

²Department of Otorhinolaryngology, Faculty of Medicine, Ghaem Hospital, Mashhad University of Medical Sciences, Mashhad, Iran

*Corresponding author: Mohsen Rajati, Department of Otorhinolaryngology, Sinus and Surgical Endoscopic Research Center, Faculty of Medicine, Ghaem Hospital, Mashhad University of Medical Sciences, Mashhad, Iran. Tel: +98-9153113520, Fax: +98-5118413492, E-mail: Rajatim@mums.ac.ir

Received: December 2, 2012; Revised: October 13, 2013; Accepted: November 18, 2013

Background: Accurate radiological assessment of the anatomical features of the temporal bone is crucial to prevent damage to vital elements in this area during surgery. Knowing the approximate location of specific temporal bone related landmarks in advance is very important for planning surgery.

Objectives: This study compared findings from computed tomography images with those observed directly during ear surgery.

Patients and Methods: Patients with various pathologies of the ear who needed surgery were referred to an imaging center for a spiral CT scan of the temporal bone. The following parameters were measured by a radiologist and also later recorded by the surgeon during surgery: 1) The distance between the postero-superior border of the outer ear canal and the sigmoid sinus; 2) The distance between the dome of the lateral semicircular canal and the mastoid cortex; and 3) The distance between the external surface of the incus and the mastoid cortex.

Results: Twenty cases were included. In the three measurements performed in this study, only the first parameter (distance between the canal and the sigmoid sinus) was significantly different between the direct measurement made during surgery and that obtained from CT scans. There was no significant difference in the measurements of the distance between the dome of the lateral semicircular canal and the bone cortex, and the distance between the external surface of the incus and the surface of the bone cortex.

Conclusions: Our study shows in terms of figures that measurements of features of the temporal bone made from spiral CT scan images and those directly obtained during surgery are similar to an adequate extent.

Keywords: Temporal Bone; Spiral Computed Tomography; Otologic Surgical Procedures

1. Background

The temporal bone is a complex anatomical space that houses the middle ear and its ossicles, as well as the inner ear, which includes the vestibule, cochlea, and the semi-circular canals. It also contains the facial and vestibulo-cochlear nerves and several blood vessels and muscles. Diagnosis and surgical intervention in this area require sufficient clinical information and a thorough knowledge of the anatomy of the temporal bone (1-3). High-resolution CT scanning is the best method for examining the anatomy and disorders of the skeletal system. The introduction of multi-slice helical (spiral) CT scanning brought about a breakthrough in CT technology. This technique yields sub-millimeter spatial resolution in the x, y, and z axes and provides more detailed anatomical features in the images (4-6). Multi-planar CT scans produce isotropic voxels, which can be rendered in every sectional plane. This technique has made it possible to accurately observe the anatomical structures of the middle

and inner ears. In addition, a high contrast between the bony structures and air chambers can be obtained using the surface-rendering technique in a virtual endoscopy of the middle ear. The 3D volume-rendered CT images can provide a better understanding of the complex anatomy of the temporal bone. The images can be rotated in space and viewed from every plane and hence, enable the evaluation of morphologic views of certain structures, such as the ossicles of the middle ear and the components of the inner ear. In view of the intricate structures involved, proper CT images are invaluable in temporal bone surgeries (7, 8). The ultimate goal of these technological breakthroughs is to offer useful information to the clinicians in order to make optimal decisions. During ear surgery, the otologist comes up with several vital structures imbedded in the bone that should be meticulously exposed by microdrills. Mastoid cortex is the first part to be drilled out so that the antrum, sigmoid sinus, incus

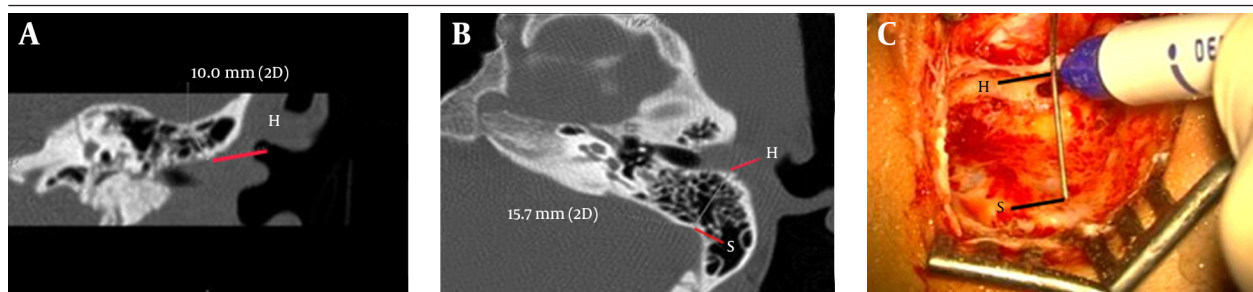


Figure 1. Measurement 1; the distance between the postero-superior border of the outer ear canal and the sigmoid sinus. A, Coronal view; B, Axial view; C, Surgical view; H: Spine of Henle; S: Anterior surface of the sigmoid sinus

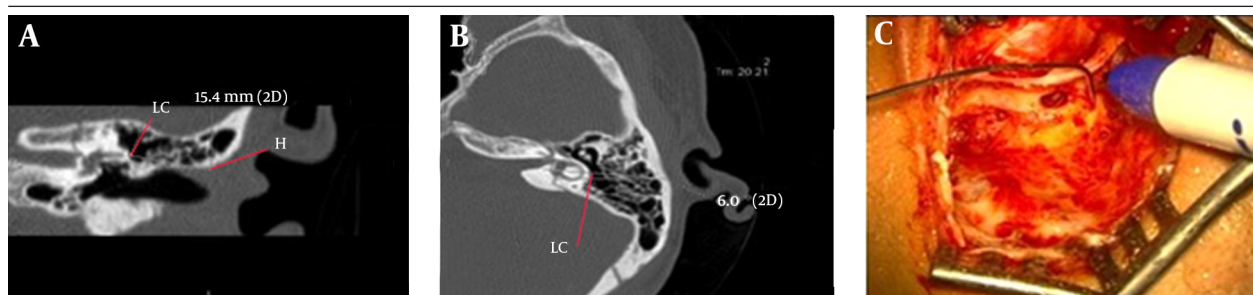


Figure 2. Measurement 2; the distance between the dome of the lateral semicircular canal and the bone cortex. A, Coronal view; B, Axial view; C, Surgical view; H: Spine of Henle; LC: Dome of the lateral semicircular canal.

and lateral semicircular canal are identified (9). Knowing the approximate location of these landmarks in advance is very helpful in planning surgery. CT provides useful information about the overall anatomy of the temporal bone and also the extent of the pathologies.

2. Objectives

In this paper, the accuracy of CT findings in terms of measurements of distances between certain temporal bone structures with those obtained during surgery is compared. The aim is to understand how reliably CT image findings may help otologists in planning temporal bone surgery. Previous studies have shown a good correlation between CT related measurements in patients and those obtained from published cadaver data and direct observation during surgery (10, 11). In this paper, the measurements in the same cases are compared so that the accuracy of CT is determined.

3. Patients and Methods

The study included patients with various ear pathologies for whom surgery (at least mastoidectomy) had been indicated by an otologist (including chronic infections of the ear with or without cholesteatoma, and fractures of the temporal bone). The patients were referred to an imaging center for a spiral CT scan. Imaging was performed using a GE multi-detector spiral CT scan (General Electric, USA) in axial sections (KV = 120, mAs = 180, matrix = 512 × 512, field-of-view = 70 × 70 mm, reconstruction interval = 0.5 mm, slice thickness = 1 mm, window width = 4000 HU, collimation = 1 mm with two detectors). Rendering of

the images was performed using the eFilm Workstation, which enabled multi-planar evaluation. The measurements included in the study were as follows:

Measurement 1: The distance between the postero-superior border of the bony external ear canal and the sigmoid sinus (from the anterior limit of the sigmoid sinus to the canal, just superior to the spine of Henle). The exact location of the spine of Henle was marked as the postero-superior border of the outer ear canal in coronal sections, and labeled the H spot. Then, using eFilm Workstation software, H was shown in axial sections and the shortest distance between H and the anterior surface of the sigmoid sinus (S) was measured in the axial sections and recorded (Figure 1).

Measurement 2: The distance between the dome of the lateral semicircular canal and the bone cortex. The exact location of the dome of the lateral semicircular canal was marked in axial sections, and labeled the LC spot. The exact location of the spine of Henle (as the landmark of the outer surface of the cortex) was marked in coronal sections and labeled the H spot. Then, using eFilm Workstation, and rotating around the H spot, semi-coronal sections were obtained and the distances measured and recorded (Figure 2)

Measurement 3: The distance between the outer surface of the incus short-process and the mastoid cortex. As with the previous two measurements, the exact location of the spine of Henle was labeled in coronal sections as the H spot. Then the exact location of the incus was identified in axial sections and its outer surface was labeled the I spot. Using eFilm Workstation and rotating around the I spot, semi-axial sections were rendered, and in whichever section both spots were present, the distance between them was measured and recorded (Figure 3).

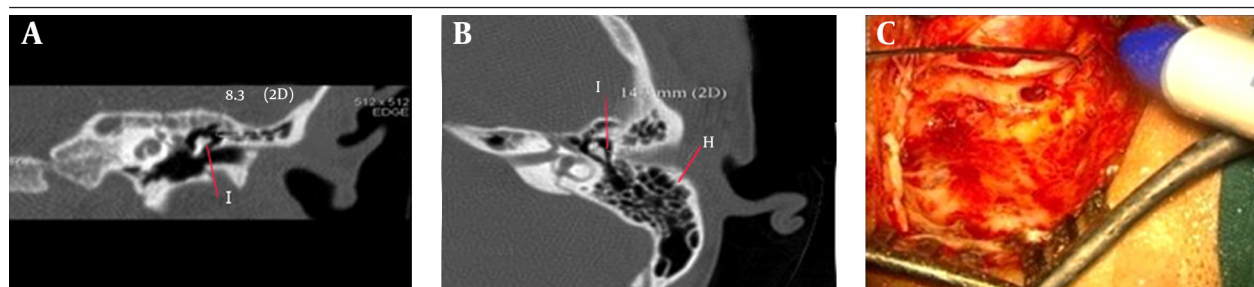


Figure 3. Measurement 3; The distance between the external surface of the incus and the mastoid cortex. A, Coronal view; B, Axial view; C, Surgical view; H: Spine of Henle; I: Outer surface of incus short process

Table 1. Indications for Surgery, Number of Patients and Types of Surgery

Indication for Surgery	Number of Patients	Type of Surgery
Chronic Otitis Media	12	Mastoidectomy + Tympanoplasty
Traumatic Facial Paralysis	5	Mastoidectomy + Facial Nerve Decompression
Total	17	

Table 2. Comparison Between the Measurements Performed by CT Scan and Directly Through Surgery^a

Type of Measurement	Measurement Results		
	Surgery	CT Scan	P Value
The distance between the postero-superior border of the outer ear canal and the sigmoid sinus	15.71 ± 2.39	14.56 ± 2.64	< 0.05
The distance between the dome of the lateral semicircular canal and the bone cortex	15.6 ± 1.5	15.25 ± 1.48	> 0.05
The distance between the external surface of the incus and the mastoid cortex	15.23 ± 1.74	15.08 ± 1.42	> 0.05

^a Data are presented as Mean ± SD.

The first step in the surgery was to drill out the mastoid air cells. Upon removal of the sufficient cortical bone, the mastoid antrum appeared and the lateral semicircular canal and incus came into sight. The direct measurements were then taken by a single surgeon (the second author) using a ruler, with the surgeon unaware of the measurements by the radiologist. All the measurements were done by a single surgeon and also a single radiologist to minimize the inter-observer variability. These parameters are the basic items that should be known to the otologist doing the mastoid surgeries and are implemented in every case. There are several other landmarks, such as the fallopian canal distances from the cortex or sigmoid sinus, but the surgeons infrequently get involved with them in the routine mastoid surgeries. All participants signed written informed consent. The results are presented as mean ± standard deviation and the differences between the pairs of measurements were analyzed using Student's paired t-test. A p value of less than 0.05 was considered to be significant. In addition, Bland-Altman plot method was used to assess agreement between the two methods of clinical measurement. The intraclass correlation coefficient (ICC) was used for quantification of intraobserver reliability. ICC values close to 1 (ICC more than 0.75) indicate satisfactory reliability.

4. Results

In this study, 17 temporal bones were examined. These 17 patients included 12 (70%) chronic otitis media and

five traumatic facial paralyses (Table 1). The youngest patient was 16 years old, and the oldest 69, with a mean age of 28 years. Of those patients, 12 (70%) were male and five (30%) were female. Using a two-sided paired t-test and considering a power equal to 100% and a significance level of 0.05 to detect a difference of 0.854 yielded a sample size of 17. For measurement 1, the mean distance between the postero-superior border of the external ear canal and the sigmoid sinus measured during surgery was 15.71 ± 2.31 mm, while it was 14.56 ± 2.64 mm when measured using CT imaging. These two measurements were significantly different ($P < 0.05$) (Table 2). For measurement 2, the distance between the dome of the lateral semicircular canal and the surface of the bone cortex, the mean figure obtained during surgery was 15.6 ± 1.5 mm, which was not significantly different from that obtained through CT imaging (15.25 ± 1.48 mm). The mean distances measured through direct observation and CT scanning for measurement 3, the distance between the incus and the cortex, were 15.23 ± 1.74 mm and 15.08 ± 1.42 mm, respectively, which were also not significantly different. Bland-Altman plots also showed that the mean of the differences in measurement 1-3 were 1.10, 0.30, and 0.47, respectively (Figure 4). It is close to zero for measurements 2 and 3, so the two clinical methods are in agreement. The intraclass correlation coefficient (ICC) for measurements 1, 2 and 3 were 0.923, 0.853 and 0.866, respectively, which indicates satisfactory reliability.

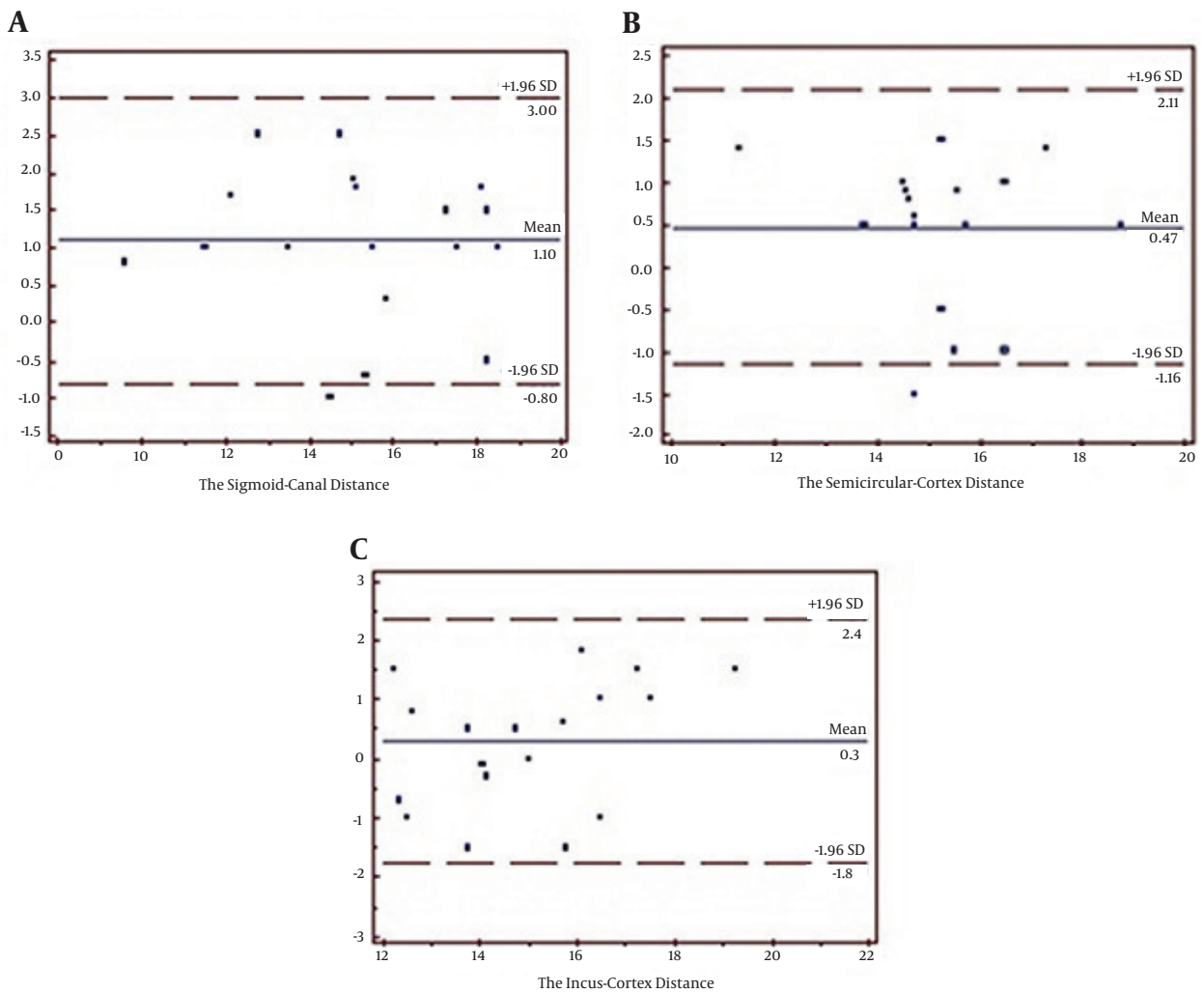


Figure 4. Bland-Altman plots for the three measurements. A, The distance between the ear canal and the sigmoid sinus; B, The distance between the lateral semicircular canal and cortex; C, The distance between the incus and cortex.

5. Discussion

Since the early 1980s, CT scanning has assumed an important role in the imaging of the temporal bone. Conventionally, low resolution CT scanning in axial and coronal sections was employed. With the advent of spiral CT scanning, minute structures, which had not previously been accurately visualized, could be clearly examined. Now the surgeons have a better understanding of the related anatomy and can assess various pathological conditions such as congenital anomalies, inflammatory, neoplastic, and traumatic diseases of the temporal bone. Pre-operative knowledge of the anatomical relationships of structures with fixed landmarks as the spine of Henle and the semicircular canal can contribute to a safe operation (4, 8, 12-15). In this paper, the basic landmarks of mastoidectomy (spine of Henle, sigmoid sinus, lateral semicircular canal and incus) were studied from an imaging aspect. The necessity of using multi-detector spiral CT scanning

and multi-planar rendering is supported by several studies showing that the technique produces higher quality images than conventional axial and coronal scans. For example, a study by Alexander et al. compared conventional axial and coronal sections against axial helical CT images in 19 patients, which were also rendered in coronal sections. The detail of the anatomical structures was observed by three independent observers who were unaware of the imaging method. In most cases, the helical CT images were rated higher (1). In another study by Jager et al. the findings of single-detector spiral CT and those of multi-detector spiral CT were compared, and it was concluded that the multi-detector spiral CT images, including the renderings, provided better images of the temporal bone anatomy (4). Jun et al. evaluated the usefulness of multi-planar rendering of images in determining the anatomy and the topographic relationships between important structures. In their study, spiral CT scanning was used to image 40 ears affected by different diseases,

and the results showed that the rendered images provided accurate anatomical details and helped the surgeon significantly in understanding the spatial relationships between the temporal bone structures (5). The results of our study are similar to those observed by Tomura et al. (2007), in a study that compared different multi-slice CT imaging methods in 80 patients in order to determine the best method for examining the middle ear in various diseases. The values from the original CT images and the 2D and 3D renderings of the components of the tympanic chamber were compared with those of the surgical findings. The results indicated that multi-planar renderings were more useful in the evaluation of skull-base traumas, skull-base tumors, and chronic inflammation of the middle ear (16). In another study by Zhen et al. (2007), images rendered from millimeter and sub-millimeter scale scans were shown to be as good as, and sometimes even better than direct observation and photography for gaining an understanding of the anatomy of the temporal bone (15). Rajati et al. reported the sensitivity and specificity of the temporal bone CT in detecting the fine fracture lines as 77.5 and 77.7 %, respectively in cases of traumatic facial paralysis (17). Mahmutoglu et al. studied the CT of 71 patients and reported the reliability of the scans in diagnosing cholesteatoma and its extension and possible accompanying complications (18). In a study by Rodt et al. (2006), spiral CT scanning was performed on 20 normal individuals, six temporal bones from cadavers, and 213 patients with middle-ear complaints, and different views of the middle ear and the ossicles were examined. On comparing the virtual views rendered from images and real views from the dissected bones, the image quality was evaluated and it was concluded that the information obtained from rendered spiral CT scan images helped in the radiological diagnosis and the selection of the surgical approach in complicated diseases of the middle ear (8). The findings revealed that there is a wide variety of anatomical differences in the dimensions of the temporal bone, and that it would be useful to make preoperative plans/maps in order to render the images in the desired sections. The protocol employed in this study was based on recommendations from reference books and can easily be used. During ear surgeries when mastoid drilling is indicated, the surgeon exposes the mastoid cortex and begins drilling in the area between the posterior ear canal and sigmoid sinus; the drilling goes on to expose the sigmoid sinus, antrum, lateral semicircular canal and the incus. These structures are important landmarks of every mastoid surgery and the surgeon must be aware of their anatomic correlation. In the three measurements performed in this study, the only significant difference between the figures obtained directly during surgery and those obtained from the CT scan images was noted in the measurement of the distance between the postero-superior border of the outer ear canal and the sigmoid sinus. This can be justified by the fact that during surgery, exposure of the sigmoid sinus is suboptimal and there is no need, and maybe even minor risk, in totally

uncovering the sinus and often a thin layer of bone is left over the sinus. In the other two cases, i.e. the distance between the semicircular canal from the cortex and the distance between the incus from the cortex, no significant differences were observed. Moreover, the semicircular canal and the incus are fairly distinct structures and more consistent in regard to the exact point used for measurement. This variability has also been reported by Vlastarakos et al. who compared CT scan and surgical findings in 50 patients, and found that the reliability of the preoperative CT scans was different in various areas (19). To reduce the inter-observer variability, a single surgeon has done all the measurements; however, the sigmoid plate measurement point in the CT scan and surgical field probably were not precisely the same. This study confirms the findings of previous studies on the high level of accuracy of spiral CT scans for the evaluation of the temporal bone, and also shows that the measurements obtained from spiral CT images are comparable with those obtained from direct observation during surgery. This finding is invaluable to surgeons, and in certain cases will give important information that can be used to ensure a more safe surgery.

Authors' Contributions

Jahanbakhsh Hashemi: director of the project, performing and analyzing CT scans; Mohsen Rajati: otologic surgeon, performing surgeries and intraoperative measurements; Lida Rezayani: data collection and analysis; Aria Bahadori: assistance with the analysis and writing the final article.

Funding/Support

This study was approved and supported in the Faculty of Medicine by the Deputy of Research, Mashhad University of Medical Sciences, Iran. The funding organizations are public institutions and had no role in the design and conduct of the study, collection, management, and analysis of the data, or preparation, review, and approval of the manuscript.

References

- Alexander AE, Jr, Caldemeyer KS, Rigby P. Clinical and surgical application of reformatted high-resolution CT of the temporal bone. *Neuroimaging Clin N Am.* 1998;**8**(3):631-50.
- Chan LL, Manolidis S, Taber KH, Hayman LA. Surgical anatomy of the temporal bone: an atlas. *Neuroradiology.* 2001;**43**(10):797-808.
- Fatterpekar GM, Mukherji SK, Lin Y, Alley JG, Stone JA, Castillo M. Normal canals at the fundus of the internal auditory canal: CT evaluation. *J Comput Assist Tomogr.* 1999;**23**(5):776-80.
- Jager L, Bonell H, Liebl M, Srivastav S, Arbusow V, Hempel M, et al. CT of the normal temporal bone: comparison of multi- and single-detector row CT. *Radiology.* 2005;**235**(1):133-41.
- Jun BC, Song SW, Cho JE, Park CS, Lee DH, Chang KH, et al. Three-dimensional reconstruction based on images from spiral high-resolution computed tomography of the temporal bone: anatomy and clinical application. *J Laryngol Otol.* 2005;**119**(9):693-8.
- Parlier-Cuau C, Champsaur P, Perrin E, Rabischong P, Lassau JP. High-resolution computed tomography of the canals of the temporal bone: anatomic correlations. *Surg Radiol Anat.* 1998;**20**(6):437-44.

7. Reisser C, Schubert O, Forsting M, Sartor K. Anatomy of the temporal bone: detailed three-dimensional display based on image data from high-resolution helical CT: a preliminary report. *Am J Otol.* 1996;**17**(3):473-9.
8. Rodt T, Ratiu P, Becker H, Bartling S, Kacher DF, Anderson M, et al. 3D visualisation of the middle ear and adjacent structures using reconstructed multi-slice CT datasets, correlating 3D images and virtual endoscopy to the 2D cross-sectional images. *Neuroradiology.* 2002;**44**(9):783-90.
9. Sajjadi H. Endoscopic middle ear and mastoid surgery for cholesteatoma. *Iran J Otorhinolaryngol.* 2013;**25**(71):63-70.
10. Chan LL, Manolidis S, Taber KH, Hayman LA. In vivo measurements of temporal bone on reconstructed clinical high-resolution computed tomography scans. *Laryngoscope.* 2000;**110**(8):1375-8.
11. Rafferty MA, Siewerdsen JH, Chan Y, Daly MJ, Moseley DJ, Jaffray DA, et al. Intraoperative cone-beam CT for guidance of temporal bone surgery. *Otolaryngol Head Neck Surg.* 2006;**134**(5):801-8.
12. Fatterpekar GM, Doshi AH, Dugar M, Delman BN, Naidich TP, Som PM. Role of 3D CT in the evaluation of the temporal bone. *Radiographics.* 2006;**26** Suppl 1:S117-32.
13. Lane JJ, Lindell EP, Witte RJ, DeLone DR, Driscoll CL. Middle and inner ear: improved depiction with multiplanar reconstruction of volumetric CT data. *Radiographics.* 2006;**26**(1):115-24.
14. Vrionis FD, Foley KT, Robertson JH, Shea JJ, 3rd. Use of cranial surface anatomic fiducials for interactive image-guided navigation in the temporal bone: a cadaveric study. *Neurosurgery.* 1997;**40**(4):755-63.
15. Zhen J, Liu C, Wang S, Liu S, He J, Wang J, et al. The thin sectional anatomy of the temporal bone correlated with multislice spiral CT. *Surg Radiol Anat.* 2007;**29**(5):409-18.
16. Tomura N, Sashi R, Kobayashi M, Hirano H, Hashimoto M, Watarai J. Normal variations of the temporal bone on high-resolution CT: their incidence and clinical significance. *Clin Radiol.* 1995;**50**(3):144-8.
17. Rajati M, Pezeshki Rad M, Irani S, Khorsandi MT, Motasaddi Zarandy M. Accuracy of high-resolution computed tomography in locating facial nerve injury sites in temporal bone trauma. *Eur Arch Otorhinolaryngol.* 2013.
18. Mahmutoglu AS, Celebi I, Sahinoglu S, Cakmakci E, Sozen E. Reliability of preoperative multidetector computed tomography scan in patients with chronic otitis media. *J Craniofac Surg.* 2013;**24**(4):1472-6.
19. Vlastarakos PV, Kiprouli C, Pappas S, Xenelis J, Maragoudakis P, Troupis G, et al. CT scan versus surgery: how reliable is the preoperative radiological assessment in patients with chronic otitis media? *Eur Arch Otorhinolaryngol.* 2012;**269**(1):81-6.