



Contents lists available at ScienceDirect

International Journal of Surgery Case Reports

journal homepage: www.casereports.com

Vitelline fistula associated with omphalocele: Diagnostic dilemma?

Edgar D. Sy^{a,b,*}, Yen-Shen Shan^{a,b}, Chyi-Her Lin^{a,b}^a National Cheng Kung University Hospital, Tainan, Taiwan^b National Cheng Kung University Medical College, Tainan, Taiwan

ARTICLE INFO

Article history:

Received 13 March 2018

Received in revised form 6 April 2018

Accepted 11 April 2018

Available online 16 April 2018

Keyword:

Omphalocele

Vitelline duct

Umbilico-enteric

Omphalomesenteric

Omphaloenteric fistula

ABSTRACT

INTRODUCTION: Combination vitelline fistula (VF) and omphalocele at birth is a rare congenital anomaly as a result disturbance in organogenesis with failure of normal return of intestines into the abdominal cavity and failed obliteration of the vitelline duct.

CASE PRESENTATION: A newborn presented with omphalocele sac with visible intestine, stoma like lesion with prolapsing mucosa just lateral to the umbilical cord and passage of meconium stool. Operative surgery was confirmed an intact omphalocele sac and vitelline fistula. Fistulectomy, using wedge resection of the small bowel and primary closure abdominal wall defect.

DISCUSSION: In our review of literature, VF associated with omphalocele had not been reported. Combination of anomaly maybe misleading, however, can be easily diagnosed the location of VF opening on the omphalocele sac, which is adjacent to the umbilical cord and luminal passage of meconium stool after birth. A fistulogram may be the best initial diagnostic imaging approach for identifying and confirmation of a fistula tract.

CONCLUSION: VF associated with omphalocele is rare. Post-natal diagnosis is easily by gross appearance stoma like lesion, which is located just lateral of the umbilical cord, an intact omphalocele sac and post-natal meconium stool passage.

© 2018 The Authors. Published by Elsevier Ltd on behalf of IJS Publishing Group Ltd. This is an open access article under the CC BY-NC-ND license (<http://creativecommons.org/licenses/by-nc-nd/4.0/>).

1. Introduction

Anomalies of failed vitelline duct obliteration, an umbilical anomaly with overall incidence of 1 in 15,000 live births, are the most frequent cause of surgical newborn consultations, in which VF is the least common [1]. However, combination of VF and omphalocele is rare and had not been reported in our review of literature, and can be mistaken as bowel perforation with rupture omphalocele sac, which necessitate aggressive early surgical intervention. This case report is reported in line with the SCARE criteria [2].

2. Case report

An out born baby boy was referred to our hospital with protruding abdominal mass with a lesion lateral to the umbilical cord. On admission, vital sign showed TPR of 35.7 °C, 160/min, 39/min, BP 74/35 mmHg and body weight of 3212 gm. Physical examination showed good skin turgor and a mass with thin sac below the umbilical cord, measured 3.5*6 cm with visible intestine and a stoma like lesion with prolapsing mucosa and passage of meconium stool. Buttock area noted to have sacral dimpling. Cardiac, abdominal and spinal echography showed small interrupted interatrial septum

at secundum portion with size of 0.2 cm with L to R shunt, mild peripheral pulmonary stenosis with pressure gradient of 8 mmHg, mild hepatomegaly, bilateral moderate hydronephrosis, and no spinal abnormal finding, respectively. Past medical history showed no history of amniocentesis, non-invasive prenatal test and with uneventful prenatal care. He was delivered by a 28 y.o., mother, G1P1, with gestational age 39+1 weeks. Birth History did not showed sign of premature rupture of membrane nor delay of initial crying. The Apgar score at birth was 8, 9 at 1 and 5 mins. Operative surgery was done with operative finding of a protruding mass below the umbilical cord, covered with thin transparent sac, containing small bowel and ascitic fluid, with abdominal defect of about 3*4 cm. Just lateral to the cord, a stoma like lesion attached to the omphalocele sac, with prolapse intestinal mucosa and opening of about 2*1.5 cm (Fig.1). On opening the sac, the fistula, about 2 cm long, was connected to the small bowel (Fig.2) with internal opening of about 0.3 cm (Fig.3). Fistulectomy, using wedge resection of the small bowel was done and the abdominal wall defect was primary close in two layers. Histopathologic examination of the lesion showed squamous epithelium-lining membranous sac continuous with intestinal mucosa. Postoperative chromosome study revealed 46XY with normal karyotype and feeding started on the 4th and was discharge on the 9th postoperative day.

* Corresponding author at: Department of Surgery, National Cheng Kung University Hospital, 138 Sheng-Li Rd, Tainan, Taiwan.

E-mail address: edsyfalcon2@yahoo.com.tw (E.D. Sy).

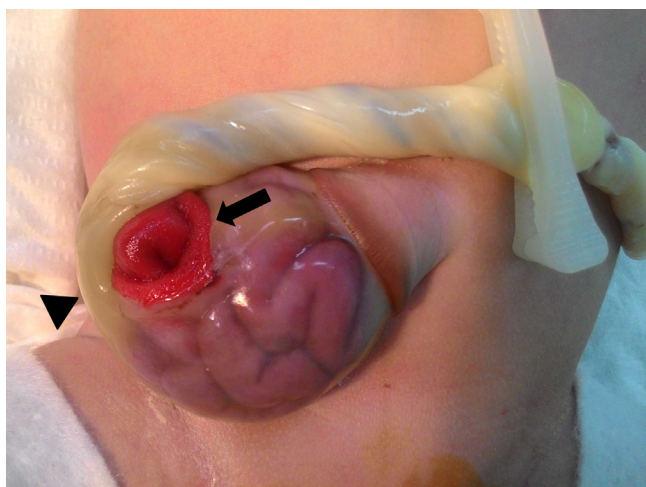


Fig. 1. Omphalocele with fistula opening and prolapsing mucosa (arrow) located on the lateral aspect of cord (arrow head).

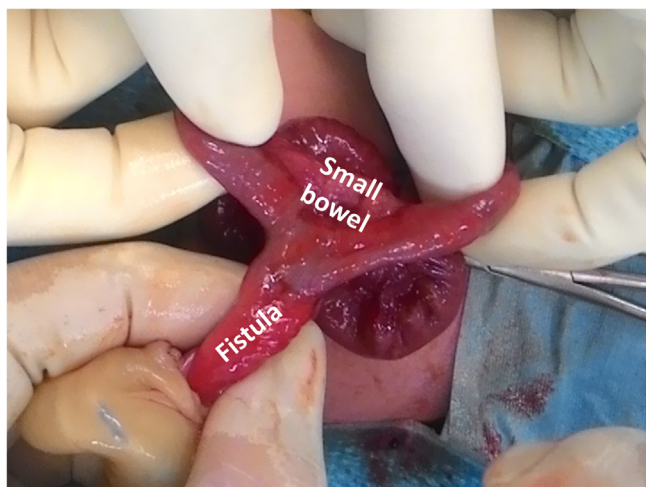


Fig. 2. The fistula connecting to small bowel.

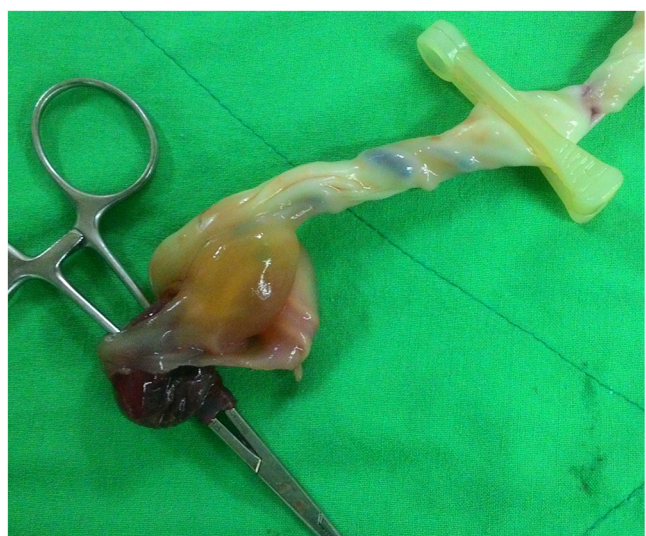

Fig. 3. The internal opening of VF probed using a mosquito forcep.

3. Discussion

The vitelline duct in the developing fetus, also known as the omphalomesenteric duct, is a long narrow tube that connecting the yolk sac and midgut. Generally, the duct fully obliterates, but a failure of the duct to close after birth result in anomaly such as Meckel's diverticulum, duct sinus, cyst, umbilical mucosal polyp and VF (also known as umbilico-enteric, omphalomesenteric, omphaloenteric fistula), which is centrally located within the umbilicus area. The overall incidence of VF anomalies of 1 in 15,000 live births, for which, VF is the least common [1,3]. In our review of literature, VF associated with omphalocele had not been reported.

An omphalocele is a rare abdominal wall defect in which organs remain outside of the abdomen in a sac with prevalence of approximately 3 per 10,000 live births [4,5]. It is associated with other congenital malformations, such as cardiac anomalies, neural tube defect and chromosomal abnormalities.

Literally, non-distress fetuses of mammals never pass meconium. However, large VF with internal opening equal to small bowel diameter and presence of distal intestinal obstruction might lead to passage of meconium. During fetal development, meconium, are propelled by small bowel peristalsis to the colon [6]. Intestinal peristalsis begins to appear as pregnancy reach 36–37 wks., and become more efficient with increasing gestational age [7]. Prenatal ultrasound may initially identify the presence echogenic amniotic fluids such as meconium, blood, or vernix caseosa. Homogeneous echogenic AF had a sensitivity of 100%, a specificity of 69%, a positive predictive value of 10%, and a negative predictive value of 100% in detecting meconium [8]. Benacerraf et al. stated that the ultrasound criteria for diagnosis of meconium-stained amniotic fluid include (1) a diffuse echogenic pattern throughout the amniotic cavity, (2) a clear contrast between the amniotic fluid and the umbilical vessels, and (3) layering in the more dependent areas [9]. When echogenic amniotic fluid is identified in a third trimester obstetrical ultrasound, Sepulveda et al. recommended direct visualization of the amniotic fluid by amniocentesis or amnioscopy, or a careful study of the fetal well-being by means of nonstress test, and/or biophysical profile [10] as fetal distress or cord compression may result in passage of meconium stool [11]. However, non-passage of meconium can be attributed to small size of internal opening of VF, the physics underlying Bernoulli's theorem or the Venturi effect, thick viscosity of meconium, and poor intestinal peristalsis in fetus.

At birth, presence of VF is suspected clinically by the passage of meconium stool or intestinal content via the umbilicus within few days after birth. However, diagnosis of VF in the presence omphalocele may be misleading. The the location of VF opening on the omphalocele sac, which is adjacent to the umbilical cord and luminal passage of meconium stool after birth leads to diagnosis. The transparent intact sac can be easily differentiated from rupture sac. The presence of bowel perforation prenatally can be noted by meconium contamination of abdominal cavity. A fistulogram may be the best initial diagnostic imaging approach for identifying and confirmation of a fistula tract [12].

Prior to or after surgical intervention, patient should be evaluated for other congenital anomalies. A preoperative CT scan can provide anatomic identification of failed obliteration of the vitelline duct while an upper gastrointestinal series to rule out malrotation [13]. However, it seems to be unnecessary in VF with omphalocele as the normal bowel can be inspected during surgical repair. Treatment of these anatomic anomalies requires surgical resection of fistula and repair of abdominal defect, either primary or stage repair, within first 24–72 h of life.

4. Conclusion

VF associated with omphalocele is rare. Post-natal diagnosis is easy by gross appearance stoma like lesion, which is located just lateral of the umbilical cord, an intact omphalocele sac and post-natal meconium stool passage.

Conflicts of interest

All authors disclose no financial and personal relationships with other people or organisations that could inappropriately influence (bias) their work.

Sources of funding

No source of funding or sponsors.

Ethical approval

The case report is approved by National Cheng Kung University Institutional Review Board (NCKUH IRB) with/IRB number BEC 106-006.

Consent

The head of our medical team/hospital has taken responsibility that exhaustive attempts have been made to contact the family and that the paper has been sufficiently anonymised not to cause harm to the patient or their family. We have uploaded a signed document to this effect.

Author contribution

Edgar D. Sy: Dr. Sy conceptualized and designed the study, carried out the initial analyses of patient data, drafted the initial manuscript, critically reviewed and revised and approved the final manuscript as submitted.

Yen-Shen Shan: Prof. Shan carried out the analyses of patient data, revised the manuscript, and approved the final manuscript as submitted.

Chyi-Her Lin: Prof. Lin carried out the final analyses of patient data, reviewed the manuscript, and approved the final manuscript as submitted.

Registration of research studies

None (non-human study).

Guarantor

Edgar D. Sy.

References

- [1] T.C. Moore, Omphalomesenteric duct malformations, *Semin. Pediatr. Surg.* 5 (May (2)) (1996) 116–123.
- [2] R.A. Agha, A.J. Fowler, A. Saeta, et al., The SCARE statement: consensus-based surgical case report guidelines, *Int. J. Surg.* 34 (October) (2016) 180–186.
- [3] E. Jauniaux, C. Donner, P. Simon, M. Vanesse, J. Hustin, F. Rodesch, Pathologic aspects of the umbilical cord after percutaneous umbilical blood sampling, *Obstet. Gynecol.* 73 (February (2)) (1989) 215–218.
- [4] T.T. Gong, Q.J. Wu, Y.L. Chen, et al., Evaluating the time trends in prevalence of exomphalos in 14 cities of Liaoning province, 2006–2015, *Sci. Rep.* 6 (September) (2016), 32901.
- [5] J. Marshall, J.L. Salemi, J.P. Tanner, et al., Prevalence, correlates, and outcomes of omphalocele in the United States, 1995–2005, *Obstet. Gynecol.* 126 (August (2)) (2015) 284–293.
- [6] D.A. Nyberg, L.A. Mack, R.M. Patten, D.R. Cyr, Fetal bowel. Normal sonographic findings, *J. Ultrasound Med.* 6 (January (1)) (1987) 3–6.
- [7] M. Ziliani, S. Fernandez, Correlation of ultrasonic images of fetal intestine with gestational age and fetal maturity, *Obstet. Gynecol.* 62 (November (5)) (1983) 569–573.
- [8] D.M. Sherer, J.S. Abramowicz, S.A. Smith, J.R. Woods Jr., Sonographically homogeneous echogenic amniotic fluid in detecting meconium-stained amniotic fluid, *Obstet. Gynecol.* 78 (November (5 Pt 1)) (1991) 819–822.
- [9] B.R. Benacerraf, M.A. Gatter, F. Ginsburgh, Ultrasound diagnosis of meconium-stained amniotic fluid, *Am. J. Obstet. Gynecol.* 149 (July (5)) (1984) 570–572.
- [10] W.H. Sepulveda, V.H. Quiroz, Sonographic detection of echogenic amniotic fluid and its clinical significance, *J. Perinat. Med.* 17 (5) (1989) 333–335.
- [11] M.D. Kilby, D. Churchill, P.N. Baker, Meconium staining of the amniotic fluid: the effects on fetal well-being, *Curr. Obstet. Gynaecol.* 4 (1) (1994) 41–46.
- [12] B.G. Cilento Jr., S.B. Bauer, A.B. Retik, C.A. Peters, A. Atala, Urachal anomalies: defining the best diagnostic modality, *Urology* 52 (July (1)) (1998) 120–122.
- [13] J. Fuijkschoot, R.M. Wijnen, G.P. Gerrits, S.V. Dubois, P.N. Rieu, A neonate with an intact congenital umbilical appendix: an alternative theory on the etiology of the appendico-umbilical fistula, *Pediatr. Surg. Int.* 22 (August (8)) (2006) 689–693.

Open Access

This article is published Open Access at [sciencedirect.com](https://www.sciencedirect.com). It is distributed under the [IJSCR Supplemental terms and conditions](#), which permits unrestricted non commercial use, distribution, and reproduction in any medium, provided the original authors and source are credited.