

ORIGINAL RESEARCH

Comparison of 2 Different Paclitaxel-Coated Balloons in Coronary In-Stent Restenosis



A Randomized Controlled Trial

Eun Jung Jun, PhD,^{a,b} Eun-Seok Shin, MD, PhD,^{a,b} Song Lin Yuan, MD,^{b,c} Youngjune Bhak, PhD,^d Scot Garg, MD, PhD,^e Woong Chol Kang, MD, PhD,^f Je Sang Kim, MD,^g June-Hong Kim, MD, PhD,^h Jang-Whan Bae, MD, PhD,ⁱ Seung-Woon Rha, MD, PhD,^j In-Ho Chae, MD, PhD^k

ABSTRACT

BACKGROUND Drug-coated balloons (DCBs) offer an effective treatment for in-stent restenosis (ISR). The Genoss DCB is a novel paclitaxel-coated balloon with a shellac plus vitamin E excipient that enhances drug delivery to the target lesion, minimizing restenosis.

OBJECTIVES This study aimed to investigate the angiographic efficacy, clinical safety, and effectiveness of the novel shellac plus vitamin E-based DCB in a randomized controlled trial designed to enable regulatory approval of this new device in South Korea.

METHODS This noninferiority trial randomized patients experiencing their first ISR to the novel shellac plus vitamin E-based DCB or the reference SeQuent Please iopromide-based DCB in a 1:1 ratio. All patients underwent planned angiographic and clinical follow-up at 6 months. The study was powered for the primary endpoint of 6 months in-segment late lumen loss (LLL).

RESULTS A total of 82 patients from 7 centers were randomized to either the novel shellac plus vitamin E-based DCB group (n = 41) or the reference iopromide-based DCB group (n = 41). The 6-month in-segment LLL was 0.15 ± 0.43 mm with the novel DCB compared with 0.24 ± 0.39 mm with the reference device. The 1-sided 97.5% upper confidence limit of the difference was 0.13 mm, lower than the noninferiority limit of 0.29 mm, achieving noninferiority (P for noninferiority = 0.001). Major cardiovascular events were comparable between 2 groups at 6 months (7.7% for the novel DCB vs 10.3% for the reference DCB; $P = 0.692$).

CONCLUSIONS In this multicenter, head-to-head comparison randomized trial, the novel shellac plus vitamin E-based DCB showed a comparable result to the reference iopromide-based device for the primary endpoint of 6-month in-segment LLL for the treatment of coronary ISR. (Compare the Safety and Efficacy of Genoss[®] DCB and SeQuent[®] Please in Korean Patient With Coronary In-stent Restenosis; [NCT04405063](https://clinicaltrials.gov/ct2/show/study/NCT04405063)) (JACC: Asia 2022;2:170–179) © 2022 The Authors. Published by Elsevier on behalf of the American College of Cardiology Foundation. This is an open access article under the CC BY-NC-ND license (<http://creativecommons.org/licenses/by-nc-nd/4.0/>).

From the ^aDivision of Cardiology, Department of Internal Medicine, Ulsan University Hospital, University of Ulsan College of Medicine, Ulsan, South Korea; ^bDivision of Cardiology, Department of Internal Medicine, Ulsan Medical Center, Ulsan, South Korea; ^cDepartment of Cardiology, Dong-A University Hospital, Busan, South Korea; ^dDepartment of Biomedical Engineering, College of Information-Bio Convergence Engineering, Ulsan National Institute of Science and Technology, Ulsan, South Korea; ^eDepartment of Cardiology, East Lancashire Hospitals NHS Trust, Blackburn, United Kingdom; ^fCardiology Division, Department of Internal Medicine, Gil Medical Center, Gachon University College of Medicine, Incheon, South Korea; ^gDepartment of Cardiology, Dongguk University Ilsan Hospital, Goyang, South Korea; ^hCardiovascular Center, Pusan National University Yangsan Hospital, Yangsan, South Korea; ⁱDivision of Cardiology, Department of Internal Medicine, College of Medicine, Chungbuk National University, Cheongju, South Korea; ^jCardiovascular Center, Korea University Guro Hospital, Seoul, South Korea; and the ^kDivision of Cardiology, Department of Internal Medicine, Seoul National University Bundang Hospital, Seongnam, South Korea.

Although drug-eluting stents (DES) have improved the clinical outcomes of patients with in-stent restenosis (ISR), the optimal treatment strategy for ISR remains unclear. Drug-coated balloons (DCBs), which are a recommended treatment option for ISR with a Class I, Level of Evidence: A recommendation in the European guidelines for revascularization, importantly avoid the need for a second layer of a stent.¹⁻³ Paclitaxel remains the preferred drug for the balloon coating because of its irreversible binding to microtubules,⁴ resulting in effective inhibition of neointimal proliferation.⁵ Most randomized studies that compare DCBs with alternative percutaneous therapies for the treatment of ISR are centered on the iopromide-based SeQuent Please (B. Braun); however, alternative paclitaxel-coated balloons (PCBs) using different excipients are available for clinical applications. Several prospective randomized studies have shown comparable angiographic and clinical outcomes among different types of DCBs for patients with coronary ISR.^{6,7} The Genoss PCB (Genoss DCB; GENOSS) is a new DCB with a different excipient, ie, shellac plus vitamin E, which is designed to enhance drug delivery to the target lesion. This study aimed to evaluate the angiographic efficacy, clinical safety, and effectiveness of this new DCB in a randomized trial designed to enable regulatory approval of the new device in South Korea.

METHODS

STUDY DESIGN AND PATIENT POPULATION.

This prospective, multicenter, randomized controlled trial compared the new shellac plus vitamin E-based DCB with the iopromide-based DCB in patients with ISR (NCT04405063). The protocol was approved by all ethics committees of all participating centers. Patients ≥ 19 years of age with clinical evidence of stable or unstable angina, silent myocardial ischemia, or a positive functional study were considered for enrollment. Clinical inclusion criteria required lesions to be Mehran type I to III ISR with at least 50% diameter stenosis (DS), occurring >90 days after coronary stent implantation. Major clinical exclusion criteria were infarct-related artery lesions in patients with acute myocardial infarction; restenosis lesions with thrombosis or bypass grafts; target vessels with

complete occlusion (Mehran type IV); known hypersensitivity or contraindications to aspirin, heparin, clopidogrel, and paclitaxel; sensitivity to contrast media not amenable to pre-medication; lesion length >40 mm; or vessel diameter <2.0 mm.

Eligible patients who provided written informed consent were enrolled from 7 university hospitals in South Korea. We randomly stratified patients on the basis of the lesion site and used an interactive Web response system to randomize patients. Study coordination, data management, and on-site monitoring support were provided by an independent contract research organization company (Synex Consulting). The study sponsor did not have any role in the analysis and interpretation of data or writing of the manuscript and did not participate in the decision to submit the paper for publication.

STUDY DEVICES AND PROCEDURES. The SeQuent Please (reference device) is an iopromide-based DCB that is coated with $3 \mu\text{g}$ paclitaxel/ mm^2 of balloon surface and uses iopromide as a hydrophilic excipient. The Genoss DCB (tested device) is also coated with $3 \mu\text{g}$ paclitaxel/ mm^2 of balloon surface but uses a wax-free shellac and vitamin E as an excipient, which is designed to enhance drug delivery to the target lesion and prevent restenosis.

Randomization was performed when the ISR lesion was judged to be capable of DCB treatment. Predilatation of the target lesion was mandatory using a standard balloon catheter, followed by full plaque modification. The DCB was selected using a balloon-to-artery ratio of 1.0, which is longer than the lesion segment. The delivery time of the DCB catheter from the vascular access to the vessel wall and expansion to nominal pressure was minimized to <3 minutes. If more than 3 minutes had elapsed, the failed DCB was removed and replaced with a new product for retreatment. The recommended DCB balloon inflation time was at least 60 seconds with nominal pressure, but if the patient could not tolerate this duration, inflation was performed twice for 30 seconds. All patients were preloaded with clopidogrel and already on aspirin before coronary angioplasty. Unfractionated heparin was administered according to the

ABBREVIATIONS AND ACRONYMS

DCB = drug-coated balloon

DES = drug-eluting stent

DS = diameter stenosis

ISR = in-stent restenosis

LLL = late lumen loss

MLD = minimal lumen diameter

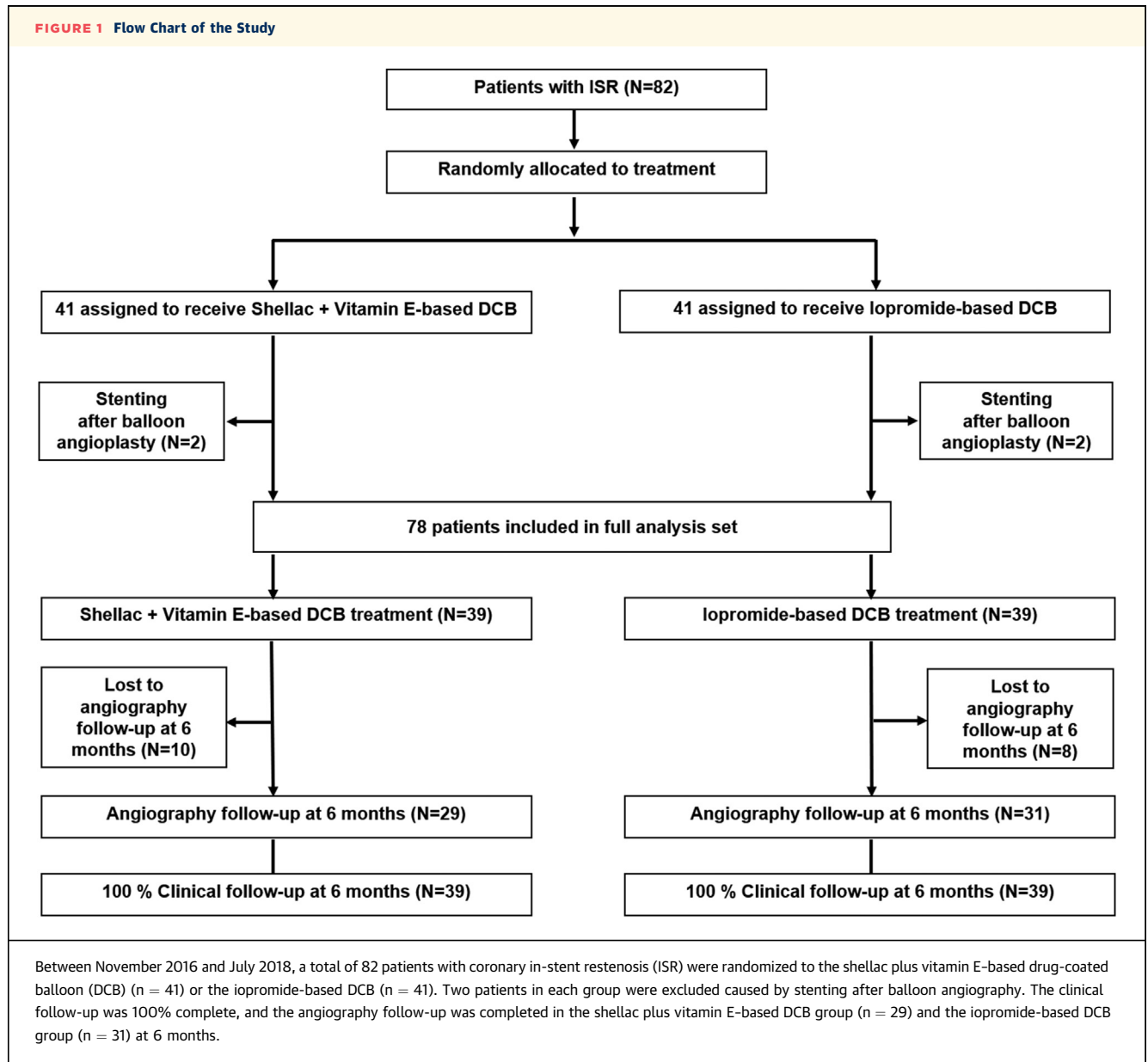
MACE = major adverse cardiovascular event

PCB = paclitaxel-coated balloon

TLR = target lesion revascularization

The authors attest they are in compliance with human studies committees and animal welfare regulations of the authors' institutions and Food and Drug Administration guidelines, including patient consent where appropriate. For more information, visit the [Author Center](#).

Manuscript received July 14, 2021; revised manuscript received September 30, 2021, accepted November 4, 2021.

FIGURE 1 Flow Chart of the Study

standard hospital practice, and most of the procedures were performed via radial access. Vascular sheaths, either through the transradial or transfemoral route, were removed according to the usual hospital practice.

QUANTITATIVE CORONARY ANGIOGRAPHY. Angiography before and after all interventions and at angiographic follow-up was performed using identical projections and analyses. All coronary angiographic images were analyzed by an expert (Yoonha Noh) in the core laboratory at the Cardiovascular Center of the Genome Research Foundation.

Measurements were obtained in the stented area with measurement shoulder to shoulder (in stent; narrowing size and references were automatically identified by the system) and in the total stented area plus 5.0 mm proximally and distally (in segment; lesion + complete treated segment + 5 mm adjacent margins). The following parameters were analyzed: reference vessel diameter, minimal lumen diameter (MLD), percent DS, acute lumen gain (defined as the difference between MLD after DCB treatment and MLD at baseline), late lumen loss (LLL) (defined as the difference between MLD after DCB treatment and MLD at follow-up), lesion length, binary restenosis, and

persistence of dissection (National Heart, Lung, and Blood Institute classification).⁸ Patterns of ISR were defined according to the Mehran classification.⁹

FOLLOW-UP AND ENDPOINTS. Dual antiplatelet therapy was continued orally for 6 months, and patients underwent follow-up angiography after 6 months. Clinical follow-up was performed at 30 ± 7 days and at 6 months ± 7 days post-procedure. All clinical endpoints and adverse events were evaluated with consensus of the investigators, and all events were cross-checked with the medical records by external monitors. Given the different packaging of the study balloon catheters, the investigators performing the study procedures were not blinded to the treatment assignment; however, statisticians were blinded. Angiographic in-segment LLL was the primary endpoint. Secondary endpoints were major adverse cardiovascular events (MACE) composed of the occurrence of cardiac death, target lesion myocardial infarction, stent thrombosis, and clinically driven target lesion revascularization (TLR) at 6 months, and these conditions were defined according to the Academic Research Consortium consensus document.¹⁰

Device success was defined as successful delivery and deployment of the study balloon. Lesion success was defined as the achievement of final residual stenosis <30% by visual estimation. Procedural success was defined as a target lesion DS <30% immediately after DCB treatment, Thrombolysis In Myocardial Infarction (TIMI) flow grade 3, and absence of in-hospital MACE. Binary restenosis was defined as a DS of at least 50% of the luminal diameter at angiographic follow-up.

STATISTICAL ANALYSIS. The study hypothesis was that the novel shellac plus vitamin E-based DCB was noninferior to the iopromide-based DCB for the treatment of ISR, in terms of in-segment LLL. Accordingly, the power calculation of the present trial included the assumption of an LLL of 0.17 mm in both arms, with a delta of 0.00, alpha of 2.5%, power of 80%, SD of 0.4, and noninferiority margin of 0.29 mm. The estimation of 0.17 to 0.42 mm of LLL in the control group was derived from previous studies with the same device in a similar lesion setting.¹¹⁻¹⁴ Therefore, we calculated a population of 34 patients per group. With an attrition rate for angiographic follow-up of 17%, we decided to include a total population of 82 patients.

For the demographic information, continuous data were summarized by descriptive statistics (number of subjects, mean, SD, median, minimum, and maximum) and categorical data by frequency and

TABLE 1 Clinical Baseline Characteristics

	Shellac + Vitamin E-Based DCB (n = 39)	Iopromide-Based DCB (n = 39)
Age, y	67.8 ± 11.2	65.2 ± 9.7
Male	33 (84.6)	29 (74.4)
Body mass index, kg/m ²	26.8 ± 8.8	24.7 ± 2.5
Hypertension	32 (82.1)	30 (76.9)
Diabetes mellitus	21 (53.9)	24 (61.5)
Insulin treatment	7 (18.0)	5 (12.8)
Hyperlipidemia	12 (30.8)	12 (30.8)
Current smoking	5 (12.8)	8 (20.5)
Prior myocardial infarction	5 (12.8)	8 (20.5)
Prior coronary artery bypass grafting	1 (2.6)	0
Prior stroke	0	0
Stable angina pectoris status	31 (79.5)	29 (74.4)
Bare-metal stent ISR	5	4
Drug-eluting stent ISR	34	35

Values are mean ± SD, n (%), or n.
 DCB = drug-coated balloon; ISR = in-stent restenosis.

fraction. Two-sided statistical tests were performed at a significance level of 5%, unless otherwise stated. The purpose of this study was to demonstrate the noninferiority of the shellac plus vitamin E-based DCB to the iopromide-based DCB in terms of in-segment LLL.

The primary endpoint, in-segment LLL, was analyzed in all patients who had undergone angiographic follow-up. For the comparison between the 2 groups, in-segment LLL values measured at 6 months were evaluated using the independent 2-sample Student's *t*-test or Wilcoxon rank sum test. At this time, if the upper limit of the 97.5% 1-sided CI between the shellac plus vitamin E-based DCB group and the iopromide-based DCB group was <0.29 mm (noninferiority limit), the shellac plus vitamin E-based DCB group was significantly noninferior to the iopromide-based DCB group. MLD and DS immediately after the procedure and at 6 months' follow-up were evaluated using the 2-sample Student's *t*-test or Wilcoxon rank sum test.

If necessary, a chi-square test or Fisher's exact test was performed to compare the 2 groups. All statistical analyses were performed at a 2-sided significance level of 0.05, using SPSS version 21.0 (IBM), NCSS (NCSS), and R version 3.6.3 (R Foundation for Statistical Computing).

RESULTS

From November 2016 to July 2018, 82 patients with coronary ISR were randomly assigned to either the shellac plus vitamin E-based DCB (n = 41) or the

TABLE 2 Angiographic and Procedural Characteristics

	Shellac + Vitamin E-Based DCB (n = 39)	Iopromide-Based DCB (n = 39)
Multivessel disease	11 (28.2)	10 (25.6)
Lesion type, B2/C	16 (41.0)	21 (53.9)
Target vessel location		
Left anterior descending artery	18 (46.2)	19 (48.7)
Left circumflex artery	10 (25.6)	9 (23.1)
Right coronary artery	11 (28.2)	11 (28.2)
Mehran type		
I	19 (48.7)	17 (43.6)
II	16 (41.0)	16 (41.0)
III	4 (10.3)	5 (12.8)
IV	0	1 (2.6)
TIMI flow grade 3 before procedure	39 (100.0)	39 (100.0)
Number of study balloons	1.0 ± 0.2 (40)	1.1 ± 0.3 (42)
Study balloon diameter, mm	3.0 ± 0.4	3.0 ± 0.4
Study balloon length, mm	24.6 ± 5.1	27.2 ± 7.0
Maximum study balloon pressure, atm	10.3 ± 2.7	9.8 ± 3.0
Study balloon inflation time, s	54.6 ± 12.5	53.9 ± 12.3
Delivery time to target lesion, s	43.8 ± 39.1	42.5 ± 33.2
TIMI flow grade 3 at end of procedure	39 (100.0)	39 (100.0)
Bailout strategy	0	0

Values are n (%), mean ± SD (n), or mean ± SD.
DCB = drug-coated balloon, TIMI = Thrombolysis In Myocardial Infarction.

iopromide-based DCB Please (n = 41) treatment group. **Figure 1** shows the flowchart of the trial. Baseline characteristics between the 2 groups were generally balanced (**Table 1**), with no significant differences. **Table 2** summarizes the angiographic and procedural characteristics, and **Table 3** summarizes the quantitative coronary angiographic results. The mean SYNTAX (SYnergy between PCI with TAXUS and Cardiac Surgery) score was 9.6 ± 7.2 mm with the shellac plus vitamin E-based DCB compared with 8.9 ± 7.4 mm with the iopromide-based DCB. The device success rate was 100%. The lesion and procedural success rate was 85.9% (shellac plus vitamin E-based DCB at 82.1% vs iopromide-based DCB at 89.7%; $P = 0.329$). No procedural complications or bailout stenting occurred after any treatment, and all patients were successfully treated with the assigned DCB without flow-limiting dissection.

ANGIOGRAPHIC OUTCOMES. Angiographic follow-up data (**Table 3**) were available for 29 patients in the shellac plus vitamin E-based DCB group and 31 patients in the iopromide-based DCB group. The 6-month in-segment LLL was 0.15 ± 0.43 mm with the shellac plus vitamin E-based DCB compared with 0.24 ± 0.39 mm with the iopromide-based DCB (**Central Illustration**). The upper limit of the 97.5%

one-sided CI for differences was 0.13 mm, lower than the noninferiority limit of 0.29 mm, achieving the noninferiority of the shellac plus vitamin E-based DCB to the iopromide-based DCB (P for noninferiority = 0.001).

Immediately after DCB treatment in both groups, there were comparable increases in reference vessel diameter and MLD and decreases in DS. In addition, in-segment (shellac plus vitamin E-based DCB 1.26 ± 0.38 mm vs iopromide-based DCB 1.37 ± 0.43 mm; $P = 0.250$) and in-stent (shellac plus vitamin E-based DCB 1.26 ± 0.38 mm vs iopromide-based DCB 1.37 ± 0.43 mm; $P = 0.249$) acute lumen gains were similar in both groups. At angiographic follow-up, no significant between-group differences were found, except for DS. In-segment (shellac plus vitamin E-based DCB $23.53 \pm 10.93\%$ vs iopromide-based DCB $30.43 \pm 11.17\%$; $P = 0.020$) and in-stent (shellac plus vitamin E-based DCB $23.53 \pm 10.93\%$ vs iopromide-based DCB $30.23 \pm 10.82\%$; $P = 0.022$) DS were significantly lower after DCB treatment than before the treatment. As shown in **Table 3**, no significant between-group differences were noted in either in-segment (shellac plus vitamin E-based DCB 0% vs iopromide-based DCB 6.45% [n = 2 of 31]; $P = 0.164$) or in-stent (shellac plus vitamin E-based DCB 0% vs iopromide-based DCB 3.22% [n = 1 of 31]; $P = 0.329$) binary restenosis. **Figures 2 and 3** present the cumulative frequency distributions of in-segment MLD, DS, and LLL.

CLINICAL OUTCOMES. Clinical follow-up was completed for all patients in both groups at 6 months. **Table 4** summarizes the clinical events at 6 months. There was no cardiac death, and the target lesion myocardial infarction rate was 2.6% (n = 1 of 39) in both groups. Stent thrombosis occurred in only 1 patient in the iopromide-based DCB group, and TLR was 5.1% (n = 2 of 39) in both groups. MACE at 6 months was 7.7% (n = 3 of 39) in the shellac plus vitamin E-based DCB group and 10.3% (n = 4 of 39) in the SeQuent Please group (**Central Illustration**).

DISCUSSION

This trial demonstrated that the shellac plus vitamin E-based DCB was noninferior to the iopromide-based DCB with regard to the primary endpoint of 6-month in-segment LLL in treating coronary ISR. Additionally, the rates of adverse clinical events within 6 months were similar between the treatment groups. The results of this new, adequately powered, head-to-head randomized trial comparing 2 different

DCBs in ISR add important insights to the available clinical evidence for treatment strategies for ISR.

Although the risk of restenosis after implantation of contemporary new-generation DES is considered very low, the number of complex coronary interventions is increasing. Consequently, the indication for approximately 10% of all coronary interventions remains the treatment of ISR.¹⁵ The main cause of ISR is excessive neointimal proliferation caused by the stimulus of the permanent implant. Therefore, ISR therapy typically involves local drug delivery to reduce the risk of neointimal proliferation.¹⁶

Although strategies for treating ISR varied and ranged from repeat balloon angioplasty to surgical revascularization, based on the available evidence, only 2 procedures could be considered effective, namely, implantation of another DES or use of a DCB.¹⁷ Ultimately, only these 2 device types have been endorsed in revascularization guidelines.¹ Common to both procedures is local drug delivery to the restenotic area within the stent to address the mechanism of excessive neointimal proliferation. As an alternative to the implantation of another stent, the treatment of ISR with a DCB was proven to be clinically effective.¹⁸ After 1 year, similar recurrence rates were observed with DES and DCB.^{12,13,19,20} In addition, evidence presents that long-term hard clinical endpoints are positively influenced by the absence of a further layer of metal.^{21,22} A recent meta-analysis of 4,590 patients compared DCBs with alternative treatments, such as DES, for coronary ISR and de novo lesions and reported a significantly lower all-cause and cardiac mortality after 3 years when using a DCB.²³ The suggested mechanism for this surprising finding is the avoidance of a permanent metal implant when treating patients with a DCB. For DES, a device-related annual event rate of up to 2% has been reported.²⁴ For this reason, several authors suggest using a DCB as the primary strategy for treating ISR,²⁵ even if the reduction in the risk of recurrent TLR appeared lower in repeat stenting with DES.²⁶

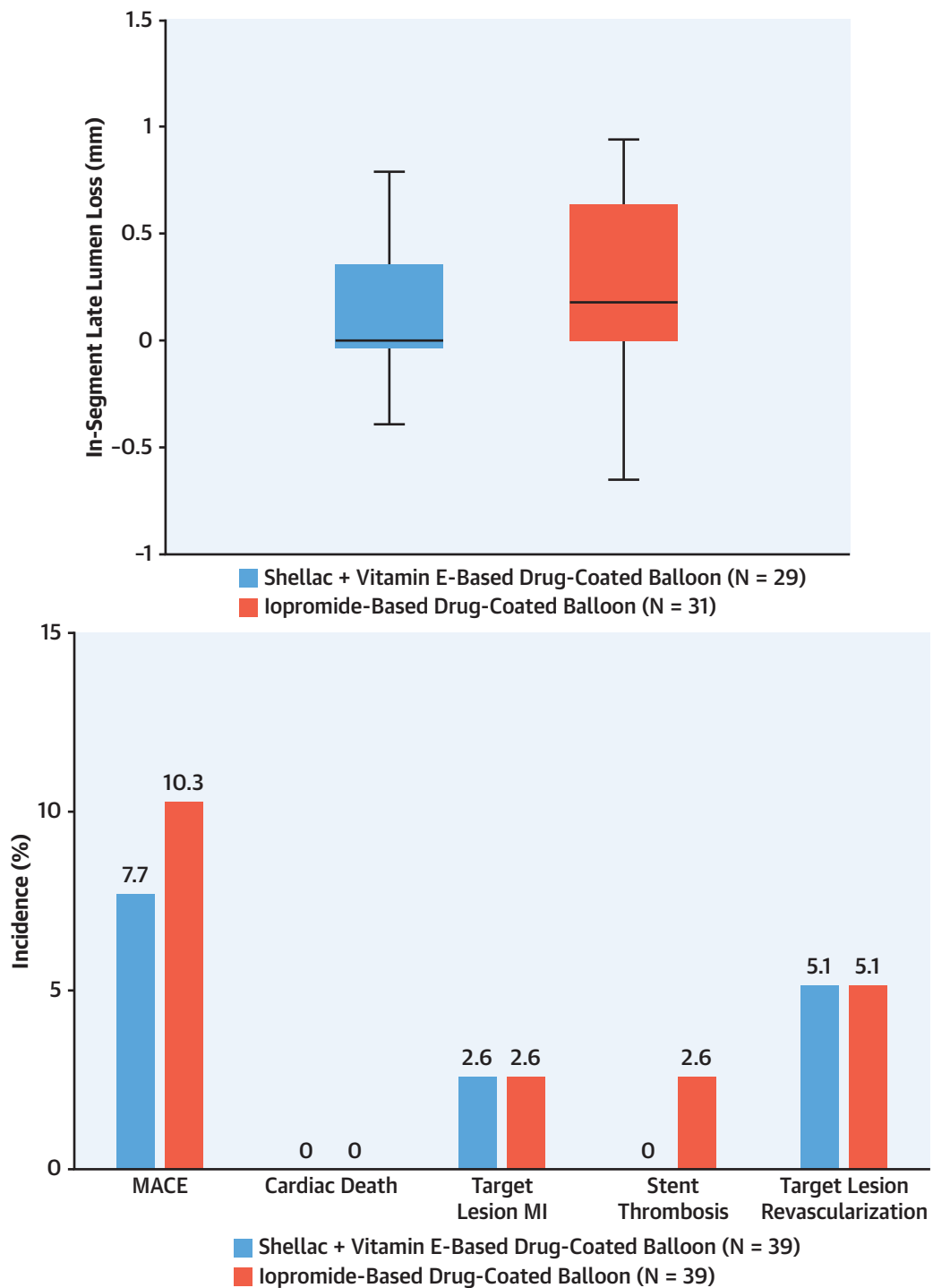
Many randomized data on the comparison of DCBs with alternative percutaneous therapies for the treatment of ISR are based on the iopromide-based DCB. Thus, we designed this trial to provide evidence for regulatory approval in South Korea by comparing the safety and efficacy of the new shellac plus vitamin E-based DCB with that of the reference iopromide-based DCB. The hydrophilic shellac coating on the surface of the new DCB allows for rapid release and diffusion into the tissue.^{27,28} Added to the coating is the antioxidant vitamin E, which is known

TABLE 3 Serial Quantitative Coronary Angiographic Results

	Shellac + Vitamin E-Based DCB	Iopromide-Based DCB	P Value
Pre-procedure	n = 39	n = 39	
LL, mm	20.10 ± 6.03	21.79 ± 8.61	0.318
RVD, mm	2.41 ± 0.48	2.49 ± 0.54	0.466
MLD, mm	0.87 ± 0.28	0.87 ± 0.34	0.936
DS, %	62.18 ± 14.02	64.95 ± 10.72	0.331
Post-balloon angioplasty	n = 39	n = 39	
RVD in-segment, mm	2.64 ± 0.46	2.64 ± 0.47	0.980
RVD in-stent, mm	2.64 ± 0.46	2.64 ± 0.47	0.980
MLD in-segment, mm	1.92 ± 0.42	1.90 ± 0.40	0.821
MLD in-stent, mm	1.92 ± 0.41	1.90 ± 0.40	0.821
DS in-segment, %	27.32 ± 11.18	27.73 ± 10.81	0.874
DS in-stent, %	27.35 ± 11.16	27.73 ± 10.81	0.882
Post-DCB	n = 39	n = 39	
RVD in-segment, mm	2.69 ± 0.54	2.80 ± 0.46	0.343
RVD in-stent, mm	2.68 ± 0.54	2.80 ± 0.46	0.310
MLD in segment, mm	2.13 ± 0.44	2.24 ± 0.36	0.220
MLD in-stent, mm	2.13 ± 0.44	2.24 ± 0.36	0.220
DS in-segment, %	20.49 ± 8.76	19.51 ± 8.86	0.625
DS in-stent, %	20.49 ± 8.76	19.51 ± 8.86	0.625
Acute lumen gain in-segment, mm	1.26 ± 0.38	1.37 ± 0.43	0.250
Acute lumen gain in-stent, mm	1.26 ± 0.38	1.37 ± 0.43	0.249
6-mo follow-up	n = 29	n = 31	
Follow-up, d	184.03 ± 24.48	187.77 ± 20.27	0.299
RVD in-segment, mm	2.71 ± 0.50	2.65 ± 0.43	0.640
RVD in-stent, mm	2.71 ± 0.50	2.66 ± 0.42	0.707
MLD in-segment, mm	2.07 ± 0.44	1.90 ± 0.55	0.196
MLD in-stent, mm	2.07 ± 0.44	1.87 ± 0.47	0.107
DS in-segment, %	23.53 ± 10.93	30.43 ± 11.17	0.020 ^a
DS in-stent, %	23.53 ± 10.93	30.23 ± 10.82	0.022 ^a
LLL in-segment, mm	0.15 ± 0.43	0.24 ± 0.39	0.299
LLL in-stent, mm	0.15 ± 0.43	0.26 ± 0.36	0.201
Binary restenosis in-segment	0	2 (6.45)	0.164
Binary restenosis rate in-stent	0	1 (3.22)	0.329

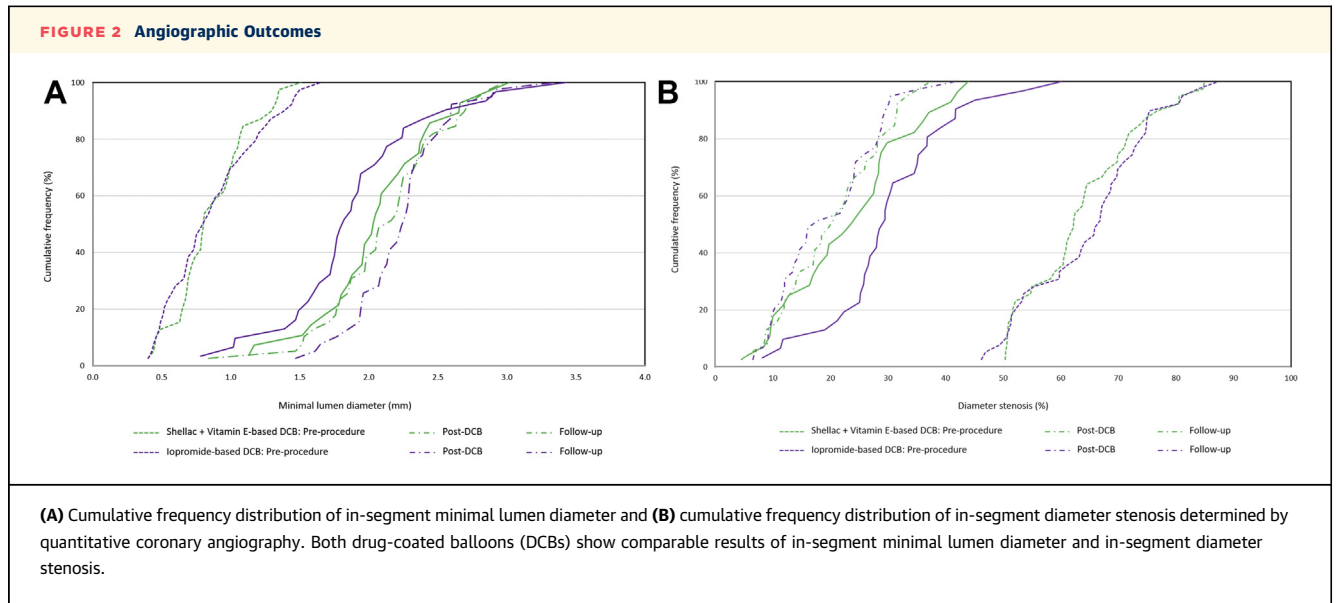
Values are mean ± SD or n (%). ^aP < 0.05.
 DCB = drug-coated balloon; DS = diameter stenosis; LL = lesion length; LLL = late lumen loss; MLD = minimal lumen diameter; RVD = reference vessel diameter.

to be effective in preventing restenosis by reducing local plasminogen activator inhibitor-1 and by directly blocking the accumulation of smooth muscle cells, which are activated when the vascular wall is damaged after balloon angioplasty.^{29,30} At the 6-month follow-up, this study yielded comparable clinical and angiographic results between the iopromide-based and shellac plus vitamin E-based DCBs. Furthermore, in-segment and in-stent DS were significantly lower at follow-up angiography with the shellac plus vitamin E-based DCB than with the iopromide-based DCB, even though the baseline and post-DCB DS were comparable. Lesion preparation, followed by local drug delivery, represents the fundamental principle of any DCB therapy.³ Clinical outcomes after ISR therapy with a DCB depend on

CENTRAL ILLUSTRATION The Primary Endpoint and the Secondary Endpoint

Jun EJ, et al. JACC: Asia. 2022;2(2):170-179.

(A) The primary endpoint of in-segment late lumen loss and (B) the secondary endpoint of major adverse cardiovascular events (MACE) at 6 months. In this multicenter, head-to-head comparison randomized trial for coronary in-stent restenosis, the shellac plus vitamin E-based drug-coated balloon (DCB) shows a comparable result to the reference iopromide-based DCB for the primary endpoint of 6 months in-segment late lumen loss. Both DCBs had similar MACE rates at 6 months. MI = myocardial infarction; TLR = target lesion revascularization.



whether the quality criteria of the DCB consensus group are met.^{31,32} The primary goal of lesion preparation is to avoid flow-limiting dissections and to reduce the degree of residual stenosis to <30%. In our study, lesion preparation was mandatory. Bailout stent implantation after DCB was not needed. Although the procedural success rate was numerically lower in the shellac plus vitamin E-based DCB group compared with the iopromide-based DCB group (82.1% vs 89.7%; $P = 0.329$), their rates of MACE at 6 months were comparable. The results of this new head-to-head comparison randomized trial of 2 different DCBs in ISR provide important insights into the available clinical evidence for the treatment strategies for ISR. To our knowledge, this is the first evidence that shellac plus vitamin E-based DCB is effective and safe, at least for the treatment of ISR at 6 months' follow-up. Following these results, we obtained regulatory approval for the device in South Korea.

STUDY LIMITATIONS. First, it was difficult to ensure sufficient power to detect differences in clinical outcomes with the relatively low sample size. Thus, no further conclusions are possible on the clinical safety or efficacy of the shellac plus vitamin E-based DCB. However, angiographic surrogate endpoints such as LLL have been widely used and validated in other trials that evaluated the safety and efficacy of DCBs. Second, although the noninferior limit was met in this study, according to the study plan, the sample calculated to prove noninferiority required 80% case follow-up. Therefore, interpretation of the results required sufficient attention. The limited sample size

and short follow-up period could have caused the absence of mortality in this study. Real-world evidence is important to confirm the clinical effectiveness of the shellac plus vitamin E-based DCB.

CONCLUSIONS

In this multicenter, head-to-head comparison, first-in-man randomized trial, the new DCB, with a shellac plus vitamin E excipient coating, shows comparable results

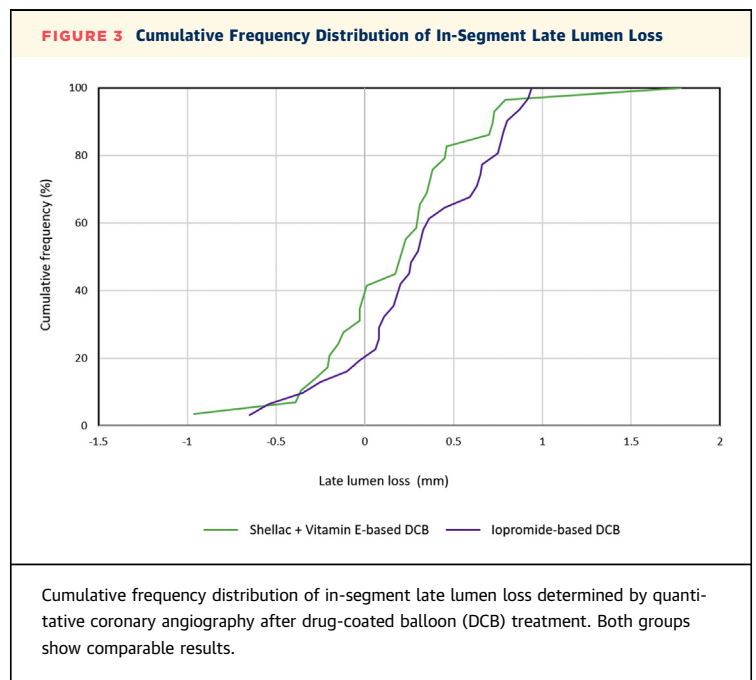


TABLE 4 Clinical Follow-Up at 6 Months

	Shellac + Vitamin E-Based DCB (n = 39)	Iopromide-Based DCB (n = 39)
Major adverse cardiovascular events	3 (7.7)	4 (10.3)
Cardiac death	0	0
Myocardial infarction	1 (2.6)	1 (2.6)
Stent thrombosis	0	1 (2.6)
Target lesion revascularization	2 (5.1)	2 (5.1)
Target vessel revascularization	2 (5.1)	2 (5.1)
Stroke	0	0
New vessel revascularization	0	0

Values are n (%).
DCB = drug-coated balloon

to the reference iopromide-coated DCB for the primary endpoint of 6-month in-segment LLL.

ACKNOWLEDGMENTS The authors thank the patients who participated in the Genoss DCB ISR South Korea trial and appreciate the dedicated efforts of the clinical research collaborators in the Genoss DCB ISR South Korea study organization, the contributions of the participating centers, and the CRO company (Synex Consulting).

FUNDING SUPPORT AND AUTHOR DISCLOSURES

This study was supported by an unrestricted research grant from GENOSS through an institutional research grant. The executive committee, together with the sponsor, designed the clinical trial. The sponsor had no role in data collection, data analysis, data interpretation, writing the manuscript, or the decision to submit

the manuscript for publication. The authors have reported that they have no relationships relevant to the contents of this paper to disclose.

ADDRESS FOR CORRESPONDENCE: Dr Eun-Seok Shin, Division of Cardiology, Department of Internal Medicine, Ulsan University Hospital, University of Ulsan College of Medicine, 877 Bangeojinsunhwan-doro, Dong-gu, Ulsan 682-714, South Korea. E-mail: sesim1989@gmail.com. Twitter: [@sesim1989](https://twitter.com/sesim1989).

PERSPECTIVES

COMPETENCY IN MEDICAL KNOWLEDGE: DCBs offer an effective treatment for ISR. With comparable clinical results, they do not require the implantation of an additional metal layer and may lead to better long-term results. In the present multicenter, head-to-head, randomized trial, the shellac plus vitamin E-based DCB was noninferior to the standard reference iopromide-coated DCB for the primary endpoint of 6-month in-segment LLL, with comparable clinical outcomes at 6 months.

TRANSLATIONAL OUTLOOK: Longer-term follow-up and large-scale studies with primary clinical endpoints are needed to evaluate clinical outcomes with the shellac plus vitamin E-based DCB in the treatment of coronary ISR. Furthermore, this new DCB should also be investigated in de novo lesions.

REFERENCES

- Windecker S, Neumann FJ, Jüni P, Sousa-Uva M, Falk V. Considerations for the choice between coronary artery bypass grafting and percutaneous coronary intervention as revascularization strategies in major categories of patients with stable multivessel coronary artery disease: an accompanying article of the task force of the 2018 ESC/EACTS guidelines on myocardial revascularization. *Eur Heart J*. 2019;40:204-212.
- Kleber FX, Mathey DG, Rittger H, Scheller B, German Drug-eluting Balloon Consensus Group. How to use the drug-eluting balloon: recommendations by the German consensus group. *EuroIntervention*. 2011;7(Suppl K):K125-K128.
- Alfonso F, Scheller B. State of the art: balloon catheter technologies-drug-coated balloon. *EuroIntervention*. 2017;13:680-695.
- Rowinsky EK, Donehower RC. Paclitaxel (taxol). *N Engl J Med*. 1995;332:1004-1014.
- Clever YP, Cremers B, Krauss B, et al. Paclitaxel and sirolimus differentially affect growth and motility of endothelial progenitor cells and coronary artery smooth muscle cells. *EuroIntervention*. 2011;7(Suppl K):K32-K42.
- Chen Y, Gao L, Qin Q, et al. RESTORE ISR China Investigators. Comparison of 2 different drug-coated balloons in in-stent restenosis: the RESTORE ISR China Randomized Trial. *J Am Coll Cardiol Interv*. 2018;11:2368-2377.
- Ali RM, Abdul Kader MASK, Wan Ahmad WA, et al. Treatment of coronary drug-eluting stent restenosis by a sirolimus-or paclitaxel-coated balloon. *J Am Coll Cardiol Interv*. 2019;12:558-566.
- Eshtehardi P, Adorjan P, Togni M, et al. Iatrogenic left main coronary artery dissection: incidence, classification, management, and long-term follow-up. *Am Heart J*. 2010;159:1147-1153.
- Mehran R, Dangas G, Abizaid AS, et al. Angiographic patterns of in-stent restenosis: classification and implications for long-term outcome. *Circulation*. 1999;100:1872-1878.
- Cutlip DE, Windecker S, Mehran R, et al. Academic Research Consortium. Clinical end points in coronary stent trials: a case for standardized definitions. *Circulation*. 2007;115:2344-2351.
- Xu B, Gao R, Wang J, et al. PEPCAD China ISR Trial Investigators. A prospective, multicenter, randomized trial of paclitaxel-coated balloon versus paclitaxel-eluting stent for the treatment of drug-eluting stent in-stent restenosis: results from the PEPCAD China ISR trial. *J Am Coll Cardiol Interv*. 2014;7:204-211.
- Rittger H, Brachmann J, Sinha AM, et al. A randomized, multicenter, single-blinded trial comparing paclitaxel-coated balloon angioplasty with plain balloon angioplasty in drug-eluting stent restenosis: the PEPCAD-DES study. *J Am Coll Cardiol*. 2012;59:1377-1382.
- Habara S, Mitsudo K, Kadota K, et al. Effectiveness of paclitaxel-eluting balloon catheter in patients with sirolimus-eluting stent restenosis. *J Am Coll Cardiol Interv*. 2011;4:149-154.
- Unverdorben M, Vallbracht C, Cremers B, et al. Paclitaxel-coated balloon catheter versus paclitaxel-coated stent for the treatment of coronary in-stent restenosis: the three-year results of the PEPCAD II ISR study. *EuroIntervention*. 2015;11:926-934.
- Moussa ID, Mohanany D, Saucedo J, et al. Trends and Outcomes of Restenosis After

Coronary Stent Implantation in the United States. *J Am Coll Cardiol*. 2020;76:1521-1531.

16. Alfonso F, Byrne RA, Rivero F, Kastrati A. Current treatment of in-stent restenosis. *J Am Coll Cardiol*. 2014;63:2659-2673.

17. Siontis GC, Stefanini GG, Mavridis D, et al. Percutaneous coronary interventional strategies for treatment of in-stent restenosis: a network meta-analysis. *Lancet*. 2015;386:655-664.

18. Scheller B, Hehrlein C, Bocksch W, et al. Treatment of coronary in-stent restenosis with a paclitaxel-coated balloon catheter. *N Engl J Med*. 2006;355:2113-2124.

19. Byrne RA, Neumann FJ, Mehilli J, et al, ISAR-DESIRE 3 investigators. Paclitaxel-eluting balloons, paclitaxel-eluting stents, and balloon angioplasty in patients with restenosis after implantation of a drug-eluting stent (ISAR-DESIRE 3): a randomised, open-label trial. *Lancet*. 2013;381:461-467.

20. Baan J, Claessen BE, Boerlage-van Dijk K, et al. A randomized comparison of paclitaxel-eluting balloon versus everolimus-eluting stent for the treatment of any in-stent restenosis: the DARE trial. *J Am Coll Cardiol Interv*. 2018;11:275-283.

21. Xu B, Qian J, Ge J, et al, PEPCAD China ISR investigators. Two-year results and subgroup analyses of the P EPCAD China in-stent restenosis trial: A prospective, multicenter, randomized trial for the treatment of drug-eluting stent in-stent restenosis. *Catheter Cardiovasc Interv*. 2016;87:624-629.

22. Kufner S, Cassese S, Valeskini M, et al, ISAR-DESIRE 3 Investigators. Long-term efficacy and safety of paclitaxel-eluting balloon for the treatment of drug-eluting stent restenosis: 3-year results of a randomized controlled trial. *J Am Coll Cardiol Interv*. 2015;8:877-884.

23. Scheller B, Vukadinovic D, Jeger R, et al. Survival after coronary revascularization with paclitaxel-coated balloons. *J Am Coll Cardiol*. 2020;75:1017-1028.

24. Madhavan MV, Kirtane AJ, Redfors B, et al. Stent-related adverse events >1 year after percutaneous coronary intervention. *J Am Coll Cardiol*. 2020;75:590-604.

25. Lansky A, Grubman D, Scheller B. Paclitaxel-coated balloons: a safe alternative to drug-eluting stents for coronary in-stent restenosis. *Eur Heart J*. 2020;41(38):3729-3731.

26. Giacoppo D, Alfonso F, Xu B, et al. Paclitaxel-coated balloon angioplasty vs. drug-eluting stenting for the treatment of coronary in-stent restenosis: a comprehensive, collaborative, individual patient data meta-analysis of 10 randomized clinical trials (DAEDALUS study). *Eur Heart J*. 2020;41:3715-3728. Published correction appears in *Eur Heart J*. 2020;41(38):3728.

27. Stella PR, Belkacemi A, Waksman R, et al. Valentine Investigators. The Valentines Trial: results of the first one week worldwide multicentre enrolment trial, evaluating the real world usage of the second generation DIOR paclitaxel drug-

eluting balloon for in-stent restenosis treatment. *EuroIntervention*. 2011;7:705-710.

28. Pósa A, Nyolczas N, Hemetsberger R, et al. Optimization of drug-eluting balloon use for safety and efficacy: evaluation of the 2nd generation paclitaxel-eluting DIOR-balloon in porcine coronary arteries. *Catheter Cardiovasc Interv*. 2010;76:395-403.

29. Konneh MK, Rutherford C, Li SR, Anggård EE, Ferns GA. Vitamin E inhibits the intimal response to balloon catheter injury in the carotid artery of the cholesterol-fed rat. *Atherosclerosis*. 1995;113:29-39.

30. Orbe J, Rodriguez JA, Calvo A, et al. Vitamins C and E attenuate plasminogen activator inhibitor-1 (PAI-1) expression in a hypercholesterolemic porcine model of angioplasty. *Cardiovasc Res*. 2001;49:484-492.

31. Jeger RV, Eccleshall S, Wan Ahmad WA, et al, International DCB Consensus Group. Drug-coated balloons for coronary artery disease: third report of the International DCB Consensus Group. *J Am Coll Cardiol Interv*. 2020;13:1391-1402.

32. Her AY, Shin ES, Bang LH, et al. Drug-coated balloon treatment in coronary artery disease: recommendations from an Asia-Pacific Consensus Group. *Cardiol J*. 2021;28(1):136-149.

KEY WORDS cardiovascular events, drug-coated balloon, in-segment late lumen loss, major adverse