

Review of Literature on Intraductal Meibomian Gland Probing with Insights from the Inventor and Developer: Fundamental Concepts and Misconceptions

Natalia A Warren¹, Steven L Maskin²

¹Not A Dry Eye Foundation, Daytona Beach, FL, USA; ²Dry Eye and Cornea Treatment Center, Tampa, FL, USA

Correspondence: Steven L Maskin, Dry Eye and Cornea Treatment Center, 3001 Swann Avenue, Tampa, FL, 33609, USA, Tel +1 8138750000, Email drmaskin@gmail.com

Abstract: Obstructive Meibomian gland dysfunction (MGD) affects millions of patients around the world. Its effective treatment with intraductal meibomian gland probing (MGP), was first reported in 2010. Since then, MGP has provided relief to thousands of patients globally suffering with refractory MGD. The purpose of Meibomian gland probing is restoring the integrity of the gland's central duct by entering the gland through the natural orifice, releasing fixed obstruction thought to be periductal fibrosis, thereby establishing and/or confirming the patency of the duct, and concurrently equilibrating intraductal pressure as well as promoting gland functionality with meibum production. There may or may not be immediate secretion of meibum upon successful restoration of ductal integrity depending on the gland's state of function and degree of atrophy. One double-blind placebo-controlled study has been conducted and, with the accumulated evidence of over 12 other peer reviewed articles in the scientific literature, overwhelmingly indicates that MGP is a safe and effective treatment for the MGD patient refractory to prior standard care and as a first-line treatment. This paper describes relevant fundamental concepts, dispels commonly held misconceptions, and provides an objective review of the current understanding and effectiveness of MGP for the treatment of obstructive MGD. Our analysis will better equip clinicians to draw informed conclusions about both subjective and objective findings reported in MGP studies and researchers to design future robust studies that provide meaningful results.

Keywords: meibomian gland dysfunction, MGD, obstructive MGD, MGP clinical trial, MGP studies, dry eye

Introduction

Meibomian gland probing (MGP) was first introduced in 2010 by author SLM.¹ This innovative treatment targets firm, focal, fixed, unyielding obstruction thought to be secondary to periductal fibrosis, the apparent root cause of Meibomian gland dysfunction (MGD), and provides evidence of its presence while also confirming or restoring patency of gland ducts.² MGP has been used to successfully treat patients around the world. Independent studies on the efficacy of MGP have been conducted in the United States,^{3–5} China,^{6–8} Turkey,^{9,10} India,¹¹ Cuba,¹² Japan,¹³ Mexico,¹⁴ and Russia.¹⁵

One previous literature review summarized study results of a subset of these studies, namely those available in English.¹⁶ However, the review had several significant limitations.¹⁷

Our paper provides fresh insights from the inventor and developer of MGP into the reviewed MGP research studies and dispels misconceptions that have entered the literature. We seek to establish a foundation for clinicians to draw informed conclusions about both objective and subjective findings reported in those and future MGP studies and to aid researchers studying MGP in designing robust studies that produce meaningful results.

Methods

Ten published peer reviewed studies from the 2021 review¹⁶ are included in our review.^{3-5,7-11,13,14} SLM, the author and inventor of MGP¹ did not provide any guidance or input toward these studies. Studies published by SLM^{1,2,18-21} and included in the 2021 review,¹⁶ are not reviewed here to avoid suggestion of bias.

Procedure

The MGP procedure¹⁹ has been previously described by the author as follows (shown in Figure 1):²

One drop of topical 0.5% tetracaine hydrochloride (Bausch and Lomb, Tampa, FL) is placed in the inferior fornix, followed by placing a bandage contact lens over the cornea. If nerve block is used for anesthetic,

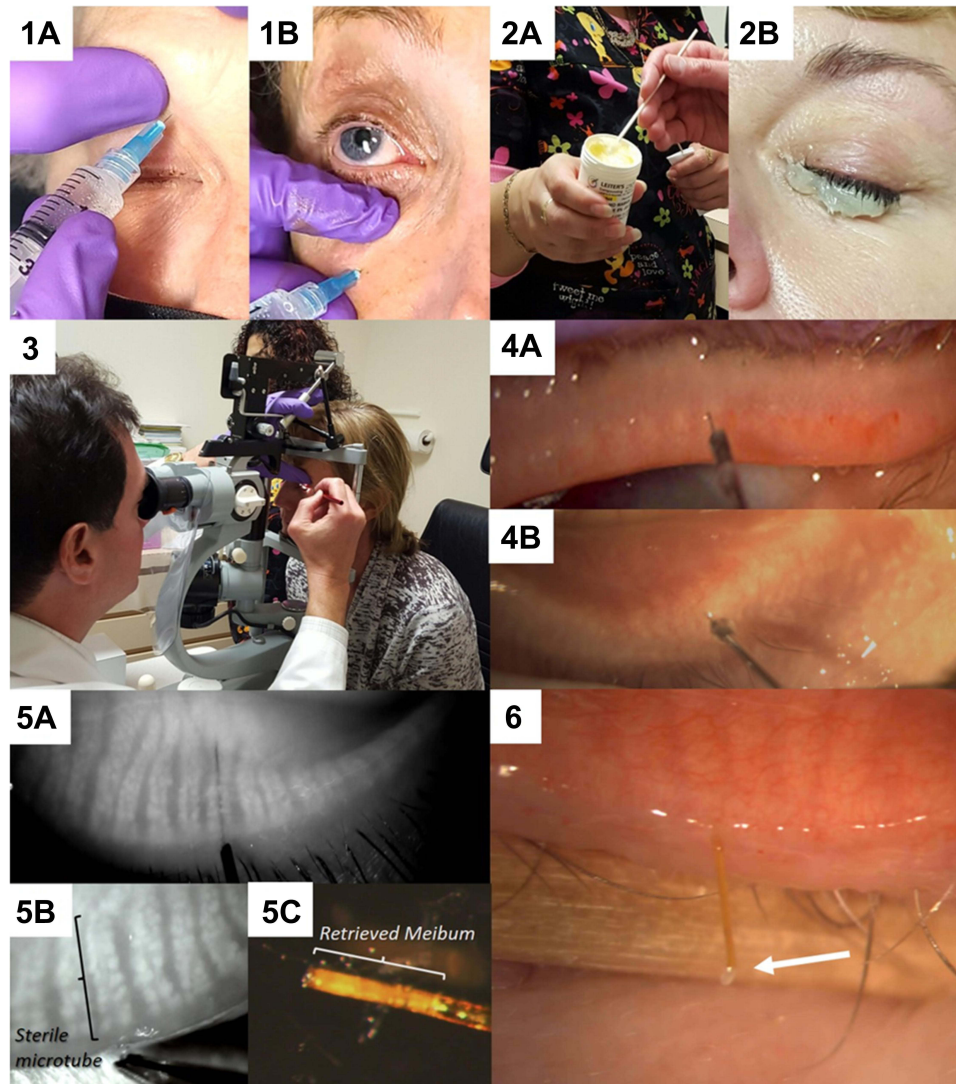


Figure 1 (1a and b) Performing supraorbital and infraorbital nerve block using JBP 33 gauge 4 mm long nanoneedles. (2a and b) Jojoba anesthetic ointment consisting of 8% lidocaine and 25% jojoba is taken from a refrigerated jar and applied to the lid margin for 10 minutes. This may be repeated. (3) The probing set-up at the slit lamp with an assistant to steady the patient for good visualization. (4) View through the slit lamp microscope of probing upper (a) and lower (b) lid Meibomian glands. (5) Meibography guided probing using the Mediworks S390L WVDR FireFly Digital Slit Lamp from Eyeefficient (Aurora, Ohio), demonstrating a 4 mm probe within the central duct (a), a sterile MicroTube Stent within the central duct for retrieval of meibum (b) and the retrieved meibum inside the MicroTube removed from within the gland (c). Reproduced from Maskin SL, Alluri S. Meibography guided intraductal meibomian gland probing using real-time infrared video feed. *Br J Ophthalmol.* 2020;104(12):1676; with permission from BMJ Publishing Group Ltd.²¹ (6) An alternative approach to obtaining a virgin sample of meibum by allowing the meibum to travel through the MicroTube Stent for collection and analysis. Arrow shows a drop of meibum at the distal end of the MicroTube Stent.²²

Notes: 1a-b, 2a-b, 3, 4a-b: Courtesy of Steven L Maskin MD; 5a-c: Reproduced from Maskin SL, Alluri S Meibography guided intraductal meibomian gland probing using real-time infrared video feed *British Journal of Ophthalmology* 2020;104:1676–1682 with permission from BMJ; 6: Reproduced from Maskin, SL, Warren NA. *Your Dry Eye Mystery Solved: Reversing Meibomian Gland Dysfunction, Restoring Hope.* Yale University Press, 2022 with permission from Yale University Press.

supraorbital, supratrochlear and infraorbital nerves are anesthetized using 2% Lidocaine with epinephrine. One mL is injected into each site using JBP 33 gauge nanoneedles of 4mm length (Henry Schein, Inc) after appropriate site preparation with povidone-iodine. Topical anesthetic ointment consisting of 8% lidocaine with 25% jojoba in a petrolatum ointment base (O'Brien Pharmacy, Mission, KS) is also applied to the inferior lid margin. The eye is then closed for 15 minutes. After 15 minutes, one additional drop of topical tetracaine is placed in the eye. The patient is then positioned at the slit lamp and the MG orifices are visualized and examined. To begin the procedure, first the angle of entry is determined with a 1-mm long stainless steel sterile intraductal MG probe (Rhein Medical, a division of Katena Products, Denville, NJ). The probe is inserted into each orifice, perpendicular to the lid margin using a dart-throwing motion. As the probe passes through the orifice lumen and into the distal duct, it typically encounters resistance. The resistance is characterized as firm, fixed, focal and unyielding, which requires additional probing force to relieve, analogous to relief of canalicular fibrosis with a punctal dilator. Relieving the obstruction creates a tactile sensation of pressure release and an audible firm pop (FP) and/or firm gritty (FG) (multiple pops) sounds which can be heard by both the patient and physician. When the tight band of contracting periductal fibrosis releases and resistance gives way, the probe can advance freely further into and then out of the duct when it is retracted.

The audible FP and gritty sounds and sensations are thought to be indicative of fibrosis' severity, extent, and position along the lumen.² For example, a single audible FP is typically accompanied by a single focus of pressure release, whereas an audible FG is typically accompanied by multiple foci of pressure release. In addition, variation in the intensity level of tactile intraductal resistance at times can be heard across the room, suggesting advanced fibrosis. Both the FP and FG sounds occur as sudden bursts, rather than as prolonged sounds, suggesting release of narrow bands of fibrosis. In fact, the multiple individual FP sounds that make up a FG, can occur immediately after each other in rapid succession or after a short delay as the probe advances through span of non-strictered duct lumen.

Less commonly, a mild back pressure or "soft" resistance, which is not fixed, not firm, and does not easily yield, may be noted. This mild pressure allows the probe to advance into the lumen without significant additional mechanical pressure and does not generate an audible sound. It does, on the other hand, "drag" on the "to and fro" movement of the wire probe. Soft resistance is not focal in contrast to the firm resistance which characteristically is focal or multifocal. Infrequently, there is a lack of resistance designated as no resistance where the probe enters the orifice and duct without any resistance or drag.

Imaging guided probing with use of infrared video meibography can dynamically visualize real time probing and tube devices within the central duct.²¹

Results from Literature

Summary of Previous Independent Study Results

Table 1 summarizes the results of independent peer-reviewed studies^{3-5,7-11,13,14} included in the 2021 review.¹⁶

The table includes details about the study designs and describes deviations from established MGP protocol.¹⁹ The table also lists p-values and improvements in subjective symptoms and objective signs in the MGP treatment group compared to control, baseline or other treatment. (SLM's published studies are not included in the table to avoid any suggestion of bias.)

Note that all patients were refractory to prior standard pre-study treatment and treatment protocols varied widely. Nevertheless, all studies reported that either subjective symptoms, objective signs, or both showed improvement in MGP-treated patients. Furthermore, no adverse events were reported by MGP-treated patients (Table 1).

Effect on Subjective and Objective Measures

As summarized in Table 1, investigators^{3-5,7-11,13,14} reported improvement on these subjective measures in MGP-treated patients: Symptom Assessment in Dry Eye questionnaire (SANDE),³ Ocular Surface Disease Index (OSDI),^{3,5,9-11}

Standard Patient Evaluation of Eye Dryness Questionnaire (SPEED),⁷ various symptoms,^{4,7,8} Dry Eye-Related Quality-of-Life Score (DEQS),¹³ visual acuity,¹⁴ comfort when blinking,¹⁴ and photophobia.¹⁴

Also as summarized in Table 1, investigators^{5,7-11,13,14} reported improvement on these objective measures in MGP-treated patients: lid tenderness,⁷ tear break-up time (TBUT),^{7-11,13,14} lid margin abnormalities,⁸ meibum grade,^{7,8} corneal fluorescein stain (CFS),⁷ Schirmer 1 test,⁹ fluorescein stain (FS),⁸ ocular surface Oxford score,⁹ meibum quality,⁹ meibum expressibility,⁹ gland blockage,⁵ keratitis,⁵ thickened lids,⁵ meibum lipid level,¹³ meibum viscosity,¹³ lipid interferometry,¹³ conjunctival hyperemia,¹⁰ lid margin vascularization,^{7,10} orifice abnormality,⁷ and lid margin congestion.¹¹

Table 1 Summary of Independent MGP Studies and Their Result

Study ^A	Date	Design	Refractory to Prior Treatment ^B	Follow-Up ^C	Study Treatment ^D	n= Pts (Eyes) [Lids] {GInd} ^E	Improvement in MGP Treatment Group Compared to Control, Baseline, or Other Treatment				
							Symptoms (Subjective)	Signs (Objective) ^F			
Kheirkhah et al ³	2020	DB RCT	3 Mo LH, WC, Top, Syst	1 Mo	MGP+Bleph+PT ^{3a,3b,3c,3d,3e,3f}	13 (26)	Compared to Baseline				
							SANDE p=0.002 OSDI p=0.02	No significance ^{3g,3h,3i}			
					MGP+GenT+PT ^{3a,3b,3c,3d,3e,3f}	14 (28)	Compared to Baseline				
							SANDE p=0.01	No significance ^{3g,3h,3i}			
					Control: Sham MGP +GenT+PT ^{3b,3d,3e,3f}	14 (28)	Compared to Baseline				
							No significance	LT p=0.02 ^{3g,3h,3i}			
Huang et al ⁷	2019	SB RCT	1 Yr WC, Mas, AT	12 Wk	MGP ^{7a,7b,7c,7d,7e}	15 (30)	Compared to Baseline				
							SPEED p<0.001	TBUT p<0.001; >5 sec: 36.67%			
							Relief: 100% of pts	CFS p<0.001			
							Worse symptoms: 0% of pts	MG p<0.001			
							SPEED ≤9, 26.67% pts	LMV p=0.001			
								OA p<0.001			
								LT p=0.001			
							Compared to IPL				
								LT p<0.001			
							6 Mo	Retreat required	3, 20%		
							9 Wk	IPL (3 sessions)+AT daily ^{7f}	14 (28)	Compared to Baseline	
										SPEED p<0.001	TBUT p<0.001; >5 sec: 17.86%
										Relief: 85.7% of pts	CFS p<0.001
										Worse symptoms: 14.8% of pts	MG p=0.003
SPEED ≤9, 14.29% pts	LMV p=0.006										
	OA p<0.001										
	LT p=0.003										
6 Mo	Retreat required (3 additional sessions)	5, 35.7%									

(Continued)

Table I (Continued).

Study ^A	Date	Design	Refractory to Prior Treatment ^B	Follow-Up ^C	Study Treatment ^D	n= Pts (Eyes) [Lids] {GInd} ^E	Improvement in MGP Treatment Group Compared to Control, Baseline, or Other Treatment	
							Symptoms (Subjective)	Signs (Objective) ^F
				12 Wk	MGP+IPL ^{7a,7b,7c,7d,7f}	14 (28)	Compared to Baseline	
				SPEED p<0.001	TBUT p<0.001; >5 sec: 92.9%			
				SPEED ≤9, 64.29% pts	CFS p<0.001			
					MG p<0.001			
					LMV p=0.001			
					OA p<0.001			
					LT p<0.001			
				Compared to MGP				
				SPEED p=0.012	TBUT p=0.012			
					MG p<0.001			
					LMV p<0.001			
					OA p=0.016			
				Compared to IPL				
				SPEED p=0.003	TBUT p=0.003			
	MG p=0.002							
	LMV p=0.002							
	LT p<0.001							
				6 Mo	Retreat required	0%	Compared to MGP	
				SPEED p=0.01				
				Compared to IPL				
				SPEED p=0.004				
Ma and Lu ⁸	2016	OL RCT	WC, Mas, AT	1 Mo	MGP+Top Ster 3x/day +PT ^{9a,8b,8c}	25 (46)	Compared to Baseline	
							Var Symp p<0.01	LM p<0.05
								MG p<0.05
							Relief in 1 day: 76% of pts (19/25)	TBUT p<0.05
								FS p<0.05
								Immediate release of meibum: (38/46)
							Compared to Control	
							Var Symp p<0.001	LM p<0.001 ^{8d,8e}
MG p <0.001 ^{8d,8f}								
TBUT p=0.0293 ^{8d,8g}								

(Continued)

Table I (Continued).

Study ^A	Date	Design	Refractory to Prior Treatment ^B	Follow-Up ^C	Study Treatment ^D	n= Pts (Eyes) [Lids] {GInD} ^E	Improvement in MGP Treatment Group Compared to Control, Baseline, or Other Treatment	
							Symptoms (Subjective)	Signs (Objective) ^F
					Control: Top Ster 3x/day +PT	24 (45)	Compared to Baseline	
							Var Symp p<0.01	LM p<0.05 ^{8d,8e,8f,8g,8h} MG p<0.05
							Relief in 1 day: 0% of pts (0/24)	TBUT p<0.05 FS p<0.05
Incekalan et al ⁹	2019	OL RCT	AT	3 Mo	MGP+CT ^{9a,9b,9c,9d}	20 (40) {8 lower lid, 12 upper lid}	Compared to Baseline	
							OSDI p<0.05	Sch I p<0.05
								TBUT p<0.05
								OS p<0.05
								MQ p<0.05
					ME p=0.0001			
					Retreat	0% ^{9e}	Compared to Control	
							OSDI faster p=0.0001	Sch I faster p=0.0001
								TBUT faster p=0.014
								OS faster p=0.0001
	MQ faster p=0.034 ME faster p=0.0001							
CT: WC, Mas, LH, AT, CP, O3, OAZ.	20 (40)	Compared to Baseline						
		OSDI p<0.05	Sch I p<0.05					
			TBUT p<0.05					
			OS p<0.05					
			MQ p<0.05					
ME p=0.0001								
Wladis ⁵	2012	PL	AT, OA, Diet	6 Mo	MGP ^{5a,5b}	10 (20) [40]	Compared to Baseline	
							OSDI p<0.05	Decreased gland blockage, keratitis, thickened lids ^{5c}
							(Retreat: 0%)	0%
Fermon et al ¹⁴	2015	PL	CT	6 Mo	MGP ^{14a,14b,14c,14d,14e}	16 (16)	Compared to Baseline	
							VA p<0.001 ^{14g}	TBUT p<0.0001 ^{14g}
							BICO p=0.008 ^{14g}	
							Pho p<0.001 ^{14g}	
					Retreat ^{14f}	2, 12.5%		

(Continued)

Table 1 (Continued).

Study ^A	Date	Design	Refractory to Prior Treatment ^B	Follow-Up ^C	Study Treatment ^D	n= Pts (Eyes) [Lids] {Gland} ^E	Improvement in MGP Treatment Group Compared to Control, Baseline, or Other Treatment	
							Symptoms (Subjective)	Signs (Objective) ^F
Nakayama et al ¹³	2015	PL	2.5, 3, or 8 Yr HA, DS, Re, LH, MCG, PP, Of, RC, Lv, Ox, or SSRI	1 Mo	MGP ^{13a,13b}	3 (3) [6] {60}	Compared to Baseline	
							DEQS: 2 cases improved ^{13c}	MLL, MV, LI: All cases improved TBUT: 2 cases improved
Sik Sarman et al ¹⁰	2016	PL	6 Mo CT, Mas	3 Mo	MGP ^{10a,10b,10c,10d} + CT ^{10e}	30 (58) [116]	Compared to Baseline	
							OSDI: significant ^{10h}	TBUT p<0.001
								CH p<0.0001
								LMV p=0.004
Treatment: 1x	8, 26.7%							
Retreat: 2x ^{10f,10g}	18, 60%							
Retreat: 3x ^{10f,10g}	3, 10%							
Retreat: 4x ^{10f,10g}	1, 3.3%							
Nirupama et al ¹¹	2019	PL	8 Wk CT	1 Mo	MGP ^{11a, 11b, 11c} +CT ^{11d}	30	Compared to Baseline	
							OSDI: 73% of pts (22/30) ^{11e}	TBUT: 73% of pts (22/30)
								LMC: 73% of pts (22/30)
							3 Mo	Retreat
6 Mo						OSDI p=0.0001; 93.3% of pts (28/30) ^{11e}	TBUT p=0.0001; 93.3% of pts (28/30)	
							LMC: 100% of pts (30/30)	
Syed and Sutula ⁴	2017	RCR	4 Wk WC, LH, AI	1-64 Wk ^{4a}	MGP ^{4b,4c,4d}	41 [70]	Compared to Baseline	
				1 Wk			Rapid symptom improvement: 91.4% of lids [64/70] ^{4f}	
				52 Wk	Retreat	[1/13]=7.7% ^{4e}		

Notes: General Comments:

- ^AAll of the studies employed different methods and no study followed developer's published and recommended probing protocol¹⁹ exactly.
- ^BAll of the subjects in each study were refractory to standard treatment or were administered standard treatment, some for at least 4 weeks (Syed and Sutula⁴) and one up to 8 years (Nakayama et al¹³) prior to enrolling in the study. Therefore, the baseline of each study, at a minimum, is prior failed treatment. (Suggesting otherwise by the review authors¹⁶ is a significant error and oversight in their analysis.)
- ^CNote the short duration of many of the studies. SLM studies have shown that patients with lid tenderness experience relief instantaneously upon probing, whereas those with other symptoms resolve over 2-3 months as gland functionality resumes gradually after probing. Patients who were reprobed 1 week or 1 month after initial probing may have been reprobed prematurely, or may have suffered with untreated comorbid diseases that led to gland re-obstruction.
- ^DStudy protocols were significantly different from each other and from the developer's published and recommended protocol.¹⁹ Some investigators used probes of their own design and all of these were larger in diameter than Maskin probes. No study started probing with a 1mm probe to determine the angle of entry. Some studies used probes of only 1 length which limited the ability to probe deeper within the gland where, glands with MGD may remain obstructed with periductal fibrosis. Adjunctive treatment varied from study to study and was not necessarily based on an individual patient's specific symptoms or comorbidities, but instead was prescribed to all patients. Therefore, patients may have been prescribed unnecessary treatment or treatment to which they were sensitive, or not prescribed needed adjunctive treatment for comorbidities.
- ^EIn at least one study both lids were not treated, and in some studies not all glands in a lid were treated, even though both lids and all glands contribute to both signs (eg TBUT) and symptoms (eg gritty, burning) of MGD.
- ^FIn some cases we include the finding, but not the p-value if it was not reported in the study.

Kheirkhah et al³

- ^{3a}Only upper lids were probed.
- ^{3b}2% lidocaine jelly was used to anesthetize lids. In cases where anesthesia was inadequate, MGP-treated lids were injected with anesthetic which can cause microtrauma and lid tenderness unresolved at the time of follow-up, whereas sham-MGP lids were not injected.
- ^{3c}Randomly assigning patients to the MGP + Blephamide or MGP + GenTeal groups ignores adjunctive treatment that patients would actually need and would influence patient outcomes considerably.
- ^{3d}During the course of the study, patients may have developed sensitivity to Blephamide or GenTeal ointment, which would have influenced patient outcomes.

- ^{3e}Patients continued prior medications (minus steroids) as well as warm compresses and lid hygiene.
- ^{3f}MGP + GenTeal lids injected with anesthesia prior to treatment may have resulted in micro trauma to lids and resulting tenderness.
- ^{3g}Because only the upper lid was treated, but both upper and lower lids can contribute to symptoms, results may be skewed.
- ^{3h}Lid tenderness evaluation is not clear raising several questions. Was topical anesthetic used prior to evaluation to prevent confounding findings from a tender ocular surface? How did the investigators manage focal versus regional versus whole lid tenderness? Were these findings identified and if so, how were they managed statistically? Were the findings combined or was there an attempt to differentiate among types?
- ³ⁱThe investigators compared results of treatment or sham treatment to baseline only, not across groups.

Syed and Sutula⁴

- ^{4a}According to the investigators, "The follow-up period ranged from 1 to 64 weeks (mean 12.9 weeks).
- ^{4b}In addition to administering topical anesthetic (topical proparacaine to the cornea, a cotton pledget soaked in 4% lidocaine and placed in the fornix) the investigators also injected 1% lidocaine with epinephrine "using a transconjunctival approach into the fornix centrally, medially, and laterally. Supplemental subcutaneous injection near the eyelid margin" was also injected. The MGP developer's protocol-recommended¹⁹ topical anesthetic is a topical jojoba anesthetic ointment containing 8% lidocaine.
- ^{4c}Investigators started with a 2mm probe to "dilate each orifice sequentially" followed by use of the 4mm probe. A short, 1mm length probe was not used initially to locate the angle of entry.
- ^{4d}According to the investigators, probing was well tolerated and there were no complications.
- ^{4e}52 weeks after initial treatment, one of the 13 long-term follow up patients underwent retreatment of 1 eyelid due to a return of symptoms.
- ^{4f}According to the investigators, "Sixty-four treatments (91.4%) resulted in subjective relief immediately after the procedure, typically within 1 week. These patients reported an improvement or resolution of their primary symptoms. The remaining 6 cases (8.6%) did not result in immediate symptom relief".

Wladis⁵

- ^{5a}For anesthesia, lids were injected with 2% lidocaine with epinephrine.
- ^{5b}Maskin probes were not used. Instead, the investigator used a hyfrecator tip (without applying electrical current) of unreported diameter and length. The hyfrecator tip is designed to destroy superficial tissue or control bleeding, and is not designed and dimensioned specifically for passing through the fixed resistance and scar tissue encountered with Meibomian gland probing. Thus, probing with a hyfrecator tip may lead to excessive trauma and hemorrhage.
- ^{5c}After probing, all patients reported improvement in "discomfort, visual effect, and tearing, and documented a decreased need for topical lubrication...Nine of ten patients (90%) were able to successfully discontinue the use of doxycycline after their 1-month postoperative visit. No complications were noted through a 6-month follow-up period, and no patients required repeat probing".

Huang et al⁷

- ^{7a}The investigators did not use Maskin probes. Probes were 4.5 mm in length and the blunt end was 0.12 mm in diameter (compared to 0.076 mm diameter Maskin probes). The hollow tube for lavage was 2.0 mm in length and had a wider diameter 0.16 mm (compared to the Maskin MicroTube 0.110 mm diameter). A single length and larger diameter probe can increase discomfort and hemorrhage.
- ^{7b}4% lidocaine was injected into the upper and lower lids which caused subcutaneous bruising in several patients and can cause persistent lid pain potentially skewing treatment results.
- ^{7c}A short, 1mm length probe was not used initially to locate the angle of entry.
- ^{7d}After probing glands were expressed with a paddle, rather than a Maskin roller.
- ^{7e}A hollow tube was used to lavage glands with 0.1% dexamethasone and 0.25% amikacin. Tobradex ointment was also applied on the day of probing.
- ^{7f}A single IPL treatment consists of three separate IPL sessions.

Ma and Lu⁸

- ^{8a}Maskin probes were not used. Instead, investigators used a 100- μ m-diameter wire not dimensioned specifically for the Meibomian gland which could make finding the angle of entry difficult.
- ^{8b}Only 2mm-long probes were used. Probes of this length can buckle causing difficulty in finding the angle of entry. A 1mm Maskin probe is shorter and stiffer, dimensioned and designed to facilitate finding the angle of entry.
- ^{8c}A 0.25% oxybuprocaine hydrochloride drop was applied to the inferior conjunctival fornix. The MGP developer's protocol-recommended¹⁹ topical anesthetic is a topical jojoba anesthetic ointment containing 8% lidocaine.
- ^{8d}The investigators stated, "In group I, [MGP + topical steroid] 76% (19/25) of the patients had symptom relief 1 day after probing before the administration of any additional medical treatment. However, in group II [topical steroid alone], there was no significant improvement on the first day without any additional medical treatment".
- ^{8e}The investigators stated, "At 1 week and 1 month, all scores in group I were lower than those in group II".
- ^{8f}The investigators stated, "Abnormalities of the lid margin were significantly improved in both groups after 1 week and 1 month of treatment, especially in lid margin congestion and orifice plugs. There were significant differences in the lid margin score 1 month after treatment between groups...".
- ^{8g}The investigators stated, "The meibum grade significantly improved in both groups, and the improvement was more significant in group I than in group II at the 1-week and 1-month follow-up visits".
- ^{8h}The investigators stated, "One month after treatment, the increase in TBUT in group I was more significant than that of group II".

Incekalan et al⁹

- ^{9a}5 glands in the upper lid and 5 glands in the lower lid were assessed for expressibility. Meibum quality was assessed in the central 8 glands of the lower lid.
- ^{9b}Not all glands in a lid were probed. 8 glands in the lower lid and 12 glands in the upper lid were probed.
- ^{9c}Maskin probes were not used.
- ^{9d}A 0.5% proparacaine hydrochloride drop was dropped into the inferior conjunctival fornix. The MGP developer's protocol-recommended¹⁹ topical anesthetic is a topical jojoba anesthetic ointment containing 8% lidocaine.
- ^{9e}No patients required retreatment at 3 months.

Sik Sarman, et al¹⁰

- ^{10a}Proparacaine hydrochloride 0.5% was used as an anesthetic. The MGP developer's protocol-recommended¹⁹ topical anesthetic is a topical jojoba anesthetic ointment containing 8% lidocaine.
- ^{10b}Maskin probes were not used.
- ^{10c}Probing started with a 2-mm length probe. A short, 1mm length probe was not used initially to locate the angle of entry.
- ^{10d}Longer probes (2.5-, 4-, or 6-mm length) were only used if resistance was met with the 2mm probe. However, glands may present with no resistance within the distal 2 mm, but deeper obstruction may still be present.
- ^{10e}After MGP, all patients uniformly used topical antibiotics, corticosteroids, and artificial tears, applied warm compresses, and massaged eyelids with a cotton-tip applicator.
- ^{10f}Patients with symptoms 1 week after initial treatment were retreated.
- ^{10g}The investigators noted the chronic recurrent course of the disease and advanced MGD in patients as the reason why 73.3% of patients required retreatment.
- ^{10h}The investigators did not provide a p-value for OSDI improvement but noted that, "Mean OSDI scores were 79.7 \pm 19.4 at baseline and 22.9 \pm 13.5 at 3 months (range, 0–100). The later OSDI scores showed a significant improvement in all the patients".

Nirupama, et al¹¹

- ^{11a}Not all glands were probed. According to the investigators, “The area of eyelid selected to be probed was the one with severe symptoms and with dilated ducts”.
- ^{11b}Proparacaine hydrochloride 0.5% was used as an anesthetic. The MGP developer’s protocol-recommended¹⁹ topical anesthetic is a topical jojoba anesthetic ointment containing 8% lidocaine.
- ^{11c}Only 4mm probes were used. A short, 1mm length probe was not used initially to locate the angle of entry.
- ^{11d}Adjunct therapy included antibiotic drops prescribed for 5 days after probing to all patients. Patients were instructed to apply warm compresses twice a day for 4–5 minutes and massage lids with a cotton tip applicator “to drain secretions”.
- ^{11e}The investigators reported that, “Patients noted increased comfort in lid excursion. The surface of the eye was smoother and cooler as described by some of them”.

Nakayama et al¹³

- ^{13a}Not all glands in a lid were probed. Instead, “10 orifices at even intervals were selected to be penetrated for each eyelid”.
- ^{13b}Only 2mm probes were used. A short, 1mm length probe was not used initially to locate the angle of entry.
- ^{13c}On the 100-point DEQS scale, 1 case improved by 14.9 points and 1 case improved by 0.9 points.

Fermon et al¹⁴

- ^{14a}One eye was treated and the other eye was used as a control.
- ^{14b}Only glands which were believed to be occluded, defined as “glands which do not transilluminate”, were probed. “The mean number of treated glands was 26”.
- ^{14c}Maskin probes (2mm and 4mm) were used but without the initial use of a 1mm probe.
- ^{14d}The investigators stated, “None of the patients referred significant discomfort during the intervention and no associated complications emerged”.
- ^{14e}No additional treatments for blepharitis were administered.
- ^{14f}The investigators stated, “In the 6 month follow-up, only 2 treated eyes (12.5% of sample) required retreatment (new probing) due to reactivation of symptoms and recurring glandular occlusion”. This may have been due to inadequately managed comorbidities since no other treatments were administered.
- ^{14g}The investigators stated, “All patients (100%) exhibited statistically significant improvement in the 4 variables of the study at the six-month assessment”. These 4 variables were objective TBUT and subjective visual acuity, blink comfort, and photophobia.

Acronyms and Abbreviations:

Design: DB, double blind; RCT, randomized controlled trial; SB, single blinded; OL, open label; PL, prospective longitudinal; RCR, retrospective chart review.

Prior Treatment: LH, lid hygiene; WC, warm compresses or eyelid warming; Top, topical treatment; Syst, systemic treatment; Mas, lid massage; AT, artificial tears; OAZ, oral azithromycin; OA, oral antibiotics; Diet, dietary modifications; CT, conventional treatment; HA, hyaluronic acid; DS, diquafosol sodium; Re, Rebamipide; MCG, moisture chamber glass; PP, punctum plugs; Of, ofloxacin ointment; RC, repair of chalasis; Lv, levofloxacin; Ox, oxalcalitriol ophthalmic ointment; SSRI, selective serotonin reuptake inhibitors; AI, topical anti-inflammatory.

Refractory/Follow-up: Mo, months; Yr, year; Wk, week.

Study Treatment: MGP, Meibomian gland probing; Bleph, blephamide; PT, prior treatment or prior conservative treatment; GenT, GenTeal PM Night-Time ointment; IPL, intense pulsed light; TopSter, topical steroid; CT, conventional treatment; WC, warm compress; Mas, lid massage; LH, lid hygiene; AT, artificial tears; CP, ciprofloxacin; O3, oral omega-3 fatty acids; OAZ, oral azithromycin.

n=: n, number of subjects; Pts, number of patients; (Eyes), number of eyes; [Lids], number of lids, {Gnd}, number of glands.

Symptoms, subjective symptoms: SANDE, Symptom Assessment in Dry Eye; OSDI, Ocular Surface Disease Index; SPEED, Standardized Patient Evaluation of Eye Dryness; Var Symp, various symptoms; DEQS, Dry Eye-Related Quality-of-Life Score; VA, visual acuity; BICO, comfort when blinking; Pho, photophobia.

Signs: LT, lid tenderness; TBUT, tear break-up time; LM, lid margin abnormalities; CFS, corneal fluorescein stain; MG, meibum grade; LMV, lid margin vascularization; OA, orifice abnormality; SchI, Schirmer I test; FS, fluorescein stain; OS, ocular surface Oxford score; MQ, meibum quality; ME, meibum expressibility; MLL, meibum lipid level; MV, meibum viscosity; LI, lipid interferometry; CH, conjunctival hyperemia; LMC, lid margin congestion.

Benefits of MGP Reported by Investigators

Studies showed that MGP consistently improved symptoms and signs in the overwhelming majority of patients, even with deviations in protocols (as noted in Table 1). Patients refractory to prior standard care showed the most improvement only after receiving MGP. Researchers arrived at the following conclusions:

Wladis:⁵

- “Intraductal meibomian gland probing is a safe, effective technique to address the ocular surface disease, tearing, and discomfort associated with ocular rosacea, and this intervention results in a dramatic improvement in these symptoms”.

Syed and Sutula:⁴

- “Immediately after the procedure, 91.4% of cases experienced symptomatic improvement, and no complications were noted”.
- “Dynamic intraductal meibomian probing is an effective and safe treatment for obstructive meibomian gland dysfunction that is resistant to traditional therapies”.

Incekalan et al:⁹

- “This study showed that intraductal meibomian gland probing seems to provide rapid symptom relief and clinical improvement for patients with obstructive-MGD (O-MGD)”.

- “Hereby, probing may become part of primary treatment as well as being an option in the patients resistant to conventional therapy in the future”.

Ma and Lu:⁸

- “Intraductal meibomian gland probing demonstrated significant efficacy in symptom relief and tear film stabilization. Probing helped release accumulated meibum and could help increase the accessibility of disease meibomian glands to topical corticosteroids”.
- “In group I [MGP + fluorometholone], 76% (19/25) of patients had symptom relief 1 day after probing before the administration of any additional medical treatment. However, in group II [fluorometholone], there was no significant improvement on the first day without any additional medical treatment”.

Nirupama et al:¹¹

- “This interventional pilot study has shown that intraductal probing into the meibomian gland duct, with Maskins Meibomian gland probe is safe and reliable. After probing the orifice of the gland becomes patent and the sequestered meibum will release through the orifice. There were no adverse effects on follow-up over 6 months”.
- “Meibomian gland probing seems is a safe and effective method in patients with obstructive meibomian gland dysfunction. Following probing there is a significant improvement in signs and symptoms of the patients”.

Fermon et al:¹⁴

- “...it can be concluded that MGP is a promising procedure for blepharitis cases exhibiting resistance to conservative treatment. In the experience of the authors, it was a safe procedure which produced significant improvements in 100% of patients who exhibited improvements after 6 months, with only 2 requiring retreatment”.

Kheirkhah et al:³

- “Compared to baseline, the MG probing/Blephamide group showed significant improvements in both OSDI and SANDE scores and the MG probing/GenTeal group demonstrated a significant improvement only in SANDE score”.

Sik Sarman et al:¹⁰

- Conclusions (from Abstract): “A procedure using modified Maskin probes was effective and reliable in the short term for patients with meibomian gland dysfunction”.

Nakayama et al:¹³

- Conclusions (from Abstract): “Intraductal meibomian gland probing seems to improve meibomian gland lipid levels, and it may be a good treatment option for cases of o-MGD that are resistant to conventional treatment”.

Huang et al:⁷

- Conclusion: “IPL, MGP, and combined MGP-IPL are all effective methods for refractory o-MGD patients; however, the combination MGP-IPL method could maximize the therapeutic benefits which is especially helpful for patients who have severe meibomian gland obstruction and obvious intraductal or eyelid margin inflammation,

who want to gain the greatest amelioration in all clinical signs and subjective symptoms or still remain frustrated to either MGP or IPL treatments”.

These conclusions by investigators, and the data shown in [Table 1](#), demonstrate the powerful therapeutic effect of MGP on patients with refractory MGD. Each peer-reviewed study^{3–5,7–11,13,14} reported significant improvement in subjective symptoms and/or objective signs in patients receiving MGP without adverse sequelae. Therefore, MGP should be considered for patients with refractory MGD or as a first-line therapy.

MGP Effectiveness Compared to Prior Standard Treatment or Control Group

Compared to Prior Standard Treatment

First, as reported by investigators, our [Table 1](#) column: Refractory to Prior Treatment shows that each study selected patients who were refractory to prior standard care treatment (some for at least 4 weeks⁴ and one patient up to 8 years¹³). These patients had already tried one or more of the following without showing improvement: lid hygiene, warm compresses, topical medications, systemic medication, lid massage, artificial tears, or other treatments. All investigators reported greatest improvement in patients only after MGP was added to the prior treatment protocol. In other words, MGP did outperform standard prior care in each study.

Compared to Control Groups Within a Study

Studies that compared MGP to standard care or sham probing all showed MGP outperformed controls or sham MGP in subjective and/or objective measures.^{3,7–9} (See our [Table 1](#): Kheirkhah et al,³ Huang et al,⁷ Ma and Lu,⁸ Incekalan et al⁹).

Kheirkhah et al³ showed statistically significant improvement in subjective measures: MGP + Blephamide, SANDE (p=0.002), OSDI (p=0.02); MGP + GenTeal, SANDE (p=0.01). Sham MGP did not show statistically significant improvement in these measures ([Table 1](#)).

Huang et al⁷ showed improvement in subjective measures: 100% of MGP patients reported symptoms relief, compared to 85.7% of IPL patients. Plus, although no patient from any group displayed SPEED score ≤ 9 prior to treatment, 14.29% of IPL patients and 26.67% of MGP patients obtained post treatment score ≤ 9 . Furthermore, no MGP patients had worsening of symptoms after treatment, whereas 14.8% of IPL patients had worsening of symptoms. Also, at 6 months, only 20% of MGP patients required retreatment, compared to 35.7% of IPL patients. In addition, for objective measures, 36.67% of MGP patients, compared to only 17.86% of IPL patients, had improvement in TBUT to >5 seconds ([Table 1](#)).

Ma and Lu⁸ compared the MGP + topical steroid group to baseline and to a control group using topical steroid only. MGP outperformed both as shown in our [Table 1](#). The MGP group, improved in both subjective symptoms compared to baseline (p<0.01) and compared to control (p<0.001). In objective signs, the MGP group improved compared to baseline: lid margin abnormalities (p<0.05), meibum grade (p<0.05), TBUT (p<0.05), and FS (p<0.05); and compared to control: lid margin abnormalities (p<0.001), meibum grade (p<0.001) and TBUT (p=0.0293). In addition, 76% of patients in the MGP group experienced symptom relief in 1 day before the first drop of topical steroid was used ([Table 1](#)).

Incekalan et al⁹ compared MGP + conventional treatment (CT) to baseline and to a control group using conventional treatment alone. In subjective symptoms, the MGP + CT group compared to baseline improved in OSDI (p<0.05) and compared to control improved faster (p<0.0001). In objective signs, the MGP + CT group improved compared to baseline: Schirmer 1 (p<0.05), TBUT (p<0.05), Oxford score (p<0.05), meibum quality (p<0.05), and meibum expressibility (p=0.0001); and compared to control all parameters improved faster: Schirmer 1 Test (p=0.0001), TBUT (p=0.014), and Oxford score, p=0.0001; meibum quality, p=0.034; meibum expressibility, p=0.0001) ([Table 1](#)).

Concepts and Insights Drawn from Experience

Definition of Successful MGP

SLM has written in recent papers^{2,18–21} that the purpose of MGP is restoring the integrity of the gland's central duct by releasing fixed obstruction thought to be periductal fibrotic and fibrovascular scar tissue, thus establishing and/or confirming the patency of the duct, and concurrently equilibrating intraductal pressure as well as promoting gland

functionality with improved meibum production.² Periductal fibrosis is thought to arise from surface and lid inflammation and disrupts the external duct wall/basement membrane with secondary constriction of duct wall and lumen with compromise of outflow capacity.²²

MGP is successful when the probe enters the gland through the natural orifice and either confirms or restores the gland's patency. Not all successfully probed glands will immediately secrete meibum. Some acinar-ductular units may be dormant (or atrophic) resulting in reduced or no sequestered meibum behind the fixed obstruction (unpublished data).^{2,21} After gland probing and the equilibration of intraductal pressure, gland functionality and meibum production returns, characterized by increased gland tissue and a proliferation of duct wall epithelium suggestive of stem cell activation.^{18,23}

Superficial (Distal) versus Deep (Proximal) Probing

Constriction from periductal fibroses can occur anywhere along a gland's length at multiple foci. Shorter and stiffer 1mm probes are used initially to locate the angle of entry and restore integrity to the distal duct. Longer 2mm or 4mm probes are used to complete the procedure when there is indication of deeper obstruction, such as persistent lid tenderness after the 1mm probe is used. Longer probes are also used in lids with MGD if minimal obstruction is found with 1mm probes, based on our study showing more than 90% of glands in these lids have fixed obstruction deeper than 1 mm by using 2 or 4mm probes.²

Significance of Lid Tenderness

Lid tenderness elicited during the exam when the examiner applies pressure to the patient's lid (after topical anesthetic is applied to the surface of the eye to ensure the sensation emanates from the lid and not the ocular surface), is a key indicator of obstructive MGD and elevated intraductal pressure in the setting of fixed periductal fibrotic obstruction.

SLM has found and published that immediately after MGP—literally instantaneously—lid tenderness disappeared with the release of periductal fibrotic obstruction and the equilibration of intraductal pressure. (Other symptoms like burning may take longer to resolve as gland functionality normalizes over 2–3 months after MGP.)^{1,19,20} If lid tenderness persists after MGP (the developer's published and recommended MGP protocol is an evaluation of the lid for tenderness after completing a pass with a 1mm probe)¹⁹ a longer probe is then used to ensure that more proximal periductal obstruction is also released.

Supporting these findings some investigators reported that patients experienced immediate or near immediate relief of symptoms after MGP suggesting the release of periductal obstruction with MGP, leading to equilibration of intraductal pressure and resolution of lid tenderness. For example, Ma and Lu⁸ found 76% of patients had immediate relief of symptoms one day after MGP even before initiating topical steroid drops. Syed and Sutula⁴ reported 91.4% of patients had relief of symptoms at 1 week follow-up.

Huang et al⁷ reported improvement specifically in lid tenderness; MGP-alone showed a clear statistically significant superior result when directly compared to IPL-alone (Intense Pulsed Light) ($p < 0.001$) for lid tenderness.

Kheirkhah et al³ reported statistically significant improvement in lid tenderness in the sham MGP group. However, in this study, lids receiving MGP were injected with anesthetic, which can cause microtrauma, hemorrhage and edema creating iatrogenic lid tenderness persisting for weeks. Sham MGP lids, in contrast, were not injected with anesthetic but rather received topical anesthetic only.³ Also, the study design did not describe how focal, regional and global lid tenderness findings were managed statistically: were they combined or was there an attempt to differentiate between focal and more diffuse tenderness? Furthermore, topical anesthetic should also have been used immediately prior to evaluating lid tenderness to rule out tenderness from the ocular surface.

Significance of Repeat MGP

Patients might be retreated after initial MGP for several reasons. For example, in the setting of inadequately treated or advanced comorbid ocular surface or systemic diseases, harsh environments, or a variety of work and lifestyle factors (such as heavy computer use), the duct will re-obstruct within 2–3 months.

Not following the published and recommended MGP protocol¹⁹ can also lead to early reprobing. For example, obstructive disease and symptoms will not be resolved when treating with only short probes when longer probes are needed. In addition, if all glands in both lids are not treated obstructive disease and symptoms may persist.

Furthermore, symptoms of MGD other than lid tenderness and soreness, such as burning, stinging and photophobia, usually improve in 2–3 months after MGP concurrent with ductal epithelial cell proliferation as seen on confocal microscopy suggestive of stem cell activation along with increased gland tissue noted on meibography as well as improved gland functionality.^{18,21,23} Thus, some study patients, like those retreated 1 week after initial treatment,¹⁰ may have been retreated prematurely.

Finally, 20% of MGP-alone patients in Huang et al⁷ required reprobating at 6 months follow up. But in the same study at 6 months follow up, 35.7% of IPL-alone patients required retreatment. That amounts to a 75% greater number of IPL patients requiring retreatment than MGP patients. Moreover, one IPL treatment consists of 3 sessions and yet the 3 individual sessions each administered several weeks apart, are considered one single treatment instead of 3 separate treatments. This means the reprobated patients required only 2 treatments whereas IPL patients required 6 total treatment sessions.

Seven of the independent studies reported on repeat probing as follows:

1. Fermon et al¹⁴ reported that 12.5% (2 of 16 patients) required retreatment, once within the six-month follow-up.
2. Nirupama et al¹¹ reported that 26.6% (8 out of 30 patients) needed retreatment after 3 months.
3. Incekalan et al⁹ reported that 0% (0 of 20 patients) were retreated at 3 months follow up.
4. Wladis⁵ reported that 0% (0 of 10 patients) were retreated at 6 months follow up.
5. Huang et al⁷ reported that 0% (0 of 14 MGP+IPL patients), 20% (3 of 15 MGP patients), and 35.7% (5 of 14 IPL patients), required retreatment.
6. Sik Sarman et al¹⁰ reported that 60% (18 of 30 patients) were treated 2 times, 10% (3 of 30 patients) were treated 3 times, and 3.3% (1 of 30 patients) were treated 4 times. Together at 1 year follow up, 73.3% (22 of 30 patients) were retreated.

Taken together, across these studies that reported on MGP retreatment (which can occur for a variety of reasons) 25.9% (35 of 135 patients) required retreatment.

In addition:

1. Syed and Sutula⁴ reported that 7.7% (1 of 13 lids with long term follow up) were retreated at 52 weeks after initial treatment.

The one outlier that reported more frequent reprobating was from Turkey. Sik Sarman et al¹⁰ (listed as #6 above) explained, “a single application was not sufficient, which was considered a result of the chronic, recurrent course of the disease and advanced MGD in the patients”. Sik Sarman et al¹⁰ also reported that all their patients who were previously refractory to medical therapy for 6 months and “who underwent more than one probing procedure, during probing, diffuse vascularization in meibomian ducts, fibrosis and minimal bleeding was observed”. This finding explains and confirms the investigators’ conclusions of advanced MGD and suggests deep multifocal periductal fibrosis and fibrovascular tissue. An aggressive co-morbid chronic inflammatory and fibrotic reaction requires combined environmental control and reprobating on subsequent visits. Still, despite managing these advanced MGD cases that were refractory to previous standard therapy for 6 months, Sik Sarman et al¹⁰ found with MGP, statistically significant improvement in TBUT ($p < 0.001$), decrease in conjunctival hyperemia ($p < 0.0001$), and eyelid margin vascularization ($p = 0.004$), as well as a significant improvement in OSDI scores, leading the investigators to state, “In conclusion, for the treatment of MGD, meibomian duct probing performed with modified Maskin cannulas was effective and reliable in short term follow ups”.

Characteristic Probe Findings and Their Significance

Two characteristic probe findings and their significance have not always been understood. These are the “popping” sound² and the post-MGP, self-limiting hemorrhage. Neither of these are side-effects, signs of adverse reactions to treatment, complication due to treatment, or indications of potential sequelae.

Popping Sound

The popping sound observed during probing is like the sound heard upon the release of canalicular fibrosis with a punctal dilator or the snap of an old rubber band and is thought to represent the release of the band of periductal fibrotic tissue constricting the gland duct. It is just a sound and not a side effect.


Multiple popping sounds in quick succession, that in the hand of the prober create a feeling of something gritty lodged within the gland, indicate the release of multiple bands of fibrotic tissue at different depths. When these fibrotic bands are present, the patient and prober will hear what sounds like nails on a washboard as the probe releases the bands of tissue in quick succession.

All of these sounds, and the tactile sensation felt by the prober, are no more side effects than the sound of brushing and flossing one's teeth. The sounds and tactile sensation are documented on a Probe Findings form (shown in Figure 2) used to monitor gland obstruction and improvement over time.

Post-MGP Hemorrhage

Occasionally a microscopic self-limiting hemorrhage is seen at the gland orifice after MGP.

The droplet of blood is not an indication that the gland has been damaged.



Date: 07/14/2021

Name: [REDACTED]

Anesthetic: JOJOBA UNG

Injected Therapeutic: DEXA

Maskin Meibum Expressor
or other expression completed

Yes No

Lid: RU LU

Probe: 1mm 2mm 4mm

TGP	MR	Firm	Soft	None	%F	%Sft	%N	Heme
35	25	22	3	10	62.9	8.6	28.6	
31	28	22	6	3	71	19.4	9.7	

FP	FG	%FP	%FG
18	4	51.4	11.4
17	5	54.8	16.1

Lid: RL LL

Probe: 1mm 2mm 4mm

TGP: Total Glands Probed

MR: Mechanical Resistance = Firm + Soft

Firm (F): Gland shows FFFUR (firm, fixed, focal, unyielding resistance)

Soft (Sft): Gland shows non-fixed, nonfocal, easily-yielding, soft resistance

None (N): No resistance

Heme: Blood present at the orifice after probing

Firm-Pop (FP): Singular pop from probe

Firm-Girty (FG): Multiple pops from probe

Figure 2 Probe findings form of a patient.

Notes: Reproduced from Maskin, SL, Warren NA. *Your Dry Eye Mystery Solved: Reversing Meibomian Gland Dysfunction, Restoring Hope*. Yale University Press, 2022 with permission from Yale University Press.²²

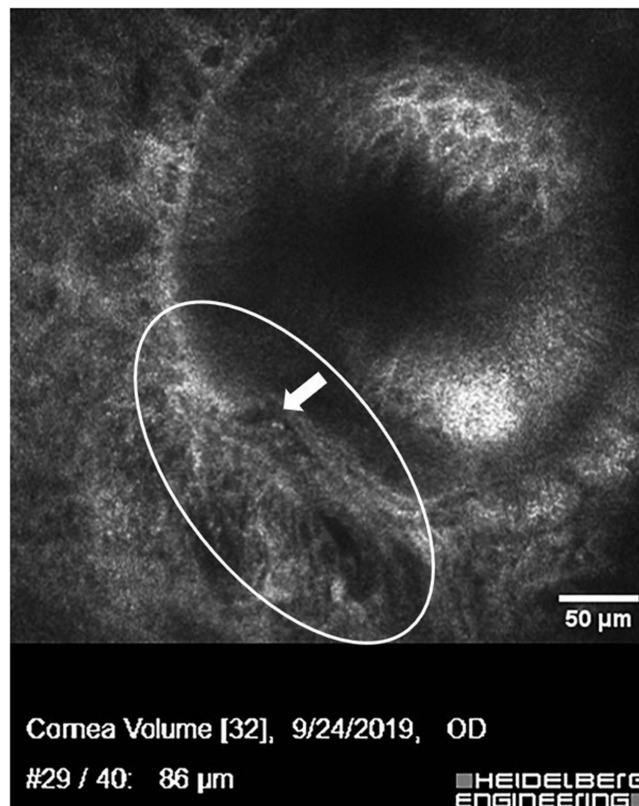


Figure 3 Confocal microscopy image of Meibomian gland distal duct showing disruption of the normally well demarcated external duct wall by fibrovascular tissue invasion. A prominent blood vessel is seen inside the oval. The disruption of the duct wall is indicated by the solid arrow showing a “step off”. This gland had not been probed. (Courtesy of SLM).

Instead, the microscopic, self-limiting hemorrhage, along with the auditory pop or gritty sound described above, confirms that fixed obstruction consisting of abnormal fibrotic or fibrovascular tissue, that often wraps the glands and disrupts the external duct walls was released with probing (Figure 3).

One would expect a released fibrovascular stricture of a Meibomian gland, like a released fibrovascular stricture elsewhere in the body, to hemorrhage. This hemorrhage is a natural result of targeting and reversing the root cause of this disease and indicates the beginning of the rehabilitative process for the diseased glands. It is analogous to the small amount of hemorrhage sometimes seen when releasing a stricture of the urethra or esophagus.

Safety of MGP

MGP is inherently safe^{6,13} because:

- The probe enters the gland through the natural orifice opening at the lid margin, not through tissue of the lid margin.
- The probe advances into the hollow lumen of the gland, like an arm into a shirt sleeve, not into the gland’s acinar structures.
- The gland’s duct is not bony or rigid. The duct is flexible and the surrounding periglandular tissue is spongy and compressible, allowing the duct to flex when the probe is inserted while remaining intact.²¹

Furthermore, MGP has no contraindications (except for active infection), unlike other MGD treatments including IPL which poses numerous contraindications, such as uncontrolled ocular surface disease, history of ocular herpes simplex, and history of migraines with risks such as scarring, pain and discomfort, and change in pigmentation.²⁴

Moreover, unlike patients treated with MGP alone, Huang et al⁷ noted that some patients treated with IPL alone reported worse symptoms, stating,

Surprisingly, instead of showing reduction in symptoms, 2 patients (14.8%) in the present study reported even more serious symptoms at the end of the IPL treatment course.

They suggested the post-IPL increase in pain was due to untreated or unreleased obstructions stating, “It can be speculated that this deterioration may relate to obstruction sites within the glands”.⁷ They further explained,

The heat released by IPL and the pressure caused by the forceps might paradoxically increase the intraductal pressure and exacerbate the inflammatory response; thus, treatment with IPL alone may not alleviate disease symptoms but instead irritate the condition.⁷

They went on to say,

This effect can also be indirectly observed in the present data in terms of the posttreatment lid tenderness of the IPL group, despite showing symptom alleviation compared with baseline, still being significantly higher than the MGP and MGP-IPL groups.⁷

Deviations from MGP Developer’s Published and Recommended Protocol

The 10 studies^{3–5,7–11,13,14} reported many deviations from MGP Developer’s Published and Recommended Protocol¹⁹ (see Table 1).

These deviations could affect outcomes and are discussed in the footnotes to Table 1:

- Inadequately anesthetizing lids.
- Injecting lids with excessively potent anesthetic that can cause toxic inflammatory side effects.
- Probing only 1 lid per eye.
- Probing a select few glands.
- Using large-diameter probes.
- Using probes not specifically designed for probing Meibomian glands.
- Not using a stiff short 1-mm probe to first locate the angle of entry.
- Probing with probes of only 1 length.
- Not checking for persistent lid tenderness after probing a lid with a 1mm probe.
- Prescribing adjunct treatment to patients regardless of comorbidities or sensitivities.
- Not identifying and successfully managing comorbid disease.
- Retreating prematurely.

Despite the fact that each of these deviations from the published MGP protocol¹⁹ would have impacted patient outcomes and study results in some way, investigators reported improvement in patients after MGP. The question remains: how much more would the patients’ outcomes and/or tolerance for the procedure have improved if the investigators had followed the developer’s published and recommended protocol?¹⁹

To illustrate, Huang et al⁷ used 4% lidocaine for injection into the upper and lower eyelids which may cause toxic eyelid reactions compared to the recommended protocol¹⁹ of using topical 8% lidocaine in jojoba anesthetic ophthalmic ointment with, if indicated, the addition of nerve block at the supra and infraorbital foramen, which does not distort local tissues. Huang et al⁷ also used 120 μ m outer diameter probes and 160 μ m outer diameter tubes rather than Maskin devices, dimensioned specifically for Meibomian glands: the 76 μ m outer diameter Maskin Probe and the 110 μ m outer diameter Maskin MicroTube. Also, the protocol²¹ strongly recommends beginning with the 1mm-long probe to find the correct entry angle into the distal duct rather than starting off with a 4.5 mm probe, as Huang et al⁷ did in their study, and which could cause more patient discomfort.

Additionally, when indicated, irrigating or lavaging topical steroids or other therapeutics into the glands through the orifice after probing them is part of the MGP protocol.²¹ Once ductal integrity is established and constriction of the lumen has been released by probing, the duct is prepared for irrigation with corticosteroid or other therapeutics.²¹

Concluding Comments

This study provides a comprehensive summary and analysis of independent peer-reviewed studies on MGP.^{3–5,7–11,13,14} Despite variations in treatment protocols, as shown in Table 1, all studies showed that MGP consistently demonstrated positive results in patients refractory to standard treatments for MGD. We provide analysis of these variations and how they impact study results.

Many of the investigators suggested that independent larger studies with longer-term follow-up are needed. Nevertheless, positive study results with no adverse effects have led some investigators to propose MGP not only as a refractory treatment for MGD but also as a primary treatment for all patients diagnosed with MGD.⁹

Author Contributions

All authors made a significant contribution to the work reported, whether that is in the conception, study design, execution, acquisition of data, analysis and interpretation, or in all these areas; took part in drafting, revising or critically reviewing the article; gave final approval of the version to be published; have agreed on the journal to which the article has been submitted; and agree to be accountable for all aspects of the work.

Funding

There is no funding to report.

Disclosure

SLM is a >5% owner of MGD Innovations, Inc. which holds patents on instrumentation and methods for intraductal diagnosis and treatment of meibomian gland disease (MGD). SLM also has patents on the use of jojoba-based treatment options for MGD. He also reports patent royalties from Katena (nos: 9510844, 10159599, and 11110003). NAW is chair of the Not A Dry Eye Foundation. The authors report no other conflicts of interest in this work.

References

1. Maskin SL. Intraductal meibomian gland probing relieves symptoms of obstructive meibomian gland dysfunction. *Cornea*. 2010;29(10):8. doi:10.1097/ICO.0b013e3181d836f3
2. Maskin SL, Alluri S. Expressible meibomian glands have occult fixed obstructions: findings from meibomian gland probing to restore intraductal integrity. *Cornea*. 2019;38(7):880–887. doi:10.1097/ICO.0000000000001954
3. Kheirikhah A, Kobashi H, Girgis J, Jamali A, Ciolino JB, Hamrah P. A randomized, sham-controlled trial of intraductal meibomian gland probing with or without topical antibiotic/steroid for obstructive meibomian gland dysfunction. *Ocul Surf*. 2020;18(4):852–856. doi:10.1016/j.jtos.2020.08.008
4. Syed ZA, Sutula FC. Dynamic intraductal meibomian probing: a modified approach to the treatment of obstructive meibomian gland dysfunction. *Ophthalm Plast Reconstr Surg*. 2017;33(4):307–309. doi:10.1097/IOP.0000000000000876
5. Wladis EJ. Intraductal meibomian gland probing in the management of ocular rosacea. *Ophthalm Plast Reconstr Surg*. 2012;28(6):416–418. doi:10.1097/IOP.0b013e3182627ebc
6. Dongju Q, Hui L, Jianjiang X. Clinical research on intraductal meibomian gland probing in the treatment of patients with meibomian gland dysfunction. *Chin J Optom Ophthalmol*. 2014;16(10):615–621.
7. Huang X, Qin Q, Wang L, Zheng J, Lin L, Jin X. Clinical results of intraductal meibomian gland probing combined with intense pulsed light in treating patients with refractory obstructive meibomian gland dysfunction: a randomized controlled trial. *BMC Ophthalmol*. 2019;19(1):211. doi:10.1186/s12886-019-1219-6
8. Ma X, Lu Y. Efficacy of intraductal meibomian gland probing on tear function in patients with obstructive meibomian gland dysfunction. *Cornea*. 2016;35(6):725–730. doi:10.1097/ICO.0000000000000777
9. Incekalan TK, Harbiyeli II, Yagmur M, Erdem E. Effectiveness of intraductal meibomian gland probing in addition to the conventional treatment in patients with obstructive meibomian gland dysfunction. *Ocul Immunol Inflamm*. 2019;27(8):1345–1351. doi:10.1080/09273948.2018.1522357
10. Sik Sarman Z, Cucen B, Yuksel N, Cengiz A, Caglar Y. Effectiveness of intraductal meibomian gland probing for obstructive meibomian gland dysfunction. *Cornea*. 2016;35(6):721–724. doi:10.1097/ICO.0000000000000820
11. Nirupama D, Hymavathi B, Prathima L, Sanjay Reddy T, SR G. Meibomian gland probing in patients with meibomian gland dysfunction. *Indian J Clin Exp Ophthalmol*. 2019;5(1):78–81.
12. Cárdenas Díaz T, Guerra Almaguer M, Hernández López I, Cruz Izquierdo D, Cuan Aguilar Y. Efficacy of intraductal probing in the dysfunction of the meibomian glands. *Rev Cubana Oftalmología*. 2016;30(2):725–730.
13. Nakayama N, Kawashima M, Kaido M, Arita R, Tsubota K. Analysis of meibum before and after intraductal meibomian gland probing in eyes with obstructive meibomian gland dysfunction. *Cornea*. 2015;34(10):1206–1208. doi:10.1097/ICO.0000000000000558
14. Fermon S, Zaga IH, Alvarez Melloni D. Intraductal meibomian gland probing for the treatment of blepharitis. *Arch Soc Esp Ophthalmol*. 2015;90(2):76–80. doi:10.1016/j.oftal.2014.04.014

15. Prozornaia LP, Brzhevskii VV. Эффективность физиотерапевтических и гигиенических процедур в лечении детей и взрослых с хроническим блефаритом и синдромом [Efficacy of physiotherapy and hygienic procedures in treatment of adults and children with chronic blepharitis and dry eye syndrome]. *Vestn Ophthalmol.* 2013;129(3):68–63. Russian.
16. Magno M, Moschowits E, Arita R, Vehof J, Utheim TP. Intraductal meibomian gland probing and its efficacy in the treatment of meibomian gland dysfunction. *Surv Ophthalmol.* 2021;66(4):612–622. doi:10.1016/j.survophthal.2020.11.005
17. Maskin SL. Comments on: intraductal meibomian gland probing and its efficacy in the treatment of meibomian gland dysfunction. *Surv Ophthalmol.* 2021;66(4):680–685. doi:10.1016/j.survophthal.2021.02.007
18. Maskin SL, Testa WR. Growth of meibomian gland tissue after intraductal meibomian gland probing in patients with obstructive meibomian gland dysfunction. *Br J Ophthalmol.* 2018;102(1):59–68. doi:10.1136/bjophthalmol-2016-310097
19. Maskin SL, Alluri S. Intraductal meibomian gland probing: background, patient selection, procedure, and perspectives. *Clin Ophthalmol.* 2019;13:1203–1223. doi:10.2147/OPTH.S183174
20. Maskin SL, Alluri S. Intraductal meibomian gland probing: background, patient selection, procedure, and perspectives [Erratum]. *Clin Ophthalmol.* 2019;13:1475.
21. Maskin SL, Alluri S. Meibography guided intraductal meibomian gland probing using real-time infrared video feed. *Br J Ophthalmol.* 2020;104(12):1676. doi:10.1136/bjophthalmol-2019-315384
22. Maskin SL, Warren NA. *Your Dry Eye Mystery Solved: Reversing Meibomian Gland Dysfunction, Restoring Hope.* Yale University Press; 2022.
23. Alluri S, Maskin SL. Intraductal meibomian gland probing (MGP) leads to ductal epithelial proliferation with increased duct wall thickness. *Invest Ophthalmol Vis Sci.* 2020;61(7):96.
24. Lumenis. Website of Lumenis. Available from: <https://lumenis.com/medical/eye-care-products/optilight>. Accessed July 29, 2021.

Clinical Ophthalmology

Dovepress

Publish your work in this journal

Clinical Ophthalmology is an international, peer-reviewed journal covering all subspecialties within ophthalmology. Key topics include: Optometry; Visual science; Pharmacology and drug therapy in eye diseases; Basic Sciences; Primary and Secondary eye care; Patient Safety and Quality of Care Improvements. This journal is indexed on PubMed Central and CAS, and is the official journal of The Society of Clinical Ophthalmology (SCO). The manuscript management system is completely online and includes a very quick and fair peer-review system, which is all easy to use. Visit <http://www.dovepress.com/testimonials.php> to read real quotes from published authors.

Submit your manuscript here: <https://www.dovepress.com/clinical-ophthalmology-journal>