

## Research Article

# Zerumbone-Loaded Nanostructured Lipid Carrier Gel Enhances Wound Healing in Diabetic Rats

Shaymaa Fadhel Abbas Albaayit <sup>1,2</sup> Rasedee Abdullah <sup>3</sup>  
and Mohd Hezme Mohd Noor <sup>4</sup>

<sup>1</sup>Department of Biology, College of Science, University of Baghdad, Baghdad, Iraq

<sup>2</sup>Institute of Biological Sciences, Faculty of Science, University of Malaya, 50603 Kuala Lumpur, Malaysia

<sup>3</sup>Department of Veterinary Laboratory Diagnosis, Faculty of Veterinary Medicine, Universiti Putra Malaysia, 43400 Serdang, Selangor, Malaysia

<sup>4</sup>Department of Veterinary Preclinical Sciences, Faculty of Veterinary Medicine, Universiti Putra Malaysia, 43400 Serdang, Selangor, Malaysia

Correspondence should be addressed to Shaymaa Fadhel Abbas Albaayit; shaymaa\_albaayit@yahoo.com and Mohd Hezme Mohd Noor; hezme@upm.edu.my

Received 4 February 2022; Accepted 9 May 2022; Published 10 September 2022

Academic Editor: K. Arunachalam

Copyright © 2022 Shaymaa Fadhel Abbas Albaayit et al. This is an open access article distributed under the Creative Commons Attribution License, which permits unrestricted use, distribution, and reproduction in any medium, provided the original work is properly cited.

This study investigated the healing effects of topical application of zerumbone, a well-known anti-inflammatory compounds loaded on nanostructured lipid carrier gel (Carbopol 940) (ZER-NLCG) on excisional wounds in streptozotocin-induced diabetic rats. Diabetic rats with inflicted superficial skin wound were topically treated with ZER-NLCG, empty NLCG, and silver sulfadiazine cream (SSDC) once daily for 21 days. Wound tissue samples were analyzed for proinflammatory cytokines, namely, interleukin-6 (IL-6), interleukin-1  $\beta$  (IL-1 $\beta$ ), and tumor necrosis factor- $\alpha$  (TNF- $\alpha$ ), hydroxyproline contents, catalase, superoxide dismutase activities, and lipid peroxidation level, and were subjected to histopathological analysis, respectively. Among the treated groups, ZER-NLCG was the most effective at decreasing proinflammatory cytokine level and inflammatory cell infiltration while increasing antioxidant enzyme activities, hydroxyproline content, and granulation of wound tissues of diabetic rats. ZER-NLCG is a potent formulation for the enhancement of wound healing in diabetic rats through its anti-inflammatory, antioxidant, and tissue repair activities.

## 1. Introduction

Wound healing is a well-organized interplay between migration and proliferation of blood cells, endothelial cells, extracellular matrix production, fibroblasts, cytokines, growth factor release, and angiogenesis [1, 2]. Delayed wound healing is a major complication in diabetics, and this is principally associated with hyperglycemia, abnormalities in cytokine expressions, oxidative stress, and impaired neovascularization [3–5]. In fact, diabetic patients are prone to develop chronic nonhealing foot ulcers [6, 7].

Numerous phytochemicals have been shown to have wound healing properties [8]. These phytochemicals include curcumin, picroliv, and arnebin-1 [9], thymoquinone [10], and zerumbone [11]. The wound healing properties of phytochemicals are partly exerted through their natural antioxidant properties [12, 13]. Unfortunately, many phytochemicals are water-insoluble, which compromise their therapeutic potentials. Several carriers have been used to solubilize these compounds. These include cyclodextrins, chitosan, liposome nanoparticles, and nanostructured lipid carriers (NLC) [14, 15]. Nanostructured lipid carriers are

TABLE 1: Blood glucose concentration in diabetic rats treated with NLCG, SSDC, and ZER-NLCG.

Treatment Groups (n = 6)	Blood glucose (mmol/l) Days postwound infliction			
	0	8	14	21
Normal (nontreated)	5.23 <sup>a</sup> ± 0.07	5.35 <sup>a</sup> ± 0.12	5.26 <sup>a</sup> ± 0.18	5.30 <sup>a</sup> ± 0.14
Diabetic (nontreated)	18.63 <sup>b</sup> ± 0.55	18.73 <sup>b</sup> ± 1.32	19.07 <sup>b</sup> ± 0.98	19.03 <sup>b</sup> ± 1.99
NLCG	19.43 <sup>b</sup> ± 1.68	19.30 <sup>b</sup> ± 2.30	19.37 <sup>b</sup> ± 1.13	19.78 <sup>b</sup> ± 2.03
SSDC	19.44 <sup>b</sup> ± 1.52	19.54 <sup>b</sup> ± 1.97	18.73 <sup>b</sup> ± 0.84	17.08 <sup>b</sup> ± 2.09
ZER-NLCG	20.33 <sup>b</sup> ± 1.46	20.15 <sup>b</sup> ± 1.40	18.83 <sup>b</sup> ± 2.20	20.58 <sup>b</sup> ± 1.86

<sup>a,b</sup>Means with different superscript within columns are statistically significant ( $p < 0.05$ ) different from the normal values.

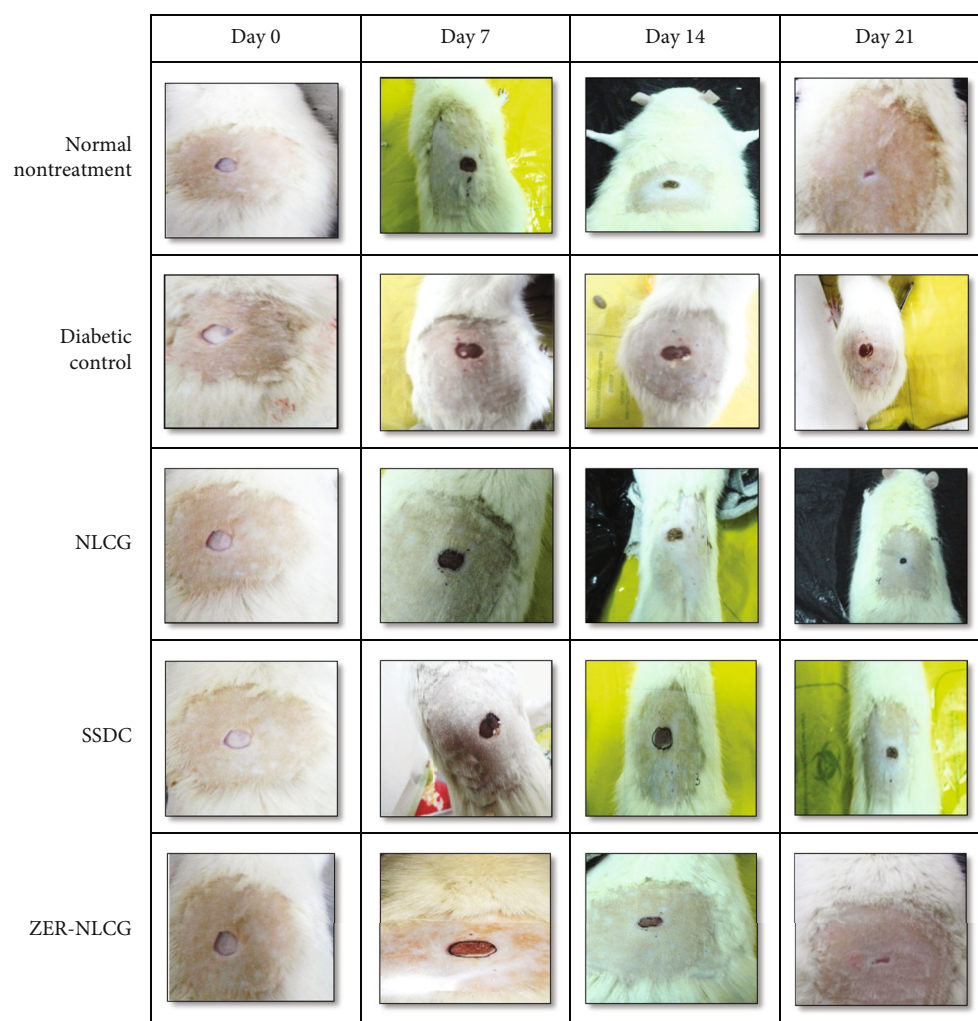


FIGURE 1: Wound healing in diabetic rats treated with NLCG, SSDC, and ZER-NLCG. ZER-NLCG produced the most best healing effect among treatment with wound contraction rate similar to that of nontreated normal rats.

second-generation lipid-based nanoparticles that are developed based on the solid lipid nanoparticles (SLN) [16]. Unlike SLN, which is primarily composed of solid lipids, the NLC has a core structure comprising of both solid and liquid lipids. The core of the NLCs has an imperfect matrix structure that increased space for accommodation of drug,

drug load, and with less potential for drug expulsion than SLN [17–19].

Zerumbone is the major sesquiterpene phytochemical in the rhizome of edible ginger *Zingiber zerumbet* (L.) Smith [20]. Zerumbone possesses antioxidant, anti-inflammatory, antimicrobial, hepatoprotective, antinociceptive [21], and

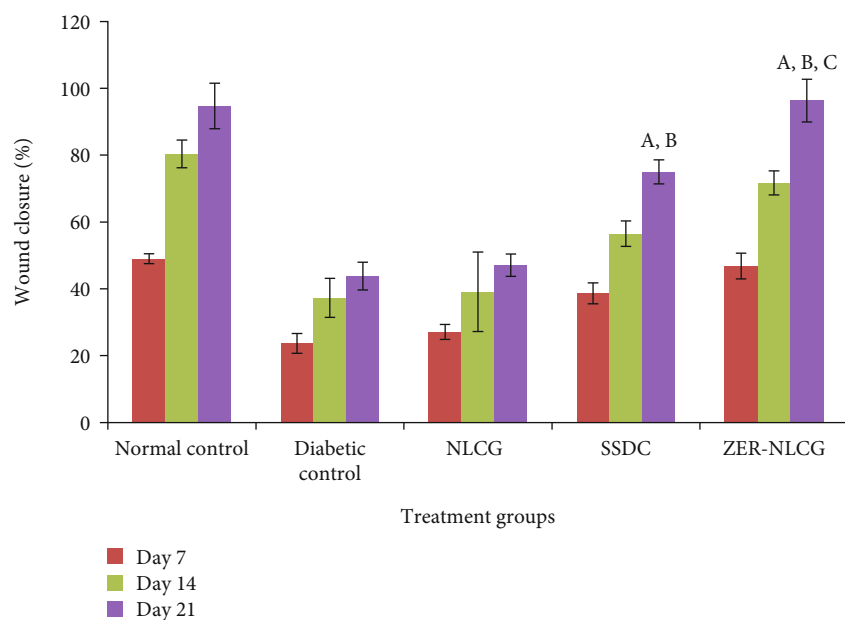


FIGURE 2: Wound contraction in diabetic rats treated with NLCG, SSDC, and ZER-NCLG. ZER-NLCG was most effective among treatments at acceleration wound closure in diabetic rats. Means significantly different from those of diabetic control<sup>a</sup>, NLCG-treated group<sup>b</sup>, and SSDC-treated group<sup>c</sup> at  $p < 0.01$ . Values are expressed as mean  $\pm$  SD.

anticancer [22, 23] properties. Despite the known therapeutic applications, the effect of zerumbone on wound healing process is still not investigated. Zerumbone has been loaded in NLC and the complex has shown to have anticancer properties [24].

Therefore, the present study was undertaken to determine the wound healing effects of free and NLC-loaded zerumbone in a streptozotocin-induced diabetic rat model.

## 2. Materials and Methods

**2.1. Chemicals and Reagents.** Streptozotocin (STZ) and sodium citrate were purchased from Sigma-Aldrich (St. Louis, USA). Ketamine and xylazine were purchased from Troy Laboratories Pte. Ltd. (New South Wales, Australia). The assay kits used for the determination of proinflammatory, hydroxyprolin levels, and enzyme activities were supplied by Cusabio Biotech (Houston, USA), while the lysis buffer (tissue protein extraction) reagent was purchased from Thermo Scientific Ltd. (Massachusetts, USA).

**2.2. Preparation of Zerumbone-Nanostructure Lipid Carrier (ZER-NLCG) Gel.** Pure colourless zerumbone (ZER) crystal was extracted from fresh *Zingiber zerumbet* rhizome essential oils using steam distillation, and zerumbone-nanostructure lipid carrier (ZER-NLC) was prepared and characterized as described by Rahman et al. [25]. The ZER-NLC gel (ZER-NLCG) and NLC gel (NLCG) were prepared as described earlier [26]. Briefly, the ZER-NLC has the particle size of  $52.68 \pm 0.1$  nm and polydispersity index of  $0.29 \pm 0.0041$  nm. The zeta potential of this compound is recorded at a level of  $25.03 \pm 1.24$  mV, while the drug entrapment value is approximately 99.03% w/w.

**2.3. Experimental Animals.** All studies were performed in accordance to the guidelines of the Institutional Animal Care and Use Committee (ACUC), University of Malaya (ISB/22/07/2013/SFA).

In the present study, healthy and normal glycaemic male Wistar albino rats weighing in between 200 to 250 g were used. Animals were housed in stainless-steel cages under controlled ambient temperature of  $25 \pm 2^\circ\text{C}$  and 12 h light-dark cycle. Commercial rat/mouse pellet (Specialty Feeds, Western Australia) and water were provided ad libitum.

**2.4. Streptozotocin-Induced Diabetes.** The rats were weighed and their fasting blood glucose were determined before the induction of diabetes. Food and water were withheld from the rats for 18 hours, and then, they were induced with a single intraperitoneal injection of 65 mg/kg streptozotocin (Sigma-Aldrich, USA) dissolved in 0.05 M sodium citrate (pH 4.5) to develop diabetes mellitus condition. Two days after the induction, the development of hyperglycemia (blood glucose levels higher than 16.7 mmol/L) in the rats was confirmed by estimating the fasting blood glucose concentrations using the Glucocheck strip (Accu-Chek® Active, Roche Diagnostic GmbH, USA) [27].

**2.5. Excision Wound Model.** Full-thickness excision skin wounds were created in the diabetic rats as described previously [28]. Briefly, while under anesthesia with intramuscular injection of ketamine hydrochloride (25 mg/kg)-xylazine hydrochloride (10 mg/kg), the hair on the dorsal neck of diabetic and normal control rats were shaved and the exposed skin were cleaned with 70% ethanol. A circular full thickness wound of 8 mm diameter was created aseptically on the exposed skin of each rat using a sterile skin biopsy punch (Biopunch®, Fray Products Corp., New York, USA). The



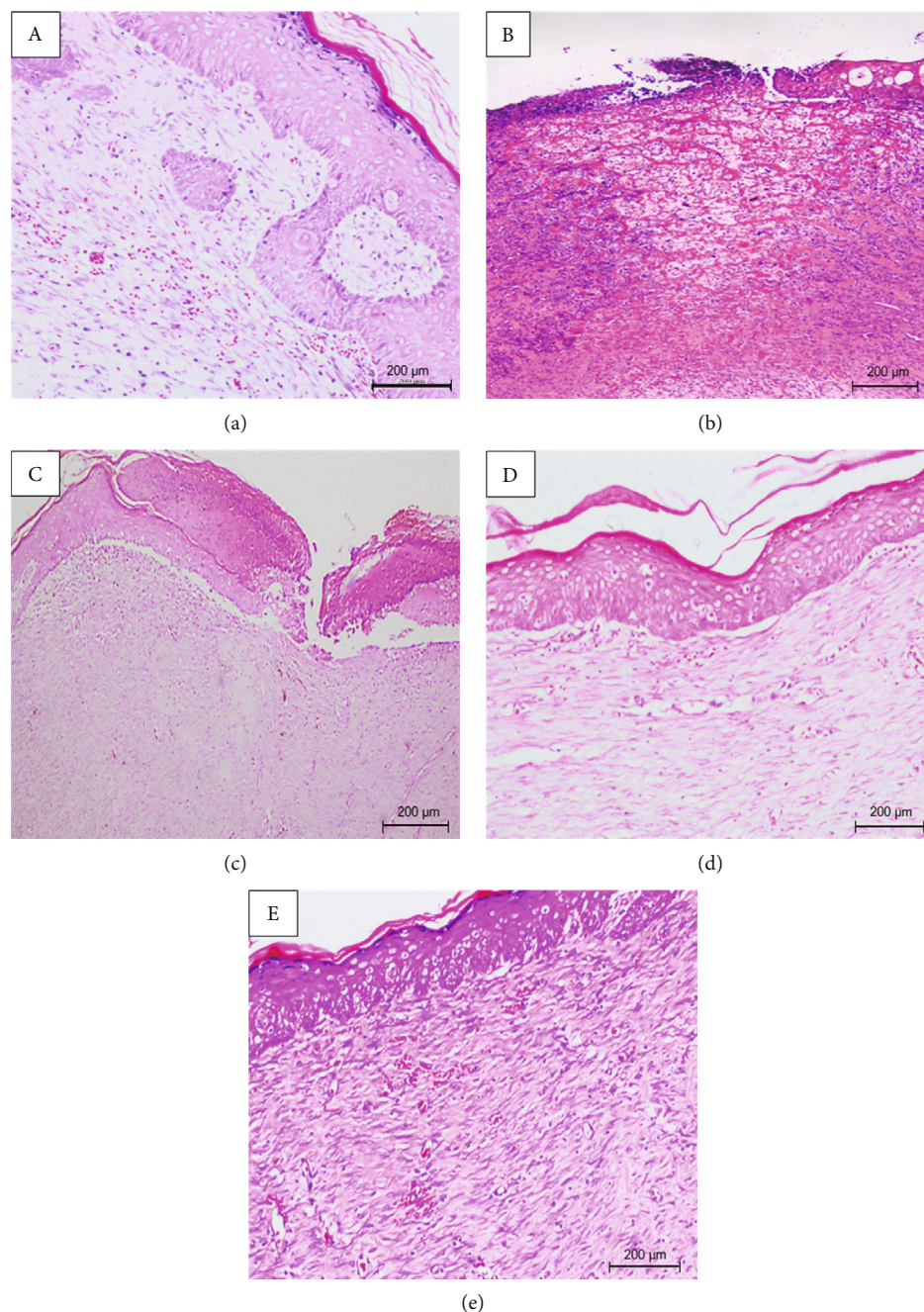


FIGURE 3: Skin wound tissue of diabetic rats treated with (c) NLCG, (d) SSDC, and (e) ZER-NLCG after 21 days. (a) Nontreated normal wound tissue and (b) nontreated diabetic wound tissue.

wounds were dabbed with cotton soaked in normal saline to stop the bleeding [29].

**2.6. Animal Grouping and Treatment.** Diabetic rats were divided into five groups ( $n = 6/\text{group}$ ). Normal nondiabetic rat control was assigned as group 1. Untreated diabetic rats were assigned as group 2. In group 3 which is considered as positive control, rats were treated with 0.2 ml 1% *w/w* silver sulfadiazine cream (SSDC) (reference standard). In group 4, rats were topically treated with 0.2 ml of NLCG, whereas in group 5, rats were topically treated with 0.5 mg/ml ZER-NLCG. These treatments were given for 21 days.

**2.7. Healing and Wound Contraction.** The size of the open wound was determined with planimetry by tracing the wound with transparent sheets, and the total area was determined with graph papers. The rate of healing was calculated and expressed as percentage wound contraction on days 7, 14, and 21. The wounds were photographed. The rate of healing was calculated using the following formula [28].

$$\text{Wound closure (\%)} = \frac{A_0(\text{mm}^3) - A_r(\text{mm}^3)}{A_0(\text{mm}^3)} \times 100, \quad (1)$$

TABLE 2: Histological changes in wound tissues of diabetic rats treated with NLCG, SSDC, and ZER-NLCG.

Parameter	Normal control	Diabetic control	Lesion score (%)		
			NLCG	SSDC	ZER-NLCG
Epidermal wound closure	87.7 <sup>a</sup> ± 3.6	0.7 <sup>b</sup> ± 0.9	51.7 <sup>a</sup> ± 12.6	100 <sup>c</sup> ± 0	100 <sup>c</sup> ± 0
Epithelial proliferation and differentiation	48.3 <sup>a</sup> ± 10.2	0.3 <sup>b</sup> ± 1.9	2.3 <sup>b</sup> ± 1.1	83.3 <sup>c</sup> ± 2.4	86.7 <sup>c</sup> ± 4.7
Epithelial ballooning	13.0 <sup>a</sup> ± 15.8	53.3 <sup>b</sup> ± 4.7	37.0 <sup>a</sup> ± 18.8	16.6 <sup>a</sup> ± 2.4	10.0 <sup>c</sup> ± 0.0
Keratin proliferation	56.6 <sup>a</sup> ± 13.1	0	0	86.6 <sup>b</sup> ± 4.7	88.0 <sup>b</sup> ± 2.4
Edema	9.0 <sup>a</sup> ± 5.4	40.0 <sup>b</sup> ± 4.1	47.0 <sup>b</sup> ± 3.1	0	0
Epidermal PMN cell infiltration	10.7 <sup>a</sup> ± 3.3	85.0 <sup>b</sup> ± 4.1	73.0 <sup>b</sup> ± 3.1	3.7 <sup>c</sup> ± 0.9	4.7 <sup>b</sup> ± 3.8
Dermal PMN cell infiltration	23.3 <sup>a</sup> ± 8.5	75.0 <sup>b</sup> ± 4.1	71.0 <sup>b</sup> ± 3.1	26.6 <sup>c</sup> ± 16.5	8.3 <sup>c</sup> ± 2.4
Neovascularization	75.0 <sup>a</sup> ± 4.1	65.0 <sup>b</sup> ± 4.1	80.0 <sup>b</sup> ± 4.1	75.0 <sup>a</sup> ± 4.1	75.0 <sup>a</sup> ± 4.1
Fibroblast proliferation	61.7 <sup>a</sup> ± 8.5	75.0 <sup>b</sup> ± 4.1	65.0 <sup>b</sup> ± 4.0	81.6 <sup>b</sup> ± 6.2	83.3 <sup>b</sup> ± 6.2
Collagen proliferation index	75.0 <sup>a</sup> ± 4.1	8.3 <sup>b</sup> ± 2.6	3.3 <sup>b</sup> ± 2.3	71.7 <sup>c</sup> ± 6.2	70.0 <sup>c</sup> ± 4.1

Values are mean ± std dev. <sup>a,b,c</sup>Means within row with different superscripts are significantly different at  $p < 0.05$ . PMN = polymorphonuclear cell.

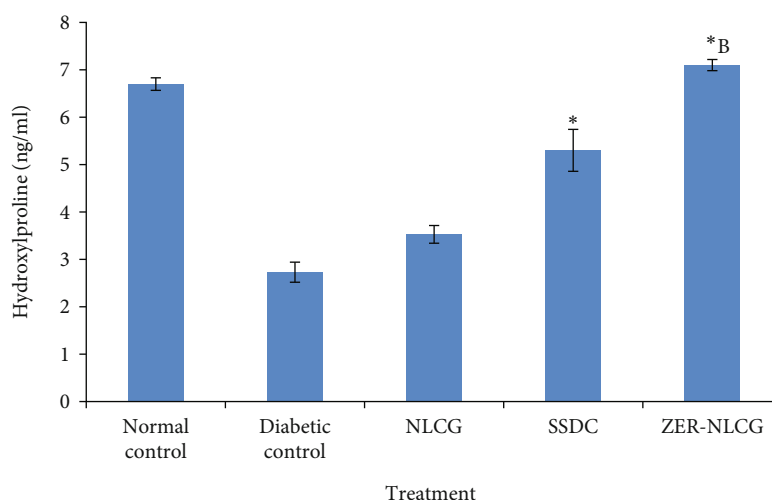


FIGURE 4: Hydroxyproline concentration in skin biopsies of diabetic rats treated with NLCG, SSDC, and ZER-NLCG. The concentrations of hydroxyproline were significantly lower in nontreated diabetic than normal rat skin. Among treatments, ZER-NLCG was the most effective in increasing hydroxyproline levels in the diabetic rat skin. Means significantly different from those of (diabetic (nontreatment) control and NLCG-treated rats)\* and SSDC-treated rats\*<sup>B</sup> at  $p < 0.05$ .

where  $A_0$  is wound area on day 0 and  $A_t$  is the wound area postwound infliction.

### 2.8. Biochemical Analysis

**2.8.1. Determination of Blood Glucose Levels.** Approximately 0.1 ml of blood was collected from the tail vein of each rat. A glucometer was used to determine the blood glucose levels immediately before and postwound infliction on days 7, 14, and 21.

**2.8.2. Determination of Collagen Synthesis.** The total collagen content in granulation tissue samples was estimated based on the hydroxyproline level. Wound tissue samples were homogenized in ice-cold tissue lysis buffer and centrifuged at  $10,000 \times g$  for 5 min, and the hydroxyproline contents in

the supernatants were quantitatively determined by ELISA (CSB-E08838r Cusabio Biotech Co., Ltd., Wuhan, China).

**2.8.3. Determination of Levels of Proinflammatory Cytokines.** Wound tissue samples were excised and wound lysates prepared using tissue lysis buffer with protease and phosphatase inhibitors and analyzed for the presence of immunoreactive IL-1 $\beta$ , IL-6, and TNF- $\alpha$  by using ELISA kits.

**2.8.4. Oxidative Stress Level Determination.** Skin tissue samples were prepared according to the method described by Albaayit et al. [28]. The activities of catalase (CAT) and superoxide dismutase (SOD) and lipid peroxidation (LPO) were determined by using ELISA kits.

**2.9. Histology.** Skin wound tissues of the rats were removed immediately after sacrifice and fixed in 10% buffered

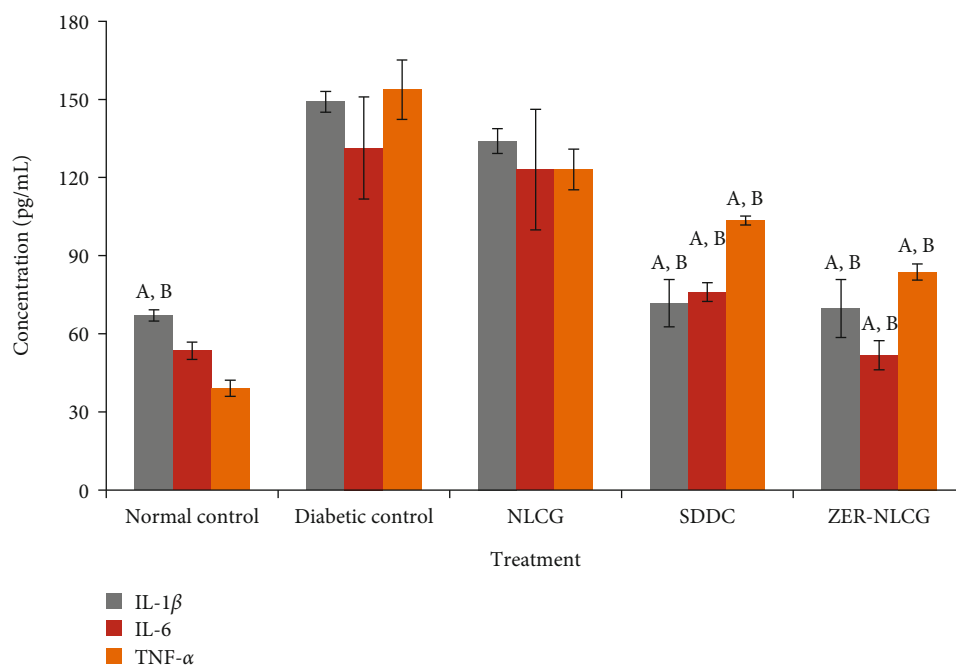


FIGURE 5: Cytokine concentrations in skin biopsies of rats treated with NLCG, SSDC, and ZER-NLCG. The concentrations of tumor necrosis factor- $\alpha$  (TNF- $\alpha$ ), interleukin-1 $\beta$  (IL-1 $\beta$ ), and interleukin-6 (IL-6) were significantly higher in nontreated diabetic than normal rat skin. Among treatments, ZER-NLCG was the most effective in reducing cytokine levels in the diabetic rat skin. Means significantly different from those of diabetic (nontreatment) control rats<sup>a</sup> and NLCG-treated rats<sup>b</sup> at  $p < 0.05$ .

formaldehyde solution pH 7.4, dehydrated through graded concentrations of 70 and 95% of absolute ethanol, cleared in xylene, and embedded in paraffin wax at the melting point of 56°C. The tissues were sectioned to 5  $\mu$ m thickness and stained with haematoxylin and eosin (H&E) and examined microscopically at 400x magnification. The wounds were histologically scored using method described by Atiba et al. [30]. Lesion parameters were scored according to their distribution in each microscopic field.

**2.10. Statistical Analysis.** Data were expressed as means  $\pm$  standard deviation (SD). Comparisons between groups and between days were performed using one-way analysis of variance (ANOVA) using GraphPad InStat version 3.0 (2000) statistical software. The level of significance was set at  $p < 0.05$ .

### 3. Results

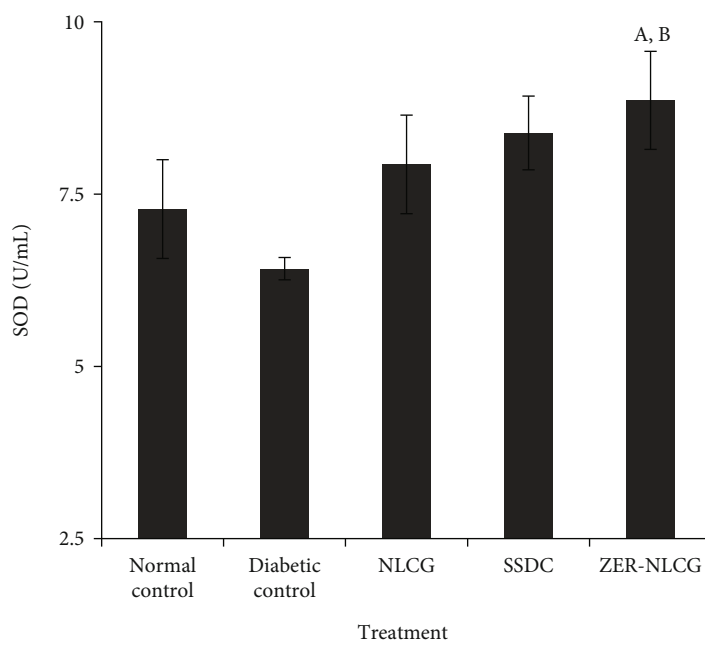
**3.1. Blood Glucose Level.** Mean blood glucose was found to be significantly stable at higher levels and in the diabetic control and NLCG-, SSDC-, and ZER-NLCG-treated diabetic rats compared to the nontreated normal rats over the 21-day period of the study (Table 1).

**3.2. Zerumbone-Nanostructure Lipid Carrier Gel Enhanced Wound Closure.** Diabetic rats treated with ZER-NLCG showed accelerated and significant wound closure with almost complete epithelialization and healing by day 21 in comparison with the nontreated diabetic control or the SSDC-treated diabetic rats (Figure 1). The rate of wound

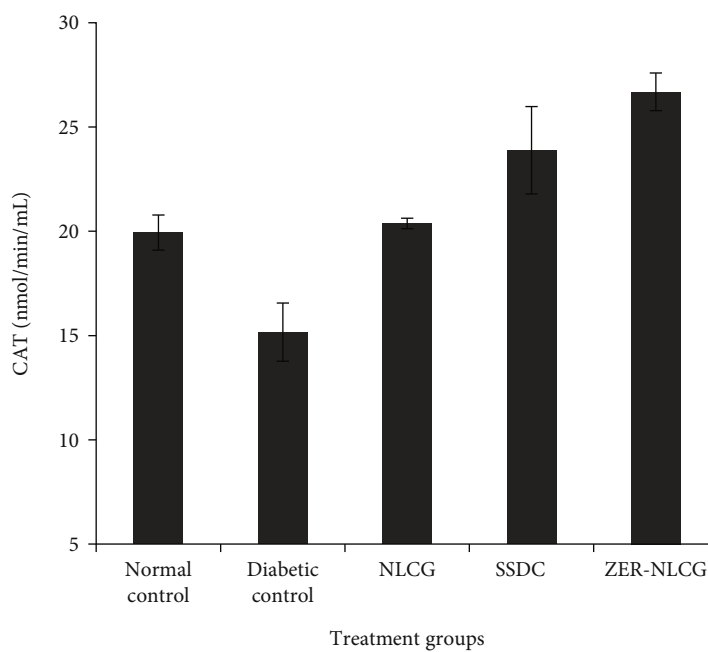
healing in diabetic rats treated with ZER-NLCG is similar to that of the normal rats. The quantitative assessment of wound healing of the treated diabetic rats is shown in Figure 2. The most significant wound contraction in order of percentage was as follows: ZER-NLCG, followed by SSDC and NLCG treatment. By day 21, wounds treated with ZER-NLCG had contracted by 96% compared to 43.7% in the nontreated normal rats.

**3.3. Histological Evaluation of Wound Tissues.** Nontreated normal and diabetic rats treated with SSDC and ZER-NLCG showed significant epithelialization in the epidermal layer and connective tissue after 21 days, which was evident in the in NLCG-treated and nontreated diabetic rats (Figure 3) (Table 2). The treated diabetic rats also showed a well-grown mature granulation tissue rich with newly formed capillaries and collagen fibers. Nontreated diabetic rats showed incomplete and mild granulation tissue in the wounds. Based on the histological changes, wound tissues of nontreated diabetic showed much slower healing than the treated diabetic rats. The effect of ZER-NLCG on wound healing was essentially similar to that of SSDC. Nontreated diabetic rats showed much slower healing than the treated diabetic rats. The effect of ZER-NLCG on wound healing was essentially similar to that of SSDC.

**3.4. Hydroxyproline.** The concentration of hydroxyproline was significantly lower ( $p < 0.05$ ) than in the skin of nontreated diabetic than normal rats (Figure 4). Treatments with NLCG, SSDC, and ZER-NLCG increased the level of hydroxyproline in the skin of the diabetic rats. ZER-NLCG



(a)



(b)

FIGURE 6: Continued.

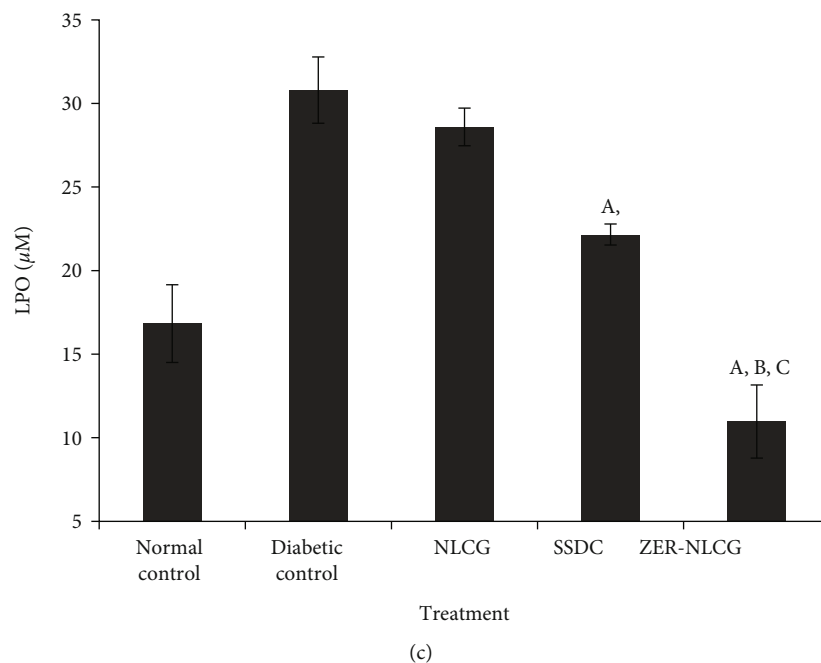


FIGURE 6: (a) Superoxide dismutase, (b) catalase, (c) glutathione peroxidase, and (d) lipid peroxidase (LPO) activities in skin biopsies of rats treated with NLCG, SSDC, and ZER-NLCG. Treatment generally increased SOD and CAT and decreased LPO activities. ZER-NLCG produced the most significant effect on the level of the enzymes. <sup>A</sup>Means significantly different from those of diabetic (nontreatment) control rats<sup>A</sup>, NLCG-treated rats<sup>B</sup>, and SSDC-treated rats<sup>C</sup> at  $p < 0.05$ .

was the most effective, among treatments, at elevating wound tissue hydroxyproline in diabetic rats to a level similar to that observed in the normal rats.

**3.5. Proinflammatory Cytokines.** Figure 5 presents the effect of treatments on the IL1- $\beta$ , IL-6, and TNF- $\alpha$  levels in the granulation tissues of control after 21 days. Treatment with NLCG, SSDC, and ZER-NLCG lowered the concentrations of cytokines in the diabetic rat skin tissue. However, significant decreases ( $p < 0.001$ ) were only observed in rats treated with SSDC and ZER-NLCG. ZER-NLCG was more effective than SSDC at reducing skin tissue cytokine levels.

**3.6. Oxidative Stress Markers in Skin Tissue.** Treatment generally increased SOD and CAT and decreased LPO activities (Figure 6). The SOD and CAT were highest while LPO activities were lowest in wound tissues of rats treated with ZER-NLCG.

#### 4. Discussion

Repair of tissue injuries is defined by several stages: coagulation and hemostasis, inflammation, proliferation, and wound modeling with scar formation. Histological changes during wound healing begin to become evident at the proliferation stage. The proliferative stage is characterized by fibroblast migration and deposition of new extracellular matrix, angiogenesis, tissue granulation, and collagen synthesis [1, 26]. Wound healing in diabetes is usually chronic and this is the result of disruption in one or more of the healing stages. One the main causes of impaired and delayed

wound healing in diabetic patients is hyperglycemia, which hampers fibroblast proliferation and decreases collagen production and impairs chemotaxis and phagocytosis [31]. In our study, nontreated diabetic rats showed incomplete and mild granulation in the wound tissues, suggesting a much slower wound healing process. Treatment with ZER-NLCG improved wound healing by prompting epithelial and keratin proliferation and epithelial differentiation. In the ZER-NLCG-treated rats, complete wound closure was observed by 21 days of treatment. This finding is supported by study from Gourishetti and colleague who indicates that the use of Sesamol-loaded PLGA nanosuspension accelerates wound healing and 90% wound closure was observed on day 15 of treatment [32].

There is ongoing search for new and cheaper therapeutic compounds from natural sources that could be used to heal wounds [33–39]. Among these compounds is zerumbone from the essential oil of the rhizomes of *Zingiber zerumbet* [40]. In pure crystalline form, zerumbone is water-insoluble due to which it has poor bioavailability and distribution in the body thus decreases its therapeutic potential. Recently, it was reported that zerumbone solubility increases upon loading into NLC [41]. The loading of zerumbone in NLC improves the biodistribution and effectiveness of the complex, allowing for parentally application of otherwise a water-insoluble compound.

Wound size and contraction are parameters used to evaluate healing of injured tissues [42–44]. In our study, wound contraction is determined by the percentage reduction in size of postwound infliction. The application of ZER-NLCG had hastened wound healing in diabetic rats through



the influence of its active principle, zerumbone. Diabetic rats showed better wound healing after ZER-NLCG than SSDC treatment. ZER-NLCG decreased the infiltration inflammatory cells and increased intensity of collagen maturation and distribution in the wound tissues. The study showed that ZER-NLCG healed wounds without scarring.

Hydroxyproline is a major component of collagen. Hydroxyproline functions to stabilize the triple helix structure of collagen. The molecule is also used as an indicator of collagen content in tissues [45]. In wound healing, collagen formation peaks and under optimal condition epithelialization occurs after 22 to 48 postinjury [46]. ZER-NLCG significantly ( $p < 0.001$ ) increased wound tissue hydroxyproline level (Figure 4), suggesting that there were increased synthesis and deposition of collagen in the wound tissues with the treatment. Based on the hydroxyproline level, ZER-NLCG was more efficacious at healing wounds in diabetic rats than SSDC.

Inflammation plays a vital role in normal wound healing process [47–49]. Inflammation delays healing of injured tissues and can cause increased scarring [50, 51]. In diabetes, tissue injuries are associated with elevated levels of proinflammatory cytokines [52] that affect the recruitment of various inflammatory cells and function of fibroblast and keratinocyte, production of extracellular matrix, and angiogenesis and impaired wound healing [5, 53]. In diabetic rats, ZER-NLCG more than SSDC significantly downregulated the proinflammatory cytokines, TNF- $\alpha$ , IL-1 $\beta$ , and IL-6. These findings highlight that the inhibition inflammatory response is one of the many facets of the wound healing effects of ZER-NLCG.

Oxidative stress in tissues is the result of the imbalance between the level of reactive oxygen species (ROS) and the ability of antioxidative mechanism to remove the ROS [54, 55]. While low tissue ROS levels initiate, high levels hinder the normal process of tissue healing [56, 57]. The tissue ROS level is high in diabetes due to decrease or/and increase in catalase (CAT), superoxide dismutase (SOD), and glutathione peroxidase (GSH-Px) production. The constant state of hyperglycemia in diabetes also increases the production of free radicals via the oxidation of glucose and the glycation of nonenzymatic proteins [58]. ZER-NLCG exerts antioxidant effects by increasing SOD and CAT and decreasing LPO activities. These effects of ZER-NLCG prevented inflammation and oxidative damage and promoted healing of wounds in diabetic rats. Previous study has also indicate that sustained drug release as in our study using ZER-NCLG are able to reduce the level of reactive oxygen species (ROS) thus increasing its antioxidant activity and promotes a much faster wound healing [59, 60].

## 5. Conclusion

Topical applications of ZER-NLCG might effectively improve wound healing in streptozotocin-induced diabetic rats by suppressing production of proinflammatory cytokines, reducing inflammatory response, increasing collagen deposition, and reducing the effect of ROS by stimulating production of antioxidant enzymes without scarring.

## Data Availability

Data used to support the findings of this study are included within the article.

## Conflicts of Interest

The authors declare that they have no conflicts of interest.

## Acknowledgments

This study was financially supported by the University of Malaya PPP Grant no. PG059-2013A.

## References

- [1] A. C. Gonzalez, T. F. Costa, Z. A. Andrade, and A. R. Medrado, "Wound healing - a literature review," *Anais Brasileiros de Dermatologia*, vol. 91, no. 5, pp. 614–620, 2016.
- [2] J. M. Reinke and H. Sorg, "Wound repair and regeneration," *European Surgery Research*, vol. 49, no. 1, pp. 35–43, 2012.
- [3] G. P. Fadini, M. Albiero, B. M. Bonora, and A. Avogaro, "Angiogenic abnormalities in diabetes mellitus: mechanistic and clinical aspects," *The Journal of Clinical Endocrinology & Metabolism*, vol. 104, no. 11, pp. 5431–5444, 2019.
- [4] L. Deng, C. Du, P. Song et al., "The role of oxidative stress and antioxidants in diabetic wound healing," *Oxidative Medicine and Cellular Longevity*, vol. 2021, Article ID 8852759, 2021.
- [5] S. Patel, S. Srivastava, M. R. Singh, and D. Singh, "Mechanistic insight into diabetic wounds: pathogenesis, molecular targets and treatment strategies to pace wound healing," *Biomedicine & Pharmacotherapy*, vol. 112, article 108615, 2019.
- [6] U. A. Okonkwo and L. A. DiPietro, "Diabetes and wound angiogenesis," *International Journal of Molecular Sciences*, vol. 18, no. 7, p. 1419, 2017.
- [7] S. I. Mohammed, E. M. Mikhael, F. T. Ahmed, H. F. Al-Tukmagi, and A. L. Jasim, "Risk factors for occurrence and recurrence of diabetic foot ulcers among Iraqi diabetic patients," *Diabetic Foot & Ankle*, vol. 7, no. 1, article 29605, 2016.
- [8] J. R. S. Rex, N. M. S. A. Muthukumar, and P. M. Selvakumar, "Phytochemicals as a potential source for anti-microbial, anti-oxidant and wound healing - a review," *MOJ Biorganic and Organic Chemistry*, vol. 2, no. 2, pp. 61–70, 2018.
- [9] R. L. Thangapazham, S. Sharad, and R. K. Maheshwari, "Phytochemicals in wound healing," *Advances in Wound Care*, vol. 5, no. 5, pp. 230–241, 2016.
- [10] N. Sallehuddin, A. Nordin, R. Bt Hj Idrus, and M. B. Fauzi, "Nigella sativa and its active compound, thymoquinone, accelerate wound healing in an in vivo animal model: a comprehensive review," *International Journal of Environmental Research and Public Health*, vol. 17, no. 11, article 4160, 2020.
- [11] W. Y. Liu, T. F. Tzeng, and I. M. Liu, "Healing potential of zerumbone ointment on experimental full-thickness excision cutaneous wounds in rat," *Journal of Tissue Viability*, vol. 26, no. 3, pp. 202–207, 2017.
- [12] S. D. Fitzmaurice, R. K. Sivamani, and R. R. Isseroff, "Antioxidant therapies for wound healing: a clinical guide to currently commercially available products," *Skin Pharmacology and Physiology*, vol. 24, no. 3, pp. 113–126, 2011.

- [13] A. G. Atiyah and N. H. R. Al-Falahi, "The role of Helianthus tuberosus powder in healing of full-thickness wounds in mice," *Veterinary World*, vol. 14, no. 5, pp. 1290–1298, 2021.
- [14] E. E. M. Eid, A. B. Abdul, F. E. O. Suliman, M. A. Sukari, A. Rasedee, and S. S. Fatah, "Characterization of the inclusion complex of zerumbone with hydroxypropyl- $\beta$ -cyclodextrin," *Carbohydrate Polymers*, vol. 83, no. 4, pp. 1707–1714, 2011.
- [15] J. K. Patra, G. Das, L. F. Fraceto et al., "Nano based drug delivery systems: recent developments and future prospects," *Journal of Nanobiotechnology*, vol. 16, no. 1, p. 71, 2018.
- [16] F. A. N. Azar, A. Pezeshki, B. Ghanbarzadeh, H. Hamishehkar, and M. Mohammadi, "Nanostructured lipid carriers: promising delivery systems for encapsulation of food ingredients," *Journal of Agriculture and Food Research*, vol. 2, article 100084, 2020.
- [17] M. Haider, S. M. Abdin, L. Kamal, and G. Orive, "Nanostructured lipid carriers for delivery of chemotherapeutics: a review," *Pharmaceutics*, vol. 12, no. 3, p. 288, 2020.
- [18] S. A. Khan, S. Rehman, B. Nabi et al., "Boosting the brain delivery of atazanavir through nanostructured lipid carrier-based approach for mitigating neuroaids," *Pharmaceutics*, vol. 12, no. 11, p. 1059, 2020.
- [19] C. W. How, R. Abdullah, and R. Abbasalipourkabir, "Physico-chemical properties of nanostructured lipid carriers as colloidal carrier system stabilized with polysorbate 20 and polysorbate 80," *African Journal of Biotechnology*, vol. 10, no. 9, pp. 1684–1689, 2011.
- [20] S. F. A. Albaayit, "Enzyme inhibitory properties of zerumbone," *Pakistan Journal of Agricultural Sciences*, vol. 58, no. 3, pp. 1207–1209, 2021.
- [21] S. F. A. Albaayit, R. Maharjan, R. Abdullah, and M. H. Mohd Noor, "Evaluation of anti-methicillin-resistant Staphylococcus aureus property of zerumbone," *Journal of Applied Biomedicine*, vol. 20, no. 1, 2022.
- [22] S. F. A. Albaayit, K. H. A. N. Mariam, and R. Abdullah, "Zerumbone induces growth inhibition of Burkitt's lymphoma cell line via apoptosis," *Natural Volatiles and Essential Oils*, vol. 8, no. 3, pp. 56–63, 2021.
- [23] M. Jalili-Nik, M. M. Sadeghi, E. Mohtashami, H. Mollazadeh, A. R. Afshari, and A. Sahebkar, "Zerumbone promotes cytotoxicity in human malignant glioblastoma cells through reactive oxygen species (ROS) generation," *Oxidative Medicine and Cellular Longevity*, vol. 2020, 9 pages, 2020.
- [24] J. N. Foong, G. T. Selvarajah, A. Rasedee et al., "Zerumbone-loaded nanostructured lipid carrier induces apoptosis of canine mammary adenocarcinoma cells," *BioMed Research International*, vol. 2018, Article ID 8691569, 2018.
- [25] H. S. Rahman, A. Rasedee, C. W. How et al., "Zerumbone-loaded nanostructured lipid carriers: preparation, characterization, and antileukemic effect," *International Journal of Nanomedicine*, vol. 8, pp. 2769–2781, 2013.
- [26] S. F. A. Albaayit, A. Rasedee, and N. Abdullah, "Zerumbone-loaded nanostructured lipid carrier gel facilitates wound healing in rats," *Revista Brasileira de Farmacognosia*, vol. 30, no. 2, pp. 272–278, 2020.
- [27] A. Al-Awar, K. Kupai, M. Veszeka et al., "Experimental diabetes mellitus in different animal models," *Journal of Diabetes Research*, vol. 2016, 12 pages, 2016.
- [28] S. F. A. Albaayit, Y. Abba, A. Rasedee, and N. Abdullah, "Effect of *Clausena excavata* Burm. f. (Rutaceae) leaf extract on wound healing and antioxidant activity in rats," *Drug Design, Development and Therapy*, vol. 9, pp. 3507–3518, 2015.
- [29] S. B. Nayak, L. P. Pereira, and D. Maharaj, "Wound healing activity of *Carica papaya* L. in experimentally induced diabetic rats," *Indian Journal of Experimental Biology*, vol. 45, no. 8, pp. 739–743, 2007.
- [30] A. Atiba, H. Ueno, and Y. Uzuka, "The effect of aloe vera oral administration on cutaneous wound healing in type 2 diabetic rats," *The Journal of Veterinary Medical Science*, vol. 73, no. 5, pp. 583–589, 2011.
- [31] S. F. Spampinato, G. I. Caruso, R. De Pasquale, M. A. Sortino, and S. Merlo, "The treatment of impaired wound healing in diabetes: looking among old drugs," *Pharmaceutics*, vol. 13, no. 4, p. 60, 2020.
- [32] K. Gourishetti, R. Keni, P. G. Nayak et al., "Sesamol-loaded PLGA nanosuspension for accelerating wound healing in diabetic foot ulcer in rats," *International Journal of Nanomedicine*, vol. 15, pp. 9265–9282, 2020.
- [33] S. F. A. Albaayit, R. Maharjan, R. Abdullah, and M. H. M. Noor, "Anti-Enterococcus Faecalis, Cytotoxicity, Phytotoxicity, and Anticancer Studies on *Clausena excavata* Burm. f. (Rutaceae) Leaves," *BioMed Research International*, vol. 2021, 9 pages, 2021.
- [34] S. F. Albaayit, M. Khan, R. Abdullah, and M. H. Noor, "Ethyl acetate extract of *Clausena excavata* induces growth inhibition of non-small-lung cancer, NCI-H460, cell line via apoptosis," *Journal of Applied Biomedicine*, vol. 19, no. 1, pp. 40–47, 2021.
- [35] S. F. A. Albaayit, "Evaluation of anti-methicillin resistant Staphylococcus aureus property of *Clausena excavata* leaves by using atomic force microscopy and flow cytometry techniques," *Pakistan Journal of Agricultural Sciences*, vol. 58, no. 1, 2021.
- [36] R. M. Al-Bahrani, H. M. Radif, and S. F. A. Albaayit, "Evaluation of potent silver nanoparticles production from *Agaricus bisporus* against *Helicobacter pylori*," *Pakistan Journal of Agricultural Sciences*, vol. 57, no. 4, pp. 1197–1201, 2020.
- [37] L. K. T. Al-Ani, M. I. Yonus, B. A. Mahdii et al., "First record of use *Fusarium proliferatum* fungi in direct treatment to control the adult of wheat flour *Tribolium confusum*, as well as, use the entomopathogenic fungi *Beauveria bassiana*," *Ecology, Environment and Conservation*, vol. 24, no. 3, pp. 29–34, 2018.
- [38] S. F. A. Albaayit, "In vitro evaluation of anticancer activity of *Moringa peregrina* seeds on breast cancer cells," *The Eurasia Proceedings of Science Technology Engineering and Mathematics*, vol. 11, pp. 163–166, 2020.
- [39] S. F. A. Albaayit and M. Ozaslan, "Cytotoxic and urease inhibition potential of *Moringa peregrina* seed ethanolic extract," *International Journal of Pharmacology*, vol. 15, no. 1, pp. 151–155, 2019.
- [40] S. F. A. Albaayit, R. Maharjan, and M. Khan, "Evaluation of hemolysis activity of zerumbone on RBCs and brine shrimp toxicity," *Baghdad Science Journal*, vol. 18, no. 1, pp. 0065–0069, 2021.
- [41] S. S. Kesharwani and G. J. Bhat, "Formulation and nanotechnology-based approaches for solubility and bioavailability enhancement of zerumbone," *Medicina*, vol. 56, no. 11, p. 557, 2020.
- [42] M. Flanagan, "Wound measurement: can it help us to monitor progression to healing?," *Journal of Wound Care*, vol. 12, no. 5, pp. 189–194, 2003.

- [43] M. Flanagan, "Improving accuracy of wound measurement in clinical practice," *OstomyWound Management*, vol. 49, pp. 38–43, 2003.
- [44] M. A. Abdul-Samad, M. A. Kadhun, B. S. Hamza, and M. M. Hamed, "The effect of Aloe vera acetone extract on wound contraction and re-epithelization on full thickness excisional wound in female rabbits," *Al-Qadisiyah Journal of Veterinary Medicine Sciences*, vol. 7, no. 2, pp. 44–49, 2008.
- [45] C. S. Samuel, "Determination of collagen content, concentration, and sub-types in kidney tissue," *Methods in Molecular Biology*, vol. 466, pp. 223–235, 2009.
- [46] M. Rodrigues, N. Kosaric, C. A. Bonham, and G. C. Gurtner, "Wound healing: a cellular perspective," *Physiological Reviews*, vol. 99, no. 1, pp. 665–706, 2019.
- [47] S. A. Eming, B. Bent, O. Teresa, and K. Manuel, "Regulation of angiogenesis: wound healing as a model," *A Progress in Histochemistry and Cytochemistry*, vol. 42, no. 3, pp. 115–170, 2007.
- [48] S. A. Eming, S. Werner, P. Bugnon et al., "Accelerated wound closure in mice deficient for interleukin-10," *American Journal of Pathology*, vol. 170, no. 1, pp. 188–202, 2007.
- [49] R. J. Bodnar, "Chemokine regulation of angiogenesis during wound healing," *Advances in Wound Care*, vol. 4, no. 11, pp. 641–650, 2015.
- [50] S. F. A. Albaayit, A. Rasedee, N. Abdullah, and Y. Abba, "Methanolic extract of *Clausena excavata* promotes wound healing via antiinflammatory and anti-apoptotic activities," *Asian Pacific Journal of Tropical Biomedicine*, vol. 10, no. 5, pp. 232–238, 2020.
- [51] S. A. Eming, T. Krieg, and J. M. Davidson, "Inflammation in wound repair: molecular and cellular mechanisms," *Journal of Investigative Dermatology*, vol. 127, no. 3, pp. 514–525, 2007.
- [52] N. Fatima, S. M. Faisal, S. Zubair et al., "Role of pro-inflammatory cytokines and biochemical markers in the pathogenesis of type 1 diabetes: correlation with age and glycemic condition in diabetic human subjects," *PLoS One*, vol. 11, no. 8, article e0161548, 2016.
- [53] S. F. A. Albaayit, A. S. K. Al-Khafaji, and H. S. Alnaimy, "In vitro macrophage nitric oxide and interleukin-1 beta suppression by *Moringa peregrina* seed," *Turkish Journal of Pharmaceutical Sciences*, vol. 16, no. 3, pp. 362–365, 2019.
- [54] S. F. A. Albaayit and R. Maharjan, "Immunomodulation of zerumbone via decreasing the production of reactive oxygen species from immune cells," *Pakistan Journal of Biological Sciences*, vol. 21, no. 9, pp. 475–479, 2018.
- [55] S. F. A. Albaayit, Y. Abba, R. Abdullah, and N. Abdullah, "Evaluation of antioxidant activity and acute toxicity of *Clausena excavata* leaves extract," *Evidence-based Complementary and Alternative Medicine*, vol. 2014, 10 pages, 2014.
- [56] S. F. A. Albaayit, Y. Abba, R. Abdullah, and N. Abdullah, "Prophylactic effects of *Clausena excavata* Burum. f. leaf extract in ethanol-induced gastric ulcers," *Drug Design, Development and Therapy*, vol. 10, pp. 1973–1986, 2016.
- [57] M. Martins-Green and S. Saeed, "Chapter 2 - role of oxidants and antioxidants in diabetic wound healing," in *Wound Healing, Tissue Repair, and Regeneration in Diabetes*, D. Bagchi, A. Das, and S. Roy, Eds., pp. 13–38, Academic Press, 2020.
- [58] U. Asmat, K. Abad, and K. Ismail, "Diabetes mellitus and oxidative stress – a concise review," *Saudi Pharmaceutical Journal*, vol. 24, no. 5, pp. 547–553, 2016.
- [59] K. K. Ghaima, "Antibacterial and wound healing activity of some *Agrimonia eupatoria* extracts," *Baghdad Science Journal*, vol. 10, no. 1, pp. 152–160, 2013.
- [60] M. V. Vanessa, R. Srinivas, R. V. Jitta, and K. Lalit, "Hesperetin loaded proposomal gel for topical antioxidant activity," *Journal of Drug Delivery Science and Technology*, vol. 66, article 102873, 2021.