

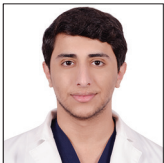## Case Report

# Xanthogranuloma of the suprasellar region mimicking cystic craniopharyngioma: A case report

Abdulaziz M. Alghamdi<sup>1,2</sup>, Abdulkarim M. Alghamdi<sup>1,2</sup> , Alaa Samkari<sup>1,2,3</sup> , Afnan Samman<sup>2,4</sup>, Ahmed Lary<sup>1,2,4</sup>

<sup>1</sup>College of Medicine, King Saud Bin Abdulaziz University for Health Sciences, <sup>2</sup>King Abdullah International Medical Research Center, Departments of <sup>3</sup>Pathology and Laboratory Medicine and <sup>4</sup>Neurosurgery, King Abdulaziz Medical City, National Guard Health Affairs, Jeddah, Saudi Arabia.

E-mail: \*Abdulaziz M. Alghamdi - [abdulazizmahdigh@gmail.com](mailto:abdulazizmahdigh@gmail.com); Abdulkarim M. Alghamdi - [kreemsg@gmail.com](mailto:kreemsg@gmail.com); Alaa Samkari - [samkari@mngha.med.sa](mailto:samkari@mngha.med.sa); Afnan Samman - [afnan.m.samman@gmail.com](mailto:afnan.m.samman@gmail.com); Ahmed Lary - [ahmed.lary.frccs@hotmail.com](mailto:ahmed.lary.frccs@hotmail.com)



### \*Corresponding author:

Abdulaziz M. Alghamdi,  
College of Medicine, King Saud  
Bin Abdulaziz University for  
Health Sciences, Jeddah,  
Saudi Arabia.

[abdulazizmahdigh@gmail.com](mailto:abdulazizmahdigh@gmail.com)

Received: 01 August 2023

Accepted: 24 August 2023

Published: 15 September 2023

DOI

[10.25259/SNI\\_646\\_2023](https://doi.org/10.25259/SNI_646_2023)

Quick Response Code:



## ABSTRACT

**Background:** Xanthogranuloma of the sellar region is an extremely rare benign entity with only case reports and series documented in the literature. We aim to describe in this report a case of a suprasellar xanthogranuloma that was diagnosed initially as a cystic craniopharyngioma.

**Case Description:** A 28-year-old woman presented to the clinic with a 2-week history of headaches, blurred vision, nausea, and vomiting. She had no medical or surgical history, no signs of hormonal disturbances, and no family history of brain tumors or endocrine diseases. Her neurological examination was unremarkable except for bitemporal hemianopia on visual field testing. A magnetic resonance imaging of the brain showed a cystic mass in the sellar region that was compressing the optic chiasm with radiological features representing cystic craniopharyngioma. She underwent endoscopic transnasal transsphenoidal surgery to excise the mass, and only subtotal excision was achieved to preserve the pituitary function. The histopathology confirmed the diagnosis of a xanthogranuloma of the sellar region. The postoperative course was unremarkable, and she did not receive any adjuvant therapy. There was no recurrence of the clinical symptoms or the mass during the 18-month follow-up period.

**Conclusion:** Although xanthogranuloma is uncommon, it should be included in the differential diagnosis of sellar/suprasellar lesions. Due to its wide range of radiological features that sometimes can mimic other lesions, a definitive diagnosis can only be made postoperatively. Surgical excision is the most accepted treatment with a favorable prognosis and low rates of recurrence.

**Keywords:** Case report, Craniopharyngioma, Sellar region, Suprasellar region, Xanthogranuloma

## INTRODUCTION

Sellar masses can present with a wide range of clinical and radiological features. Their presentations can range from asymptomatic incidental and hormonal effects to compressive local mass effects with presenting symptoms related to the specific anatomical landmarks of the sella turcica and the surrounding parasellar region.<sup>[2,3]</sup> A 10-year retrospective analysis of 1367 abnormal sellar/parasellar magnetic resonance imaging (MRI) findings found that the most common diagnosis was pituitary adenoma and only 216 cases (18%) were non-adenomatous lesions. Out of the 216 cases, 42 (19%) were Rathke's cleft cysts, 32 (15%) were craniopharyngiomas, 32 (15%) were meningiomas, and only one case (0.7%) of xanthogranuloma.<sup>[2,3]</sup> Xanthogranuloma, also known

This is an open-access article distributed under the terms of the Creative Commons Attribution-Non Commercial-Share Alike 4.0 License, which allows others to remix, transform, and build upon the work non-commercially, as long as the author is credited and the new creations are licensed under the identical terms.

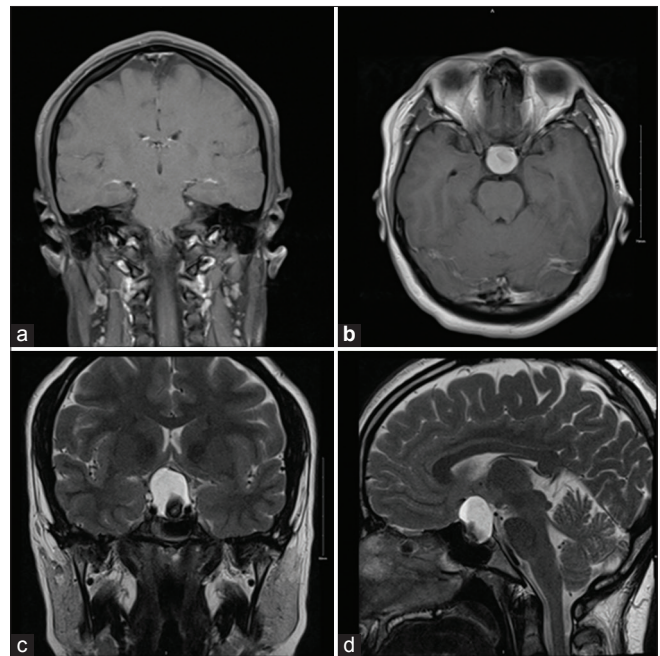
©2023 Published by Scientific Scholar on behalf of Surgical Neurology International

as cholesterol granuloma, is a non-neoplastic histological rare brain lesion characterized by both granuloma and xanthoma cells and is usually located in the middle ear, petrous apex, paranasal sinuses, choroid plexus, and trigone of the lateral ventricle.<sup>[3,4]</sup> Xanthogranuloma of the sellar region is an extremely rare entity with only case reports and series documented in the literature. A recent systematic review of sellar, suprasellar, and parasellar xanthogranuloma cases found only 71 cases in the literature.<sup>[3]</sup> According to the recent 5<sup>th</sup> edition of the World Health Organization (WHO) classification of central nervous system (CNS) tumors, it is considered to be a reactive lesion from other tumors, such as craniopharyngiomas and Rathke's cleft cysts, arising from chronic irritation or trauma.<sup>[7]</sup> Preoperatively, diagnosing a sellar xanthogranuloma based on clinical and radiological features is challenging; however, it usually has a favorable outcome.<sup>[3,4]</sup> Considering the rarity of this entity, we aim to describe a rare case of a suprasellar xanthogranuloma that was diagnosed initially as a cystic craniopharyngioma.

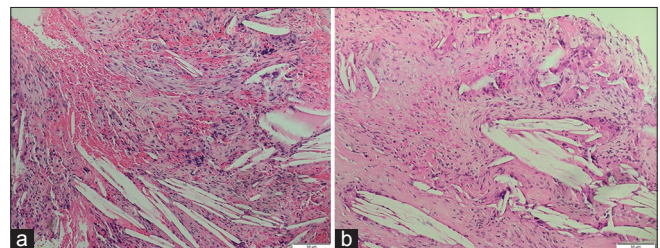
## CASE DESCRIPTION

A 28-year-old Saudi right-handed woman, who is not known to have any medical or surgical history, presented to the clinic with a history of right-sided headaches associated with blurred vision for the past 2 weeks. The headache was severe, sudden, tension-like, associated with nausea and infrequent vomiting, and partially relieved by acetaminophen tablets. She had no history of trauma, loss of consciousness, or seizure. She had a history of irregular menses since puberty for which she was not investigated before. She had no symptoms of thyroid dysfunction or other hormonal disorders. She had no family history of brain tumors or endocrine diseases, and she was not taking any regular medications. Other systemic reviews were unremarkable. On examination, she was vitally stable, conscious, alert, and oriented. She had bitemporal hemianopia on visual field testing. Other cranial nerves, motor, sensory, and cerebellar functions were all intact. Her hormonal profile and laboratory tests were unremarkable. She underwent a brain MRI which demonstrated a clear intrasellar and suprasellar mass measuring 2.5 cm in its largest axis that was compressing the optic chiasm and displacing the anterior communicating artery [Figure 1]. The mass appeared predominantly cystic with an internal area of mixed signal intensity and enhancement at the anterior lateral side of the cyst. The preoperative diagnosis based on the radiological features was consistent with cystic craniopharyngioma. As the patient was symptomatic, surgical management was offered to her. Two weeks after the presentation, she underwent an elective endoscopic transnasal transsphenoidal surgery to excise the lesion. The ear, nose, and throat team exposed the sellar region endonasally, after which the neurosurgery team proceeded to resect the mass. Intraoperatively, as a small portion of the

lesion was attached to the pituitary gland without a clear plan for separation, only subtotal excision was achieved to prevent hormonal imbalances in the patient. The postoperative course was unremarkable, and the patient made a full recovery and was discharged on the 6<sup>th</sup> postoperative day. The specimen was sent for histopathological examination which showed foamy macrophages, chronic inflammatory cells, multinucleated giant cells, necrotic debris, hemosiderin deposits, and cholesterol clefts [Figure 2]. The histopathological findings confirmed the diagnosis of a xanthogranuloma of the sellar region. A 1-month follow-up brain MRI revealed a residual tumor with calcific and cystic components [Figure 3]. The patient was evaluated by the radiation oncology team for potential adjuvant therapy, but it was deemed unnecessary due to the low grade of the tumor; so no adjuvant chemotherapy or radiotherapy was given to the patient. A 6-month postoperative follow-up brain MRI



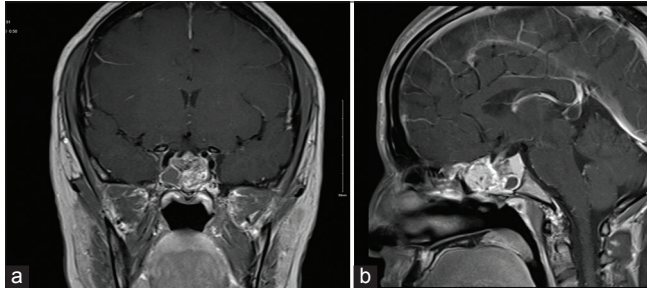
**Figure 1:** (a and b) preparative coronal and axial T1-weighted MRI with contrast and (c and d) preparative coronal and sagittal T2-weighted MRI.



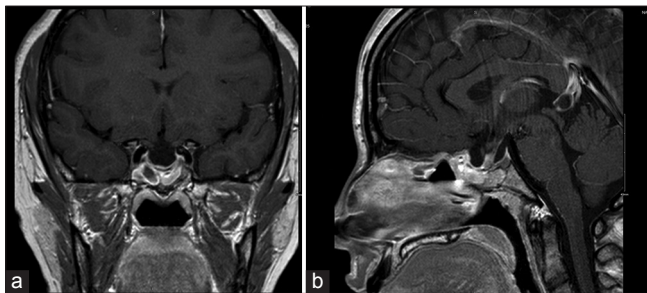
**Figure 2:** (a and b) Hematoxylin and eosin staining of the resected mass showed cholesterol clefts, macrophages, chronic inflammatory cells, necrotic debris, and hemosiderin deposits.



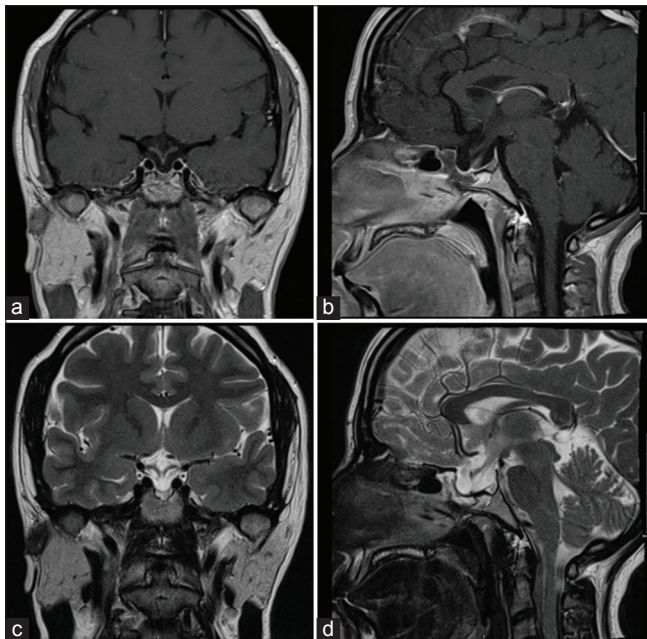
showed marked improvement in the size and appearance of the residual lesion with no evidence of recurrence [Figure 4]. Moreover, an 18-month follow-up brain MRI revealed no signs of tumor recurrence and a stable lesion appearance [Figure 5]. The patient experienced no recurrence of the



**Figure 3:** (a and b) 1-month postoperative coronal and sagittal T1-weighted MRI with contrast.



**Figure 4:** (a and b) 6-months postoperative coronal and sagittal T1-weighted MRI with contrast.



**Figure 5:** (a and b) 18-months postoperative coronal and sagittal T1-weighted MRI with contrast and (c and d) 18-months postoperative coronal and sagittal T2-weighted MRI.

clinical symptoms during the follow-up period and was discharged from the clinic as she was moving to live abroad.

## DISCUSSION

Xanthogranuloma is a benign histological entity characterized by a persistent chronic inflammatory reaction to the presence of cholesterol crystals in an enclosed space, secondary to either hemorrhage, infarction, inflammation, or necrosis. Inflammatory reaction markers of this entity include granulomatous tissue with cholesterol clefts, hemosiderin deposits, macrophages containing lipid-rich foam cells (also known as xanthoma cells), multinucleated giant cells, and lymphocytes.<sup>[3,4]</sup> Xanthogranuloma is a different entity than juvenile xanthogranuloma, which was added to the WHO classification of CNS tumors in 2016 as a primary CNS lesion of the non-Langerhans cell histiocytosis spectrum. Therefore, these two entities should not be confused with each other.<sup>[3,7]</sup> Xanthogranuloma can occur in any part of the body, but the most common site of occurrence is in the petrous apex of the anterior skull base.<sup>[1,8]</sup> Sellar xanthogranuloma is an extremely rare entity with an incident rate of 0.7% among 1367 positive sellar/parasellar MRI findings.<sup>[2]</sup> It was first described by Shirataki *et al.* in 1988.<sup>[6]</sup> The classification of xanthogranuloma has changed several times during the past decades. At first, it was thought to be a granulomatous reaction of sellar cystic lesions such as craniopharyngioma. Then, in 2000, it was announced as a distinct entity that is independent of other sellar cystic lesions by the WHO classification of CNS tumors.<sup>[3]</sup> Finally, according to the recent 5<sup>th</sup> edition of the WHO classification of CNS tumors that was released in 2021, xanthogranuloma is now considered to be a reactive lesion from other tumors arising from chronic inflammatory status as proven by the latest findings.<sup>[7]</sup>

The clinical presentation of sellar xanthogranuloma is nonspecific with no selective gender or age distribution. It can range from completely asymptomatic presentations to mass-effect symptoms such as headaches, visual disturbances, and endocrine disturbances, which are similar to other sellar lesions.<sup>[3,8]</sup> Other less common clinical manifestations reported in the literature were diabetes insipidus and obstructive hydrocephalus.<sup>[8]</sup> Our case had both headaches and visual disturbance in the form of bitemporal hemianopia, which is the classic presentation of sellar lesions.

Preoperative diagnosis of sellar xanthogranuloma can be challenging as its radiological features are variant and can resemble other sellar lesions as a reflective measure of the complexity of its histologic components.<sup>[8]</sup> Some helpful radiological features that have been described by previous reports are suprasellar involvement, hyperintensity in T1-weighted images, heterogeneous appearance in T2-weighted images, and peripheral contrast enhancement.<sup>[3]</sup> Other useful radiological features to rule out

sellar xanthogranuloma are the presence of calcification and cavernous sinus infiltration. All these radiological features have been suggested as typical of xanthogranuloma of the sellar region. However, variants can still exist, and definitive diagnosis requires pathological examination as it tends to have typical histopathological features.<sup>[3,8]</sup> Preoperative differential diagnoses of sellar xanthogranuloma include craniopharyngioma, Rathke's cleft cyst, and pituitary adenoma. Our case showed a heterogeneous cystic appearance mass on the brain MRI scan, which subsequently led to the misdiagnosis of cystic craniopharyngioma as it had its typical radiological features. This heterogeneous cystic appearance most likely resulted from intralesional focal hemorrhage and hemosiderin deposits.<sup>[8]</sup> This cystic component, when present, adds more difficulty to the preoperative diagnosis and can lead to a higher degree of misdiagnosis. Three reported cases of sellar/suprasellar xanthogranuloma by Pilonieta *et al.* initially showed cystic features on brain MRI scans and, therefore, were misdiagnosed as cystic pituitary prolactinoma and 2 Rathke's cleft cysts.<sup>[5]</sup>

Surgical gross total resection is the most acceptable treatment approach in symptomatic patients, with permanent panhypopituitarism reported as one of the most common surgical complications.<sup>[3,4]</sup> Although gross total resection is preferable to decrease the chances of tumor regrowth and recurrence, its benefits and harms should be considered. In our case, gross total resection could not be achieved as a small part of the tumor was adherent to the pituitary gland, and the risk of panhypopituitarism was high with resecting it. Hence, we decided to go with a subtotal gross resection only to preserve the quality of life of our young patient. Other reported less common surgical complications were visual disturbance and intraoperative bleeding. Moreover, there has been no role of treatment beyond surgical resection in the majority of cases in the literature. Mainly, the prognosis of sellar xanthogranuloma is favorable with very low chances of recurrence that were all related to tumor residual and no reported cases of mortality in the literature.<sup>[3,5]</sup>

### Limitations

This study has some limitations as it only included one case report of sellar xanthogranuloma. However, considering how rare this condition is, we aim to contribute to the literature to help in understanding these lesions more. Further studies with more cases of sellar xanthogranuloma to help understand the underlying causes and predict the prognosis are recommended.

### CONCLUSION

Sellar xanthogranuloma is an extremely rare lesion. Nevertheless, it should be included in the differential

diagnosis of sellar/suprasellar lesions. It exhibits a wide range of radiological features, making diagnosing preoperatively difficult. This makes histopathological examination the definitive way of diagnosis. Surgical excision is the main treatment. It has a favorable prognosis with low rates of recurrence, only reported in subtotal gross resected cases. However, the benefits and harms of gross total surgical resection should be considered as it can cause permanent complications to the patients.

### Declaration of patient consent

The authors certify that they have obtained all appropriate patient consent.

### Financial support and sponsorship

Nil.

### Conflicts of interest

There are no conflicts of interest.

### Use of artificial intelligence (AI)-assisted technology for manuscript preparation

The author(s) confirms that there was no use of artificial intelligence (AI)-assisted technology for assisting in the writing or editing of the manuscript and no images were manipulated using AI.

### REFERENCES

- Ahmetgjekaj I, Harizi E, Rahman A, Hyseni F, Nasir F, Decka A, *et al.* Giant cholesterol granuloma of petrous apex. *Radiol Case Rep* 2022;17:1220-4.
- Famini P, Maya MM, Melmed S. Pituitary magnetic resonance imaging for sellar and parasellar masses: Ten-year experience in 2598 patients. *J Clin Endocrinol Metab* 2011;96:1633-41.
- Guerrero-Pérez F, Marengo AP, Vilarrasa N, Vidal N, Ruiz-Roig N, Sánchez-Fernández JJ, *et al.* Xanthogranuloma of the sellar region: A systematic review. *Hormones (Athens)* 2023;22:199-210.
- La Rocca G, Rigante M, Gessi M, D'Alessandris QG, Auricchio AM, Chiloiro S, *et al.* Xanthogranuloma of the sellar region: A rare tumor. Case illustration and literature review. *J Clin Neurosci* 2019;59:318-24.
- Pilonieta M, Martin M, Revuelta Barbero JM, Hardesty DA, Carrau RL, Otto BA, *et al.* Sellar cholesterol granuloma mimicking cystic sellar lesions: A report of three cases and literature review. *World Neurosurg* 2020;144:250-5.
- Shirataki K, Okada S, Matsumoto S. Histopathological study of the "cholesterol granuloma reaction" in the sellar and juxtaseellar tumors. *No To Shinkei* 1988;40:133-9.
- WHO Classification of Tumours Editorial Board. *Central Nervous System Tumours*. 5<sup>th</sup> ed., Vol. 6. Lyon: International Agency for Research on Cancer; 2021.

8. Yang B, Yang C, Fang J, Li G, Wang J, Jia G, *et al.* Clinicoradiologic features and surgical outcomes of sellar xanthogranulomas: A single-center 10-year experience. *World Neurosurg* 2017;99:439-47.

**How to cite this article:** Alghamdi AM, Alghamdi AM, Samkari A, Samman A, Lary A. Xanthogranuloma of the suprasellar region mimicking cystic craniopharyngioma: A case report. *Surg Neurol Int* 2023;14:331.

### Disclaimer

The views and opinions expressed in this article are those of the authors and do not necessarily reflect the official policy or position of the Journal or its management. The information contained in this article should not be considered to be medical advice; patients should consult their own physicians for advice as to their specific medical needs.