

Submitted: 22/05/2015

Accepted: 04/08/2015

Published: 07/09/2015

Pylo-ro-duodenal hernia with formation of enterocutaneous fistula in a buffalo calf following a dog attack

G. Kamalakar^{1,*}, V. Devi Prasad¹, J. Devaratnam¹ and A. Ganeshan²

¹Department of Veterinary Surgery and Radiology, College of Veterinary Science, Proddatur, Andhra Pradesh, India, 516360

²Department of Animal Reproduction and Gynaecology, College of Veterinary Science, Proddatur, Andhra Pradesh, India, 516360

Abstract

A body wall hernia entrapping abomasum and concurrent duodenal fistula in a buffalo calf aged about 8 months, secondary to a dog bite was successfully treated by closure of fistulous orifice and ventro lateral herniorrhaphy.

Keywords: Abomaso-epiplocele, Buffalo calf, Duodenal fistula, Herniorrhaphy.

Introduction

Protrusion of abdominal contents through a natural orifice or an abnormal opening is called hernia. Acquired hernias are commonly encountered in domestic animals and most of them are traumatic in origin (Krishnamurthy, 1993). Ventro lateral hernia can be seen at costal arch, flank and caudal abdomen, and may not be covered with peritoneum, thus leading to formation of adhesions between hernial contents and skin. Often times this can become irreducible and manifests local peritonitis and infection (O'Connor, 2005). Hernial contents may be rumen, reticulum, omasum, abomasum omentum, etc. Such hernias through abnormal openings may be associated with fistulae (Vertenten *et al.*, 2009). If neglected, such hernias may become irreducible due to formation of adhesions, and any accidental penetrating wound at that site may lead to fistulation due to a direct access to the visceral organs. Many surgeons have documented cases regarding herniation and fistulation of abomasum but no reports of a concurrent duodenal fistula exist in the literature. In the present paper, a rare case of abomaso-epiplocele (herniation of abomasum and omentum) with secondary duodenal fistula and its successful surgical management in a buffalo calf has been described.

Case history and observations

An eight month old graded buffalo heifer calf weighing about 60 kg was presented to the Department of Veterinary Surgery and Radiology with a 10 day history of leakage of green coloured digesta from right lateral abdomen (Fig. 1). Other multiple open wounds were observed on the body. The calf has been attacked by dogs and was treated empirically.

Clinically, the calf was anorectic, appeared dull and dehydrated with normal clinical parameters. Open wounds were observed at the right lateral abdomen with gangrenous skin, right thigh, base of neck and

left flank regions with different stages of healing. Of these, the wound at right lateral abdomen was open and bigger, with digesta leaking through it. On uncovering the gangrenous skin flap, fistula was visualized with lot of cutaneous adhesions and damaged muscular tissue with purulent exudate. No sign of herniation was observed on physical examination. pH of the digesta was on acidic side (pH 2). Packed cell volume and haemoglobin were 22% and 8 g/dL respectively. Ultrasonographic examination revealed discontinuity in the abdominal muscle layers and subcutaneous herniation of the viscera (Fig. 2). Based on the clinical signs, pH of the digesta and the position of fistula it was tentatively diagnosed as caudal abomasal hernia associated with fistula. Although it was not a clinical emergency, it was attended immediately because; the animal owner wanted to salvage the animal as he was from far off place from our college hospital. Moreover, treatment was already delayed and there was a risk of further contamination by existing sepsis. Thus, we decided to perform an emergency surgery.

Treatment

The calf was administered with 2.5 liters of Ringer's Lactate solution and injected with Ketoprofen at a dose of 2 mg/kg BW I/V for rehydration and as preemptive analgesia respectively. After preparing surgical area aseptically, the calf was sedated with xylazine hydrochloride at a dose of 0.01 mg/kg BW and local analgesia was achieved by inverted L block using 2% lignocaine hydrochloride. The dry gangrenous skin flap was excised and fistulous orifice was closed with a sterile pledget to avoid contamination. A hernial ring (Fig. 3) measuring 7 X 10 cm with its cranial border formed by 12th rib was found on lifting the herniated contents. The area was thoroughly irrigated with normal saline to clear the pus and necrotic tissue. By blunt and fine dissection the adhesions between the skin and

*Corresponding Author: Dr. Gurram Kamalakar. Department of Veterinary Surgery and Radiology, College of Veterinary Science, Proddatur, Andhra Pradesh, India, 516360. E-mail: drkamal_vet@yahoo.co.in

abomasum, abomasum and lesser omentum (Fig. 4) were broken with the help of a scrubbed assistant to hold the organs and leaving them back only if the serosa at the place of adhesion was intact. However there were no serosal perforations. It was found that the fistula was just caudal to pyloro-duodenal junction at cranial duodenum even before portal flexure. The serosal layer of the part surrounding the fistula and pyloric antrum appeared excoriated and ulcerated. The inflamed edges of the fistulous opening were bevelled out (Fig. 5). The fistula was closed by single layered interrupted Lembert sutures with chromic catgut No. 1/0. Whole viscera were irrigated with normal saline and metronidazole and repositioned in to the abdomen. The edges of the hernial ring were trimmed and closed with chromic catgut No. 2 in simple continuous pattern super imposed by simple interrupted sutures. There was no much tension on the closure of

the hernial ring. The necrosed tissue was scarified and skin edges were freshened and closed with sterile braided black silk in horizontal mattress pattern which was best known aversion suture pattern for closure of skin incision. Suture line was smeared with lorexane ointment (Gamma benzene hexachloride, Proflavin hemisulphate and Cetrimide cream). Post operatively, 500 ml normal saline, 500 ml Ringer's Lactate solution, 100 ml metronidazole I/V, 500 mg inj. ceftriaxone, 5 ml inj. Tribivet and 5 ml chlorpheniramine maleate (anti histamine) I/M were administered and this regimen was followed for the next 5 days. With appropriate fluid and anti-bacterial therapy and proper post-operative care the calf recovered uneventfully. Cutaneous sutures were removed on 12th post-operative day. No complications were observed till 4 months post-surgery.

Discussion

Abomasal Fistulae can be formed due to direct trauma (Sobti *et al.*, 1998), persistent adhesions resulting from infections leading to incarceration (Sangwan *et al.*, 2011) and as complication of abomasopexy techniques (Parker and Fubini, 1987). This condition causes leakage of ingesta, loss of electrolytes and

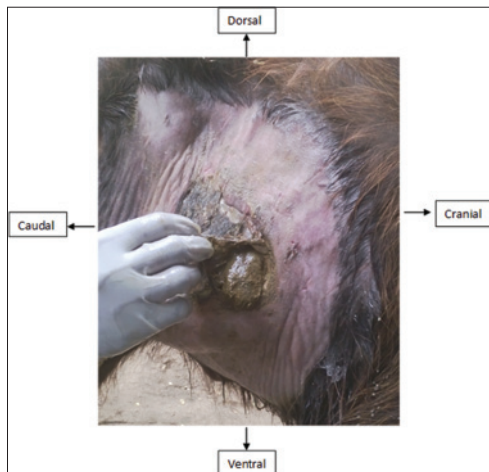


Fig. 1. Right ventro-lateral abdomen of calf illustrating duodenal fistula. Note the ingesta passing from the center of the fistula.

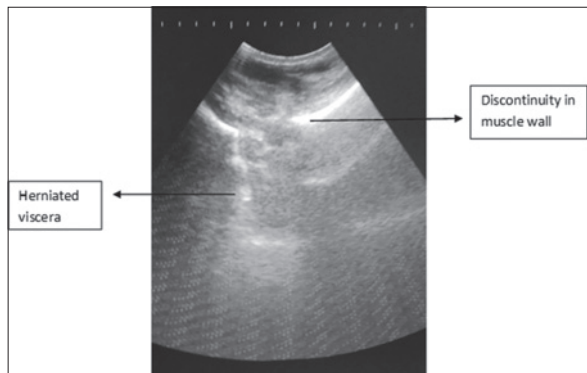


Fig. 2. Ultrasonographic view of the abdomen (Curvilinear probe, 3.5 MHz, Probe placed at area dorsal to the wound at ventro lateral abdomen in transverse plane). Observe discontinuity in muscle wall.

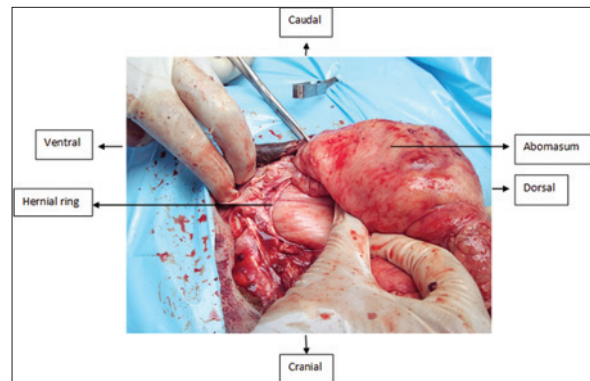


Fig. 3. Hernial ring and herniated abomasum at wound on ventro lateral abdomen.

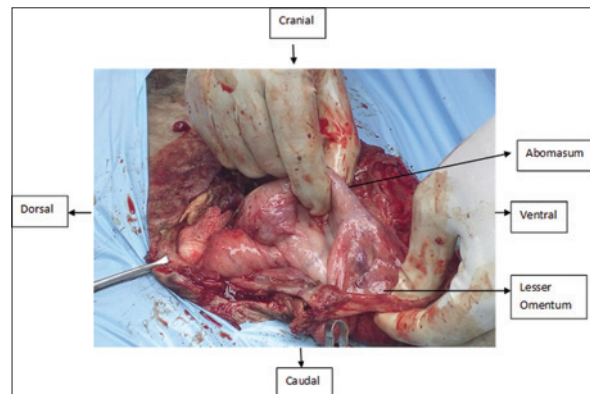


Fig. 4. Separation of adhesions between abomasum and lesser omentum.

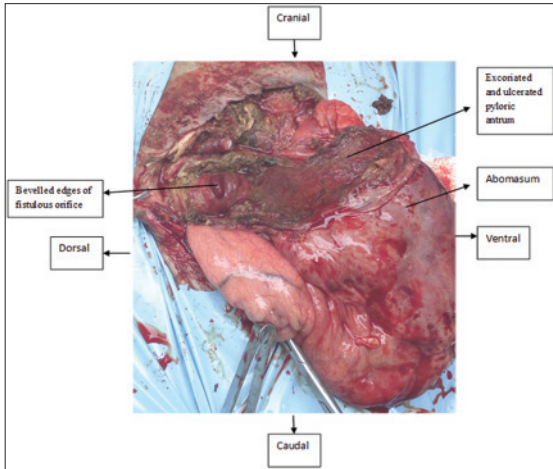


Fig. 5. Observe bevelled opening of fistula and damaged pyloric antrum.

the animal goes down in condition. Decision of early surgical correction is inevitable and is most successful in such cases (Sharma *et al.*, 2011). In the present case, the ventro lateral hernia was due to a neglected case of dog bites causing perforated wounds, consequent infection, incarceration, peritonitis, adhesions that ended up in fistulation. The adhesions formed between hernial contents and skin might have prevented diffuse abdominal contamination (O'Connor, 2005). Such complicated fistula in umbilical region was also reported by Sangwan *et al.* (2011). The fistulation was reported to be associated with umbilical hernia (Rijkenhuizen and Sickmann, 1994; Sharma *et al.*, 2011) and ventral hernia (Vertenten *et al.*, 2009). But Parker and Fubini (1987) reported abomasal fistula as a complication from an abomasopexy. The diameter of the proximal part of the duodenum is larger, when compared to other segments; Lembert suture was chosen which was thought to prevent leakage without causing much stenosis. As the serosal healing takes place rapidly and chromic catgut can be in tissues for not less than 10 days, we selected the chromic catgut as a suture material. Only the bevelled edges of duodenal fistula were closed perpendicular to abomasal axis such that the luminal stenosis is avoided and also leakage of digesta. Techniques like wedge resection of necrosed part of abomasum (Sangwan *et al.*, 2011), and end to end anastomosis of abomasal ends after resection of necrosed tissue (Vertenten *et al.*, 2009) were not

practised here as the condition of abomasum did not necessitate because the necrosis was not severe and if anastomosis was performed it might lead to pyloric stenosis. The hernial ring was closed with simple continuous pattern due to lack of space, instead, vest over pant (Sangwan *et al.*, 2011) or near far - far near patterns (Vertenten *et al.*, 2009) that have also been used successfully in other reports. Hypochloreaemic metabolic acidosis observed in abomasal fistula as reported by Fubini and Smith (1984) was counteracted by Ringer's Lactate solution and normal saline administration. Metronidazole is an empirical drug of choice for combating anaerobic infections and is freely available in India.

References

- Fubini, S.L. and Smith, D.F. 1984. Umbilical hernia with abomasal-umbilical fistula in a calf. *J. Am. Vet. Med. Assoc.* 184, 1510-1511.
- Krishnamurthy, D. 1993. Hernia. In: *Ruminant Surgery A textbook of the diseases of cattle, buffaloes, camels, sheep and goats* by RPS Tyagi and J Singh (Eds), 1st Edition, CBS Publishers and Distributors, Delhi, pp: 226-227.
- O'Connor, J.J. 2005. The Abdomen, In *Dollar's Veterinary Surgery*, 4th Ed., CBS Publishers and Distributors, New Delhi, pp: 665.
- Parker, J.E. and Fubini, S.L. 1987. Abomasal fistulas in dairy cows. *Cornell Vet.* 77, 303-309.
- Rijkenhuizen, A.B. and Sickmann, H.G. 1994. Incarcerated umbilical hernia with enterocutaneous fistula in a calf. *Tijdschr Diergeneesk.* 120(1), 8-10.
- Sangwan, V., Kumar, A., Singh, K. and Mahajan, S.K. 2011. Umbilical hernia with Abomasal – Umbilical fistula in a cow calf. *Vet. Scan.* 6(1), 83.
- Sharma, A., Upadhye, S.V. and Kour, K. 2011. Congenital abomasal fistula in a buffalo calf and its successful treatment. *Buff. Bull.* 30(1), 1-3.
- Sobti, V.K., Saini, N.S., Singh, K.I., Bansal, P.S. and Simran, P.S. 1998. Surgical management of abomasal herniation and its fistulation in a buffalo. *Indian Vet. J.* 75, 1046-1047.
- Vertenten, G., Declercq, J., Gasthuys, F., Devisscher, L., Torfs, S., Loon, G.V. and Martens, A. 2009. Abomasal end-to-end anastomosis as treatment for abomasal fistulation and herniation in a cow. *Vet. Rec.* 164(25), 785-786.