


# Comparative Effectiveness of Expandable Versus Static Interbody Spacers via MIS LLIF: A 2-Year Radiographic and Clinical Outcomes Study

Yan Michael Li, MD<sup>1</sup>, Richard F. Frisch, MD<sup>2</sup>, Zheng Huang MD, PhD<sup>3</sup>, James Towner, MD<sup>1</sup>, Yan Icy Li, PhD<sup>1</sup>, Samantha L. Greeley, BS<sup>4</sup> , and Charles Ledonio, MD, CCRP<sup>4</sup>

Global Spine Journal  
2020, Vol. 10(8) 998-1005  
© The Author(s) 2019  
Article reuse guidelines:  
sagepub.com/journals-permissions  
DOI: 10.1177/2192568219886278  
journals.sagepub.com/home/gsj



## Abstract

**Study Design:** Retrospective cohort study.

**Objective:** The purpose of this study is to compare the radiographic and clinical outcomes of expandable interbody spacers to static interbody spacers.

**Methods:** This is a retrospective, institutional review board–exempt chart review of 62 consecutive patients diagnosed with degenerative disc disease who underwent minimally invasive spine surgery lateral lumbar interbody fusion (MIS LLIF) using static or expandable spacers. There were 27 patients treated with static spacers, and 35 with expandable spacers. Radiographic and clinical functional outcomes were collected. Statistical results were significant if  $P < .05$ .

**Results:** Mean improvement in visual analogue scale back and leg pain scores was significantly greater in the expandable group compared to the static group at 6 and 24 months by 42.3% and 63.8%, respectively ( $P < .05$ ). Average improvement in Oswestry Disability Index scores was significantly greater in the expandable group than the static group at 3, 6, 12, and 24 months by 28%, 44%, 59%, 53%, and 89%, respectively ( $P < .05$ ). For disc height, the mean improvement from baseline to 24 months was greater in the static group compared to the expandable group ( $P < .05$ ). Implant subsidence was significantly greater in the static group (16.1%, 5/31 levels) compared with the expandable group (6.7%, 3/45 levels;  $P < .05$ ).

**Conclusions:** This study showed positive clinical and radiographic outcomes for patients who underwent MIS LLIF with expandable spacers compared to those with static spacers. Sagittal correction and pain relief was achieved and maintained through 24-month follow-up. The expandable group had a lower subsidence rate than the static group.

## Keywords

minimally invasive spine surgery, lateral lumbar interbody fusion, expandable spacers, static spacers

## Introduction

The lateral lumbar interbody fusion (LLIF) approach was introduced by Ozgur et al<sup>1</sup> in 2006, and has since been established as an effective method for lumbar interbody fusion.<sup>2-6</sup> The minimally invasive (MIS) LLIF technique is associated with decreased operative times, minimized tissue dissection, reduced postoperative pain, and decreased rates of complications compared to open anterior and posterior approaches.<sup>7-9</sup> The MIS LLIF approach provides adequate surgical exposure to the disc space enabling placement of an interbody spacer with a large footprint, which affords biomechanical

<sup>1</sup> University of Rochester Medical Center, Rochester, NY, USA

<sup>2</sup> Southeastern Spine Institute, Mt Pleasant, SC, USA


<sup>3</sup> Guanghua Hospital, Shanghai, People's Republic of China

<sup>4</sup> Musculoskeletal Education and Research Center (MERC), A Division of Globus Medical, Audubon, PA, USA

### Corresponding Author:

Yan Michael Li, University of Rochester Medical Center, 601 Elmwood Ave, Rochester, NY 14642, USA.  
Email: dr.yanli@gmail.com





**Figure 1.** Continuously expandable interbody spacer in (A) minimized and (B) expanded forms (RISE-L Globus Medical, Inc, Audubon, PA).


stability. This results in indirect decompression of the neural elements.<sup>10,11</sup>

Traditionally, static spacers have been utilized with this technique. However, static interbody spacers require excessive trialing, aggressive endplate preparation, and forceful impaction, which may lead to endplate damage and consequently, spacer subsidence.<sup>11</sup> Expandable technology was designed to expand vertically within the disc space, refuting the need for forceful impaction and minimizing iatrogenic overdistracton during insertion.<sup>11</sup> Additionally, there may be better disc height restoration and sagittal alignment correction compared with static spacers; however, studies comparing static spacers with expandable spacers are lacking.<sup>12-17</sup> The importance of restoring radiographic parameters for improved functional outcomes has been well established.<sup>18-20</sup> The goal of this study is to compare the surgical outcomes of patients treated with expandable spacers after an MIS LLIF to those who were treated with static spacers.

## Materials and Methods

### Patient Population

This was a multisite, multisurgeon, retrospective clinical study from a prospectively collected database with institutional review board approval. It included 62 consecutive patients and 76 operative levels with a diagnosis of degenerative disc disease (DDD) at 1 or 2 contiguous levels from L1 to L5 with or without grade 1 spondylolisthesis. All patients underwent MIS LLIF surgery using either an expandable interbody spacer (RISE-L, Globus Medical, Inc, Audubon, PA) or a static interbody spacer (TransContinental, Globus Medical, Inc), with posterior pedicle screw and rod fixation (Figures 1 and 2). Patient self-assessment forms and radiographic records were used to assess clinical and radiologic outcomes.



**Figure 2.** Static interbody spacer (TransContinental, Globus Medical, Inc, Audubon, PA).

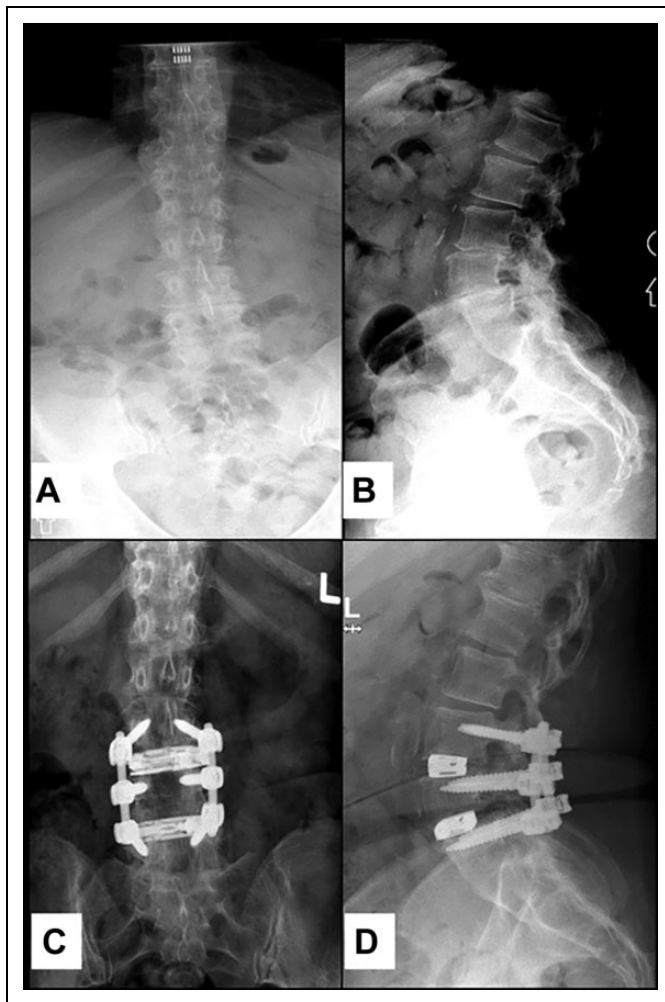
### Surgical Technique

Under general anesthesia, patients were placed in the lateral decubitus position and secured to the operating table with adhesive tape. Under fluoroscopic guidance, an oblique incision was made at the symptomatic disc segment. Blunt dissection was performed under direct visualization through subcutaneous tissue, external and internal oblique muscles, and transversus abdominis. Retroperitoneal fat was mobilized anteriorly, exposing the underlying psoas muscle. The psoas muscle was palpated, and fluoroscopic images confirmed the level and location of the spinal marker. Blunt dissection was performed anteriorly to or at the very anterior part of the psoas muscle down to the operative intervertebral disc level. Neuromonitoring stimulation did not show any nerve conduction abnormalities (lumbar plexus). After fluoroscopic confirmation of the appropriate level, a minimally invasive retractor was docked, sequentially dilated at the segment, and secured to the table-mounted arm. An annulotomy was then performed, followed by a discectomy and decortication of endplates. Sequential trials were used to allow for gradual distraction of the disc space. An appropriately sized static lateral cage was then selected, packed with autograft, and placed in the disc space. For expandable spacers, there was less trialing and the spacer was filled with autograft and placed in a collapsed state, and then expanded in situ to the desired height and backfilled with autograft. After verification of the spacer positioning, the retractor was removed.

Posterior decompression was performed in cases of severe spinal stenosis with neurological deficit or in cases where LLIF procedure did not increase preoperative disc height by more than double. Pedicle screws and rods were used for supplemental fixation. Locking caps were set once the rods were in their proper position. Intraoperative fluoroscopy images were taken of the final construct (Figure 3). Surgical incisions were cleaned and closed in the standard fashion.

### Interbody Spacers

The expandable interbody spacer used in this study is manufactured from titanium alloy. The device is inserted at a contracted height and expanded in situ once correctly positioned within the intervertebral space, offering continuous expansion



**Figure 3.** Preoperative (A) anteroposterior (AP) and (B) lateral radiographs and (C) postoperative AP and (D) lateral radiographs of a 2-level MIS LLIF (minimally invasive spine surgery lateral lumbar interbody fusion) at L3/4 and L4/5.

for optimal endplate-to-endplate contact. The static interbody spacer is manufactured from radiolucent polymer with titanium alloy or tantalum markers and includes a self-distracting leading edge for implant insertion.

### Outcome Measures

Demographic and perioperative data were recorded. Patient self-assessment questionnaires such as the visual analogue scale (VAS) for back and leg pain and Oswestry Disability Index (ODI) were evaluated preoperatively and at 6 weeks, 3, 6, 12, and 24 months postoperatively. Radiographic parameters, including disc height, neuroforaminal height, segmental lordosis, and implant subsidence were assessed. The radiographic measurements were conducted by different observers but verified by an orthopedic surgeon.

Subsidence was defined as a measured reduction in disc height greater than 2 mm at 24 months compared with 6-week disc height.<sup>21</sup> Disc heights were measured from the

**Table 1.** Classification of Interbody Fusion Success: Brantigan, Steffee, Fraser (BSF).<sup>22</sup>

BSF-1: Radiographical pseudoarthrosis is indicated by collapse of the construct, loss of disc height, vertebral slip, broken screws, displacement of the carbon cage, significant resorption of the bone graft, or lucency visible around the periphery of the graft or cage.
BSF-2: Radiographical lock pseudoarthrosis is indicated by lucency visible in the middle of the cages with solid bone growing into the cage from each vertebral endplate.
BSF-3: Radiographical fusion: Bone bridges at least half of the fusion area with at least the density originally achieved at surgery. Radiographical fusion through one cage (half of the fusion area) is considered to be mechanically solid fusion even if there is lucency on the opposite side.

middle portion of the endplates immediately above and below the referenced index levels on the lateral plane. Neuroforaminal height was measured as the distance from the inferior pedicle wall of the level above to the superior pedicle wall of the level below. Segmental lordosis was measured from inferior endplate of the caudal vertebral body to the superior endplate of the cephalad vertebral body. Fusion was evaluated on radiographic images using the Brantigan, Steffee, and Fraser (BSF) radiographic classification<sup>22</sup> (Table 1). According to this classification, BSF-1 is radiographic pseudoarthrosis, BSF-2 is radiographical locked pseudoarthrosis, and BSF-3 is radiographical fusion.

### Statistical Methods

Statistical analysis was performed with SPSS v20.0.0 software for Windows (IBM Corp., Armonk, NY). Descriptive statistics were recorded as mean and standard deviation, or frequency and percentage, where applicable. Fisher's exact test and paired and independent-samples *t* tests were used to calculate differences in ordinal and interval variables from preoperative to each postoperative follow-up time. Any significant differences between demographic or baseline values were reported. Statistical significance was set at  $P < .05$ .

## Results

### Patient Demographic and Operative Data

Sixty-two patients were enrolled in this study, with an average age of  $63.0 \pm 11.0$  years; 61.3% (38/62) were female. Twenty-seven consecutive patients underwent MIS LLIF with static spacers from May 2014 to February 2016. The patients were 74.1% (20/27) female and 25.9% male (7/27) with an average age of  $65.5 \pm 9.3$  years (range: 45-81 years). Thirty-five consecutive patients underwent MIS LLIF with expandable spacers from August 2016 to January 2017. The patients were 51.4% (18/35) female and 48.6% (17/35) male with an average age of  $61.1 \pm 12.0$  years (range: 34-79 years).

There were no significant differences in age or gender between groups ( $P = .13$  and  $.11$ , respectively). No significant

**Table 2.** Baseline Characteristics.

Parameter	Expandable	Static
Number of Patients	35	27
Gender, n (%)		
Female	18 (51.4)	20 (74.1)
Male	17 (48.6)	7 (25.9)
Age, years, mean $\pm$ SD (range)	61.1 $\pm$ 12.0 (34-79)	65.5 $\pm$ 9.3 (45-81)
Baseline VAS back and leg pain	7.5	6.9
Baseline ODI	62.4 <sup>a</sup>	46.9

Abbreviations: VAS, visual analogue scale; ODI, Oswestry Disability Index.

<sup>a</sup> $P < .05$  compared with static.

difference in baseline VAS scores were observed between groups ( $P = .357$ ). However, there were significant differences in ODI, disc height, neuroforaminal height, and segmental lordosis between baseline static and expandable groups ( $P < .05$ ; (Table 2). Specifically, baseline ODI was significantly higher in the expandable group while baseline disc height, neuroforaminal height, and segmental lordosis was statistically higher in the static group.

Among the 76 spinal fusion levels, 36.8% (28/76) at L3-4 and 44.7% (34/76) at L4-5. Of the 62 patients, 77.4% (48/62) were single-level (1L) procedures and 22.6% (14/62) were 2-level fusion (2L). All patients had 24-month follow-up data and percentages of patients at each time point is presented in Table 3. Mean operative time was similar between groups, with the expandable group averaging 62.8  $\pm$  24.3 minutes for 1L fusions and 94.2  $\pm$  36.2 minutes for 2L fusions, and the static group averaging 66.9  $\pm$  42.9 minutes for 1L and 74.5  $\pm$  17.6 minutes for 2L. Length of hospital stay for the expandable group was 3.5  $\pm$  1.7 days for 1L fusions and 3.5  $\pm$  1.4 days for 2L fusions, with the static group averaging 2.1  $\pm$  1.3 days for 1L and 2.0  $\pm$  1.4 for 2L. Mean estimated blood loss for the expandable spacers was 23.5  $\pm$  13.3 cm<sup>3</sup> for 1L fusions and 42.0  $\pm$  41.5 cm<sup>3</sup> for 2L. Static interbody spacers mean estimated blood loss was 40.2  $\pm$  39.3 cm<sup>3</sup> for 1L fusions and 37.5  $\pm$  25.0 cm<sup>3</sup> for 2L (Table 3).

### Clinical Outcomes

Patients reported improvements in pain and disability, and comparisons were made between the static and expandable groups by comparing their mean baseline to 24-month differences. Raw values for each time point are presented in Table 4 and the mean improvements from preoperative are presented in Table 5. Mean improvement in VAS back and leg pain scores was significantly greater in the expandable spacer group compared to the static spacer group at 6 and 24 months by 42.3% and 63.8%, respectively ( $P < .05$ ; Figure 4). In the expandable spacer group, average VAS back and leg pain scores significantly improved from baseline by 58% (4.3  $\pm$  2.4), 69% (5.2  $\pm$  2.1), 74% (5.5  $\pm$  2.4), 74% (5.7  $\pm$  2.5), and 86% (6.5  $\pm$  2.5) at 6 weeks, 3, 6, 12, and 24 months, respectively

**Table 3.** Minimally Invasive Spine Surgery Lateral Lumbar Interbody Fusion (MIS LLIF) Procedure Characteristics.

Parameter	Expandable	Static
Type of surgery, n (%)		
One-level	25 (71.4)	23 (85.2)
Two-level	10 (28.6)	4 (14.8)
Levels treated, n (%)		
L2-L3	10 (22.2)	4 (12.9)
L3-L4	20 (44.5)	8 (25.8)
L4-L5	15 (33.3)	19 (61.3)
Mean estimated blood loss, cm <sup>3</sup> , mean $\pm$ SD		
One-level	23.5 $\pm$ 13.3	40.2 $\pm$ 39.3
Two-level	42.0 $\pm$ 41.5	37.5 $\pm$ 25.0
Mean operative time, minutes, mean $\pm$ SD		
One-level	62.8 $\pm$ 24.3	66.9 $\pm$ 42.9
Two-level	94.2 $\pm$ 36.2	74.5 $\pm$ 17.6
Mean length of hospital stay, days, mean $\pm$ SD		
One-level	3.5 $\pm$ 1.7	2.1 $\pm$ 1.3
Two-level	3.5 $\pm$ 1.4	2.0 $\pm$ 1.4

( $P < .001$ ). In the static spacer group, average VAS back and leg pain scores significantly improved from baseline by 65.2% (4.5  $\pm$  2.7), 68.8% (4.7  $\pm$  2.8), 53.3% (3.6  $\pm$  3.6), 65.9% (4.5  $\pm$  2.9), and 50.4% (3.3  $\pm$  3.3) at 6 weeks, 3, 6, 12, and 24 months, respectively ( $P < .001$ ).

The mean improvement in ODI scores was significantly greater in the expandable spacer group compared with the static spacer group at 3, 6, 12, and 24 months by 28%, 44%, 59%, 53%, and 89%, respectively ( $P < .05$ ; Figure 5). In the expandable spacer group, the mean ODI scores significantly improved from baseline by 47% (29.4  $\pm$  17.7), 61% (38.6  $\pm$  16.9), 71% (44.1  $\pm$  20.8), 75% (46.7  $\pm$  25.5), 82% (51.4  $\pm$  25.1) at 6 weeks, 3, 6, 12, and 24 months, respectively ( $P < .001$ ). In the static spacer group, average ODI scores significantly improved from baseline by 43% (22.1  $\pm$  26.6), 53% (24.7  $\pm$  25.0), 51% (24.1  $\pm$  24.1), 57% (27.1  $\pm$  23.9), and 42% (19.8  $\pm$  21.5) at 6 weeks, 3, 6, 12, and 24 months, respectively ( $P < .001$ ).

### Radiographic Outcomes

Mean outcomes for each time point are presented in Table 4, and the average improvements from preoperative are presented in Table 5. In the expandable spacer group, disc height significantly increased from baseline by an average of 80% (5.6  $\pm$  3.2 mm), 75% (5.3  $\pm$  3.5 mm), 64% (4.5  $\pm$  3.6 mm), 65% (4.5  $\pm$  3.7 mm), and 61% (4.3  $\pm$  3.6 mm) at 6 weeks, 3, 6, 12, and 24 months, respectively ( $P < .001$ ). In the static spacer group, mean disc height increased significantly from baseline by 62% (5.3  $\pm$  2.6 mm), 62% (5.3  $\pm$  2.7 mm), 60% (5.1  $\pm$  2.8 mm), 57% (4.9  $\pm$  3.1 mm), and 73% (6.4  $\pm$  2.9 mm) at 6 weeks, 3, 6, 12, and 24 months, respectively ( $P < .05$ ). Significant differences in intervertebral disc height were observed between groups at 24 months ( $P < .05$ ).

**Table 4.** Mean Values of Patient-Reported Outcomes and Radiographic Parameters.<sup>a</sup>

Parameter	Device	Baseline	6 Weeks	3 Months	6 Months	12 Months	24 Months
VAS back and leg pain	Expandable	7.5 ± 2.0	3.1 ± 2.0 <sup>b</sup>	2.4 ± 1.5 <sup>b</sup>	2.0 ± 1.6 <sup>b</sup>	1.9 ± 1.9 <sup>b</sup>	1.0 ± 1.1 <sup>b</sup>
	Static	6.9 ± 2.3	2.4 ± 2.2 <sup>b</sup>	2.2 ± 2.1 <sup>b</sup>	3.2 ± 3.0 <sup>b</sup>	2.4 ± 2.4 <sup>b</sup>	3.4 ± 2.7 <sup>b</sup>
ODI	Expandable	62.5 ± 22.0	33.1 ± 16.3 <sup>b</sup>	24.4 ± 13.9 <sup>b</sup>	18.4 ± 13.7 <sup>b</sup>	15.7 ± 13.4 <sup>b</sup>	11.1 ± 9.4 <sup>b</sup>
	Static	46.9 ± 19.5	26.6 ± 20.5 <sup>b</sup>	22.2 ± 17.4 <sup>b</sup>	22.8 ± 20.2 <sup>b</sup>	20.3 ± 19.0 <sup>b</sup>	27.1 ± 19.5 <sup>b</sup>
MDH (mm)	Expandable	7.0 ± 3.2	12.5 ± 2.8 <sup>b</sup>	12.2 ± 2.8 <sup>b</sup>	11.5 ± 2.7 <sup>b</sup>	11.5 ± 2.5 <sup>b</sup>	11.3 ± 2.2 <sup>b</sup>
	Static	8.6 ± 3.1	13.9 ± 2.3 <sup>b</sup>	13.9 ± 2.7 <sup>b</sup>	13.7 ± 2.7 <sup>b</sup>	13.4 ± 3.0 <sup>b</sup>	14.8 ± 2.2 <sup>b</sup>
NFH (mm)	Expandable	15.4 ± 4.3	20.0 ± 3.8 <sup>b</sup>	19.1 ± 3.9 <sup>b</sup>	18.9 ± 3.7 <sup>b</sup>	18.2 ± 4.7 <sup>b</sup>	18.7 ± 4.3 <sup>b</sup>
	Static	20.3 ± 4.4	23.6 ± 3.7 <sup>b</sup>	23.1 ± 3.5 <sup>b</sup>	22.4 ± 3.7 <sup>b</sup>	23.1 ± 3.5 <sup>b</sup>	22.0 ± 3.3 <sup>b</sup>
Segmental lordosis (deg)	Expandable	8.1 ± 6.7	11.0 ± 6.1 <sup>b</sup>	10.4 ± 6.5 <sup>b</sup>	10.5 ± 6.2 <sup>b</sup>	10.6 ± 7.1 <sup>b</sup>	9.9 ± 6.0 <sup>b</sup>
	Static	14.8 ± 9.2	16.2 ± 8.1	16.2 ± 8.7	15.9 ± 8.4	15.4 ± 9.0	17.3 ± 9.6 <sup>b</sup>

Abbreviations: VAS, visual analogue scale; ODI, Oswestry Disability Index; MDH, mean disc height; NFH, neuroforaminal height.

<sup>a</sup>Values are given as mean ± standard deviation.

<sup>b</sup>p < .05 compared with baseline.

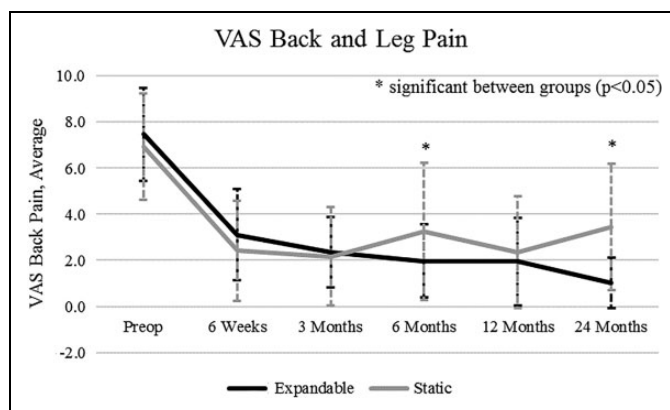
**Table 5.** Mean Differences From Baseline of Patient-Reported Outcomes and Radiographic Parameters.<sup>a</sup>

Parameter	Device	6 Weeks	3 Months	6 Months	12 Months	24 Months
VAS back and leg pain	Expandable	4.3 ± 2.4	5.2 ± 2.1	5.5 ± 2.4 <sup>b</sup>	5.7 ± 2.5	6.5 ± 2.5 <sup>b</sup>
	Static	4.5 ± 2.7	4.7 ± 2.8	3.6 ± 3.6	4.5 ± 2.9	3.3 ± 3.3
ODI	Expandable	29.4 ± 17.7	38.6 ± 16.9 <sup>b</sup>	44.1 ± 20.8 <sup>b</sup>	46.7 ± 25.5 <sup>b</sup>	51.4 ± 25.1 <sup>b</sup>
	Static	22.1 ± 26.6	24.7 ± 25.0	24.1 ± 24.1	27.1 ± 23.9	19.8 ± 21.5
MDH (mm)	Expandable	5.6 ± 3.2	5.3 ± 3.5	4.5 ± 3.6	4.5 ± 3.7	4.3 ± 3.6 <sup>b</sup>
	Static	5.3 ± 2.6	5.3 ± 2.7	5.1 ± 2.8	4.9 ± 3.1	6.4 ± 2.9
NFH (mm)	Expandable	4.6 ± 4.4	3.5 ± 3.8	3.4 ± 3.4	2.8 ± 5.0	3.3 ± 4.1
	Static	3.4 ± 3.3	2.8 ± 4.0	2.2 ± 3.2	3.0 ± 4.4	1.8 ± 4.3
Segmental Lordosis (deg)	Expandable	2.9 ± 3.4	2.2 ± 3.3	2.3 ± 2.7	2.5 ± 3.4	1.8 ± 3.4
	Static	1.3 ± 5.1	1.4 ± 5.2	1.0 ± 5.8	0.5 ± 4.4	2.5 ± 5.2

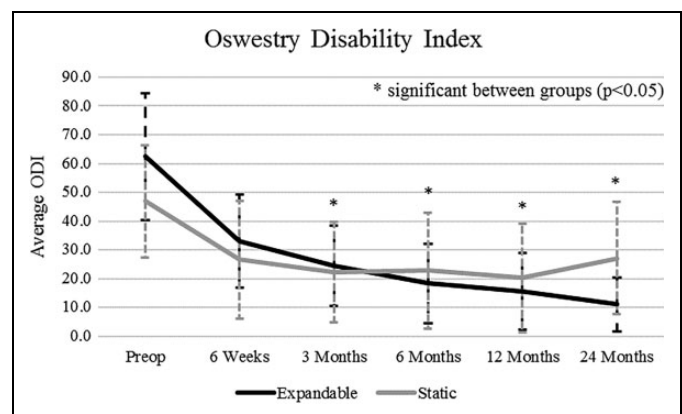
Abbreviations: VAS, visual analogue scale; ODI, Oswestry Disability Index; MDH, mean disc height; NFH, neuroforaminal height.

<sup>a</sup>Values are given as mean ± standard deviation.

<sup>b</sup>p < .05 compared with static.



**Figure 4.** Average visual analogue scale (VAS) back and leg pain scores are shown. Significant decreases from baseline were achieved and maintained at 6 weeks, 3, 6, 12, and 24 months. However, an upward trend was observed in the static group, and a downward trend in the expandable group.



**Figure 5.** Average Oswestry Disability Index (ODI) scores are shown. Significant decreases from baseline were achieved and maintained at 6 weeks, 3, 6, 12, and 24 months. An upward trend is observed in the static group, while a downward trend is observed in the expandable group.

Patients treated with expandable spacers showed a significant increase in neuroforaminal height from baseline by a mean of 30% (4.6 ± 4.4 mm), 24% (3.5 ± 3.8 mm), 23% (3.4 ± 3.4 mm), 18% (2.8 ± 5.0 mm), and 21% (3.3 ± 4.1 mm) at

6 weeks, 3, 6, 12, and 24 months, respectively (*P* < .001). Additionally, neuroforaminal height significantly increased from baseline in the static spacer group by an average of 17% (3.4 ± 3.3 mm), 14% (2.8 ± 4.0 mm), 11% (2.2 ± 3.2 mm),

14% ( $3.0 \pm 4.4$  mm), 8.5% ( $1.8 \pm 4.3$ ) at 6 weeks, 3, 6, 12, and 24 months, respectively ( $P < .05$ ). There was no significant difference in mean improvements from baseline between the expandable spacer and static spacer groups.

In the expandable spacer group, segmental lordosis significantly increased from baseline at 6 weeks, 3, 6, 12, and 24 months by an average of 36% ( $2.9^\circ \pm 3.4^\circ$ ), 27% ( $2.2^\circ \pm 3.3^\circ$ ), 30% ( $2.3^\circ \pm 2.7^\circ$ ), 31% ( $2.5^\circ \pm 3.4^\circ$ ), and 23% ( $1.8^\circ \pm 3.4^\circ$ ), respectively. In the static spacer group, segmental lordosis increased significantly from baseline at 24 months only by an average of 17.2% ( $2.5^\circ \pm 5.2^\circ$ ;  $P < .05$ ). However, there was not a significant difference in mean improvements from baseline between expandable and static spacer groups.

All operative levels were considered radiographically fused (BSF-3)<sup>22</sup> in both the expandable and the static groups at 24 months.

### Implant-Related Observations

Implant subsidence was greater in the static group at 16.1% (5/31 levels) compared with the expandable group at 6.7% (3/45 levels). All cases of subsidence were asymptomatic with no revision surgery necessary.

### Discussion

There are few clinical studies comparing expandable interbody spacers to static interbody spacers, making comparisons to existing literature challenging. Long-term clinical outcomes and radiographic analysis are necessary to determine the safety and effectiveness of expandable spacers compared with static spacers. Results from this study found a significant improvement in VAS back and leg pain scores in the expandable group compared with the static group (86% vs 50%) at 24 months. Similarly, there was a significant improvement in ODI scores in the expandable group compared with the static group by 82% and 42%, respectively. This study reported a 61% improvement in disc height in the expandable spacer group and a 73% improvement in disc height in the static spacer group. Disc height in the static spacer group showed a significantly larger improvement from baseline at 24 months. There was a greater increase from baseline for neuroforaminal height and segmental lordosis between expandable spacers and static spacers (21% vs 9% and 23% vs 17%, respectively). The current cohort also found a 6.7% (3/45 levels) rate of subsidence when using expandable spacers, a 16.1% (5/31 levels) rate of subsidence when using static spacers, and a 0% reoperation rate for all cases of subsidence.

The results from this study showed a large improvement in VAS and ODI scores for both groups, exceeding the minimally clinically important difference.<sup>23-26</sup> There was also a significantly larger improvement in ODI scores observed in the expandable group compared with the static group. A potential reason may be that static spacers are typically large spacers impacted into the disc space. There may be increased disc

height but a greater chance of subsidence, which could result in pain. Even though there was a significant difference in baseline radiographic parameters, results were presented as mean change from baseline for each group individually and then statistical comparisons were performed on mean changes to assess any differences between groups.

A 2015 study by Alimi et al<sup>27</sup> examined expandable PEEK (polyetheretherketone) spacers used in transforaminal lumbar interbody fusion (TLIF). This study reported significant improvements in VAS back pain scores and ODI scores by 52% and 45%, respectively, at 19-month follow-up. Additionally, the authors found a significant 26% improvement in disc height and a significant 19% increase in neuroforaminal height. Results from this study found a higher change in VAS back and leg pain scores and ODI scores, a larger improvement in disc height from baseline, and a comparable improvement in neuroforaminal height.

In a multicenter cohort by Frisch et al<sup>28</sup> comparing static with expandable spacers, VAS back pain scores significantly improved by 43% and 45%, respectively, at 24-month follow-up. From baseline, ODI scores significantly improved by 44% and 39% in the static spacer group and the expandable spacer group, respectively. In the static group, disc height, neuroforaminal height, and segmental lordosis increased by 85% and 16%, respectively. Disc height and neuroforaminal height increased by 41% and 13%, respectively, in the expandable group. These changes from baseline in the expandable group are much lower than what was found in the current evaluation.

The impaction force and overdistracted required when inserting static spacers may have contributed to the higher rate of subsidence in the static spacer group.<sup>28</sup> Subsidence in interbody fusion is of great concern, as it can lead to loss of lordosis and adjacent segment disease, subsequently requiring revision surgery.<sup>29,30</sup> There was a 16.1% subsidence rate in the static group and a 0% subsidence rate in the expandable spacer in the aforementioned analysis by Frisch et al.<sup>28</sup> This coincides with the results from this study, a higher rate of subsidence in the static group than the expandable group. In the previously mentioned study by Alimi et al,<sup>27</sup> there was a 7.4% subsidence rate; however, the small footprint of the spacer and the TLIF approach may have affected endplate strength. A larger interbody footprint has been associated with greater biomechanical stability and decreased risk of subsidence.<sup>31,32</sup> A systematic 2019 review of 21 publications by Macki et al<sup>33</sup> found subsidence in 141 of 1362 patients (10.3%) and a reoperation rate of 2.7%, which is higher than what was found in the current study.

According to the results of this study, spine surgeons may want to consider the advantages of expandable spacers when performing LLIF. Using static spacers may result in a larger disc height and greater segmental lordosis; however, patients report less pain after being treated with an expandable spacer during an LLIF procedure. Another consideration when choosing a spacer is the decreased risk of subsidence observed in the expandable spacer group.

There are limitations to this study. The cases compared were from 2 separate institutions with different sample sizes by 2

spine surgeons with different specialties (neurosurgery vs orthopedic). However, both surgeons used similar techniques. The radiographic measurements were conducted by different observers but verified by an orthopaedic surgeon. An unexpected result was that the static group had a higher improvement in segmental lordosis at 24 months than the expandable group. This may be due to the fact that the static group had a larger percentage of the operative levels at the L4-L5 disc, where lordosis occurs naturally. A larger sample size with a more even group distribution of the L4-L5 operative level is needed to further evaluate the differences in segmental lordosis between expandable and static spacers. Additionally, preoperative radiographic measurements were significantly different between groups, yet comparing mean differences helped mitigate this heterogeneity. Future studies should focus on larger patient cohorts to further examine the differences between static and expandable spacers.

## Conclusion

Results from this study revealed that, both static and expandable spacers in MIS LLIF increase disc height, neuroforaminal height, and segmental lordosis through 24 months. Static spacers resulted in a significantly larger increase in disc height at 24 months compared with expandable spacers. The use of an expandable spacer in a MIS LLIF lead to a greater improvement in clinical outcomes when compared to the use of static spacers. There was also an increase in subsidence when using static spacers, demonstrating the benefits of expandable technology in avoiding endplate damage during spacer insertion. Expandable spacers are safe, efficient, and durable when used in conjunction with the LLIF procedure in the patient population studied.

## Declaration of Conflicting Interests

The author(s) declared the following potential conflicts of interest with respect to the research, authorship, and/or publication of this article: SLG and CL are salaried employees (with stock options) of Globus Medical, Inc (GMI). The RISE-L and TransContinental spacers described in this article are manufactured by GMI where authors SLG and CL are employees. YML receives research support from GMI and is a consultant for Depuy Synthes. RFF receives research support, royalties, and is a consultant for GMI. ZH and YIL receive research support from GMI. JT has no conflicts of interest.

## Funding

The author(s) received no financial support for the research, authorship, and/or publication of this article.

## ORCID iD

Samantha L. Greeley, BS  <https://orcid.org/0000-0002-7568-131X>

## References

- Ozgun BM, Aryan HE, Pimenta L, Taylor WR. Extreme lateral interbody fusion (XLIF): a novel surgical technique for anterior lumbar interbody fusion. *Spine J*. 2006;6:435-443.
- Rodgers J, Gerber E, Lehmen J, Rodgers W. Clinical and radiographic outcome in less invasive lumbar fusion: XLIF at two year follow-up. *J Spine Neurosurg*. 2013;2:3.
- Lee YS, Park SW, Kim YB. Direct lateral lumbar interbody fusion: clinical and radiological outcomes. *J Korean Neurosurg Soc*. 2014;55:248-254.
- Le TV, Vivas AC, Dakwar E, Baaj AA, Uribe JS. The effect of the retroperitoneal transpsoas minimally invasive lateral interbody fusion on segmental and regional lumbar lordosis. *Scientific-WorldJournal*. 2012;2012:516706.
- Lehmen JA, Gerber EJ. MIS lateral spine surgery: a systematic literature review of complications, outcomes, and economics. *Eur Spine J*. 2015;24(suppl 3):287-313.
- Phan K, Rao PJ, Scherman DB, Dandie G, Mobbs RJ. Lateral lumbar interbody fusion for sagittal balance correction and spinal deformity. *J Clin Neurosc*. 2015;22:1714-1721.
- Anand N, Agrawal A, Burger EL, et al. The prevalence of the use of MIS techniques in the treatment of adult spinal deformity (ASD) amongst Members of the Scoliosis Research Society (SRS) in 2016. *Spine Deform*. 2019;7:319-324.
- Kotwal S, Kawaguchi S, Lebl D, et al. Minimally invasive lateral lumbar interbody fusion: clinical and radiographic outcome at a minimum 2-year follow-up. *J Spinal Disord Tech*. 2015;28:119-125.
- Godzik J, Kalb S, Reis MT, et al. Biomechanical evaluation of interbody fixation with secondary augmentation: lateral lumbar interbody fusion versus posterior lumbar interbody fusion. *J Spine Surg*. 2018;4:180-186.
- Salzmann SN, Shue J, Hughes AP. Lateral lumbar interbody fusion-outcomes and complications. *Curr Rev Musculoskelet Med*. 2017;10:539-546.
- Torretti J, Harris JA, Bucklen BS, Moldavsky M, Khalil SED. In vitro biomechanical and fluoroscopic study of a continuously expandable interbody spacer concerning its role in insertion force and segmental kinematics. *Asian Spine J*. 2018;12:601-610.
- Folman Y, Lee SH, Silvera JR, Gepstein R. Posterior lumbar interbody fusion for degenerative disc disease using a minimally invasive B-twin expandable spinal spacer: a multicenter study. *J Spinal Disord Tech*. 2003;16:455-460.
- Bhatia NN, Lee KH, Bui CN, Luna M, Wahba GM, Lee TQ. Biomechanical evaluation of an expandable cage in single-segment posterior lumbar interbody fusion. *Spine (Phila Pa 1976)*. 2012;37:E79-E85.
- Zheng X, Chaudhari R, Wu C, Mehbod AA, Erkan S, Transfeldt EE. Biomechanical evaluation of an expandable meshed bag augmented with pedicle or facet screws for percutaneous lumbar interbody fusion. *Spine J*. 2010;10:987-993.
- Qandah NA, Klocke NF, Synkowski JJ, et al. Additional sagittal correction can be obtained when using an expandable titanium interbody device in lumbar Smith-Peterson osteotomies: a biomechanical study. *Spine J*. 2015;15:506-513.
- Park JH, Bae CW, Jeon SR, Rhim SC, Kim CJ, Roh SW. Clinical and radiological outcomes of unilateral facetectomy and interbody fusion using expandable cages for lumbosacral foraminal stenosis. *J Korean Neurosurg Soc*. 2010;48:496-500.

17. Mantell M, Cyriac M, Haines CM, Gudipally M, O'Brien JR. Biomechanical analysis of an expandable lateral cage and a static transforaminal lumbar interbody fusion cage with posterior instrumentation in an in vitro spondylolisthesis model. *J Neurosurg Spine*. 2016;24:32-38.
18. Glassman SD, Berven S, Bridwell K, Horton W, Dimar JR. Correlation of radiographic parameters and clinical symptoms in adult scoliosis. *Spine (Phila Pa 1976)*. 2005;30:682-688.
19. Lazennec JY, Ramare S, Arafati N, et al. Sagittal alignment in lumbosacral fusion: relations between radiological parameters and pain. *Eur Spine J*. 2000;9:47-55.
20. Glassman SD, Bridwell K, Dimar JR, Horton W, Berven S, Schwab F. The impact of positive sagittal balance in adult spinal deformity. *Spine (Phila Pa 1976)*. 2005;30:2024-2029.
21. Choi JY, Sung KH. Subsidence after anterior lumbar interbody fusion using paired stand-alone rectangular cages. *Eur Spine J*. 2006;15:16-22.
22. Fogel GR, Toohey JS, Neidre A, Brantigan JW. Fusion assessment of posterior lumbar interbody fusion using radiolucent cages: X-ray films and helical computed tomography scans compared with surgical exploration of fusion. *Spine J*. 2008;8:570-577.
23. Copay AG, Glassman SD, Subach BR, Berven S, Schuler TC, Carreon LY. Minimum clinically important difference in lumbar spine surgery patients: a choice of methods using the Oswestry Disability Index, Medical Outcomes Study questionnaire Short Form 36, and pain scales. *Spine J*. 2008;8:968-974.
24. Glassman S, Gornet MF, Branch C, et al. MOS short form 36 and Oswestry Disability Index outcomes in lumbar fusion: a multi-center experience. *Spine J*. 2006;6:21-26.
25. Katz NP, Paillard FC, Ekman E. Determining the clinical importance of treatment benefits for interventions for painful orthopedic conditions. *J Orthop Surg Res*. 2015;10:24.
26. Lee JS, Hobden E, Stiell IG, Wells GA. Clinically important change in the visual analog scale after adequate pain control. *Acad Emerg Med*. 2003;10:1128-1130.
27. Alimi M, Shin B, Macielak M, et al. Expandable polyaryl-ether-ether-ketone spacers for interbody distraction in the lumbar spine. *Global Spine J*. 2015;5:169-178.
28. Frisch RF, Luna IY, Brooks DM, Joshua G, O'Brien JR. Clinical and radiographic analysis of expandable versus static lateral lumbar interbody fusion devices with two-year follow-up. *J Spine Surg*. 2018;4:62-71.
29. Tempel ZJ, McDowell MM, Panczykowski DM, et al. Graft subsidence as a predictor of revision surgery following stand-alone lateral lumbar interbody fusion. *J Neurosurg Spine*. 2018;28:50-56.
30. Marchi L, Abdala N, Oliveira L, Amaral R, Coutinho E, Pimenta L. Stand-alone lateral interbody fusion for the treatment of low-grade degenerative spondylolisthesis. *ScientificWorldJournal*. 2012;2012:456346.
31. Pimenta L, Turner AW, Dooley ZA, Parikh RD, Peterson MD. Biomechanics of lateral interbody spacers: going wider for going stiffer. *ScientificWorldJournal*. 2012;2012:381814.
32. Marchi L, Abdala N, Oliveira L, Amaral R, Coutinho E, Pimenta L. Radiographic and clinical evaluation of cage subsidence after stand-alone lateral interbody fusion. *J Neurosurg Spine*. 2013;19:110-118.
33. Macki M, Anand SK, Surapaneni A, Park P, Chang V. Subsidence rates after lateral lumbar interbody fusion: a systematic review. *World Neurosurg*. 2019;122:599-606.