

Case Report

Isolated ligamentum flavum ossification in primary hypoparathyroidism

Amir H. Sohail, Muhammad A. A. Maan, Muhammad S. Khan, Qamar Masood¹Aga Khan University Medical College, ¹Department of Medicine, Aga Khan University, Karachi, PakistanE-mail: *Amir H. Sohail - ameer.hamzasohail@gmail.com; Muhammad A. A. Maan - marlsanarif@ymail.com; Muhammad S. Khan - salmankhan3935@gmail.com; Qamar Masood - qamar.masood@aku.edu

*Corresponding author

Received: 27 September 17 Accepted: 26 October 17 Published: 10 January 18

Abstract

Background: The ligamenta flava can undergo ossification and calcification resulting in myelopathy. Only seven cases of ligamentum flavum ossification in association with hypoparathyroidism have been reported, most of which had concurrent osseous changes in other spinal ligaments. Here, we report a patient with hypoparathyroidism who presented with ligamentum flavum ossification causing both cervical and thoracic myelopathy.

Case Description: A 43-year-old male presented with backache, urinary retention, and lower limb weakness for the last few days. Magnetic resonance imaging scan showed ossification of the ligamentum flavum in the cervical and thoracic regions, with severe spinal stenosis. Following spinal decompressive surgery, the patient made a complete recovery. Primary hypoparathyroidism was found to be the underlying cause for ligamentum flavum ossification.

Conclusion: Ossification of ligamentum flavum secondary to hypoparathyroidism should be considered as a possible cause of myelopathy in all patients presenting with symptoms of spinal cord compression.

Key Words: Hypoparathyroidism, ligamentum flavum, myelopathy, ossification, parathyroid hormone

Access this article online

Website:www.surgicalneurologyint.com**DOI:**

10.4103/sni.sni_364_17

Quick Response Code:

INTRODUCTION

Degenerative calcification/ossification of the ligamentum flavum (OLF) often affects the geriatric Asian population. Although it is most prominent in the Japanese, it is only rarely found in the Pakistani population.^[2,6]

OLF, resulting in thoracic myelopathy, is most frequently attributed to hypoparathyroidism, as well as to other factors and conditions (e.g. vitamin D, parathyroid hormone (PTH), local tissue growth factors, insulin, hyperthyroidism, hemochromatosis) [Table 1].^[2,12] Here, we present a patient with hypoparathyroidism with isolated OLF resulting in both thoracic and cervical myelopathy.

CASE PRESENTATION

A 43-year-old Punjabi male presented with backache, lower extremity weakness, and urinary retention of several days

This is an open access article distributed under the terms of the Creative Commons Attribution-NonCommercial-ShareAlike 3.0 License, which allows others to remix, tweak, and build upon the work non-commercially, as long as the author is credited and the new creations are licensed under the identical terms.

For reprints contact: reprints@medknow.com

How to cite this article: Sohail AH, Maan MA, Khan MS, Masood Q. Isolated ligamentum flavum ossification in primary hypoparathyroidism. *Surg Neurol Int* 2018;9:4.

<http://surgicalneurologyint.com/Isolated-ligamentum-flavum-ossification-in-primary-hypoparathyroidism/>

duration. He had fallen from a height of three feet while working in the fields the previous week. The neurological examination was consistent with a severe spastic paraplegia; marked lower extremity weakness/paraparesis (1/5), bilateral diffuse hyperreflexia, and bilateral Babinski responses.

Magnetic resonance imaging (MRI) scan of the spine showed multilevel OLF with marked spinal cord compression at the C4-C5 and T10-T11 levels [Figures 1-3]. Intramedullary hyperintense signals were also identified on T2-weighted sequences at the T3 and T10-T11 levels [Figures 4 and 5].

The patient underwent laminectomies at the C4-C5, T3-T4, and T10-T11 levels. Intraoperatively, the patient sustained an acute myocardial infarction. Calcium and phosphorus studies were consistent with the diagnosis of primary hypoparathyroidism; low ionized calcium level (1.99 mg/dL), low calcium level (4.2 mg/dL), low corrected calcium (5.0 mg/dL), low magnesium

(0.9 mg/dL), high phosphorus (7.7 mg/dL), and a low parathyroid hormone level (<3.0 pg/ml). The patient was treated with intravenous calcium gluconate and magnesium, and oral calcium, magnesium, and vitamin D.

Table 1: Causes for ligamentum flavum ossification reported in literature^[1]

Hypoparathyroidism
Diabetes mellitus Type 1 and 2
Hyperthyroidism
Hemochromatosis
Fluorosis
Rickets
Hypophosphatemic vitamin D resistant rickets
Diffuse idiopathic skeletal hyperostosis
Paget's disease
Adenocarcinomatous metastasis

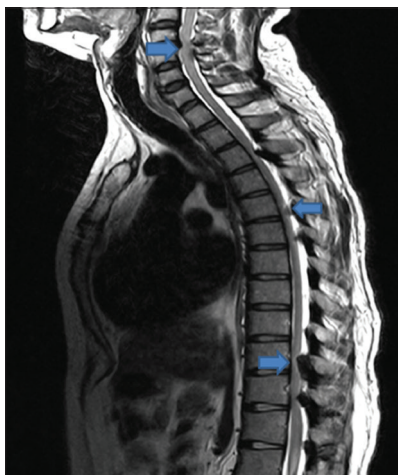


Figure 1: T2-weighted sagittal section showing multilevel ossification of ligamentum flavum (arrows) causing cord compression at multiple levels in cervical and thorax spine

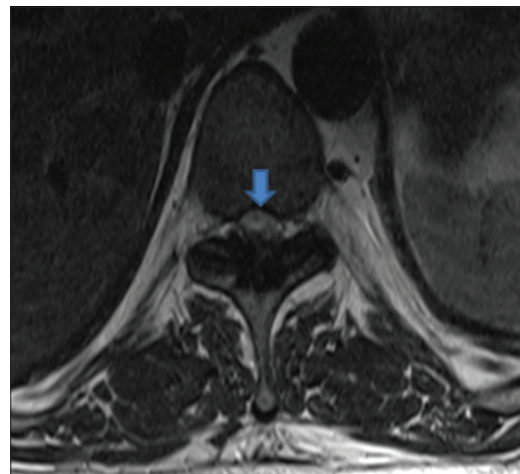


Figure 2: T2-weighted axial section at T10-T11 level showing ossification of ligamentum flavum with severe spinal canal stenosis and cord compression (arrow)

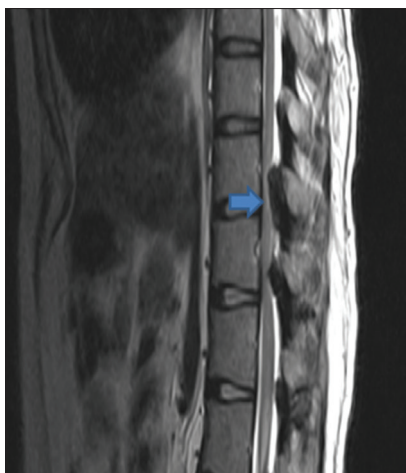


Figure 3: T2-weighted sagittal section at T10-T11 level showing ossification of ligamentum flavum with severe spinal canal stenosis and cord compression (arrow)

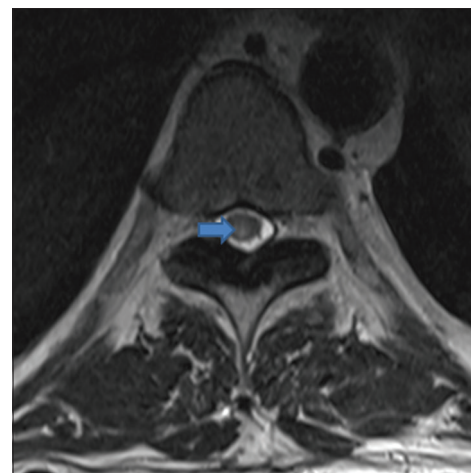


Figure 4: T2-weighted axial section at T10-T11 level showing intramedullary hyperintense signal changes (arrow) suggesting cord edema

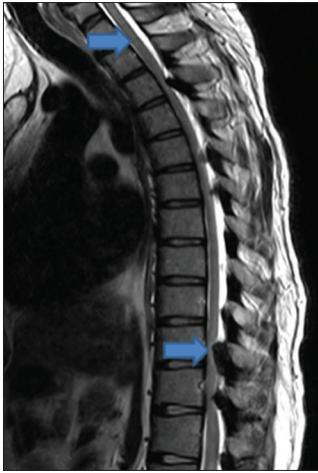

Figure 5: T2-weighted sagittal section showing intramedullary hyperintense signal changes at T10-T11 and T3 levels (arrows) suggesting cord edema

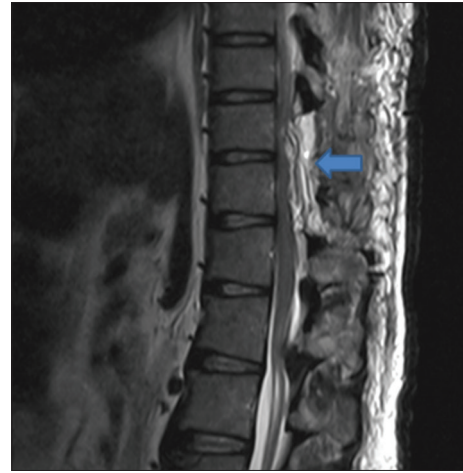

Figure 6: T2 weighted sagittal section at T10-T11 level showing removal of previously present large ossified ligamentum flavum segment (arrow). Significant postsurgical changes are seen

Table 2: Hypoparathyroidism patients with ossification of ligamentum flavum in literature

Author	Age (years)	Sex	Cause	Other ligaments ossified
Okazaki <i>et al.</i>	66	M	Idiopathic	PLL, ALL, SSL, NL, PPL
	55	F	Idiopathic	PLL, ALL, SSL, PPL
	49	F	Idiopathic	PLL, ALL, SSL, NL, PPL
	21	F	Idiopathic	-
	31	M	Idiopathic	-
Adams <i>et al.</i>	62	M	Idiopathic	ALL
Chakravarty <i>et al.</i>	45	M	Post-surgical	-

PLL: Posterior longitudinal ligaments, ALL: Anterior longitudinal ligaments, SSL: Supraspinatus ligaments, NL: Nuchal ligaments, PPL: Peripelvic ligaments

The postoperative MRI scans documented adequate OLF removal at the C4-C5 and T10-T11 levels [Figure 6]. The patient was discharged on the 10th postoperative day with a corrected calcium level of 7.8 mg/dl, having attained complete resolution of his preoperative motor deficit and urinary incontinence.

DISCUSSION

Patients with OLF can present with myelopathy due to cervical and/or thoracic cord compression [Table 2].^[2] OLF is most commonly found between the T9 and T12 levels.^[6] Some may present with classical myelopathy or atypical symptoms (e.g., chest/abdominal pain, numbness, lower extremity claudication, or no deficit whatsoever).^[3,5]

The pathophysiology of OLF, most typically attributed to hypoparathyroidism, is incompletely understood.^[1,4,8] Disorders of calcium regulating hormonal factors (e.g., hypoparathyroidism) can result in abnormal calcium and phosphorus levels that lead to ligamentum flavum calcification and ossification.^[9,11] Two studies suggested OLF was attributable to low calciuric responses

whereas another study found no association between 1-25 dihydroxycholecalciferol and OLF.^[7,9,11]

About 50% of patients with thoracic myelopathy due to OLF will improve.^[2] Poor prognostic factors include high intramedullary cord signals seen on MR examinations (e.g., myelomalacia rather than just edema) and dural adhesions/ossifications documented on preoperative CT studies.^[2,10]

CONCLUSION

Ossification of ligamentum flavum is a possible cause of myelopathy in patients with symptoms of spinal cord compression. If OLF is present, laboratory investigations should include a workup for hypoparathyroidism. Most critically, when myelopathy is significant, prompt surgical decompression is warranted.

Declaration of patient consent

The authors certify that they have obtained all appropriate patient consent forms. In the form the patient has given her consent for her images and other clinical information to be reported in the journal. The patient understands that name and initial will not be published and due efforts will be made to conceal identity, but anonymity cannot be guaranteed.

Financial support and sponsorship

Nil.

Conflicts of interest

There are no conflicts of interest.

REFERENCES

- Adams JE, Davies M. Paravertebral and peripheral ligamentous ossification: An unusual association of hypoparathyroidism. *Postgrad Med J* 1977;53:167-72.
- Ahn DK, Lee S, Moon SH, Boo KH, Chang BK, Lee J. Ossification of the

- Ligamentum Flavum. *Asian Spine J* 2014;8:89-96.
3. Aizawa T, Sato T, Sasaki H, Matsumoto F, Morozumi N, Kusakabe T, et al. Results of surgical treatment for thoracic myelopathy: Minimum 2-year follow-up study in 132 patients. *J Neurosurg Spine* 2007;7:13-20.
 4. Chakravarty A, Anand S, Sapra H, Mehta Y. Undetected hypoparathyroidism: An unusual cause of perioperative morbidity. *Indian J Anaesth* 2014;58:470.
 5. Hur H, Lee J, Lee J, Kim J, Kim S. Thoracic Myelopathy Caused by Ossification of the Ligamentum Flavum. *J Korean Neurosurg Soc* 2009;46:189.
 6. Kang K, Lee C, Shin S, Park S, Chung C, Chung S. Ossification of the ligamentum flavum of the thoracic spine in the Korean population. *J Neurosurg Spine* 2011;14:513-9.
 7. Li H, Jiang L, Dai L. Hormones and growth factors in the pathogenesis of spinal ligament ossification. *Eur Spine J* 2007;16:1075-84.
 8. Okazaki T, Takuwa Y, Yamamoto M, Matsumoto T, Igarashi T, Kurokawa T, et al. Ossification of the paravertebral ligaments: A frequent complication of hypoparathyroidism. *Metabolism* 1984;33:710-3.
 9. Park B, Min W, Oh C, Jeon I, Kim S, Kyung H, et al. Surgical outcome of thoracic myelopathy secondary to ossification of ligamentum flavum. *Joint Bone Spine* 2007;74:600-5.
 10. Seichi A, Hoshino Y, Kimura A, Nakahara S, Watanabe M, Kato T, et al. Neurological Complications of Cervical Laminoplasty for Patients With Ossification of the Posterior Longitudinal Ligament—A multi-Institutional Retrospective Study. *Spine* 2011;36:E998-E1003.
 11. Shen HX, Li L, Yang ZG, Hou TS. Position of increased signal intensity in the spinal cord on MR images: Does it predict the outcome of cervical spondylotic myelopathy?. *Chin Med J (Engl)* 2009;122:1418-22.
 12. Shiraishi T, Crock HV, Lewis P. Thoracic myelopathy due to isolated ossification of the ligamentum flavum. *J Bone Joint Surg* 1995;77-B: 131-3.