

# A Child of Congenital Muscular Dystrophy-Dystroglycanopathy with Homozygous Missense Variation in Exon 3 of the ISPD Gene: A Rare Case from Odisha

## Abstract

Dystroglycanopathy is a type of congenital muscular dystrophy caused by mutations causing defective glycosylation of a dystrophin-associated glycoprotein, dystroglycan and as such is a very rare disease entity. We are reporting a 1-year-old girl child with dystroglycanopathy who presented with motor predominant developmental delay. She had motor development quotient of 52, mental development quotient of 75, facial dysmorphism, mixed hypotonia with a global decrease in muscle power, and areflexia. Serum CPK level was elevated; magnetic resonance imaging brain revealed multiple intraparenchymal cysts in the cerebellum with disorganized folia. Next-generation sequencing revealed a homozygous missense mutation in exon 3 of the ISPD gene (p.Gln215His; ENST00000407010) consistent with the diagnosis of dystroglycanopathy muscle-eye-brain disease. Genetic counseling and prenatal diagnosis for subsequent pregnancies were advised for the family, apart from appropriate rehabilitation for the child.

**Keywords:** *Cysts in cerebellum, dystroglycanopathies, generalized hypotonia, muscle-eye-brain, Odisha*

## Introduction

Dystroglycanopathy is a type of congenital muscular dystrophy caused by mutations causing defective glycosylation of a dystrophin-associated glycoprotein, dystroglycan. They are very often associated with clinical manifestation of the central nervous system and ocular involvement.<sup>[1]</sup> The dystroglycanopathy may be a very severe degree in Walker–Warburg syndrome (WWS), moderately severe in muscle-eye-brain disease (MEB), or milder manifestations in cases of Fukuyama congenital muscular dystrophy (FCMD).<sup>[2]</sup>

MEB was first detected in 1977 in Finland, which demonstrates autosomal recessive inheritance.<sup>[3]</sup> MEB patients are mostly floppy infants with visual and cognitive impairment. The mixed hypotonia is attributed to muscular dystrophy and cerebral malfunction. Hypotonia progressively becomes hypertonic and later leads to contracture formation. Impaired vision is due to the development of myopia, degeneration of the retina, and congenital glaucoma. They may develop juvenile

cataracts develop if they survive up to the age of 10 years.<sup>[4]</sup>

The average life expectancy of MEB children is around 10–30 years.<sup>[5]</sup> We should know the difference among all the three muscular dystrophies to prognosticate the life expectancy and complications.

## Case Report

A 1-year-old girl second born to a consanguineous couple presented with motor predominant developmental delay. She was not able to stand or walk but was able to sit only with support. She was able to speak bisyllables, and her hearing and vision were normal. Her motor development quotient was 52, and the mental development quotient was 75 (overall development quotient was 63.5 in Development Assessment Scale for Indian Infant). There was no history of seizures or recurrent episodes of encephalopathy. There was a history of sibling death (intrauterine). The child had one episode of hospitalization in the past for pneumonia and also had feeding difficulties. Family history and birth history was uneventful.

This is an open access journal, and articles are distributed under the terms of the Creative Commons Attribution-NonCommercial-ShareAlike 4.0 License, which allows others to remix, tweak, and build upon the work non-commercially, as long as appropriate credit is given and the new creations are licensed under the identical terms.

For reprints contact: WKHLRPMedknow\_reprints@wolterskluwer.com

**How to cite this article:** Biswal S, Panigrahi D, Mohakud NK, Kumar M, Swain N. A child of congenital muscular dystrophy-dystroglycanopathy with homozygous missense variation in exon 3 of the ISPD Gene: A rare case from Odisha. *Adv Biomed Res* 2020;9:70.

**Sebaranjan Biswal, Debasish Panigrahi<sup>1</sup>, Nirmal Kumar Mohakud, Manoj Kumar, Natabara Swain**

*Department of Pediatrics, Kalinga Institute of Medical Sciences, KIIT Deemed to be University, <sup>1</sup>Department of Pediatrics, Jagarnath Hospital, Bhubaneswar, Odisha, India*

### Address for correspondence:

*Dr. Nirmal Kumar Mohakud, Department of Paediatrics, Kalinga Institute of Medical Sciences, KIIT Deemed to be University, Bhubaneswar, Odisha, India.  
E-mail: nirmal.mahakud@kims.ac.in*

**Received:** 24 June 2019

**Revised:** 06 July 2020

**Accepted:** 29 July 2020

**Published:** 28 November 2020

### Access this article online

**Website:** www.advbiores.net

**DOI:** 10.4103/abr.abr\_141\_19

### Quick Response Code:



On examination, she had stable vitals, facial dysmorphism in the form of depressed nasal bridge, squint, and protruded tongue [Figure 1]. Neurological examination revealed generalized hypotonia with reduced muscle power, more in bilateral lower limbs [Figure 2]. Deep tendon reflexes were absent in both upper and lower limbs, the bilateral plantar response was flexor, and there were no sensory deficits. There was no fasciculations or hypertrophy of any group of muscles. The examination of other systems was found to be normal. On fundoscopy, foveal reflex was normal, but left temporal pallor with the tilted disc was found. An abnormally high hairline on the forehead was observed [Figure 3].

Investigations revealed normal complete blood counts, serum electrolytes, and thyroid function tests. Serum CPK levels were very high (6562 U/L). Magnetic resonance imaging brain revealed multiple intraparenchymal cysts in the cerebellum with disorganized folia, and white matter showed diffusely abnormal hyperintensities on T2-weighted images [Figure 4].

Nerve conduction study was normal, and electromyography was suggestive of the myopathic

pattern. Echocardiogram showed normal cardiac function. Next-generation sequencing revealed a homozygous pathogenic missense variation in exon 3 of the Isoprenoid Synthase Domain-Containing Protein (ISPD) gene (chr7:16415756T>G; Depth: 91x) that resulted in the amino acid substitution of Histidine for Glutamine at codon 215 (p.Gln215His; ENST00000407010). The presence of this pathogenic mutation was confirmed by sanger sequencing. The observed variation was found to reside in the 2-C-methyl-D-erythritol 4-phosphate cytidyltransferase of the ISPD protein. This novel variant was not found to be reported in ExAC, 1000 genomes, and other genetic databases, and in silico prediction of this variant by Polyphen-2, SIFT and Mutation Taster 2 was found to be damaging. The reference codon was found to be conserved across species. Both parents were found to be carriers for the detected variant in the co-segregation analysis. Genetic counseling and prenatal diagnosis for subsequent pregnancies were advised for the family, apart from appropriate rehabilitation for the child.

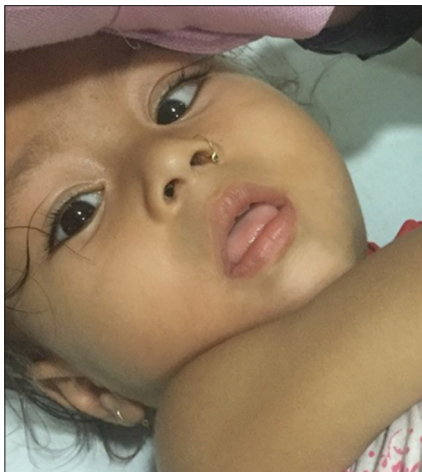

Figure 1: Hypertelorism, squint, protruded tongue, and scarf sign (hyper mobility of joints)

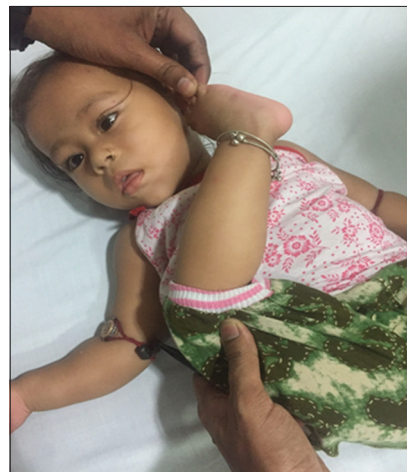

Figure 2: Floppy child with hypermobility of joint shown by heel to ear test

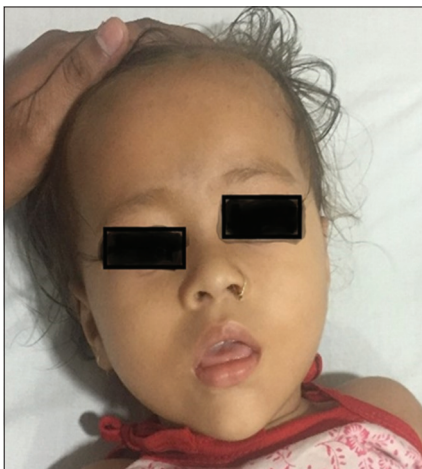

Figure 3: Abnormally high hairline on the forehead

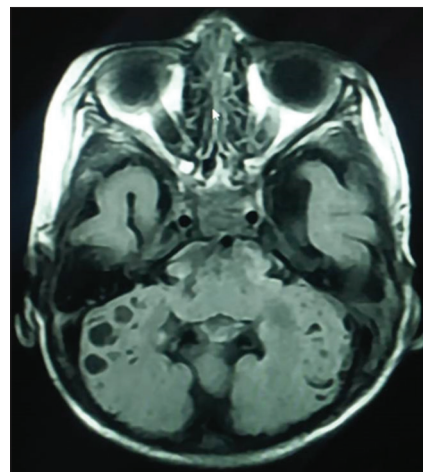


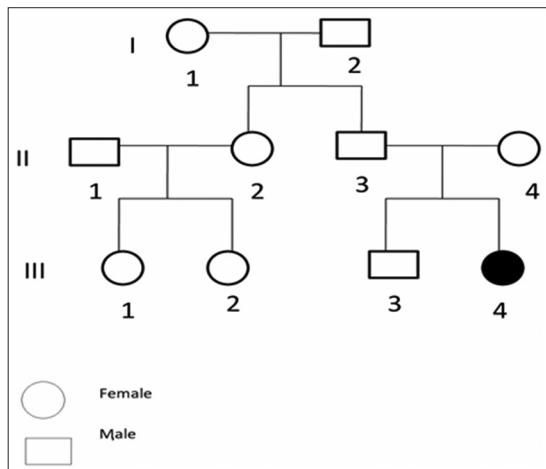
Figure 4: Revealed multiple intraparenchymal cysts in cerebellum with disorganized folia and diffusely abnormal white matter signal on T2-weighted images

## Discussion

Congenital muscular dystrophy is as such classified into merosin positive and merosin negative muscular dystrophy. In the merosin positive group apart from dystroglycanopathy, collagen VI associated muscular dystrophy and other rare types have been described. Dystroglycanopathy is divided into three types, i.e., Type A; MDDGA3, Type B; MDDGB3 and Type C; MDDGC3 depending on mutations in the POMGnT1 gene.<sup>[6]</sup> Type A represents WWS, WWS-like, MEB, and FCMD-like; type B represents CMD CRB (CMD with cerebellar involvement), CMD MR and CMD no MR; and type C represents both LGMD MR (limb-girdle muscular dystrophy with mental retardation) and LGMD no MR.<sup>[1]</sup> These clinical categories are further subdivided into seven subtypes, as represented by a genetic defect. Subtype 1: POMT1, subtype 2: POMT2, subtype 3: POMGNT1, subtype 4: FKTN, subtype 5: FKR, subtype 6: LARGE and subtype 7: ISPD.<sup>[7]</sup>

Dystroglycanopathy with the brain and eye anomalies may occur due to homozygous or compound heterozygous mutations in the ISPD gene (OMIM\*614631). It results from defective glycosylation of alpha-dystroglycan. Histopathological examination of muscle biopsy specimen shows dystrophic changes and a reduction of glycosylated alpha-dystroglycan. Their average life expectancy is 2 years.<sup>[8]</sup> To the best of our knowledge, this case is the first detection of the Gln215His variant and has not been reported in databases.

We initially also clinically suspected the child to suffer from congenital muscular dystrophy, most probably dystroglycanopathy due to the delayed motor milestone, past hospitalization for pneumonia and also had feeding difficulties, mixed hypotonia (floppiness), facial dysmorphism, neuroimaging abnormalities, and fundus abnormalities. The genetic study also confirmed the case to be a case of MEB. Genetic sequencing should be performed in cases with suspected congenital muscular dystrophy, as it helps in prognosticating by finding exact genetic etiology



**Figure 5: Pedigree chart. An autosomal recessive inheritance, possibility of 25% sibling is affected**

and complex posttranslational modification pathways which involves the development of brain and muscles.<sup>[8]</sup>

As it is a disorder of an autosomal recessive inheritance, the possibility of 25% sibling is affected, 50% being the carrier, and 25% being normal is expected [Figure 5]. Hence, parents need to be tested for carrier state, and antenatal screening during subsequent pregnancies is advised for the family. In the animal model, it was found that the viral genome may be used to deliver LARGE to skeletal muscles *in vivo* and thereby establishing the glycosylation function of muscles in dystroglycanopathy disorders.<sup>[9]</sup> This may be the feature therapeutic option for these diseases.

## Declaration of patient consent

The authors certify that they have obtained all appropriate patient consent forms. In the form, the patient's parents have given their consent for her images and other clinical information to be reported in the journal. The parents understand that the name and initials will not be published, and due efforts will be made to conceal identity.

## Financial support and sponsorship

Nil.

## Conflicts of interest

There are no conflicts of interest.

## References

- Godfrey C, Foley AR, Clement E, Muntoni F. Dystroglycanopathies: Coming into focus. *Curr Opin Genet Dev* 2011;21:278-85.
- de Bernabé DB, Currier S, Steinbrecher A, Celli J, van Beusekom E, van der Zwaag B, et al. Mutations in the O-Mannosyltransferase Gene POMT1 Give Rise to the Severe Neuronal Migration Disorder Walker-Warburg Syndrome. *Am J Hum Genet* 2002;71:1033-43.
- Diesen C, Saarinen A, Pihko H, Rosenlew C, Cormand B, Dobyns WB, et al. POMGnT1 mutation and phenotypic spectrum in muscle-eye-brain disease. *J Med Genet* 2004;41:e115.
- Norio R. Finnish disease heritage I. *Hum Genet* 2003;112:441-56.
- Teber S, Sezer T, Kafalı M, Manzini MC, Yüksel BK, Tekin M, et al. Severe muscle-eye-brain disease is associated with a homozygous mutation in the POMGnT1 gene. *Eur J Paediatr Neurol* 2008;12:133-336.
- Amberger J, Bocchini C, Hamosh A. A new face and new challenges for Online Mendelian Inheritance in Man (OMIM®). *Hum Mutat* 2011;32:564-7.
- Sparks SE, Quijano-Roy S, Harper A, Rutkowski A, Gordon E, Hoffman EP, et al. Congenital muscular dystrophy overview. In: Adam MP, et al. Ardingner HH, Pagon RA, Wallace SE, Bean LJH, Stephens K, et al., editors. *GeneReviews®*. Seattle (WA): University of Washington, Seattle; January 22, 2001.
- Roscioli T, Kamsteeg EJ, Buysse K, Maystadt I, Reeuwijk JV, Elzen CV, et al. Mutations in ISPD cause Walker-Warburg syndrome and defective glycosylation of  $\alpha$ -dystroglycan. *Nat Genet* 2012;44:581.
- Brockington M, Torelli S, Sharp PS, Liu K, Cirak S, Brown SC, et al. Transgenic overexpression of LARGE induces  $\alpha$ -dystroglycan hyperglycosylation in skeletal and cardiac muscle. *PLoS One* 2010;5:e14434.