

Cyclosporine in the Treatment of a Case of Fulminant and Refractory Acute Disseminated Encephalomyelitis

Mohammad-Mehdi Taghdiri¹, MD; Ali Amanati², MD, and Babak Abdolkarimi², MD

1. Department of Pediatrics, Hamadan University of Medical Sciences, Hamadan, Iran
2. Fatemeh Hospital, Hamadan University of Medical Sciences, Hamadan, Iran

Received: Aug 10, 2010; Final Revision: Mar 17, 2011; Accepted: May 19, 2011

Abstract

Background: Acute disseminated encephalomyelitis (ADEM) is a rare, monophasic, demyelinating disease of the CNS which sometimes could be refractory to traditional treatment.

Case Presentation: We present a case of fulminant ADEM which is treated with combination of corticosteroid, intravenous immunoglobulin and cyclosporine.

Conclusion: Immunosuppressive agents such as cyclosporine may be effective especially in fulminant form of the disease.

Iranian Journal of Pediatrics, Volume 21 (Number 4), December 2011, Pages: 535-538

Key Words: Acute disseminated encephalomyelitis; ADEM; Cyclosporine; Demyelination

Introduction

Acute disseminated encephalomyelitis (ADEM) is a monophasic syndrome characterized by the rapid onset of neurologic signs and symptoms after viral or bacterial infections or more rarely by vaccination with an incidence of 0.4 to 0.8 per 100,000 per year [1-6], and generally affects children aged 5 months to 12 years [8]. A triad of focal neurologic deficit, ataxia and alteration in mental state has been described for this rare condition [9]. Features that may aid in distinguishing ADEM include prodromal febrile illness, frequent widespread central nervous system (CNS) disturbance (coma/drowsiness), with high load lesions, large bilateral white matter lesions and thalamic involvement in neuroimaging

[10]. Therapeutic agents include corticosteroids, intravenous immunoglobulin, and plasmapheresis [6,11]. Immunosuppressive agents have been used in rare circumstances [12,13]. It is more frequently encountered in children than in adults [14] and affecting boys more frequently. No association was found between magnetic resonance imaging (MRI) finding and disability [4,15].

Case Presentation

This 6-year-old boy visited pediatric clinic in Besat, a university-affiliated urban hospital, because of acute onset ataxia, loss of

* Corresponding Author;

Address: Neonatal Division, Fatemeh Hospital, Hamadan University of Medical Sciences, Hamadan, Iran

E-mail: ali_amanati_1356@yahoo.com

consciousness and disorientation after upper respiratory illness for one week. He was admitted in pediatric neurology ward with primary diagnosis of acute encephalitis. Rapid course of clinical signs and symptoms included progressive loss of consciousness, confusion, ptosis, drooling and progressed to bulbar palsy and respiratory insufficiency. Because of rapid mental deterioration mechanical ventilation started 6 hours after admission. Axillary body temperature was 37.2°C, BP 100/60mmHg, RR 24/min, and PR 120/min. Papillary reflexes were normal, deep tendon reflex was diminished in patellar tendons; bilaterally upward Babinski sign, and decreased muscle force especially in lower extremities were present. Cerebrospinal fluid (CSF), blood, and urine cultures were negative. CSF-PCR for HSV also was negative. BUN 16, Cr 0.7, liver function tests and plasma ammonia were normal. ESR was 34 and C-reactive protein was positive (2+). Anti nuclear antibodies (ANA), peripheral and Cytoplasmic antineutrophil cytoplasmic antibodies (p-ANCA and c-ANCA) were negative. The course of treatment was complicated with aspiration pneumonia and right side focal tonic colonic seizures. In the course of treatment (in PICU) two times of CPR performed successfully. Brain CT scan (without contrast) was normal, brain MRI revealed demyelinating areas in subcortical and posterior occipital lobes (Fig. 1).

Clinical signs of encephalitis, rapid progressive course of the disease and MRI features were

suggestive of ADEM. Intravenous methylprednisolone 30 mg/kg/day for 3 days led to no improvement, so it was tapered during 14 days. Intravenous immunoglobulin (IVIg) (0.4gr/Kg/day) given for 5 days, did not change mental status. The patient was ventilator dependent. Eight days after admission we decided to give intravenous cyclosporine 3 mg/Kg/day and discontinued after 5 days. Renal function was monitored by intermittent BUN and Creatinine measurements. Four days later consciousness of the patient had significantly improved and he could be weaned from ventilator. After 26 days he was discharged from pediatric intensive care unit (PICU) and transmitted to pediatric ward. Electromyography done later in follow up showed a demyelinating pattern. After six months follow up he had no neurologic sequels.

Discussion

The diagnosis of ADEM in our patient was based on clinical presentation with fever, altered level of consciousness, motor deficits, imaging findings [16], and the exclusion of acute CNS infections. Alteration of consciousness and rapid evolution of disease have been shown in previous reports to be poor prognostic factors [2] which were positive in

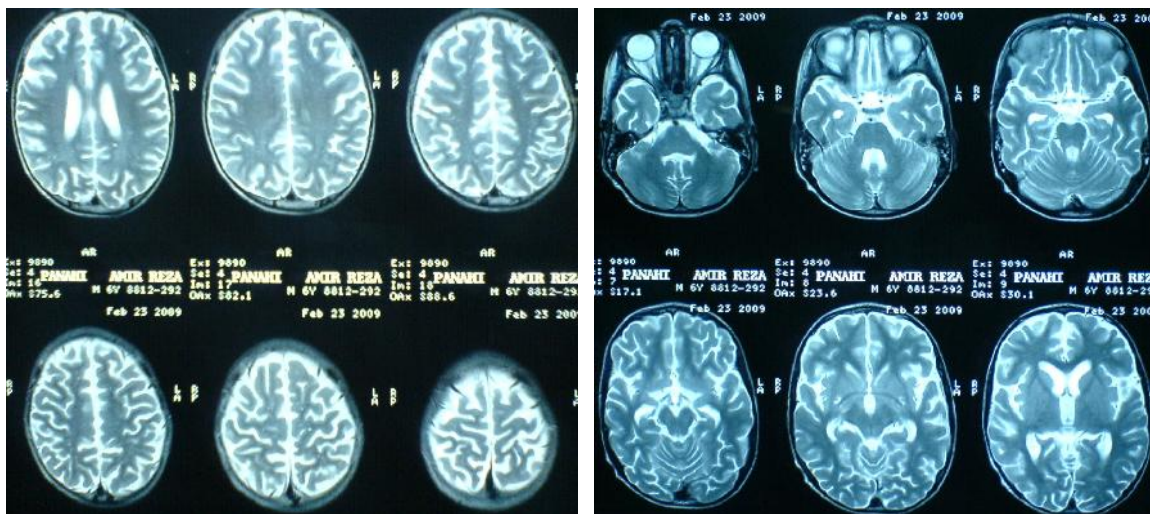


Fig. 1: Brain MRI shows multiple hyperintense images as diffuse subcortical demyelinating areas especially in posterior occipital lobes

in our patient and classified him as a severe fulminant form of ADEM [17]. Up to now, intravenous high-dose corticosteroid treatment, based on empirical evidence, is widely accepted as the first-line therapy [4,18]. The usual approach is administration of methyl-prednisolone for 3-5 days intravenously [2]. High dose intravenous methyl-prednisolone (15-30 mg/kg/day, maximum 1 g) given for 3 days, when used early during the course of fulminant ADEM, was effective in some reports [18,19]. Clinical improvement generally begins within 24 hours of the first dose of methyl-prednisolone even in patients with protracted worsening before the institution of treatment [5]. Other anti-inflammatory and immunosuppressant therapies as well as plasmapheresis and intravenous immunoglobulin may be effective [2,20,21]. Appreciable clinical improvement in ADEM patients treated with intravenous immunoglobulin was noted after 2-4 days [22]. In refractory cases, steroids have been used in combination with intravenous immuno-globulin [17,19,23]. Immunosuppressive agents, such as cyclophosphamide or cyclosporine, should be considered as alternative therapies if corticosteroid treatment shows no clinical effect [2,12,13,24]. Recently, a therapeutic guideline has been proposed to facilitate clinical judgment and decision making on treatment of fulminant ADEM [17]. According to this protocol the presence of the following progressively deteriorating clinical manifestations, either isolated or in continuum, were considered indications for either high-dose methyl-prednisolone or intravenous immunoglobulin (or combined) treatment: (1) rapid deterioration to become unconscious along with impairment of cranial nerves and bulbar insufficiency; (2) severe optic neuritis associated with progressive visual loss; (3) motor deterioration to develop flaccid paraplegia and become bedridden; and (4) respiratory failure requiring mechanical ventilation [17]. As noted previously, our patient had 3 criteria of this guideline. So methyl-prednisolone pulse was tried after the diagnosis of ADEM was established without clinically observed significant improvement. Because of rapid progression of the disease and severe clinical course we started IVIG as a second line therapy. Our patient was in fairly

severe clinical state at the time of starting IVIG therapy. Although the treatment was attempted rapidly, there was no improvement in clinical state after 5 days; thus a third line agent (immunosuppressive drug) was started. Although a spontaneous improvement cannot be ruled out, we think the effect of cyclosporine in our patient was remarkable.

Conclusion

In conclusion, we observed that although high-dose corticosteroid and IV immunoglobulin treatments are widely used as routine therapeutic approaches in ADEM, treatment failure is still possible. This should be taken into consideration in designing therapeutic trials in ADEM. Immunosuppressive agents such as cyclosporine may be effective, especially in patients who present with a fulminant form of the disease.

References

1. Dale RC. Acute disseminated encephalomyelitis. *Sem Pediatr Infect Dis* 2003;14(2):90-5.
2. Menge T, Hemmer B, Nessler S, et al. Acute Disseminated encephalomyelitis. An update. *Arch Neurol* 2005;62(11):1673-80.
3. Stonehouse M, Gupte G, Wassmer E, et al. Acute disseminated encephalomyelitis: recognition in the hands of general paediatricians. *Arch Dis Childh* 2003;88(2):122-4.
4. Tenembaum S, Chamoles D, Fejerman N. Acute disseminated encephalomyelitis: A long-term follow-up study of 84 pediatric patients. *Neurology* 2002;59(8):1224-31.
5. Hynson JL, Kornberg AJ, Coleman LT, et al. Clinical and neuroradiologic features of acute disseminated encephalomyelitis in children. *Neurology* 2001;56(10):1308-12.
6. Sejvar JJ, Kohl KS, Bilynsky R, et al. Encephalitis, myelitis, and acute disseminated encephalomyelitis (ADEM): Case definitions and guidelines for collection, analysis, and

- presentation of immunization safety data. *Vaccine* 2007;25(31):5771-92.
7. Khosroshahi N, Sotoudeh K. Acute Disseminated Encephalomyelitis. *Iran J Pediatr* 2008;18(Suppl 1):81-7.
 8. Khosroshahi N, Mahvelati F, Ghofrani M. Acute disseminated encephalomyelitis in childhood; epidemiologic, clinical, and laboratory features. *Iran J Med Sci* 2007; 32(6):143-6.
 9. Rust R, Menkes JH. Autoimmune and Postinfectious Disease. In: Menkes JH, Sarnat HB, Maria BL, (eds) *Child Neurology*. 7th ed. Philadelphia: Lippincott Williams & Wilkins. 2006; Pp: 578-83.
 10. Wingerchuk DM. The clinical course of acute disseminated encephalomyelitis. *Neurol Res* 2006;28(3):341-7.
 11. Murthy SNK, Cohen ME, Bakshi R. Acute disseminated encephalomyelitis in children. *Pediatrics* 2002;110(2):e1-e7.
 12. Rust RS. Acute disseminated encephalomyelitis. Treatment and management. Available at: <http://emedicine.medscape.com/article/1147044-treatment>. Access date: 2010 November 18,
 13. Kruisselbrink RJ, Ahmad ZS. Acute disseminated encephalomyelitis with features of locked-in syndrome: successful treatment with cyclophosphamide. *Amer J Respir Critical Care Med* 2010;181 (Meeting Abstracts): PA6093.
 14. Rommel PL, Gary K. Combination regimen of methylprednisolone, IV immunoglobulin, and plasmapheresis early in the treatment of acute disseminated encephalomyelitis. *J Clin Apheresis* 2006. 21(4):260-5.
 15. Leake JA, Albani S, Kao AS, et al. Acute disseminated encephalomyelitis in childhood: epidemiologic, clinical and laboratory features. *Pediatr Infect Dis J* 2004;23(8):756-64.
 16. Ketelslegers IA, Neuteboom RF, Boon M, et al. A comparison of MRI criteria for diagnosing pediatric ADEM and MS. *Neurology* 2010. 74(18):1412-5.
 17. Shahar E, Andraus J, Savitzki D, et al. Outcome of severe encephalomyelitis in children: Effect of high-dose Methylprednisolone and Immunoglobulins. *J Child Neurol* 2002;17(11): 810-4.
 18. Apak RA, Anlar B, Saatci I. A case of relapsing acute disseminated encephalomyelitis with high dose corticosteroid treatment. *Brain Dev* 1999;21(4):279-82.
 19. Nishikawa M, Ichiyama T, Hayashi T, et al. Intravenous immunoglobulin therapy in acute disseminated encephalomyelitis. *Pediatr Neurol* 1999;21(2):583-6.
 20. Kanter DS, Horensky D, Sperling RA, et al. Plasmapheresis in fulminant acute disseminated encephalomyelitis. *Neurology* 1995;45(4):824-7.
 21. Keegan M, Pineda AA, McClelland RL, et al. Plasma exchange for severe attacks of CNS demyelination: Predictors of response. *Neurology* 2002;58(1):143-6.
 22. Pradhan S, Gupta RP, Shashank S, Pandey N. Intravenous immunoglobulin therapy in acute disseminated encephalomyelitis. *J Neurol Sci* 1999;165(1):56-61.
 23. Marchioni E, Marinou-Aktipi K, Uggetti C, et al. Effectiveness of intravenous immunoglobulin treatment in adult patients with steroid-resistant monophasic or recurrent acute disseminated encephalomyelitis. *J Neurol* 2002;249(1):100-4.
 24. Borel JF, Gunn HC. Cyclosporine as a new approach to therapy of autoimmune diseases. *Ann N Y Acad Sci* 1986;475:307-19.