

Case Report

Bilateral Sterile Pyogranulomatous Keratitis in a Dog

Michael C. Rahe ¹, Aubrey Cordray,² and Joseph Haynes³

¹Department of Veterinary Diagnostic and Production Animal Medicine, Iowa State University, 1850 Christensen Dr., Ames, IA 50011, USA

²Humboldt Veterinary Clinic, Humboldt, IA, USA

³Department of Veterinary Pathology, Iowa State University, Ames, IA, USA

Correspondence should be addressed to Michael C. Rahe; mrahe86@gmail.com

Received 16 May 2019; Revised 9 July 2019; Accepted 21 July 2019; Published 20 August 2019

Academic Editor: Isabel Pires

Copyright © 2019 Michael C. Rahe et al. This is an open access article distributed under the Creative Commons Attribution License, which permits unrestricted use, distribution, and reproduction in any medium, provided the original work is properly cited.

Purpose. To describe the clinicopathologic features of bilateral sterile pyogranulomatous keratitis in a 16-year-old spayed female rat terrier dog. **Methods.** The dog presented one year prior due to ulceration of the right and left corneas. The ulcers healed but plaques developed on both eyes which progressed, during the course of one year, to cover both the left and the right corneas. Due to the animal's loss of sight and its painful condition, bilateral enucleation was performed with submission of the eyes for histopathology. **Results.** Microscopic examination revealed bilateral pyogranulomatous keratitis absent of etiological organisms. **Conclusions.** To the authors' knowledge, this is the first documented case of bilateral sterile pyogranulomatous keratitis in a dog.

1. Introduction

Pyogranulomatous inflammation is a chronic inflammatory response of both macrophages and neutrophils which can result from a variety of causes, including failure of the acute inflammatory response, unique biochemical characteristics (foreign material), and/or virulence factors in infectious agents such as *B. dermatitidis*, *Nocardia*, *Mycobacterium spp.*, or *Leishmania*. Generally, this inflammation is induced by an exogenous agent which has entered the body, is recognized as foreign, and is subsequently surrounded and destroyed by reactive white blood cells. However, an etiologic agent is not always necessary, or found, to incite pyogranuloma formation. There are numerous cases of granulomatous or pyogranulomatous inflammation which are thought to be caused by immunoreactivity to an allergen or an autoantigen, including sperm granulomas, eosinophilic granuloma complex, and sterile pyogranuloma/granuloma syndrome (SPGS) [1–3]. In the eye, nodular granulomatous episcleritis (NGE) and necrotic scleritis are two conditions which are known to induce histiocytic to granulomatous inflammation in the absence of an etiologic agent [4, 5]. However, these conditions are primarily restricted to the sclera of domestic animals.

Here, we present the clinicopathologic characteristics of a 16-year-old spayed female rat terrier with a history of bilateral

corneal plaques. Following therapeutic failure and progression of the plaques, bilateral enucleation and histopathology revealed the lesions to consist of sterile pyogranulomatous nodules which were restricted to the cornea. To the authors' knowledge, this is the first reported case of bilateral sterile pyogranulomatous keratitis in a dog.

2. Case Presentation

A 16-year-old spayed female rat terrier that had never traveled out of the state of Iowa presented to the Humboldt Veterinary Clinic in June of 2017 for squinting of the right eye (OD). There was neovascularization and congestion of the sclera OD and fluorescein stain identified two small corneal ulcers in the right (1 mm) and left (1.5 mm) eyes. Intraocular pressure was 10 mmHg OD and 9 mmHg on the left eye (OS). Topical gentocin drops were started at that time.

The dog represented four months later, in October of 2017, for continued squinting. Body temperature (99.5°F) and intraocular pressure were still normal, OD 16 mmHg and OS 19 mmHg. The corneal ulcers were no longer present, but the sclera still showed neovascularization and congestion of vessels. Gentocin eye drops were continued and oral nonsteroidal anti-inflammatories (NSAIDs), carprofen, were

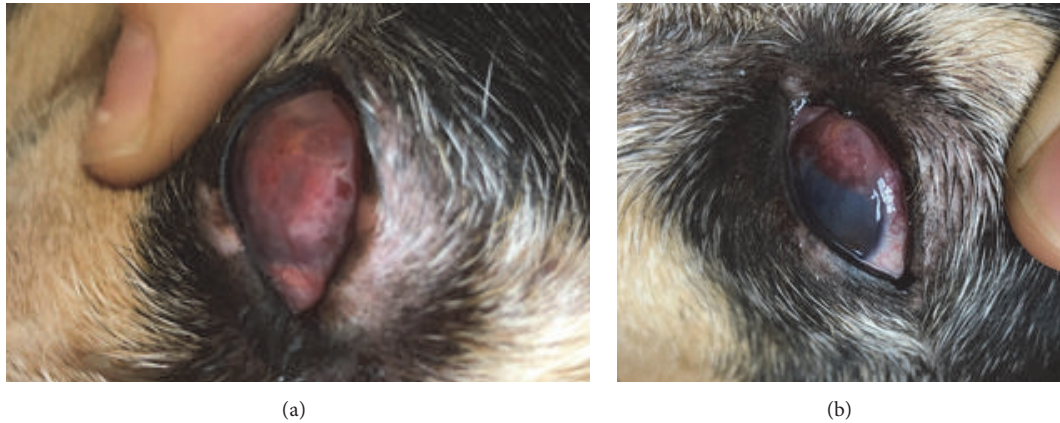


FIGURE 1: Canine-photographs of progressive plaques over the right (a) and left (b) corneas.

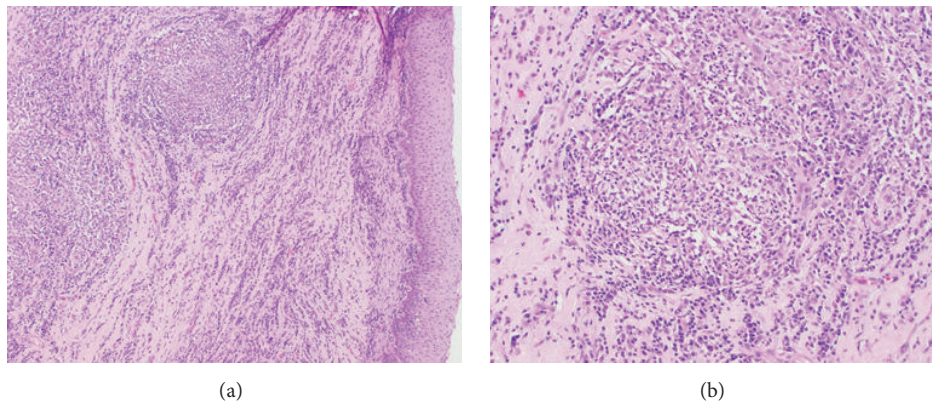


FIGURE 2: (a) Anterior cornea of the right eye (100X, H&E stain): surface epithelium is markedly hyperplastic with expansion of underlying stroma by small caliber vessels and multifocal pyogranulomatous nodules surrounded by infiltrates of lymphocytes and plasma cells. (b) Anterior cornea of the right eye (200X, H&E stain): higher magnification of previously described lesion highlighting pyogranulomatous inflammation.

started. At recheck, two weeks later, the sclera of the right eye was still inflamed so a neomycin and polymyxin B sulfates with dexamethasone (.1%) eye drop were added to the treatment regimen OD.

The dog was scheduled to be rechecked in two weeks but only presented seven weeks later, exhibiting bilateral white to red corneal plaques. The right cornea was completely covered (Figure 1(a)) while only 1/3 of the left cornea was effaced (Figure 1(b)). Differentials for the plaques included neoplasia, fungal, protozoal, or bacterial infection, or autoimmune keratitis. To rule out cultivable infectious agents, both corneas were anesthetized, the corneal plaques were gently debrided, and culture swabs of both corneas were taken for bacterial and fungal culture. Neither culture resulted in any growth. The dog was prescribed erythromycin eye drops for both eyes and continued on the oral NSAID.

The animal was rechecked five days later. Complete blood cell count (CBC) and blood chemistry (chem) were performed. The CBC showed a leukopenia, $5.06 \times 10^9/L$ (normal = $6 - 17 \times 10^9/L$) and mild lymphopenia, $0.89 \times 10^9/L$ (normal = $1 - 4.8 \times 10^9/L$). The only significant finding in the blood chemistry was a high blood urea nitrogen (BUN) 48 mg/dL

(normal = $7 - 27$ mg/dL); though, creatinine was normal. Prednisolone drops (1%) were prescribed for the eyes, as well as oral tramadol at a dose of 3.125 mg/kg every eight hours for pain management.

After five months of prednisolone therapy, the corneal plaques had continued to progress resulting in blindness in both eyes. As a result of this, the owners elected for bilateral enucleation. Following surgery, both eyes were submitted for histopathologic evaluation to the Surgical Pathology Service of the Department of Veterinary Pathology, Iowa State. A follow-up CBC/chem showed no abnormal findings in the CBC, while the serum chemistry panel revealed the abnormally high BUN, 47 mg/dL (normal = $7-27$ mg/dL), with normal creatinine similar to previous results.

Histopathologic evaluation of both eyes revealed markedly expanded corneas due to pronounced hyperplasia of the surface epithelium, along with neovascularization, fibrosis of the stroma, and a marked infiltrate of numerous distinct pyogranulomas surrounded by a diffuse infiltrate of lymphocytes and plasma cells (Figure 2(a)). The pyogranulomas were characterized by a peripheral zone of epithelioid macrophages, fewer lymphocytes and plasma

cells, and a central zone of polymorphonuclear cells (Figure 2(b)). Descemet's membrane was intact but there was a layer of plasma cells and lymphocytes subjacent to the endothelium. There was a moderate perivascular infiltrate of lymphocytes and plasma cells in the iris. Also, there was a substantial infiltrate of lymphocytes and plasma cells in the bulbar conjunctiva and around the scleral vessels at the limbus. Posterior segments of the eyes were unremarkable. There was no evidence of neoplasia.

Special stains were ordered to highlight potential infectious organisms within the pyogranulomas. However, no agents were identified with Haematoxylin and Eosin (H&E), periodic acid Schiff (PAS), Grocott's methenamine silver (GMS), Giemsa, Gram and acid-fast stains. The animal responded well to the bilateral enucleation and is doing great post-op.

3. Discussion

Previous reported cases of pyogranulomatous keratitis in the dog identified several protozoal organisms (ex. *Toxoplasma gondii* and *Leishmania*) as well as *Acanthamoeba* as causative agents with visualization of organisms followed by confirmatory ancillary testing [6–8]. The Beckwith-Cohen et al. protozoal keratitis cases were all identified in dogs that had received long term, topical or systemic, immunosuppressive therapy for keratoconjunctivitis sicca before masses were noted to be progressing over the corneas. In the presented case, the lesions started progressing prior to steroid treatment and continued in spite of prescribed therapy. In fact, the left eye had not received treatment of any kind prior to its development of plaques. Had the animal been infected with a protozoan, *Toxoplasma* or *Acanthamoeba* organisms likely would have been visible in one of our many sections or stains. While *Leishmania* would be more difficult to identify with histopathology, the dog has never left the state of Iowa and lives in a nonendemic area [9]. Furthermore, Giemsa stains, which have previously been shown to highlight *Leishmania* organisms in histopathology sections, were negative for amastigotes [10].

It is important to note that, while there was extensive pyogranulomatous inflammation in the cornea, there were also substantial populations of lymphocytes and plasma cells throughout the cornea with more mild aggregates in adjacent conjunctiva, iris, and subjacent to Descemet's membrane. This lymphoplasmacytic infiltrate was often peripheral to pyogranulomatous inflammation and could have developed in response to a number of stimuli including cytokines released from reactive macrophages, damaged keratocytes, or corneal epithelium [11, 12]. However, the lymphocytes may also be the primary reactors as can be seen in autoimmune disease and are thus responsible for pulling in additional inflammatory cells, or they may be regulatory T cells attempting to mitigate inflammation [13]. An incomplete understanding of the relationship between canine T cell coreceptor phenotype and autoimmune function/importance makes further investigation of the described lymphocytic populations difficult and likely unrewarding.

The seemingly sterile nature of these lesions would suggest that this animal developed an immune response against one of the components of the corneal stroma. This is strongly supported by the absence of pyogranulomatous inflammation in any structure of the eye besides the cornea. In general, autoimmune keratitis is rare, as the cornea is an immune privileged site [14]. Under homeostatic conditions there are numerous factors, such as anterior chamber-associated immune deviation (ACAID), that prevent naïve effector lymphocytes from responding to antigens which are normally expressed there [15, 16]. However, following injury to the eye and subsequent inflammation, this immune privilege can break down and result in an autoimmune response to proteins normally found in the anterior chamber or cornea. The result, in humans, is a sometimes markedly delayed T cell-mediated granulomatous inflammatory response of the uvea in both the injured eye (known as the exciting eye) and the uninjured contralateral eye (known as the sympathetic eye) [17]. This is known as sympathetic ophthalmia and while there are numerous publications on this phenomenon in humans, this autoimmune disease has never been described in a companion animal species [18].

Nodular granulomatous episcleritis (NGE) and necrotizing scleritis are two idiopathic inflammatory conditions of the eye characterized by numerous infiltrates of histiocytes and lymphocytes. Classically, these lesions are primarily confined to the sclera [19]. However, recent work has presented three cases of corneocentric variants of NGE [20]. It is important to note that the microscopic features of corneocentric NGE do not fit the described microscopic findings of this case. In necrotizing scleritis, lesions consist of coalescing granulomas centered on remnants of collagen with peripheral infiltrates of lymphocytes. This presentation is similar to the described case; though, we observed a large neutrophilic component to the inflammatory infiltrate and an absence of necrotic collagen within the center of granulomas. While it is possible that the presented case is a corneocentric variant of necrotizing scleritis, the disparity in microscopic characteristics warrants caution and likely requires the description of additional cases with similar features before this can be termed a true variant. As a result of this, the presented case is, to the authors' knowledge, the first reported example of bilateral pyogranulomatous keratitis in a dog without infectious stimulus or foreign substance.

Conflicts of Interest

The authors declare that they have no conflicts of interest.

References

- [1] A. M. Aguirre, P. G. Fernandez, and M. S. Muela, "Sperm granuloma in the dog: complication of vasectomy," *Journal of Small Animal Practice*, vol. 37, no. 8, pp. 392-393, 1996.
- [2] P. B. Bloom, "Canine and feline eosinophilic skin diseases," *Veterinary Clinics of North America: Small Animal Practice*, vol. 36, no. 1, pp. 141-160, 2006.
- [3] S. Kawai, S. Matsuura, S. Yamamoto et al., "A case of cutaneous sterile pyogranuloma/granuloma syndrome in a maltese,"

- Journal of the American Animal Hospital Association*, vol. 50, no. 4, pp. 278–283, 2014.
- [4] C. B. Breaux, L. S. Sandmeyer, and B. H. Grahn, “Immunohistochemical investigation of canine episcleritis,” *Veterinary Ophthalmology*, vol. 10, no. 3, pp. 168–172, 2007.
- [5] B. H. Grahn, C. L. Cullen, and J. Wolfer, “Diagnostic ophthalmology. necrotic scleritis and uveitis,” *The Canadian veterinary journal. La revue vétérinaire canadienne*, vol. 40, no. 9, pp. 679–680, 1999.
- [6] B. Beckwith-Cohen, D. J. Gasper, E. Bentley et al., “Protozoal infections of the cornea and conjunctiva in dogs associated with chronic ocular surface disease and topical immunosuppression,” *Veterinary Ophthalmology*, vol. 19, no. 3, pp. 206–213, 2016.
- [7] M. Valladares, M. Reyes-Batlle, C. M. Martín-Navarro et al., “Molecular characterization of acanthamoeba strains isolated from domestic dogs in tenerife, Canary Islands, Spain,” *Archives of Microbiology*, vol. 197, no. 5, article 1096, pp. 639–643, 2015.
- [8] J. C. Freitas, D. C. Nunes-Pinheiro, B. E. Lopes Neto et al., “Clinical and laboratory alterations in dogs naturally infected by *Leishmania chagasi*,” *Revista da Sociedade Brasileira de Medicina Tropical*, vol. 45, no. 1, pp. 24–29, 2012.
- [9] D. M. Pigott, S. Bhatt, N. Golding, K. A. Duda, K. E. Battle, and O. J. Brady, “Global distribution maps of the leishmaniasis,” *Elife*, vol. 3, 2014.
- [10] K. Laurent, J. Susong, E. Fillman, and S. Ritchie, “Cutaneous leishmaniasis in a saudi arabian soldier stationed in the united states,” *Military Medicine*, vol. 182, no. 7, pp. e1953–e1956, 2017.
- [11] S. K. Lee, B. K. Choi, W. J. Kang et al., “MCP-1 derived from stromal keratocyte induces corneal infiltration of CD4+ T cells in herpetic stromal keratitis,” *Molecules and Cells*, vol. 26, no. 1, pp. 67–73, 2008.
- [12] J. Shirane, T. Nakayama, D. Nagakubo et al., “Corneal epithelial cells and stromal keratocytes efficiently produce CC chemokine-ligand 20 (CCL20) and attract cells expressing its receptor CCR6 in mouse herpetic stromal keratitis,” *Current Eye Research*, vol. 28, no. 5, pp. 297–306, 2004.
- [13] Y. Huang, Z. Yang, C. Huang et al., “ $\gamma\delta$ T cell-dependent regulatory T cells prevent the development of autoimmune keratitis,” *The Journal of Immunology*, vol. 195, no. 12, pp. 5572–5581, 2015.
- [14] P. B. Medawar, “Immunity to homologous grafted skin; the fate of skin homografts transplanted to the brain, to subcutaneous tissue, and to the anterior chamber of the eye,” *British Journal of Experimental Pathology*, vol. 29, no. 1, pp. 58–69, 1948.
- [15] O. Treacy, G. Fahy, T. Ritter, and L. O’Flynn, “Corneal immunosuppressive mechanisms, anterior chamber-associated immune deviation (ACAID) and their role in allograft rejection,” *Methods in Molecular Biology*, vol. 1371, pp. 205–214, 2016.
- [16] J. Y. Niederkorn and J. Mellon, “Anterior chamber-associated immune deviation promotes corneal allograft survival,” *Investigative Ophthalmology & Visual Science*, vol. 37, no. 13, pp. 2700–2707, 1996.
- [17] N. Chaithanyaa, S. K. Devireddy, R. Kishore Kumar, R. S. Gali, and V. Aneja, “Sympathetic ophthalmia: a review of literature,” *Oral Surgery, Oral Medicine, Oral Pathology, Oral Radiology, and Endodontology*, vol. 113, no. 2, pp. 172–176, 2012.
- [18] Y. Wang and C.-C. Chan, “Gender differences in vogt-koyanagi-harada disease and sympathetic ophthalmia,” *Journal of Ophthalmology*, vol. 2014, Article ID 157803, 8 pages, 2014.
- [19] N. Denk, L. S. Sandmeyer, C. C. Lim, B. S. Bauer, and B. H. Grahn, “A retrospective study of the clinical, histological, and immunohistochemical manifestations of 5 dogs originally diagnosed histologically as necrotizing scleritis,” *Veterinary Ophthalmology*, vol. 15, no. 2, pp. 102–109, 2012.
- [20] N. Hamzianpour, C. Heinrich, R. G. Jones, P. McElroy, N. Wilson, and E. Scurrall, “Clinical and pathological findings in three dogs with a corneocentric presentation of nodular granulomatous episcleritis,” *Veterinary Ophthalmology*, 2019.