

# Stereological comparison of intraprostatic injection of alcohol and bleomycin with finasteride gavages in rats

Ali Eslahi<sup>1</sup>, Ali Noorafshan<sup>2</sup>, Ali-Reza Safarpour<sup>3</sup>, Masood Sepehrimanesh<sup>4</sup>, Ali Ariafara<sup>1</sup>, Elham Nadimi<sup>4</sup>

<sup>1</sup>Department of Urology, Shiraz University of Medical Sciences, Shiraz, Iran

<sup>2</sup>Histomorphometry and Stereology Research Center, Shiraz University of Medical Sciences, Shiraz, Iran

<sup>3</sup>Gastroenterohepatology Research Center, Shiraz University of Medical Sciences, Shiraz, Iran

<sup>4</sup>Histomorphometry and Stereology Research Center, Shiraz University of Medical Sciences, Shiraz, Iran

**Citation:** Eslahi A, Noorafshan A, Safarpour A-R, Sepehrimanesh M, Ariafara A, Nadimi E. Stereological comparison of intraprostatic injection of alcohol and bleomycin with finasteride gavages in rats. Cent European J Urol. 2017; 70: 163-169.

## Article history

Submitted: Dec. 26, 2016

Accepted: April 10, 2017

Published online: April 13, 2017

## Corresponding author

Ali Noorafshan  
Shiraz University  
of Medical Sciences  
Histomorphometry  
and Stereology  
Research Center  
71348-45794 Shiraz, Iran  
phone: 987112304372 ext. 0  
noora@sums.ac.ir

**Introduction** Resection of the prostate is one of the standard surgical treatments for symptomatic Benign Prostatic Hyperplasia (BPH). To evaluate minimally invasive treatments, intraprostatic injections of ethanol and bleomycin were compared with oral finasteride administration in rats with BPH.

**Material and methods** The rats were divided into six groups. The control rats received no BPH/no treatment. BPH was induced using injections of testosterone (2 mg/day/rat for 4 weeks) in groups II–VI. After 4 weeks, Group II received no treatment while Group III received oral finasteride (10 mg/kg/day). Moreover, Groups IV–VI received a single injection of ethanol (95%), bleomycin (5 mg/kg) and normal saline 25 mm<sup>3</sup> in each ventral lobe of the prostate respectively. Two weeks after the injections, the ventral lobes underwent a quantitative stereological study.

**Results** The volume of the ventral lobes, glandular epithelium, fibromuscular tissue and microvessels increased by 1.7, 3.1, 2.4 and 1.6 times in BPH rats respectively (P < 0.01). Alcohol or bleomycin injection in BPH rats induced drastic recession of the increased volume of the ventral lobe, glandular epithelium and fibromuscular tissue (P < 0.01). Regarding the BPH+alcohol group, the glandular epithelium volume restored to the normal values of the control rats (P < 0.01). BPH+finasteride also incited an atrophic change in the volume of the whole prostate and glandular epithelium, but not the fibromuscular tissue and microvessels (P < 0.01).

**Conclusions** Injection of alcohol and bleomycin (approximately 10% of the volume of ventral prostatic) as well as consuming finasteride can induce a reduction of 1/3, 1/4 and 1/5 in the hypertrophied gland respectively.

**Key Words:** ethanol ↔ finasteride ↔ bleomycin ↔ prostatic hypertrophy ↔ stereology ↔ rats

## INTRODUCTION

Benign Prostatic Hyperplasia (BPH) is a common urologic disorder, which mostly affects elderly men [1]. This disorder can affect approximately 50% of men aged between 51 and 60 and also more than 70% of those over 70 years old [2, 3]. The two major impacts of BPH are the proliferations of smooth muscle and epithelial cells located in the prostate, which cause the urinary tract to narrow. While the BPH

etiology is arguable, testosterone and dihydrotestosterone are widely known to be related to the development of BPH [4].

Among the several treatments available for this disorder are the medical and surgical ones. Finasteride administration is one of the most prevalent treatments for BPH. Finasteride is a type of steroid reductase inhibitor which causes a certain amount of decrease in the hormone dihydrotestosterone in the body. This induces the prostate gland to get

smaller, which in turn helps relieve urinary problems. In addition to medical approaches, surgical treatments such as transurethral resection of the prostate, which is considered to be the standard method [5], laser therapy [6], open prostatectomy and other minimally invasive procedures are available [7]. The difficulties associated with these approaches are two-fold. Not only can some patients not tolerate surgery, but also all of these treatments involve other concerns such as high expense, orthostatic hypotension, ejaculation changes, headaches and nasal congestion [8].

One of the less invasive treatment methods of BPH is injection therapy. This involves the application of a variety of chemical compounds, including alcohol [95%], Lugol's solution, 5–10% of silver nitrate, and sodium hydroxide (10%), carbolic acid, glacial acetic acid, glycerin [9]. The majority of these compounds are reported to provoke some level of inflammatory reactions which ultimately lead to local coagulative necrosis [9]. Consequently, the prostate volume would reduce and this would result in different degrees of urethral syndrome relief. Previously, numerous cases have confirmed the safety and efficacy of ethanol and provide support for its application in BPH [9]. In an attempt to introduce other injectable agents, this study was conducted to compare bleomycin with ethanol injection and finasteride therapy. Bleomycin is a medication used to treat cases of cancer such as lymphomas, testicular and ovarian cancer. In order to remove cancer cells, bleomycin stimulates DNA strand breaks and also takes parts in lipid peroxidation and oxidation of other cellular molecules. Bleomycin has certain applications in dermatology and has been applied to treat various benign skin conditions including warts, hemangiomas, vascular malformations, telangiectasias as well as several types of cutaneous malignancies, condyloma acuminata, and the lesions of leishmaniasis cutis [10]. However, there have been few studies on its application in BPH treatment using a prostatic injection. Therefore, the aim of the present study was to evaluate and compare the effects of intraprostatic injection of ethanol 96%, bleomycin and oral administration of finasteride and the subsequent stereological changes in prostate tissue. Stereological methods can bring about quantitative, reliable and comparable data. This study aimed to answer the following questions:

- How much of the volume of the prostate and its components (glandular epithelium, fibromuscular tissue and microvessels) would increase after testosterone administration?
- Can intraprostatic injection of ethanol 96% reverse the increments of the prostatic structures in BPH rats? If so, by how much?

- Can the intraprostatic injection of bleomycin revert the growth of the prostatic structures in BPH animals? If so, by how much?
- Can the oral finasteride administration reverse the enhancement of the prostatic structures in BPH rats? If so, by how much?

## MATERIAL AND METHODS

### Animals and interventions

In this study, we opted for a rat model consisting of thirty Sprague-Dawley rats with an average weight of 300 +/-50g, which were obtained from The Center of Comparative and Experimental Medicine of the University. The animal experiments were allowed and approved by the Vice Chancellor of the University. The rats were then randomly assigned to six equal groups ( $n = 5$ ). Group I (control) consisted of normal rats which had neither BPH nor treatment. BPH was induced using intramuscular injection of testosterone (2 mg/day) for 4 consecutive weeks in group II–VI. Group II received no further treatments. Through gavage feeding, Group III also received 10 mg/kg/day finasteride for two weeks. Group IV–VI received ethanol (95%), bleomycin (5 mg/kg) and distilled water using direct injection to the ventral lobes of the prostate, respectively. The last three injections were single injections and performed at the end of the 4<sup>th</sup> week. To perform the direct injection, the animal received Ketamine (70–100 ml/kg) and xylazine (6–10 ml/kg) intramuscularly to induce anesthesia. After the lower abdominal area was sectioned, the bladder was identified and the ventral prostate lobes were found at the base of bladder. Afterwards, ethanol, bleomycin and normal saline (25 mm<sup>3</sup>) were injected in the ventral lobe of prostate. This amount was 1/10 of the average volume of each ventral lobe of prostate (250 mm<sup>3</sup>), which was estimated in a pilot study. Then the surgical site was sutured using nylon 5/0 and the animals were returned to their corresponding cages for recovery. Two weeks after injections, all animals were scarified under deep anesthesia with ketamine and xylazine and this was followed by the extraction of ventral lobes of prostate tissue. The weight and the volume of ventral lobes were measured and then the tissue was fixed in buffered formalin for future stereological evaluations.

### Stereological study

The volume of the ventral lobes of prostate was estimated using the immersion method developed by Scherle [11]. Additionally, to estimate the volume

density of the gland's epithelium, fibromuscular tissue and vessels, the sampled sections were examined using a videomicroscopy system. Systematic random sections of the prostate were prepared and embedded in one paraffin block. Four micrometer sections were prepared and stained with Heidenhain's AZAN trichrome stain. The field of view in each section was subsampled by systematic random sampling using the microscope's stage vernier. The volume density of the structures was estimated at final magnification of 80x using the point-counting method and the following formula [11]:

$$V_v(\text{structure/prostate}) = P(\text{structure})/P(\text{prostate})$$

where 'P(structure)' indicates the number of points hitting the favored histological structures and P(prostate) is the number of points hitting the reference space, here whole prostatic sections. The absolute total volume of each structure was estimated by the volume density multiplied by the total volume of the prostate.

### Statistical methods

The data was analyzed using the Kruskal-Wallis and Mann-Whitney U tests. A value of  $P < 0.05$  was considered to be significant.

## RESULTS

### Quantitative evaluations

The results of quantitative evaluations are presented in Figure 1. Broadly speaking, The volume of the ventral lobes of prostate, glandular epithelium, fibromuscular tissue and microvessles increased by 1.7, 3.1, 2.4 and 1.6 times respectively in testosterone-treated rats (BPH) in comparison to the control rats ( $P < 0.01$ ). These findings indicate the hypertrophic effect of testosterone on the main histological structures of the prostate.

Injection of alcohol in the BPH rats brought about a devolution of the total volume of the ventral lobes, glandular epithelium and fibromuscular tissue as opposed to the BPH group ( $P < 0.01$ ). In other words, the volume of the ventral lobes and fibromuscular tissue decreased substantially and even glandular epithelium was restored to the normal values of the control rats. In contrast, the volume of the microvessels increased significantly in alcohol+BPH group (3.5 folds) as compared to both the control group and even the BPH ( $P < 0.01$ ). In short, injection of alcohol clearly recovered the hypertrophic change of the prostate.

The injection of bleomycin in the BPH rats caused an atrophic change in the volume of the ventral lobes of prostate, glandular epithelium and fibromuscular tissue. In contrast, however,

the volume of microvessels decreased significantly in the bleomycin group in comparison to the BPH group ( $P < 0.01$ ), hence its angioinhibitory effect. In addition, another interesting finding revealed by the comparison of alcohol and bleomycin was a significant difference in case of glandular epithelium. It indicated that alcohol had more potency to recover the increased volume of the epithelium in BPH rats.

The administration of finasteride in the BPH animals also incited an atrophic change in the prostate glandular epithelium as compared to the BPH group ( $P < 0.01$ ). However, the increment of fibromuscular tissue and vessels volume in BPH+finasteride rats did not revert in comparison with the BPH group.

### Qualitative evaluations

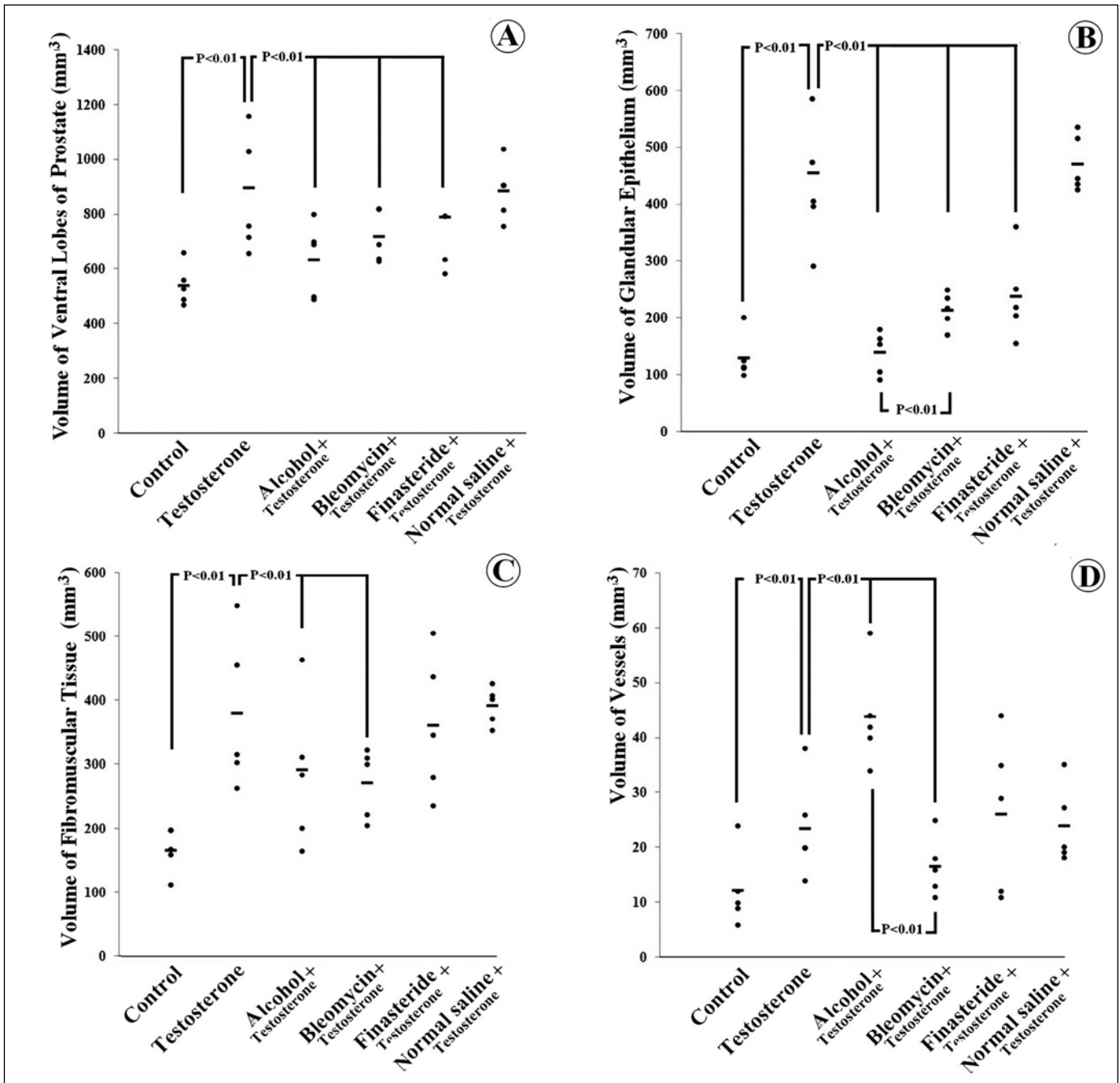
The results of microscopic and macroscopic qualitative evaluations are presented in Figures 2 and 3 respectively. Regarding the control rats, the glandular tissue along with their pseudostratified columnar epithelium of varying heights could be seen. The columnar cells contained apical secretory granules. Some basal cells could also be found between the columnar cells for regeneration of the epithelium. The glandular tissue was surrounded by connective tissue and smooth muscle (fibromuscular stroma).

As for the testosterone treated rats, the epithelial hyperplasia formed papillary projections in the glandular tissue. These papillary structures with their supporting stroma extended into the glandular lumen. In addition, nuclear crowding, occasional mitotic figures, piling up, and slight basophilia of the hyperplastic epithelium could be observed.

After applying ethanol and bleomycin in a case of experimental hypertrophy of the prostate, a coagulative necrotic tissue was observed which was generally lobular shaped. The necrotic tissue was associated with protein denaturation. Necrotic tissue could be seen even on the macroscopic scale.

## DISCUSSION

The present experimental study compared the intraprostatic injection of bleomycin (as a novel BPH treatment strategy) with intraprostatic injection of ethanol (95%) and oral administration of finasteride. The latter two methods were considered to be the classic medical treatments. While intraprostatic injection of different agents is considered a minimally invasive technique in lower urinary tract symptoms associated with benign prostatic hyperplasia, further studies on the efficacy of more

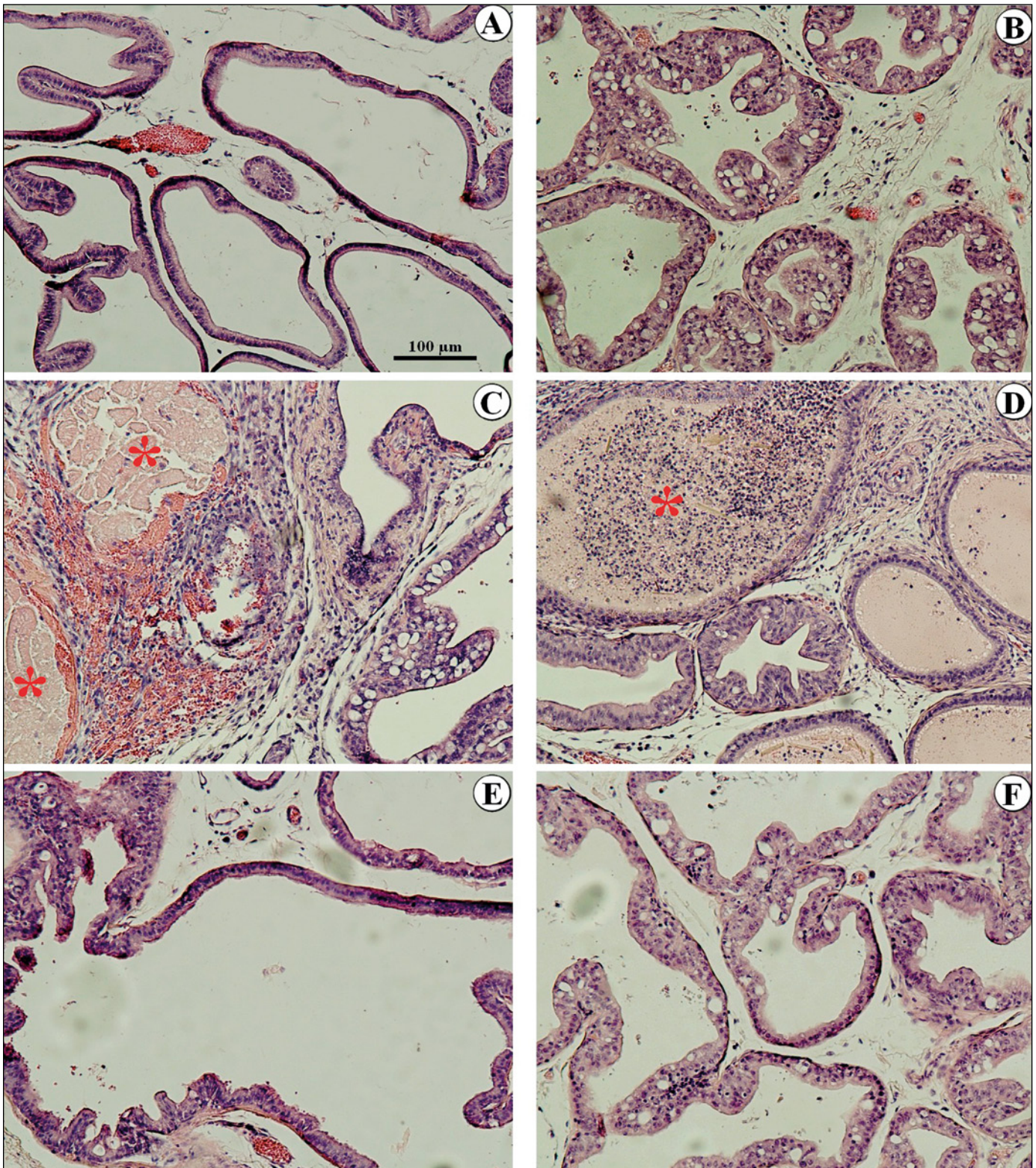


**Figure 1.** Dot of the parameters in prostate of the rats. The total volume of the prostate's ventral lobe (A), glandular epithelium (B), fibromuscular tissue (C) and vessels (D) of the rats in the control group, and the testosterone-treated rats co-treated with no treatment, alcohol, bleomycin, finasteride and normal saline. Each dot represents the estimated parameter in an animal. Horizontal bar indicates the mean in each group.

novel agents are needed [12]. Mechanical devices such as Urolift are also emerging for patients who desire to save their sexual function or cannot tolerate surgery [13]. Recently, there has been an increasing interest in novel agents for intraprostatic injection. Although alcohol has been one of the most widely used injectable agents so far, Botoli-

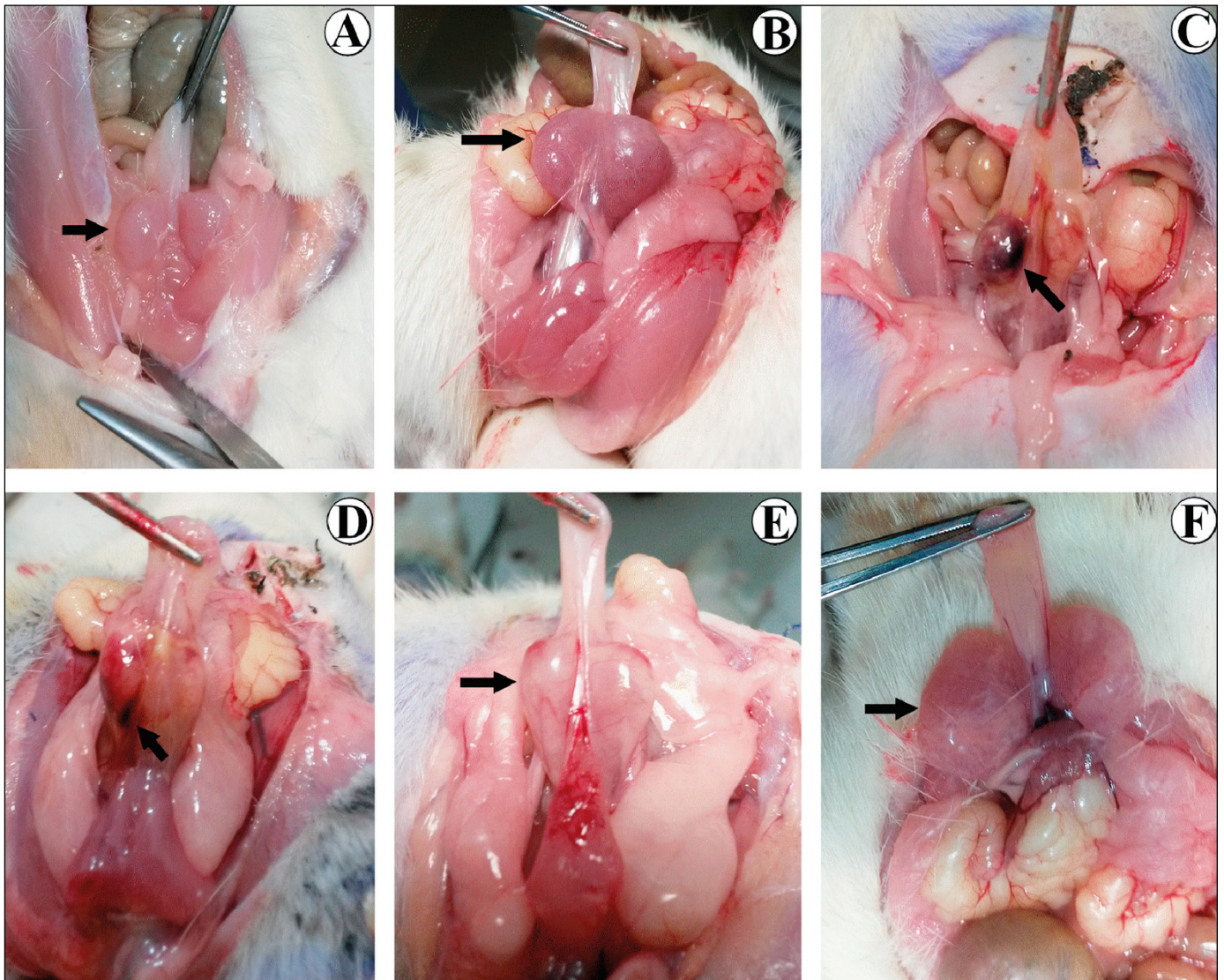
num toxin also showed efficacy in symptom relief of BPH patients. Other agents such as NX-1207 and PRX302 have also been reported to have promising effects [14]. The present research applied unbiased stereological methods to obtain quantitative results. As was expected, a single injection of ethanol could effectively decrease all the hypertrophied





**Figure 2.** Photomicrograph of the rat's prostate. **A.** Control group. The glandular tissue with their pseudostratified columnar epithelium, vessels and fibromuscular tissue surrounds the glands. No obvious structural change can be seen in the control group. **B.** In the testosterone treated rats, the epithelial hyperplasia formed the papillary projections in the glandular tissue can be seen. In addition, nuclear crowding and piling up could be observed. After ethanol (**C**) and bleomycin (**D**) injections in BPH rats, coagulative necrotic tissue associated with protein denaturation can be seen [asterisk]. **E.** Receiving finasteride ameliorated the prostatic changes due to BPH. **F.** No recovery were observed in the BPH animals treated with normal saline.





**Figure 3.** Photograph of the rat's ventral prostate. **A.** Control group. **B.** BPH, testosterone treated. **C.** BPH+ethanol. **D.** BPH+bleomycin. **E.** BPH+finasteride. **F.** BPH+normal saline. The arrows indicate the ventral lobe of prostate. In **C** and **D** the necrotic tissue can be seen.

structures except vessels. The results point to the likelihood of eliminating one third of prostatic volume in the PBH rats through injecting 10% of the average prostate volume of ethanol. Injection of the same amount of bleomycin could reduce the prostatic volume by 1/4. Despite this, there have been few studies on the detailed quantitative histological changes of the prostate after direct injection. Ethanol injection is an old concept which was first described in the early 1900s and since then it has attracted widespread interest [15]. Nonetheless, dehydrated ethanol injections have led to damages and extraprostatic leakages which in turn can result in grave consequences. Some of the common adverse effects of ethanol injection are dysuria, urinary retention, hematuria and rare cases of bladder necro-

sis [15]. Certain cases of ethanol injection have also been reported to cause complications such as liquefaction necrosis and urinary tract injury [15]. Therefore, this study introduced bleomycin as an alternative method. In the literature, there seems to be no reports about intraprostatic injection of bleomycin for the treatment of BPH, while there are several examples concerning other diseases. Direct intralesional injection of bleomycin for benign diseases such as hemangioma have been mentioned in the literature [16]. Additionally, it has been used in the treatment of orbital varicose veins as sclerotherapy [17]. Even in cases of abdominal simple cysts, in the kidneys and liver, for instance, bleomycin was used with hopeful results and a significant cyst volume reduction was reported [18].

In a survey that was published by Songaeng et al. [19], the authors retrospectively reviewed the experience in treating venous malformations using two sclerosing agents, ethanol 95% and bleomycin. In long term follow-up, they reported more positive results for the bleomycin treatment group [19]. According to their findings, not only did alcohol have a slightly higher success rate but also it required fewer therapy sessions. In addition, bleomycin had a lower complication rate and less swelling after surgery. They further claimed that bleomycin treatment might be better tolerated and is thus preferred over alcohol sclerotherapy [20]. Efficacy of bleomycin in reducing the size of lymphatic and venous malformation as well as fewer severe complications has given it priority over other sclerosing agents [21]. The present study is a preliminary animal experiment of the application of bleomycin and future work should be followed and completed in human research.

## CONCLUSIONS

Injection of alcohol and bleomycin as well as the treatment with finasteride while the volume of injection was approximately 10% of the ventral prostatic volume induced abolishment of 1/3, 1/4 and 1/5 of the gland respectively.

## CONFLICTS OF INTEREST

The authors declare no conflicts of interest.

## ACKNOWLEDGMENTS

The present research was supported financially by the Histomorphometry and Stereology Research Center, Shiraz University of Medical Sciences, Shiraz, Iran. The authors wish to thank Mr. Omid Koohi-Hosseini-abadi and Dr. Mahjoob Vahedi for their kind help in providing laboratory animals. We would also like to show our gratitude to Mr. Morteza Giti for sharing his pearls of wisdom with us and improving the use of English in this paper.

## References

- Udendi UK, Tchounwou PB. Oxidative stress in prostate hyperplasia and carcinogenesis. *J Exp Clin Cancer Res.* 2016; 35: 139.
- Chang RT, Kirby R, Challacombe BJ. Is there a link between BPH and prostate cancer? *Practitioner.* 2012; 256: 13-62.
- Kuiper JG, Bezemer ID, Driessen MT, Vasylyev A, Roehrborn CG, Penning-van Beest FJ, Herings RM. Rates of prostate surgery and acute urinary retention for benign prostatic hyperplasia in men treated with dutasteride or finasteride. *BMC Urol.* 2016; 16: 53.
- Choi HM, Jung Y, Park J, et al. Cinnamomi Cortex (*Cinnamomum verum*) Suppresses Testosterone-induced Benign Prostatic Hyperplasia by Regulating 5 $\alpha$ -reductase. *Sci Rep.* 2016; 6: 31906.
- Thiruchelvam N. Surgical therapy for benign prostatic hypertrophy/bladder outflow obstruction. *Indian J Urol.* 2014; 30: 202-207.
- Ruszat R, Seitz M, Wyler SF, et al. GreenLight laser vaporization of the prostate: single-center experience and long-term results after 500 procedures. *Eur Urol.* 2008; 54: 893-901.
- Pinheiro LC, Martins Pisco J. Treatment of benign prostatic hyperplasia. *Tech Vasc Interv Radiol.* 2012; 15: 256-260.
- Traish AM, Hassani J, Guay AT, Zitzmann M, Hansen ML. Adverse side effects of 5 $\alpha$ -reductase inhibitors therapy: persistent diminished libido and erectile dysfunction and depression in a subset of patients. *J Sex Med.* 2011; 8: 872-884.
- Saemi AM, Folsom JB, Plante MK. Injection therapy for prostatic disease: A renaissance concept. *Indian J Urol.* 2008; 24: 329-335.
- Saitta P, Krishnamurthy K, Brown LH. Bleomycin in dermatology: a review of intralesional applications. *Dermatol Surg.* 2008; 34: 1299-1313.
- Nyengaard JR. Stereologic methods and their application in kidney research. *J Am Soc Nephrol.* 1999; 10: 1100-1123.
- Andersson KE. Intraprostatic injections for lower urinary tract symptoms treatment. *Curr Opin Urol.* 2015; 25: 12-18.
- Chung A, Woo HH. What's truly minimally invasive in benign prostatic hyperplasia surgery? *Curr Opin Urol.* 2014; 24: 36-41.
- Andersson KE. Treatment of lower urinary tract symptoms: agents for intraprostatic injection. *Scand J Urol.* 2013; 47: 83-90.
- Li Y, Zhao Q, Dong L. Efficacy and safety of ultrasound-guided transrectal ethanol injection for the treatment of benign prostatic hyperplasia in patients with high-risk comorbidities: a long-term study at a single tertiary care institution. *Urology.* 2014; 83: 586-591.
- Omidvari S, Nezakatgoo N, Ahmadloo N, Mohammadianpanah M, Mosalaei A. Role of intralesional bleomycin in the treatment of complicated hemangiomas: prospective clinical study. *Dermatol Surg.* 2005; 31: 499-501.
- Vadlamudi V, Gemmete JJ, Chaudhary N, Pandey AS, Kahana A. Transvenous sclerotherapy of a large symptomatic orbital venous varix using a microcatheter balloon and bleomycin. *J Neurointerv Surg.* 2016; 8: e30.
- Souftas VD, Kosmidou M, Karanikas M, Souftas D, Menexes G, Prassopoulos P. Symptomatic abdominal simple cysts: is percutaneous sclerotherapy with hypertonic saline and bleomycin a treatment option? *Gastroenterol Res Pract.* 2015; 2015: 489363.
- Songsaeng D, Churojana A, Khumthong R, Mahiwan L. Comparative outcomes for sclerotherapy of head and neck venous vascular malformation between alcohol and bleomycin. *J Med Assoc Thai.* 2015; 98: 408-413.
- Spence J, Krings T, TerBrugge KG, Agid R. Percutaneous treatment of facial venous malformations: a matched comparison of alcohol and bleomycin sclerotherapy. *Head Neck.* 2011; 33: 125-130.
- Horbach SE, Rigter IM, Smitt JH, Reekers JA, Spuls PI, van der Horst CM. Intralesional Bleomycin Injections for Vascular Malformations: A Systematic Review and Meta-Analysis. *Plast Reconstr Surg.* 2016; 137: 244-256. ■