

# Magnetic Resonance Angiography-based Prediction of the Results of Balloon Test Occlusion

Noriaki FUKUHARA,<sup>1,2,3</sup> Wataro TSURUTA,<sup>3,4</sup> Hisayuki HOSOO,<sup>4</sup> Masayuki SATO,<sup>5</sup> Yuji MATSUMARU,<sup>5</sup> Mitsuo YAMAGUCHI-OKADA,<sup>1</sup> Masanori YOSHINO,<sup>3,6</sup> Takayuki HARA,<sup>3,7</sup> Shozo YAMADA,<sup>3,8</sup> and Hiroshi NISHIOKA<sup>1,3</sup>

<sup>1</sup>Department of Hypothalamic and Pituitary Surgery, Toranomon Hospital, Tokyo, Japan;

<sup>2</sup>Department of Comprehensive Pathology, Tokyo Medical and Dental University, Tokyo, Japan;

<sup>3</sup>Okinaka Memorial Institute for Medical Research, Tokyo, Japan;

<sup>4</sup>Department of Neuro-Endovascular Therapy, Toranomon Hospital, Tokyo, Japan;

<sup>5</sup>Division of Stroke, Department of Neurosurgery, Faculty of Medicine, University of Tsukuba, Tsukuba, Ibaraki, Japan;

<sup>6</sup>Department of Neurosurgery, Tokyo Metropolitan Police Hospital, Tokyo, Japan;

<sup>7</sup>Department of Neurosurgery, Toranomon Hospital, Tokyo, Japan;

<sup>8</sup>Department of Neurosurgery, Tokyo Neurological Center, Tokyo, Japan

## Abstract

Precautious balloon test occlusion (BTO) is sometimes performed in cases of high-risk intraoperative internal carotid artery injury. We investigated whether magnetic resonance angiography (MRA) findings could predict BTO results to thus avoid the use of precautionary BTO. This retrospective study, included 96 patients who underwent BTO, eight of whom underwent bilateral BTO. The relationship between the BTO results for 104 internal carotid arteries and the MRA findings obtained in 96 patients were retrospectively evaluated. On MRA, anterior cerebral artery (A1)–anterior communicating artery–A1 was defined as anterior collateral circulation (ACC), and posterior cerebral artery–posterior communicating artery was defined as posterior collateral circulation (PCC). BTO was tolerated in all 27 sides with thick ACC regardless of PCC thickness. In 31 of 44 cases with a thin ACC, the tested sides were BTO-tolerant (70.5%). Of these 44 tested sides, all five with a thick PCC were BTO-tolerant, but eight with a thin PCC and 31 with an invisible PCC showed results other than tolerance. Among cases with an invisible ACC, 10 of 33 tested sides were BTO-tolerant (30.3%). Among these 33 tested sides, outcomes other than tolerance were observed regardless of PCC thickness. Thick, thin, and invisible ACCs were assigned 3, 1, and 0 points, respectively; and thick, thin, and invisible PCCs were assigned 2, 1, and 0 points, respectively. A sum of 3 points in the ACC and PCC indicated that all sides were BTO-tolerant. In conclusion, a thick ACC or a thin ACC with a thick PCC indicates BTO-tolerance. The BTO prediction score is useful for predicting results of BTO.

Key words: balloon test occlusion, magnetic resonance angiography, skull base tumor, pituitary adenoma, giant cerebral aneurysm

## Introduction

Internal carotid artery (ICA) sacrifice is required to treat parts of giant or blister-like aneurysms. Balloon test occlusion (BTO) is the gold-standard test used to diagnose the risk of cerebral ischemia after ICA sacrifice.<sup>1–3</sup> BTO is performed not only for cases of

planned ICA sacrifice but also for cases with intraoperative ICA injury to confirm collateral flow.<sup>3,4</sup> Therefore, precautionary BTO is sometimes performed in high-risk cases of intraoperative ICA injury before surgery for invasive skull base tumors.<sup>5,6</sup> BTO is an invasive test with reported complication rates of 3.2–3.7% in large series.<sup>7,8</sup> Although other non-invasive tests can be used to predict the results of BTO, alternative non-invasive tests for BTO have not been reported. The aim of this study was to investigate whether magnetic resonance angiography (MRA) findings can predict the results of BTO.

Received April 10, 2019; Accepted June 28, 2019

Copyright© 2019 by The Japan Neurosurgical Society This work is licensed under a Creative Commons Attribution-NonCommercial-NoDerivatives International License.

## Materials and Methods

### Study design and patients

This retrospective study was approved by the Institutional Review Board of Toranomon Hospital (No. 1465). Between January 2011 and March 2017, 99 patients underwent BTO at Toranomon Hospital. However, three of these 99 patients were excluded because the ICA was still occluded by tumor invasion in one patient, one patient had moyamoya disease, and the BTO procedure was terminated due to ICA spasm in the remaining patient. Therefore, 96 cases were included in this study. In addition, eight patients underwent BTO of both ICAs. One patient underwent BTO and then subsequent ICA sacrifice under general anesthesia. However, this patient was included because the clinical results of BTO were obtained after ICA sacrifice.

Twenty-six men and 70 women were included, with an age range of 19–90 years (median 57 years). Of these patients, 62 underwent preoperative BTO for invasive pituitary adenomas, 20 underwent BTO for ICA aneurysms, nine underwent BTO for parasellar meningiomas, and five underwent BTO for parasellar tumors.

The relationship between the BTO results obtained in 104 ICAs and the MRA findings obtained in 96 patients were retrospectively evaluated.

### BTO procedure

Balloon test occlusion was performed using Allura Xper (Philips Healthcare, Best, The Netherlands) under local anesthesia without sedation. A 5-Fr sheath was placed in the right common femoral artery, and a 4-Fr sheath was placed in the right radial artery. Intravenous heparin was administered to maintain an activated clotting time greater than 250 s during the procedure. After diagnostic angiography of both the ICA and the unilateral vertebral artery, a 5-Fr guide catheter was placed into the ICA of the test occlusion. A balloon catheter (HyperForm 7 × 7 mm; ev3, Medtronic, Santa Rosa, CA, USA) was advanced through the guide catheter into the petrous portion of the tested ICA. After inflation of the balloon, complete occlusion was confirmed by angiography. The patient underwent a continuous neurologic evaluation throughout the examination. In the presence of a change in neurologic status, the balloon was immediately deflated, and the procedure was terminated. The ICA was occluded for up to 20 min or more. After ICA test occlusion, aortography was performed with a 4-Fr pigtail catheter to assess the venous phase delay between the occluded hemisphere and the contralateral hemisphere. About 30 mL of iodine contrast medium was injected at an

injection speed of 10 mL/s for aortography. Selective angiography of the ICA and external carotid artery of the opposite side, the common carotid artery of the tested side and the unilateral vertebral artery was performed after aortography in a subset of patients. Follow-up intracranial angiography through the guide catheter was performed after deflation of the balloon to rule out ischemic complications. Heparin was reversed using protamine sulfate before the sheath was withdrawn.

### Diagnostic criteria of BTO

Ischemic tolerance during BTO occlusion was evaluated through neurological symptoms and angiographic findings. Patients who exhibited any neurological symptoms (consciousness disturbance, focal neurological deficits) were diagnosed as BTO intolerant (intolerant group). In the absence of neurological symptoms during 20 min of BTO, patients with a delayed opacification of cortical veins (venous phase delay) of 2 s or greater on the tested side compared with that on the contralateral side were diagnosed as BTO intolerant (venous delay group). Patients who exhibited no neurologic symptoms during BTO and a venous phase delay <2 s on the tested side were diagnosed as BTO tolerant (tolerant group).

### Evaluation of MRA findings

Magnetic resonance angiographies were acquired using a 1.5-T MRI (1.5T MAGNETOM Symphony, Siemens Healthcare, Erlangen, Germany and 1.5T Excelart Vantage Power Plus, Toshiba Medical Systems, Tokyo, Japan) or a 3.0-T MRI (3.0T Ingenia, Philips Healthcare) system. MRAs were independently reviewed by a neurosurgeon (N Fukuhara) and a neurointerventionist (H Hosoo). A linear weighted  $\kappa$  coefficients were used to evaluate the inter-observer agreement for MRA. Statistical analysis was performed using IBM SPSS Statistics version 21.0 (IBM Corp., Armonk, NY, USA). The thicknesses of the bilateral anterior cerebral artery (A1) segments of the A1, the anterior communicating artery (ACOM), the posterior cerebral artery (P1) segment of the P1 of the tested side, and the posterior communicating artery (PCOM) of the tested side were independently evaluated on MRA. Each vessel was placed in one of three groups based on the narrowest part of each segment: thick (>1 mm on MRA), thin (<1 mm on MRA), and invisible. A1–ACOM–A1 was defined as the anterior collateral circulation (ACC), and P1–PCOM was defined as the posterior collateral circulation (PCC). The ACC and PCC were respectively defined as thick if all segments were thick, they were defined as thin if any segment of the ACC or PCC was thin and not invisible, and they were

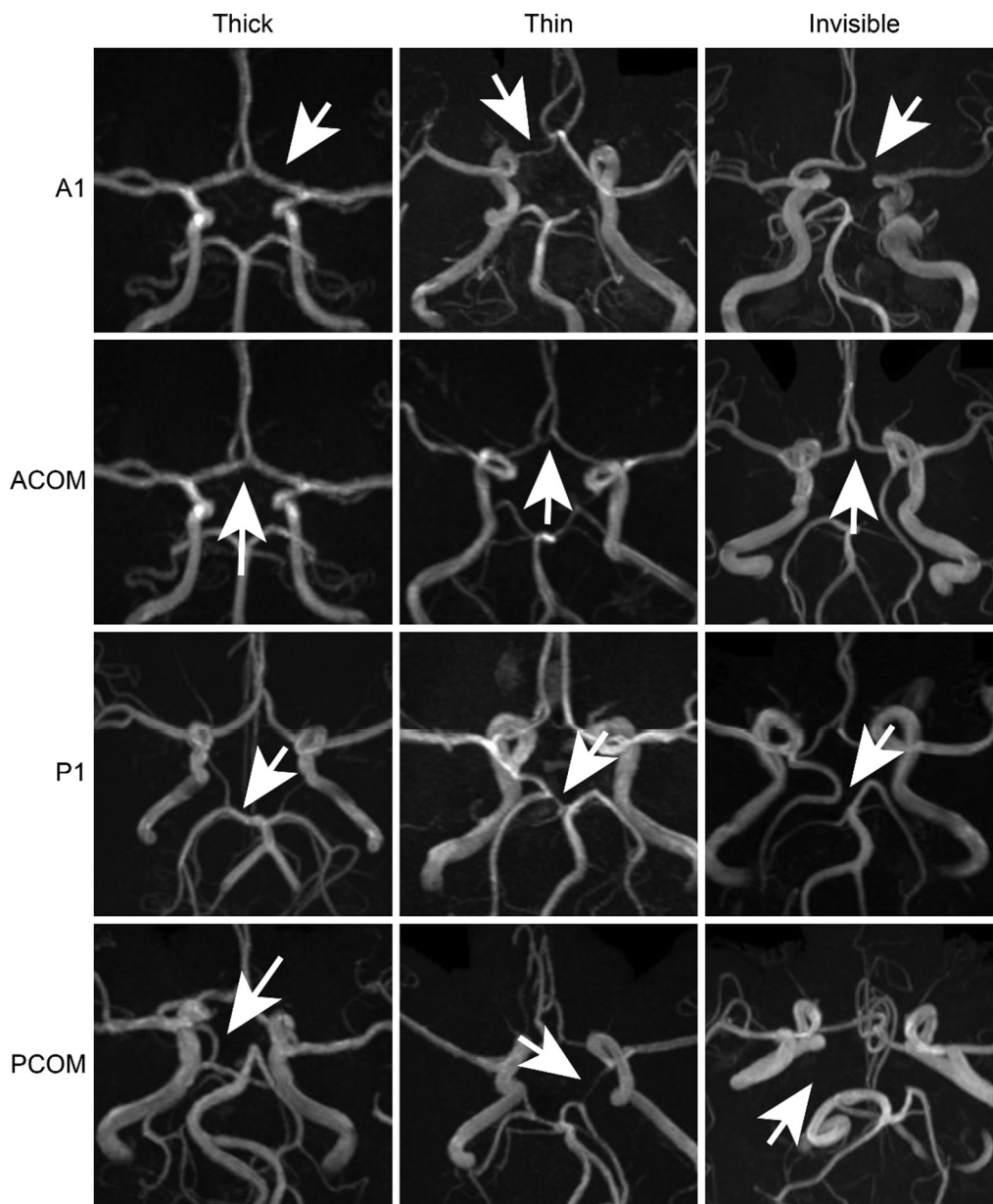
defined as invisible if any segment of the ACC or PCC was invisible (Fig. 1). A hypoplastic ICA or bilateral vertebral or basilar artery on MRA was not observed in any patient in this study.

## Results

### Correlations between BTO and MRA findings

The MRA findings of 96 patients were as follows: 84 patients (87.5%) had thick bilateral A1s, six

patients (6.3%) had a thick unilateral A1 and a thin contralateral A1, and six patients (6.3%) had a thick unilateral A1 but an invisible contralateral A1. The ACOM was thick in 35 patients (36.4%), thin in 36 patients (37.5%), and invisible in 25 patients (26.0%). These results defined the ACC as thick in 26 patients (27.1%), thin in 39 patients (40.6%), and invisible in 31 patients (32.3%). The PCC of 104 tested ICA sides was thick on 15 sides (14.4%), thin on 20 sides (19.2%), and invisible on 69 sides (66.3%).



**Fig. 1** Definitions of vessel thicknesses on magnetic resonance angiography. A1–ACOM–A1 was defined as the anterior collateral circulation. P1–PCOM was defined as the posterior collateral circulation. The collateral circulation was defined as thick if all segments were thick, thin if any segment was thin but not invisible, and invisible if any segment was invisible. A1: anterior cerebral artery, ACOM: anterior communicating artery, P1: posterior cerebral artery, PCOM: posterior communicating artery.

Inter-observer agreement between two readers was good ( $\kappa = 0.66$ , 95% CI: 0.58–0.75). BTO of 104 ICAs resulted in 68 ICAs (65.4%) that were tolerant, 19 (18.3%) that exhibited venous delay, and 17 (16.3%) that were intolerant. The results of MRA and BTO are shown in Table 1.

The results showed that all 27 sides that underwent BTO (26 patients) with thick ACC on MRA were tolerant regardless of the thickness of the PCC. Among cases with thin ACC on MRA, 31 of the 44 tested sides (39 patients) were tolerant (70.5%), seven exhibited venous delay (15.6%), and six were intolerant (11.4%). Of these 44 tested sides, all five tested sides (five patients) with a thick PCC on MRA were tolerant, but eight sides with thin PCC on MRA included patients showing venous delay, and 31 sides with invisible PCC on MRA constituted the remaining BTO-tested sides. Among cases with invisible ACC on MRA, 10 of the 33 tested sides (31 patients) were tolerant (30.3%), 12 exhibited venous delay (36.3%), and 11 were intolerant (33.3%). Of these 33 tested sides, six sides with thick PCC on MRA exhibited tolerance or venous delay, and four sides with thin PCC on MRA and 23 sides with invisible PCC on MRA constituted the remaining BTO-tested sides.

For the relationship between PCC and the results of BTO, the results were as follows. Among cases with thick PCC on MRA, 12 of the 15 tested sides were tolerant (80.0%), and three exhibited venous delay (20.0%). Among cases with thin PCC on MRA, 17 of the 20 tested sides were tolerant (85.0%), two exhibited venous delay (10.0%), and one was intolerant (5.0%). Among cases with invisible PCC on MRA, 39 of the 69 tested sides were tolerant (56.5%), 14 exhibited venous delay (20.3%), and 16

were intolerant (23.2%). These results indicated that it is impossible to predict the results of BTO using only the thickness of the PCC on MRA. However, the ratio of intolerant cases decreased in proportion to the thickness of the PCC on MRA.

### BTO prediction score

Based on these results, we proposed the new scoring system to predict the results of BTO from MRA findings. Thick, thin, and invisible ACC were assigned 3, 1, and 0 points, respectively, and thick, thin, and invisible PCC were assigned 2, 1, and 0 points, respectively. The sum of the points for the ACC and PCC represents the BTO prediction score. All 32 sides of BTO (30 patients) with >2 points were tolerant. Fourteen BTO-tested sides with 2 points (14 patients) included 10 patients in the BTO-tolerant group (71.4%) and four patients exhibiting venous delay (28.6%), but no intolerant patients. Thirty-five BTO-tested sides with 1 point (32 patients) included 21 patients in the BTO-tolerant group (60%), seven patients exhibiting venous delay (20%), and seven patients in the BTO-intolerant group (20%). Twenty-three sides tested with BTO with 0 point (22 patients) included five patients in the BTO-tolerant group (21.7%), eight patients exhibiting venous delay (34.8%), and 10 patients in the BTO-intolerant group (43.5%). The patient with a BTO prediction score >2 points did not require pre-cautious BTO, as all patients were regarded as tolerant. The patient with a BTO prediction score of <2 points was considered high risk because this group included intolerant cases. Summaries of the BTO results using this scoring system are shown in Tables 2 and 3.

**Table 1 Results summary of BTO of 104 ICAs and MRA findings**

MRA findings		BTO			Total
ACC	PCC	Tolerance	Venous delay	BTO intolerance	
Thick	Thick	4			4
	Thin	8			8
	Invisible	15			15
Thin	Thick	5			5
	Thin	7	1		8
	Invisible	19	6	6	31
Invisible	Thick	3	3		6
	Thin	2	1	1	4
	Invisible	5	8	10	23
Total		68 (66.3%)	19 (18.3%)	17 (16.3%)	104

The ACOM and A1 findings overlapped in eight cases because BTO was performed bilaterally in these patients. ACC: anterior collateral circulation, BTO: balloon test occlusion, MRA: magnetic resonance angiography, PCC: posterior collateral circulation.



**Table 2 Summary of the results of BTO using the BTO prediction score**

BTO prediction score	≥3	2	1	0
Tolerance (%)	100	71.4	60.0	21.7
Venous delay (%)		28.6	20.0	34.8
Intolerance (%)			20.0	43.5

All patients with >2 points were BTO tolerant; thus, preventative BTO can be omitted in this group. Patients with 2 points showed tolerance and venous delay, but they were not BTO intolerant. Patients with <2 points were BTO intolerant and represented the high-risk group. When the BTO prediction score is ≤2, the patient should undergo preventative BTO prior to undergoing surgery due to a high risk of ICA injury. BTO: balloon test occlusion, ICA: internal carotid artery.

**Table 3 Sensitivity, specificity, and accuracy of each BTO prediction score**

Cut-off	1	2	3
Sensitivity (%)	77.8	91.3	100
Specificity (%)	78.2	55.2	50
Accuracy (%)	77.9	71.2	65.4

The sensitivity, specificity, and accuracy to predict BTO tolerability for each BTO prediction score are set for the indicated cut-off values. Sensitivity is 100% when the cut-off of the BTO prediction score is ≥3 because all these patients tolerated BTO. BTO: balloon test occlusion.

### Selective angiography during BTO

During ICA balloon occlusion, selective angiography of the common carotid artery and the unilateral vertebral artery in addition to aortography was performed in 84 tested ICAs of 78 patients (six patients underwent bilateral selective angiography). BTO of these 84 ICA sides was tolerated in 65 sides of 63 patients, resulted in venous delay in 18 sides of 18 patients, and was intolerable in one side.

Cross-flow through the ACC was observed in all 27 sides tested with BTO (100%) with thick ACC on MRA, in 33 of 34 sides (97.1%) with thin ACC on MRA, and in 13 of 23 sides (56.5%) with invisible ACC on MRA. Cross-flow through the PCC was observed in all 15 sides tested with BTO (100%) with thick PCC on MRA, in 13 of 19 sides (68.4%) with thin PCC on MRA, and in 25 of 50 sides (50.0%) with invisible PCC on MRA. In addition, cross-flow through the ophthalmic artery was observed in 30 of 84 sides tested with BTO. Moreover, the main cross-flow was through the ophthalmic artery in one BTO-tested side in a patient with invisible ACC and invisible PCC on MRA. These results are summarized in Table 4.

### BTO of bilateral ICAs

Among the eight cases in which BTO was performed on the ICA of both sides, the results of bilateral BTO

**Table 4 Summary of the results of selective angiography during BTO**

			Cross-flow on selective angiography during BTO (%)
MRA findings	ACC	Thick	27/27 (100)
		Thin	33/34 (97.1)
		Invisible	13/23 (56.5)
	PCC	Thick	15/15 (100)
		Thin	13/19 (68.4)
		Invisible	25/50 (50.0)

When collateral circulation was thick on MRA, cross-flow on BTO was observed in all patients. Cross-flow on BTO was observed in approximately half of the patients without collateral circulation on MRA. ACC: anterior collateral circulation, BTO: balloon test occlusion, MRA: magnetic resonance angiography, PCC: posterior collateral circulation.

were the same in four cases (tolerated in three and venous delay in one). The main collateral flow of these patients was through the ACC. The results of bilateral BTO differed among the other four cases. The discrepancies in the results of bilateral BTO were due to differences in blood flow through the PCC. In particular, the MRA findings of both PCOMs were equal (undetectable) in two of these four cases, although the findings differed in the other two cases.

### ICA sacrifice cases

Eight patients underwent ICA sacrifice. Three of the four patients who were BTO-tolerant exhibited no neurological symptoms after ICA sacrifice (their BTO prediction scores were 1, 2 and 3); however, one patient who was BTO-tolerant underwent high-flow bypass after ICA sacrifice because the patient exhibited a decrease in cerebral blood flow on single photon emission computed tomography (SPECT) without a deterioration in neurological symptoms (the BTO prediction score was 1). The decrease in cerebral blood flow seemed to be caused by shower embolization that occurred during internal trapping of the ICA. Cross flow was sufficient during BTO performed in the same session. A final angiogram performed after trapping demonstrated delayed washout of contrast in the distal branches in the territory of the MCA. High-flow bypass was performed to prevent further ischemic complications. Two of three patients with venous delay in BTO (the BTO prediction scores were 0 and 1) and one patient who was BTO intolerant (the BTO prediction score was 1) underwent bypass when the ICA was sacrificed. However, one of three patients with venous delay in BTO (the BTO prediction score was 0) exhibited no neurological symptoms without bypass.

## Complications

No serious complications were observed in any cases of BTO. Transient hypotension after BTO was observed in three patients, and vomiting after BTO was observed in one patient. Arterial dissection treated with observation alone was observed in two patients upon diagnostic angiography immediately prior to BTO.

## Discussion

In skull base tumor or head and neck tumor surgeries involving the ICA, ICA sacrifice is sometimes required for gross total tumor resection or due to intraoperative ICA injury. In these high-risk cases, BTO is preoperatively performed to evaluate cerebral cross-flow. However, ICA sacrifice is not performed in all patients who preoperatively undergo BTO. In previous studies on preoperative BTO, BTO was performed for high-risk patients with ICA occlusion; however, the ICA was sacrificed in only a subset of the patients.<sup>6,9)</sup> In our institution, BTO is frequently performed, especially for invasive skull base tumors, although only 10% of patients undergo practical ICA sacrifice. The other 90% of patients undergo precautionary BTO when ICA sacrifice is emergently required. Nevertheless, omitting precautionary BTO is preferred if possible to avoid complications and to reduce costs. Most previous BTO studies have investigated the accuracy of BTO,<sup>10–13)</sup> although one study examined the correlation between the results of BTO and Matas/Allcock tests.<sup>14)</sup> No studies have reported a correlation between the results of BTO and MRA. MRA is a non-invasive test that is relatively inexpensive and widely available. Therefore, predicting the results of BTO by MRA would be very useful.

This study indicates that it is possible to omit precautionary BTO when MRA reveals thick ACC or thin ACC with thick PCC (BTO prediction score >2). However, other variations are associated with BTO intolerance or venous delay. Therefore, BTO should be performed for high-risk patients with ICA injury when MRA shows other variations, especially if both the ACC and PCC are invisible or if one is thin and the other is invisible (BTO prediction score <2) because it is difficult to predict the results of BTO. These results indicate that ACC cross-flow is important in the context of ICA occlusion. PCC cross-flow appears to be only supportive, as thick PCC was not always indicative of BTO tolerance. The thickness of the PCC is also related to ischemic tolerance during BTO because the intolerance rate increased in cases with thin or invisible PCC.

A good BTO prediction score indicates that the vessels of the ACC and PCC are thicker and that collateral cross-flow is richer. Low blood flow and angiostenosis

are known to be overestimated on MRA compared with angiography. Therefore, a thick vessel on MRA may indicate sufficient blood flow on angiography, which would be consistent with the judgment of a clinician, so this scoring system is easy to understand and apply in clinical practice. All cases with a BTO prediction score >2 showed tolerance on BTO, meaning that precautionary BTO can be avoided even in high-risk patients with ICA injury. Cases with a BTO prediction score <2 included BTO-intolerant patients, so this group includes patients with a high risk for ICA sacrifice. In addition, fewer tolerant patients and more intolerant patients were found to have BTO prediction scores of 0 rather than 1. Collateral cross-flow through the ACC or PCC was especially minimal in patients with invisible ACC and PCC on MRA. The patients with a BTO prediction score of 2 included patients exhibiting venous delay, but no intolerant patients. Whether precautionary BTO should be omitted in this group is controversial, as the absence of symptoms but the presence of venous delay on BTO does not always imply ischemic tolerance.

In this study, a venous phase delay >2 s without neurological symptoms was diagnosed as insufficient cross-flow. It was previously reported that a venous delay >2 s on BTO corresponded to a high risk of ischemic complications after ICA sacrifice, although BTO was performed under general anesthesia in this report.<sup>15)</sup> Although one of four patients in this study in the BTO-tolerant group exhibited decreased cerebral blood flow (CBF) on SPECT after practical ICA sacrifice, the decreased CBF was seemed to be caused by shower embolization that occurred during internal trapping of the ICA. Therefore, this does not deny the reliability of the diagnostic criteria of BTO. However, the criteria for venous phase delay vary among reports, and ischemic tolerance with ICA occlusion was not associated with venous phase delay in a recent report.<sup>12,16,17)</sup> It has been reported that SPECT, positron emission tomography (PET), electroencephalogram, and stump pressure were used in combination for evaluating ischemic tolerance in BTO.<sup>11–13,17–20)</sup> It is clear that a patient exhibiting neurological symptoms during BTO would not be tolerant to ischemia after ICA sacrifice. However, whether a patient with a venous phase delay on BTO will show ischemic tolerance remains controversial. Emergent ICA sacrifice is required if intraoperative ICA injury occurs. Patients with venous phase delay on BTO may have some risk of comprehensive cerebral ischemia immediately after ICA sacrifice, although no such symptoms were found during BTO. These ischemic complications can be caused by factors that are not evaluated during BTO, such as hypotension. Therefore, precautionary BTO could not

be avoided in our venous delay or tolerant group; however, one patient who exhibited venous delay on BTO had no neurological symptoms after ICA sacrifice was performed without bypass.

In some cases, cross-flow was confirmed on selective angiography even if vessels were invisible on MRA. Therefore, patients with an invisible ACOM and/or PCOM on MRA should not be diagnosed as BTO intolerant.

Four of the eight patients who underwent bilateral BTO exhibited consistent results on the left and right sides. The results mainly differ depending on blood flow from the PCOM. In addition, collateral flows through the ophthalmic artery or leptomeningeal anastomosis may also influence the differences in the results of bilateral BTO. Therefore, BTO should be performed for bilateral ICAs if necessary. It was not possible to predict the results of BTO based on the results of the opposite side.

A limitation of this study was the small number of patients for some variations of MRA findings. It is difficult to evaluate collateral flows through the ophthalmic artery or leptomeningeal anastomosis by MRA and to incorporate influences of these collateral flows into a BTO prediction score. In this study, the thickness of each vessel was categorized as one of three types. The vessel thickness was not defined by strict size because the MRI model (1.5 or 3.0T) or setting of each institute can affect the MRA findings and result in discrepancies. The interpretation of thickness is likely different for each physician. However, for application in actual clinical practice, using detailed definitions is difficult. Therefore, in this study, blood vessel thickness was simply divided into three categories. In addition, duplicate results were included for the eight patients who underwent bilateral BTO, although these patients constituted a small proportion of the entire patient sample. By increasing the number of patients, it may be possible to more clearly differentiate between cases that do or do not require BTO to avoid complications due to unnecessary BTO. Therefore, BTO should be omitted only for a certain group of patients who exhibit tolerance, as the ischemic complications of ICA sacrifice are severe. In addition, precautious BTO should only be performed when necessary, although the risk of serious complications with BTO was low in this study.

## Conclusion

Some MRA findings can predict the results of BTO in a subset of cases. Thick or thin ACC with thick PCC on MRA indicated tolerance of BTO. In these cases, BTO can be omitted. Our new "BTO prediction score" is useful for predicting the results of BTO.

## Conflicts of Interest Disclosure

The authors declare they have no conflicts of interest and no commercial relationships and received no support from pharmaceutical or other companies. All authors who are members of The Japan Neurosurgical Society (JNS) have completed the Self-reported COI Disclosure Statement Forms available at the website for JNS members.

## References

- 1) Rashad S, Hassan T, Aziz W, Marei A: Carotid artery occlusion for the treatment of symptomatic giant carotid aneurysms: a proposal of classification and surgical protocol. *Neurosurg Rev* 37: 501–511; discussion 511, 2014
- 2) Kim BC, Kwon OK, Oh CW, et al.: Endovascular internal carotid artery trapping for ruptured blood blister-like aneurysms: long-term results from a single centre. *Neuroradiology* 56: 211–217, 2014
- 3) Meling TR, Sorteberg A, Bakke SJ, Slettebø H, Hernesniemi J, Sorteberg W: Blood blister-like aneurysms of the internal carotid artery trunk causing subarachnoid hemorrhage: treatment and outcome. *J Neurosurg* 108: 662–671, 2008
- 4) Park YS, Jung JY, Ahn JY, Kim DJ, Kim SH: Emergency endovascular stent graft and coil placement for internal carotid artery injury during transphenoidal surgery. *Surg Neurol* 72: 741–746, 2009
- 5) Tamaki N, Nagashima T, Ehara K, Motooka Y, Barua KK: Surgical approaches and strategies for skull base chordomas. *Neurosurg Focus* 10: E9, 2001
- 6) Carpentier A, Blanquet A, George B: Suboccipital and cervical chordomas: radical resection with vertebral artery control. *Neurosurg Focus* 10: E4, 2001
- 7) Mathis JM, Barr JD, Jungreis CA, et al.: Temporary balloon test occlusion of the internal carotid artery: experience in 500 cases. *AJNR Am J Neuroradiol* 16: 749–754, 1995
- 8) Tarr RW, Jungreis CA, Horton JA, et al.: Complications of preoperative balloon test occlusion of the internal carotid arteries: experience in 300 cases. *Skull Base Surg* 1: 240–244, 1991
- 9) George B, Ferrario CA, Blanquet A, Kolb F: Cavernous sinus exenteration for invasive cranial base tumors. *Neurosurgery* 52: 772–780; discussion 780–782, 2003
- 10) Dare AO, Chaloupka JC, Putman CM, Fayad PB, Awad IA: Failure of the hypotensive provocative test during temporary balloon test occlusion of the internal carotid artery to predict delayed hemodynamic ischemia after therapeutic carotid occlusion. *Surg Neurol* 50: 147–155; discussion 155–156, 1998
- 11) Wang AY, Chen CC, Lai HY, Lee ST: Balloon test occlusion of the internal carotid artery with stump pressure ratio and venous phase delay technique. *J Stroke Cerebrovasc Dis* 22: e533–e540, 2013

- 12) Sato K, Shimizu H, Inoue T, et al.: Angiographic circulation time and cerebral blood flow during balloon test occlusion of the internal carotid artery. *J Cereb Blood Flow Metab* 34: 136–143, 2014
- 13) Tansavatdi K, Dublin AB, Donald PJ, Dahlin B: Combined balloon test occlusion and SPECT analysis for carotid sacrifice: angiographic predictors for success or failure? *J Neurol Surg B Skull Base* 76: 249–251, 2015
- 14) Kikuchi K, Yoshiura T, Hiwatashi A, Togao O, Yamashita K, Honda H: Balloon test occlusion of internal carotid artery: angiographic findings predictive of results. *World J Radiol* 6: 619–624, 2014
- 15) Abud DG, Spelle L, Piotin M, Mounayer C, Vanzin JR, Moret J: Venous phase timing during balloon test occlusion as a criterion for permanent internal carotid artery sacrifice. *AJNR Am J Neuroradiol* 26: 2602–2609, 2005
- 16) van Rooij WJ, Sluzewski M, Slob MJ, Rinkel GJ: Predictive value of angiographic testing for tolerance to therapeutic occlusion of the carotid artery. *AJNR Am J Neuroradiol* 26: 175–178, 2005
- 17) Snelling BM, Sur S, Shah SS, et al.: Venous phase timing does not predict SPECT results during balloon test occlusion of the internal carotid artery. *World Neurosurg* 102: 229–234, 2017
- 18) Murphy KJ, Payne T, Jamadar DA, Beydoun A, Frey KA, Brunberg JA: Correlation of continuous EEG monitoring with [O-15]H<sub>2</sub>O positron emission tomography determination of cerebral blood flow during balloon test occlusion of the internal carotid artery. Experience in 34 cases. *Interv Neuroradiol* 4: 51–55, 1998
- 19) Morishima H, Kurata A, Miyasaka Y, Fujii K, Kan S: Efficacy of the stump pressure ratio as a guide to the safety of permanent occlusion of the internal carotid artery. *Neurol Res* 20: 732–736, 1998
- 20) Herkes GK, Morgan M, Grinnell V, et al.: EEG monitoring during angiographic balloon test carotid occlusion: experience in sixteen cases. *Clin Exp Neurol* 30: 98–103, 1993

---

*Address reprint requests to:* Noriaki Fukuhara, MD, Department of Hypothalamic and Pituitary Surgery, Toranomon Hospital, 2-2-2 Toranomon, Minato-ku, Tokyo 105-8470, Japan.  
*e-mail:* n-fukuhara@hotmail.co.jp