



Published in final edited form as:

*Interdiscip Neurosurg.* 2021 March ; 23: . doi:10.1016/j.inat.2020.100904.

## Resection of a conus medullaris hemangioblastoma: Case report

Reinier Alvarez<sup>a,b,c</sup>, Panagiotis Mastorakos<sup>c,d</sup>, Prashant Chittiboina<sup>a,c,\*</sup>

<sup>a</sup>Neurosurgery Unit for Pituitary and Inheritable Diseases, National Institute of Neurological Disorders and Stroke, Bethesda, MD, United States

<sup>b</sup>Florida International University Herbert Wertheim College of Medicine, Miami, FL, United States

<sup>c</sup>Surgical Neurology Branch, National Institute of Neurological Disorders and Stroke, Bethesda, MD, United States

<sup>d</sup>Department of Neurosurgery, University of Virginia, Charlottesville, VA, United States

### Abstract

**Background:** Conus medullaris tumors are rare, as the majority of all spinal cord tumors occur in the cervical and thoracic regions. Hemangioblastomas of the spinal cord account for 3%–4% of all intramedullary spinal cord tumors and can be sporadic or associated with von Hippel-Lindau disease. There are only fourteen cases of conus medullaris hemangioblastomas published in the literature, herein we present the fifteenth.

**Case description:** A 44-year old male with von Hippel Lindau disease presented with worsening bilateral lower extremity weakness, gait imbalance as well as absent perineal and genital sensation with weak voluntary anal contraction. MRI demonstrated multiple stable spinal tumors and a 6 mm conus medullaris hemangioblastoma with growth and a new peri-tumoral cyst. The patient underwent uncomplicated surgical resection with appreciable improvement in perineal sensation and sphincteric control during post-operative course.

**Conclusions:** Timely resection of conus medullaris tumors can provide symptomatic relief and prevent the progression of devastating neurological deficits. Careful microsurgical dissection with appropriate patient selection allows for safe resection of conus medullaris tumors.

### Keywords

Conus medullaris; Hemangioblastoma; Intramedullary spinal cord tumor; Von Hippel Lindau

---

This is an open access article under the CC BY-NC-ND license.

\*Corresponding author at: Neurosurgery Unit for Pituitary and Inheritable Diseases, National Institute of Neurological Disorders and Stroke, National Institutes of Health, 10 Center Drive, Room 3D20, Bethesda, MD 20892-1414, United States. prashant.chittiboina@nih.gov (P. Chittiboina).

#### Declaration of Competing Interest

The authors declare that they have no known competing financial interests or personal relationships that could have appeared to influence the work reported in this paper.

Appendix A. Supplementary data

Supplementary data to this article can be found online at <https://doi.org/10.1016/j.inat.2020.100904>.

## 1. Introduction

Intramedullary spinal cord tumors (IMSCT) are rare, making up 2%–4% of all primary central nervous system (CNS) neoplasms [1]. Ependymomas are the most common histological subtype identified in adults with intramedullary spinal cord tumors, while astrocytomas are the most common tumors in pediatric patients [2]. The third most common tumors are hemangioblastomas, accounting for 3%–4% of all IMSCT [1], although they can be sporadic, 10%–30% of patients with spinal cord HGB have a diagnosis of von Hippel-Lindau (VHL) [2]. As with all primary IMSCT, hemangioblastomas most commonly occur in the cervical and thoracic region of the spinal cord [1,3,4]. Tumors of the conus medullaris have been reported to occur in 10% of individuals with IMSCT, however, there have only been fourteen cases of conus medullaris hemangioblastomas reported in the literature [3,5–14].

The rarity of primary conus medullaris tumors and the apprehension of causing further damage to the surrounding neural elements may cause concern about the ideal treatment approach for these patients. Here, we discuss the pertinent clinical course of a 44-year-old man with von Hippel-Lindau disease who presented with saddle anesthesia and worsening lower extremity weakness, as well as with urinary and bowel disturbances due to a conus medullaris hemangioblastoma. Within, we provide details on the operative approach used and the indications for surgical intervention in patients with a symptomatic primary tumor of the conus medullaris.

## 2. Case presentation

### 2.1. Clinical course

A 44-year old male with von Hippel Lindau disease and heavy disease burden in the spinal cord and cauda equina presented with worsening bilateral lower extremity weakness, gait imbalance as well as perineal and genital numbness over the past 6 months. He also noted worsening urinary urgency as well as decreased bowel control without episodes of incontinence. He had previously undergone multiple suboccipital approaches for resection of brainstem and cerebellar hemangioblastomas as well as thoracic and lumbar laminectomies for resection of intramedullary and cauda equina hemangioblastomas, respectively.

Neurological examination demonstrated weakness in bilateral lower extremities. More specifically bilateral hip flexion was 3/5, right knee extension and flexion 4/5 and left knee extension and flexion 3/5, right dorsi flexion and plantar flexion 3/5 and left dorsiflexion and plantar-flexion 1/5. While left ankle weakness was stable from previous surgery the remaining findings represented deterioration over the past 6 months. We also noted absent perineal and genital sensation with weak voluntary anal contraction. There was patchy decreased bilateral lower extremity sensation that was more pronounced on the right with decreased proprioception bilaterally.

Whole spine MRI demonstrated post-operative changes from previous T4–T7 and L2–L4 laminectomies and numerous enhancing lesions involving the spinal cord and cauda equina (Fig. 1A). Most of the lesions had not appreciably changed, apart from a 2 mm increase in

size of a right dorsal intramedullary conus medullaris lesion at T12-L1 vertebral levels with development of a new peri-tumoral cyst (Fig. 1B, C). Considering the worsening conus medullaris symptoms and increase in lesion size and especially development of a peritumoral cyst, we recommended a surgical resection of this symptomatic tumor.

## 2.2. Operative details

The patient was positioned prone on a standard operating table with a Wilson frame. Neuromonitoring was used to monitor somatosensory and motor evoked potentials as well as free-run and triggered EMG for direct stimulation. Based on anatomic landmarks and previous incisions, the incision was made over the T12-L1 spinous processes. Following posterior approach T12 and L1 laminectomies were completed using a Sonopet ultrasonic aspirator (Stryker). Under microscopic visualization, we completed a durotomy using a #15 blade, extended rostrally and caudally using an #11 blade over a groove dental dissector. Subsequently, the arachnoid was opened sharply using an #11 blade and the opening was further extended by splitting.

The multiple dorsal arterialized supra-pial veins were identified, and ultrasound was used to identify the tumor deep to the right dorsal root entry zone (DREZ). Using bipolar electrocautery, we coagulated the arterialized supra-pial veins and sharply incised the pia medial to the DREZ using a diamond knife. We extended the incision by spreading using a microdissecting bipolar, identified the tumor and exposed the dorsal aspect from superior to inferior pole (Fig. 1D). Bipolar stimulation with 0.5 mA on the white matter lateral to the tumor resulted in activation of the urethral lead. We continued to develop the plain between the tumor and the surrounding parenchyma. Medially, two arterial feeders were identified, coagulated and sharply incised. Subsequently, the plane was further developed and the hemangioblastoma was rolled out in one piece. During dissection there was transient free-run EMG activity in the periurethral and perianal lead. The resection cavity was inspected, and small bleeders were spot coagulated.

The dura was reapproximated using running 4–0 vicryl. The wound was copiously irrigated and closed in a standard fashion. Throughout the case motor-evoked potentials (MEPs) were stable with good right leg and periurethral response, small perianal response and no reproducibly present left leg responses. Somatosensory-evoked potentials (SSEPs) were not reproducibly present throughout the surgery.

## 2.3. Post-operative course

He tolerated the procedure well with no perioperative complication. He noted gradual return of perineal and genital sensation on post-operative day 1. Improved bowel movement control was also noted during his post-operative hospital course, his exam remained otherwise stable compared to pre-operative baseline. Voiding trial was attempted during his hospital stay and was unsuccessful. He was discharged with a Foley catheter and will be followed as an outpatient for discontinuation of Foley, if permitted.

### 3. Discussion

We present a case of a VHL-associated conus medullaris hemangioblastoma with significant symptom improvement after surgical resection with intra-operative monitoring. This rare disease entity represents a decision-making and technical challenge. In our case presentation, we underline the importance of preserving the plane between the spinal cord and the tumor as well as completing an en-bloc resection, a concept that extends beyond hemangioblastomas. Careful patient selection and microsurgical technique can allow for symptomatic improvement after resection of a conus medullaris tumor.

The relatively low incidence of IMSCT of the conus medullaris has subsequently led to limited concise literature on the optimal management of these tumors [15]. It has been established that the main predictor of long-term post-operative outcome for IMSCT is the patients pre-operative neurological condition [12,15–17]. Wostrack *et al.* showed that 60% of patients operated on for conus medullaris or cauda equina tumors with 1 year or less of neurologic deficits showed post-operative improvement compared to only 50% of patients that had deficits for longer than one year [16]. Of patients that undergo gross total resection of tumors isolated to the conus medullaris, more than 50% of patients had sustained long-term improvement of their symptoms [16]. Moreover, Han *et al.* showed that 34.6% of patients that underwent surgery for conus medullaris tumors had improved post-operative, modified Japanese Orthopaedic Association (JOA) score for bladder function, while only 26.9% worsened [12]. Ultimately, early surgical resection prior to symptom onset or at initial presentation is of utmost importance in preserving neurological function.

Patients with von Hippel-Lindau disease (VHL) suffer from multiple neoplastic lesions due to an autosomal dominant germline mutation of the tumor suppressor *VHL* gene [18]. The majority will develop multiple CNS hemangioblastomas (HGB) in their lifetime, predominantly in the cerebellum and brainstem, however, 13% of hemangioblastomas may occur in the spinal cord [1,19]. To date, fourteen cases of conus medullaris hemangioblastomas have been reported (Table 1.) [3,5,14,6–13]. Of these, three were in VHL patients [3,6,8], five cases were sporadic [3,7,9,11,14], and the remaining six were not identified as either [5,10,12,13]. Ten of the fourteen cases had sphincteric dysfunction causing bladder and/or bowel incontinence or urgency on presentation, amongst other symptoms [3,5,8–12]. All fourteen patients were treated surgically with only two suffering post-operative neurological worsening. One patient developed a new onset paraparesis that continued to progress on long-term follow-up for which the authors concluded were likely due to incomplete tumor removal [3]. The other patient had progression of bladder disturbance that persisted on follow-up, likely due to overly aggressive tumor resection, as per the authors [12]. Of the remaining ten patients, seven were noted to have sustained post-operative improvement in their neurological function [5,10,11,13] four had no change in symptomatology or function [3,7,9,12], and for one there were no details on outcome [8].

As in intramedullary tumors located elsewhere in the CNS, histological classification will determine the presence of a clear dissection plane and feasibility of gross total resection [1]. Patients with non-astrocytic and non-invasive IMSCT have been shown to have better long-term post-operative outcomes with decreased recurrence following gross total resection [26].

In addition to pre-operative neurological status, the tumor histology is a key prognostic factor in predicting post-operative outcomes and surgical candidacy for patients with IMSCT, including those of the conus medullaris. The microsurgical techniques for resection of CNS hemangioblastomas have been well established, emphasizing the importance of extracapsular tumor dissection [20–25]. These principles of extracapsular, en-bloc resection extend to conus medullaris HGB, as described in our case. Circumferential dissection away from the surrounding neural tissue minimizes intraoperative blood loss as well as ensuring the complete resection of the HGB with the subsequent involution of the peritumoral cyst [23].

#### 4. Conclusion

Conus medullaris tumors can cause devastating neurological deficits that may be irreversible if untreated. The advances in microsurgical techniques, intraoperative electrophysiological monitoring, and histological tumor classification has made gross total resection of conus medullaris tumors a safe and feasible option. Prompt surgical resection of symptomatic conus medullaris tumors can provide symptomatic relief while preventing further progression. Large natural history studies can offer further information that can help guide clinical decision making in patients with conus medullaris tumors.

#### Supplementary Material

Refer to Web version on PubMed Central for supplementary material.

#### Acknowledgements

This study was funded by the Intramural Research Program of the National Institute of Neurological Diseases and Stroke.

#### Abbreviations:

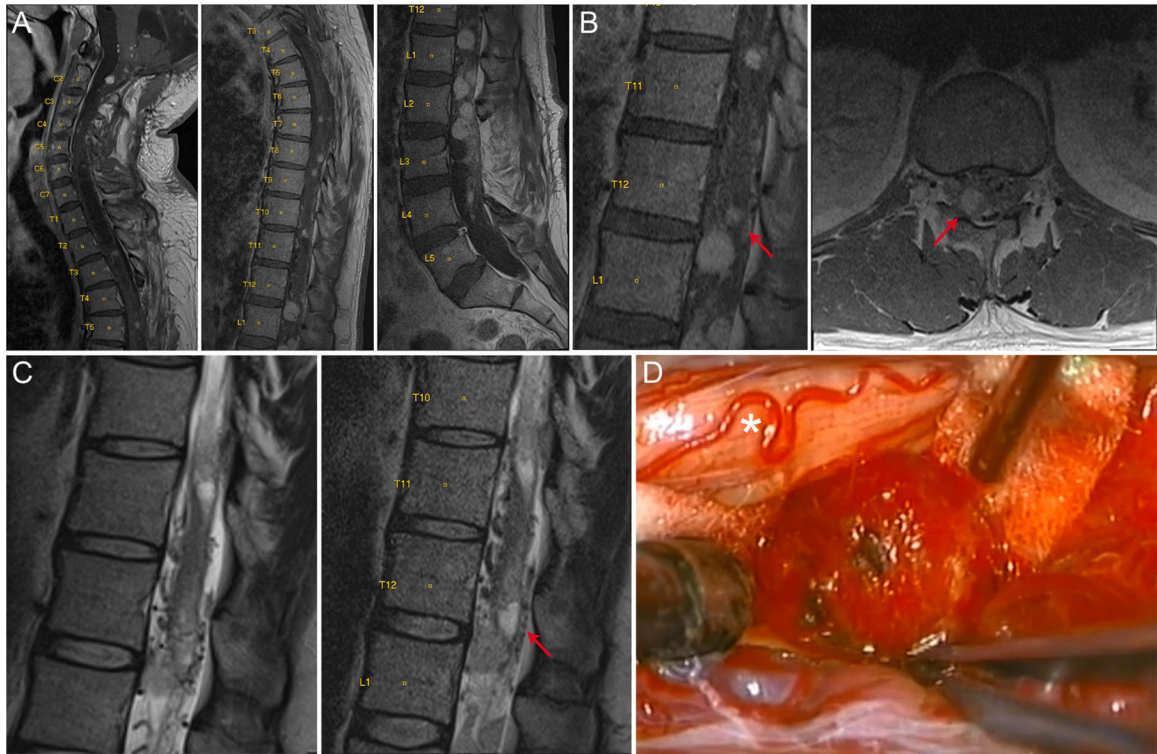
<b>CNS</b>	central nervous system
<b>DREZ</b>	dorsal root entry zone
<b>EMG</b>	electromyography
<b>HGB</b>	hemangioblastoma
<b>IMSCT</b>	intramedullary spinal cord tumor
<b>JOA</b>	Japanese Orthopaedic Association
<b>MRI</b>	magnetic resonance imaging
<b>MEP</b>	motor evoked potentials
<b>mm</b>	millimeter
<b>SSEP</b>	somatosensory evoked potentials

## VHL von Hippel Lindau

### References

- [1]. Tobin MK, Geraghty JR, Engelhard HH, Linninger A, Mehta AI, Intramedullary spinal cord tumors: a review of current and future treatment strategies, *Neurosurg. Focus* 39 (2) (2015) E14, 10.3171/2015.5.FOCUS15158.
- [2]. Chamberlain MC, Tredway TL, Adult primary intradural spinal cord tumors: a review, *Curr. Neurol. Neurosci. Rep* 11 (3) (2011) 320–328, 10.1007/s11910-011-0190-2. [PubMed: 21327734]
- [3]. Lee DK, Choe WJ, Chung CK, Kim HJ, Spinal cord hemangioblastoma: surgical strategy and clinical outcome, *J. Neurooncol* 61 (1) (2003) 27–34, 10.1023/A:1021297622944. [PubMed: 12587793]
- [4]. Kane PJ, El-Mahdy W, Singh A, Powell MP, Crockard HA, Spinal intradural tumours: Part II – Intramedullary, *Br. J. Neurosurg* 13 (6) (1999) 558–563, 10.1080/02688699943051. [PubMed: 10715723]
- [5]. Chen CY, Chen PH, Yao MS, Chu JS, Chan WP, MRI of hemangioblastoma in the conus medullaris, *Comput. Med. Imaging Graph.* 32 (1) (2008) 78–81, 10.1016/j.compmedimag.2007.08.008. [PubMed: 17931832]
- [6]. Van Velthoven V, Reinacher PC, Klisch J, et al., Treatment of intramedullary hemangioblastomas, with special attention to Von Hippel-Lindau disease, *Neurosurgery* 53 (6) (2003) 1306–1314, 10.1227/01.NEU.0000093497.81390.29. [PubMed: 14633297]
- [7]. Michaud LJ, Jaffe KM, Benjamin DR, Timothy Stuntz J, Lemire RJ, Hemangioblastoma of the conus medullaris associated with cutaneous hemangioma, *Pediatr. Neurol* 4 (5) (1988) 309–312, 10.1016/0887-8994(88)90072-0. [PubMed: 3242536]
- [8]. Chu BC, Terae S, Hida K, Furukawa M, Abe S, Miyasaka K, MR findings in spinal hemangioblastoma: correlation with symptoms and with angiographic and surgical findings, *Am. J. Neuroradiol* 22 (1) (2001) 206–217. [PubMed: 11158911]
- [9]. Roonprapunt C, Silvera VM, Setton A, Freed D, Epstein FJ, Jallo GI, Surgical management of isolated hemangioblastomas of the spinal cord, *Neurosurgery* 49 (2) (2001) 321–328, 10.1097/00006123-200108000-00012. [PubMed: 11504107]
- [10]. Spetzger U, Bertalanffy H, Huffmann B, Mayfrank L, Reul J, Gilsbach JM, Hemangioblastomas of the spinal cord and the brainstem: diagnostic and therapeutic features, *Neurosurg. Rev* 19 (3) (1996) 147–151, 10.1007/BF00512042. [PubMed: 8875501]
- [11]. Biondi A, Ricciardi GK, Faillot T, Capelle L, Van Effenterre R, Chiras J, Hemangioblastomas of the lower spinal region: report of four cases with preoperative embolization and review of the literature, *Am. J. Neuroradiol* 26 (4) (2005) 936–945. [PubMed: 15814949]
- [12]. Han IH, Kuh SU, Chin DK, Kim KS, Jin BH, Cho YE, Surgical treatment of primary spinal tumors in the conus medullaris, *J. Korean Neurosurg. Soc* 44 (2) (2008) 72–77, 10.3340/jkns.2008.44.2.72. [PubMed: 19096696]
- [13]. Boström A, Hans FJ, Reinacher PC, et al., Intramedullary hemangioblastomas: timing of surgery, microsurgical technique and follow-up in 23 patients, *Eur. Spine J* 17 (6) (2008) 882–886, 10.1007/s00586-008-0658-1. [PubMed: 18389290]
- [14]. Malis LI, Atraumatic bloodless removal of intramedullary hemangioblastomas of the spinal cord, *J. Neurosurg* 97 (1 SUPPL.) (2002) 1–6, 10.3171/spi.2002.97.1.0001.
- [15]. Ebner FH, Roser F, Acioly MA, Schoeber W, Tatagiba M, Intramedullary lesions of the conus medullaris: Differential diagnosis and surgical management, *Neurosurg. Rev* 32 (3) (2009) 287–301, 10.1007/s10143-008-0173-1. [PubMed: 18820958]
- [16]. Wostrack M, Shiban E, Obermueller T, Gemempt J, Meyer B, Ringegele F, Conus medullaris and cauda equina tumors: clinical presentation, prognosis, and outcome after surgical treatment – clinical article, *J. Neurosurg. Spine* 20 (3) (2014) 335–343, 10.3171/2013.12.SPINE13668. [PubMed: 24438427]

- [17]. Shrivastava RK, Epstein FJ, Perin NI, Post KD, Jallo GI, Intramedullary spinal cord tumors in patients older than 50 years of age: management and outcome analysis, *J. Neurosurg. Spine* 2 (3) (2005) 249–255, 10.3171/spi.2005.2.3.0249. [PubMed: 15796348]
- [18]. Latif F, Tory K, Gnarr J, et al., Identification of the von Hippel-Lindau disease tumor suppressor gene, *Science* (80-) 260 (5112) (1993) 1317–1320, 10.1126/science.8493574.
- [19]. Wanebo JE, Lonser RR, Glenn GM, Oldfield EH, The natural history of hemangioblastomas of the central nervous system in patients with von Hippel-Lindau disease, *J. Neurosurg* 98 (1 SUPPL.) (2003) 82–94, 10.3171/jns.2003.98.1.0082. [PubMed: 12546356]
- [20]. Jagannathan J, Lonser RR, Smith R, DeVroom HL, Oldfield EH, Surgical management of cerebellar hemangioblastomas in patients with von Hippel-Lindau disease, *J. Neurosurg* 108 (2) (2008) 210–222, 10.3171/JNS/2008/108/2/0210. [PubMed: 18240914]
- [21]. Mehta GU, Asthagiri AR, Bakhtian KD, Aua S, Oldfield EH, Lonser RR, Functional outcome after resection of spinal cord hemangioblastomas associated with von Hippel-Lindau disease: clinical article, *J. Neurosurg. Spine* 12 (3) (2010) 233–242, 10.3171/2009.10.SPINE09592. [PubMed: 20192620]
- [22]. Weil RJ, Lonser RR, Devroom HL, Wanebo JE, Oldfield EH, Surgical management of brainstem hemangioblastomas in patients with von Hippel—Lindau disease, *J. Neurosurg* 98 (1) (2003) 95–105, 10.3171/jns.2003.98.1.0095. [PubMed: 12546357]
- [23]. Wind JJ, Lonser RR, Management of von Hippel-Lindau disease-associated CNS lesions, *Expert Rev. Neurother* 11 (10) (2011) 1433–1441, 10.1586/ern.11.124. [PubMed: 21955200]
- [24]. Lonser RR, Weil RJ, Wanebo JE, Devroom HL, Oldfield EH, Surgical management of spinal cord hemangioblastomas in patients with von Hippel—Lindau disease, *J. Neurosurg* 98 (1) (2003) 106–116, 10.3171/jns.2003.98.1.0106. [PubMed: 12546358]
- [25]. Lonser RR, Oldfield EH, Microsurgical resection of spinal cord hemangioblastomas, *Neurosurgery* 57 (4 SUPPL.) (2005) 372–376, 10.1227/01.NEU.0000176849.76663.E4. [PubMed: 16234688]
- [26]. Karikari IO, Nimjee SM, Hodges TR, et al., Impact of tumor histology on resectability and neurological outcome in primary intramedullary spinal cord tumors: a single-center experience with 102 patients, *Neurosurgery* 68 (1) (2011) 188–197, 10.1227/NEU.0b013e3181fe3794.



**Fig. 1.**  
 VHL – associated hemangioblastoma of the conus medullaris. (A) Whole spine sagittal T1 post-contrast MRI demonstrates numerous enhancing lesions involving the spinal cord and cauda equina. (B) Sagittal and axial T1 post-contrast MRI of the thoracic spine demonstrate intraparenchymal conus medullaris lesion (red arrow). (C) Sagittal T2 thoracic MRIs over a 2-year interval demonstrate development of a peri-tumoral cyst (red arrow) at the conus medullaris. (D) Intra-operative microscopic view of hemangioblastoma. Asterisk depicts dorsal root entry zone.



**Table 1**

Literature review.

<b>Conus Medullaris Hemangioblastoma</b>				
<b>Author &amp; Year</b>	<b>Age (yrs), Sex</b>	<b>Location</b>	<b>VHL</b>	<b>Post-Operative Condition</b>
Michaud et al. 1988	0.5, F	T12-L1	–	No deficits
Spetzger et al. 1996	44, F	T11-L2	Unknown	Improved
	65, M	T12-L1	Unknown	Improved
Chu et al. 2001	30, M	T12-L1	+	—
Malis L. 2002	21, F	T12	–	Improved
Roonprapunt et al. 2003	31, F	T12-L1	–	Unchanged
Lee et al. 2003	27, F	T11-L1	–	Unchanged
	29, M	T12-L1	+	Worse (new paraparesis)
Van-Velthoven et al. 2003	27, F	T12	+	Improved
Biondi et al. 2005	24, F	T12-L1	–	Improved
Chen et al. 2008	74, M	T12-L1	Unknown	Improved
Han et al. 2008	57, M	L1-L2	Unknown	Unchanged
	61, M	T12-L1	Unknown	Unchanged
	37, F	T12-L1	Unknown	Worse (neurogenic bladder)
Bostrom et al. 2008	–	–	Unknown	Improved