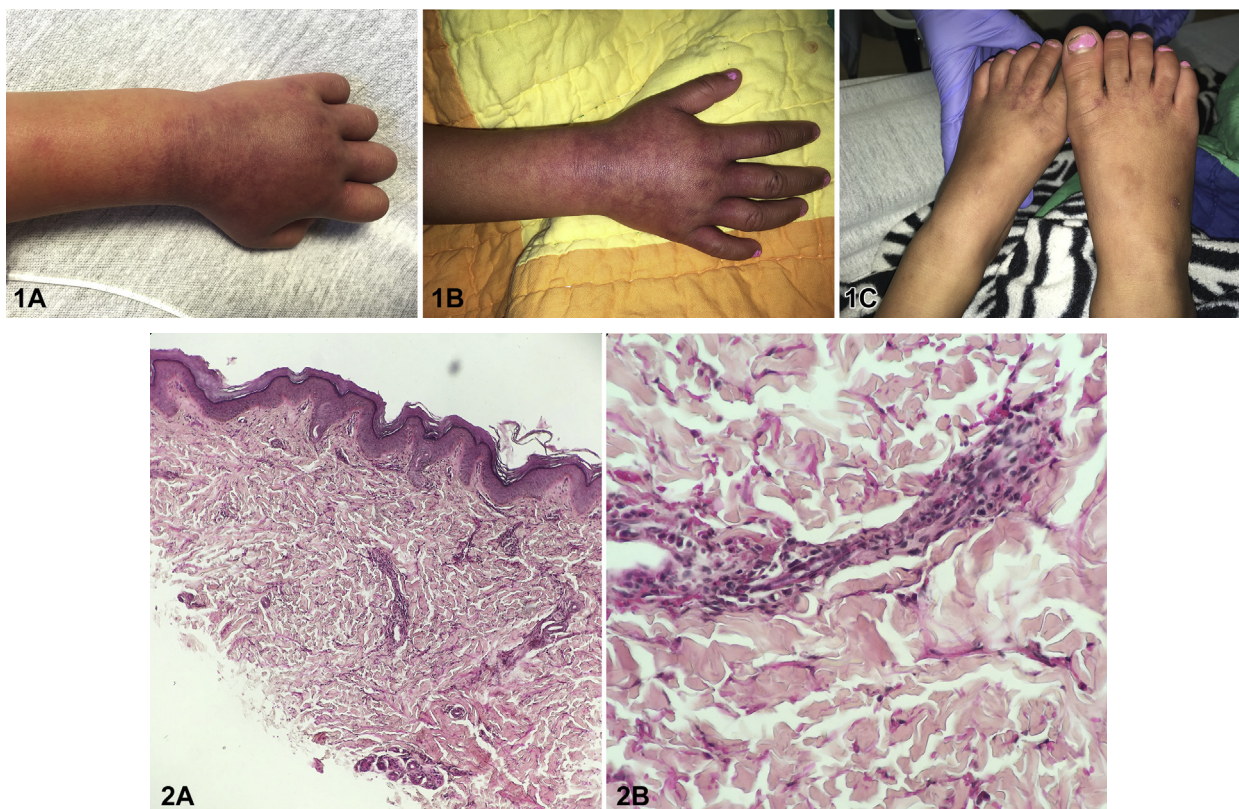


Purpuric eruption in a child



Alfredo Bou-Prieto, MD, Carla N. Cruz-Diaz, MD, and Rafael F. Martín-García, MD
San Juan, Puerto Rico

Key words: coxsackie B6; papular purpuric gloves and socks syndrome.



A 4-year-old girl with history of asthma presented with acral lesions that appeared 1 day before evaluation. Her parents reported that the lesions were painful and noted swelling. On examination, the patient had erythematous and purpuric macules, confluent into patches on the dorsal hands with extension to the distal forearms (Fig 1, A and B) and fewer similar lesions on the distal dorsal feet (Fig 1, C). No mucosal lesions or lymphadenopathy was identified. Her parents denied fever, diarrhea, abdominal pain, travel history, or recent medications. Laboratory values showed leukocytosis of 11.9 (neutrophils, 64%; lymphocytes, 24%) and platelets of 45,000. Punch biopsy results are shown in Fig 2, (A and B). On follow-up visit at 5 weeks, eruption and thrombocytopenia had resolved.

From the Department of Dermatology, University of Puerto Rico School of Medicine.

Funding sources: None.

Conflicts of interest: None disclosed.

This case was presented at the Gross and Microscopic Symposium at the American Academy of Dermatology 2019 Annual Meeting in Washington DC on March 2, 2019.

Correspondence to: Alfredo Bou-Prieto, MD, PO Box 365067, San Juan, PR 00936. E-mail: bou.alfredo@gmail.com.

JAAD Case Reports 2020;6:63-5.
2352-5126/\$36.00

© 2019 by the American Academy of Dermatology, Inc. Published by Elsevier, Inc. This is an open access article under the CC BY-NC-ND license (<http://creativecommons.org/licenses/by-nc-nd/4.0/>).

<https://doi.org/10.1016/j.jidcr.2019.09.010>

Question 1: What is the diagnosis?

- A. Henoch-Schonlein purpura (HSP)
- B. Rocky Mountain spotted fever (RMSF)
- C. Hand-foot-mouth disease (HFMD)
- D. Papular purpuric gloves and socks syndrome (PPGSS)
- E. Exanthematous drug eruption

Answers:

A. HSP – Incorrect. HSP is a type of small-vessel vasculitis seen mostly in children, commonly after an upper respiratory tract infection. It presents with palpable purpura and is often associated with extracutaneous manifestations such as arthralgias, abdominal pain, and nephritis. Pathology in HSP shows leukocytoclastic vasculitis of small vessels.

B. RMSF – Incorrect. The patient had no relevant travel history to endemic regions. Additionally, RMSF is commonly preceded by systemic symptoms such as fever, severe headache, and myalgias. Pathology in RMSF shows early perivascular edema, erythrocyte extravasation, thrombosis, and vasculitis in later lesions.

C. HFMD – Incorrect. HFMD presents with oval-shaped vesicles on the hands and feet and oral lesions which were not present in this patient.

D. PPGSS – Correct. The clinical presentation of erythematous and purpuric patches on the hands and feet were consistent with this condition. Serum testing showed Coxsackie B6 as the culprit, a previously reported cause of PPGSS.^{1,2} Pathology showed a superficial perivascular mixed infiltrate of lymphocytes and eosinophils and dermal hemorrhage. Because histopathologic findings in PPGSS are nonspecific and common to viral exanthems, biopsy is not needed as part of the evaluation.² In this case, it was performed to exclude vasculitis.

E. Exanthematous drug eruption – Incorrect. This condition presents with confluent macules and papules and not exclusively on hands and feet. The patient's parents did not recall any recent medications.

Question 2: What is the most common cause of this disease?

- A. Cutaneous small vessel vasculitis with vascular IgA deposition
- B. *Rickettsia rickettsi*

- C. Parvovirus B19
- D. Cytomegalovirus (CMV)
- E. Epstein-Barr virus (EBV)

Answers:

A. Cutaneous small vessel vasculitis with vascular IgA deposition – Incorrect. This is the pathogenesis of HSP.

B. *Rickettsia rickettsi* – Incorrect. This is the cause of RMSF, which is acquired from tick bites.

C. Parvovirus B19 – Correct. PPGSS is a rare, but very characteristic exanthem, first described in 1990.^{1,2} The following year, PPGSS was proposed to be caused by parvovirus B19.^{1,2} Since then, several other viruses have been increasingly implicated, including measles, hepatitis B, EBV, Coxsackie, HHV6, and CMV.^{1,2} It is now estimated that parvovirus B19 is the cause in 60% to 80% of cases.^{2,3}

D. CMV – Incorrect. Although CMV has been reported as a cause of PPGSS, parvovirus B19 is the most common etiology.¹⁻³

E. EBV – Incorrect. EBV has been reported to cause purpuric gloves and socks syndrome as well, but it is not the most common cause.¹⁻³

Question 3: Which is true regarding this condition?

- A. It is rarely seen in adolescents and young adults.
- B. Its borders never extend beyond the ankles and wrists.
- C. Lymphopenia, neutropenia, and thrombocytopenia have not been previously reported.
- D. It occurs less commonly during summer and spring.
- E. It is not as rare in children as previously thought.

Answers:

A. It is rarely seen in adolescents and young adults – Incorrect. PPGSS is seen most commonly in adolescents and young adults. It presents with pruritic or painful edema and erythema of hands and feet followed by the appearance of confluent petechial or purpuric lesions.^{1,3,4} Occasionally,

slightly raised papules may be seen.³ Mucosal lesions and lymphadenopathy are often observed.^{3,4}

B. Its borders never extend beyond the ankles and wrists – Incorrect. Borders can be irregular and often sharply demarcated and can extend beyond ankles and wrists.^{1,3,4}

C. Lymphopenia, neutropenia, and thrombocytopenia have not been previously reported – Incorrect. Lymphopenia, neutropenia, and thrombocytopenia have been reported in some cases. This finding likely depends on the infectious etiologic agent and its hematologic toxicity rather than the type of skin reaction.³

D. It occurs less commonly during summer and spring – Incorrect. PPGSS occurs most commonly during summer and spring.⁴

E. It is not as rare in children as previously thought – Correct. Although PPGSS is seen mostly in adolescents and young adults, a juvenile variant has been observed with several differences to the classic presentation.⁵ In the largest study of 33 juvenile patients, Hsieh and Huang⁵ observed the petechial component to be less pronounced, oral erosions in only 1 case, no fever or palpable

lymphadenopathy, peak incidence in October to December, and a longer average duration (4.8 weeks).

Abbreviations used:

CMV: cytomegalovirus

EBV: Epstein-Barr virus

HFMD: hand-foot-mouth disease

HSP: Henoch-Schonlein purpura

PPGSS: papular purpuric gloves and socks syndrome

RMSF: Rocky Mountain spotted fever

REFERENCES

1. Rosales Santillan M, Dietert JB, Jahan-Tigh R. Adult-onset papular purpuric gloves and socks syndrome. *Dermatol Online J.* 2018;24(4).
2. Smith SB, Libow LF, Elston DM, Bernert RA, Warschaw KE. Gloves and socks syndrome: early and late histopathologic features. *J Am Acad Dermatol.* 2002;47(5):749-754.
3. Feldmann R, Wruhs M, Loader D, Steiner A. Papular-purpuric gloves and socks syndrome. *J Dtsch Dermatol Ges.* 2015;13(12):1286-1288.
4. Scaparrotta A, Rossi N, Attanasi M, Petrosino MI, Di Pillo S, Chiarelli F. A strange rash with “gloves and socks” distribution. *Arch Med Sci.* 2015;11(4):908-910.
5. Hsieh MY, Huang PH. The juvenile variant of papular-purpuric gloves and socks syndrome and its association with viral infections. *Br J Dermatol.* 2004;151(1):201-206.