

Case Report

The role of exercise therapy in managing post-radiotherapy trismus in head and neck cancer



Yousef E. Ezzat, MDS<sup>a,b</sup>, Rayan M. Sharika, MDS<sup>c</sup>, Adel A. Huzaimi, CFMP<sup>a,d</sup>, Khaled M. Al-Zahrani, FRCDC<sup>e</sup> and Hassan H. Abed, MSc<sup>f,\*</sup>

<sup>a</sup> Department of Prosthodontic, College of Dentistry, Riyadh Elm University, Riyadh, KSA

<sup>b</sup> Yanbu Dental Center, General Directorate of Health Affairs of Almadinah Almunawwarah, Ministry of Health, Yanbu, KSA

<sup>c</sup> Department of Oral and Maxillofacial Surgery, Faculty of Dentistry, Umm Alqura University, Makkah, KSA

<sup>d</sup> King Fahad Medical City, Department of Maxillofacial Surgery and Rehabilitation, Riyadh, KSA

<sup>e</sup> Department of Prosthetic Dental Science, Prince Sattam Bin Abdulaziz University, Al-Kharj, KSA

<sup>f</sup> Department of Basic and Clinical Oral Sciences, Faculty of Dentistry, Umm Alqura University, Makkah, KSA

Received 8 April 2020; revised 11 July 2020; accepted 14 July 2020; Available online 8 August 2020

المخلص

التشنج الفكي أو ما يعرف بالضرز هو أحد مضاعفات العلاج الإشعاعي التي تصيب الناجين من أورام الرأس والعنق. يُعرّف الضرز بأنه انخفاض في القدرة على فتح الفم إلى أقل من ٣٥ ملم بسبب التهاب العضلات الراقعة للفك السفلي نتيجة للعلاج الإشعاعي المؤبد. بسبب الطبيعة التقدمية للضرز، يُعد التدخل المبكر أمراً بالغ الأهمية لمنع المزيد من الضرر وضعف العضلات الراقعة للفك السفلي. تناقش هذه الورقة العلمية حالة مريضة تبلغ من العمر ٤٠ عاماً، تم تشخيصها بورم الخلايا الحرشفية في الجزء الأيمن من الفك العلوي. حيث تمت عملية استئصال جراحية للجزء الأيمن من الفك العلوي متبوعة بـ ٣٣ دورة من العلاج الإشعاعي. بعد خمسة أشهر من العلاج الإشعاعي، أبدت المريضة اهتماماً باستبدال أسنانها المفقودة لاستعادة وظائفها الفموية وتحسين الشكل الجمالي للوجه. خلال زيارتها بعد العلاج الإشعاعي في العيادة التخصصية للأسنان، وُجد أن فتحة الفم محدودة بمقدار ١٢ ملم. واشتملت الخطة العلاجية على استخدام جهاز خاص لزيادة قدرة المريضة على فتح الفم تدريجياً بالتناوب مع مثبتات اللسان الخشبية. بعد مرور ستة أسابيع من العلاج تحسن مقدار فتحة الفم إلى ٢٠ ملم. ونتيجة لذلك، أمكن علاجها بتريكية تعويضية صناعية للجزء المفقود من الفك والأسنان وذلك باستخدام تقنيات التصميم والتصنيع بمساعدة الحاسوب. تشير هذه الحالة إلى أن استخدام الجهاز الخاص لزيادة ارتفاع فتحة الفم ومثبتات اللسان الخشبية يساهمان في تحسين قدرة المريض على فتح الفم بشكل ملحوظ إذا استخدمتا بالتناوب.

الكلمات المفتاحية: العلاج الإشعاعي؛ الضرز؛ فتح الفم؛ مظهر الوجه؛ أورام الفك والعنق

Abstract

Trismus is a post-radiotherapy complication that affects survivors of head and neck cancers. It is described as the reduction of mouth opening to less than 35 mm. The condition is a progressive process; hence early intervention is crucial to prevent further damage and weakness to the elevator muscles of the mandible. Here, we report a 40-year-old woman with known squamous cell carcinoma of the maxillary sinus in stage T3N0M0 who had undergone upper right partial maxillectomy with subsequent 33 fractions of radiotherapy (66 Gy; intensity-modulating radiotherapy). Five months post-radiotherapy, the patient showed interest in replacing her missing teeth to restore her oral functions and facial appearance. At her post-radiotherapy visit in the dental assessment clinic, she showed a mouth opening of 12 mm. The TheraBite<sup>®</sup> Jaw Motion Rehabilitation System<sup>™</sup> and wooden tongue depressors were alternatively used for 6 weeks (4–5 stretches/day; each stretch held for 15 s). Mouth opening gradually increased to 20 mm. Consequently, a definitive obturator prosthesis was fabricated using computer-aided design and computer-aided manufacturing technologies with the 3Shape D900 model scanner. These were challenging and time-consuming steps, but acceptable facial appearance and mouth opening were restored for the patient. This case suggests that TheraBite<sup>®</sup> Jaw Motion Rehabilitation System<sup>™</sup> and wooden tongue depressors help to increase mouth opening significantly if used together and alternatively.

\* Corresponding address: Department of Basic and Clinical Oral Sciences, Faculty of Dentistry, Umm AL-Qura University, P.O.BOX 14405, 21955, Makkah, KSA.

E-mail: hh Abed@uqu.edu.sa (H.H. Abed)

Peer review under responsibility of Taibah University.



**Keywords:** Facial appearance; Mouth opening; Radiotherapy; Therabite® Jaw Motion Rehabilitation System™; Trismus

© 2020 The Authors.

Production and hosting by Elsevier Ltd on behalf of Taibah University. This is an open access article under the CC BY-NC-ND license (<http://creativecommons.org/licenses/by-nc-nd/4.0/>).

## Introduction

Radiotherapy is considered a major treatment modality for head and neck cancers (HNCs).<sup>1</sup> In addition, some HNC patients require treatment with chemotherapy and/or surgery.<sup>2</sup> Advancements in radiotherapy techniques have produced successful results that aid in improving the quality of life (QoL) and increasing the survival rate of HNC patients<sup>3</sup>; however, it can still produce acute (short-term) and chronic (long-term) side effects.<sup>1</sup> Acute side effects develop 7–10 days after starting treatment with radiotherapy (i.e., dry mouth, oral mucositis, and loss of taste).<sup>4</sup> The risk of chronic side effects persists with HNC survivors even after treatment with radiotherapy is completed. These chronic side effects might include radiation caries, trismus, and/or osteoradionecrosis (ORN).<sup>5</sup>

ORN is a serious complication that might develop following treatment with radiotherapy for HNC patients.<sup>6</sup> Marx<sup>7</sup> described ORN as “an area of exposed, devitalised bone present for greater than 3 months in an area that has been irradiated with no signs of local neoplastic disease.” ORN may develop spontaneously or following an invasive procedure that impacts the jawbone.<sup>5</sup> Signs and symptoms of ORN include an area of exposed necrotic bone, numbness, abnormal mouth opening, orocutaneous fistula, and pain in the jaw area, which might also extend beyond the jaws.<sup>8</sup> Therefore, dental assessment before starting the treatment with radiotherapy for HNC patients is crucial.<sup>9</sup> This includes patient education about possible side effects of cancer therapy, prescription of a high fluoride-containing toothpaste, and dental extraction of teeth with a poor prognosis, which helps to reduce the need for dental extraction in HNC survivors post-radiotherapy, thereby reducing the risk of ORN.

Trismus may also develop in HNC survivors following radiotherapy. Dijkstra et al.<sup>10</sup> described trismus as a reduction in mouth opening to less than 35 mm due to the inflammation of the mandibular elevator muscles resulting from ionising radiation. Mouth opening is essential to observe the previously treated area for recurrence.<sup>4</sup>

Trismus usually develops in HNC survivors due to the inflammation process and subsequent pain.<sup>11</sup> A systematic review concluded that the prevalence of trismus was found to be 17% at baseline, 44% at 6 months post-radiotherapy, 32% at 12 months post-radiotherapy, and 32% at 3–10 years post-radiotherapy.<sup>11</sup> It appears clinically 2 months post-radiotherapy.<sup>12</sup> Bhandari et al.<sup>12</sup> reported

that reduced mouth opening is approximately 2%–4% per month at the interincisal opening level. However, they also reported that the progression in reduced mouth opening might continue for up to 9 months. Therefore, early intervention is crucial to prevent further damage and weakening of the mandibular elevator muscles.

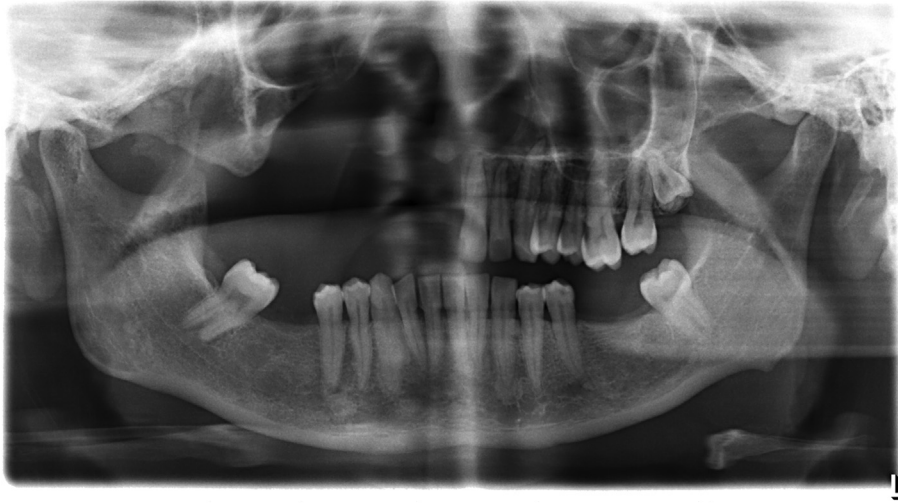Trismus restricts mouth opening for HNC survivors, which complicates their ability to eat and talk normally.<sup>12</sup> Subsequently, poor QoL may result.<sup>1,4</sup> A retrospective hospital-based study found that HNC survivors had an average of 14 missing teeth following radiotherapy.<sup>13</sup> Prophylactic molar extraction at the pre-radiotherapy dental assessment stage might explain why HNC patients have more missing teeth.<sup>14</sup> In addition to trismus, living with missing teeth further complicates eating, chewing, and speaking in HNC survivors.<sup>13</sup>

A systematic review found that replacement of the missing teeth with dentures may not be related to the development of ORN.<sup>15</sup> Abed et al.<sup>13</sup> in their retrospective study of 439 HNC survivors did not find ORN cases associated with denture use.<sup>13</sup> Moreover, Sharka et al.<sup>16</sup> in their umbrella systematic review concluded that replacement of the missing teeth with dentures might provide the same level of QoL compared to the replacement with dental implants. However, if trismus is left untreated, it complicates the fabrication of the dental prosthesis; thus, this impacts HNC survivors' oral function and QoL, necessitating early intervention. Here, we report a case of a woman diagnosed with squamous cell carcinoma of the maxillary sinus who was treated with partial maxillectomy and radiotherapy. The patient attended the dental clinic with a challenging limited mouth opening as a consequence of radiotherapy. She received a definitive maxillary obturator after 6 weeks of exercise therapy for the mandibular elevator muscles. The mouth opening rose from 12 to 20 mm.

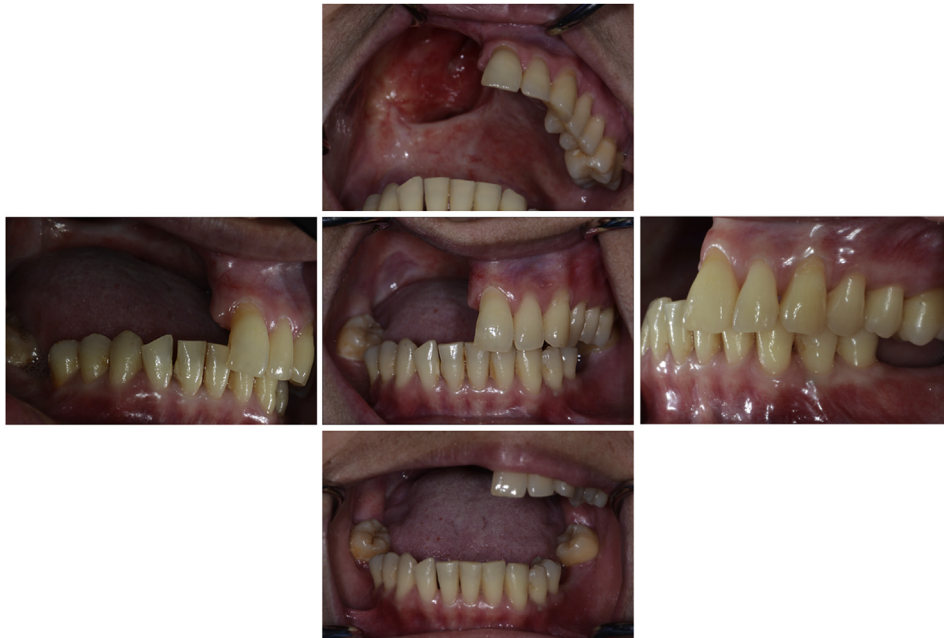## Case report

A 40-year-old Asian woman was referred from the Oncology Department to the Department of Oral and Maxillofacial Prosthodontic at the Riyadh Elm University (Riyadh, KSA) following cancer therapy. The patient was diagnosed with squamous cell carcinoma affecting the right maxillary sinus (tumour [T], nodes [N], and metastasis [M] stage: T3N0M0). She underwent upper right partial maxillectomy followed by 33 fractions of radiotherapy (66 Gy; IMRT; intensity-modulated radiotherapy). Five months post-radiotherapy, the patient was keen to replace her surgical maxillary obturator prosthesis, restore her oral functioning, and improve her appearance.

Radiographic examination, including panoramic tomography (Figure 1), revealed a large bony defect in the area of the right maxillary sinus consistent with the history of partial maxillectomy. The left maxillary sinuses were well-pneumatised with the evidence of mucosal thickening, suggestive of mucositis. The temporomandibular joints appeared unremarkable. No abnormalities were detected in the extraoral examination. Intraoral examination (IOE) revealed an oroantral communication with the



**Figure 1:** A dental panoramic tomograph (DPT).



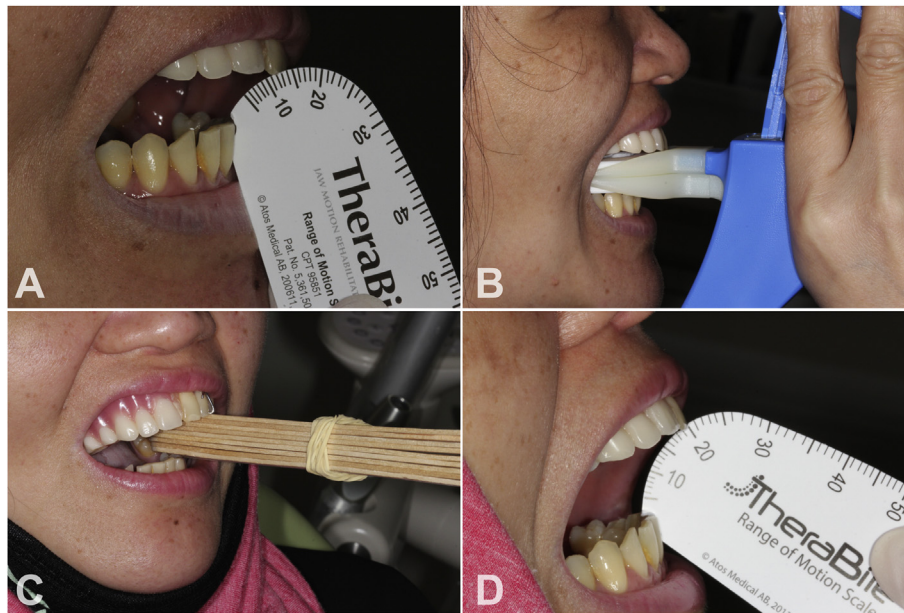
**Figure 2:** Pre-treatment clinical photographs.

upper right maxillary sinus and a few lower missing teeth (Figure 2). It showed that the patient had adequate oral hygiene, but some calculus accumulations. The patient had a challenging limited mouth opening (12 mm) as a consequence of radiotherapy (Figure 3A). She reported brushing her teeth twice daily using a high fluoride-containing toothpaste.

The treatment plan was discussed with the patient. She was advised by a prosthodontist to wear a new temporary obturator prosthesis to help increase her mouth opening. A temporary upper right obturator prosthesis was fabricated

with a limited mouth opening (12 mm). The patient was also informed about the importance of mouth-opening exercises using Therabite® Jaw Motion Rehabilitation System™ (TJMRS) and wooden tongue depressors (Figure 3B, C). She was instructed to use TJMRS and wooden tongue depressors alternatively every day as much as she could until she felt muscle fatigue (4–5 stretches/day; each stretch held for 15 s). However, she was informed to stop exercise therapy immediately if pain was experienced in the jaw area. The patient was educated about using both techniques by a prosthodontist to ensure that she could exercise





**Figure 3:** (A) Pre-exercise mouth opening = 12 mm; (B) Therabite® Jaw Motion Rehabilitation System™. (C) Wooden tongue depressors and (D) post-exercise mouth opening = 20 mm.

independently at home. The mouth opening started at 12 mm and increased to 20 mm in 6 weeks (Figure 3D). The patient was followed-up in the clinic by the prosthodontist at the end of each week. Consequently, a definitive obturator prosthesis was fabricated using computer-aided design and computer-aided manufacturing (CAD/CAM) technologies with the 3Shape D900 model scanner (3SD900) (3Shape, North America). Figure 4 shows the steps of fabrication of the definitive obturator prosthesis. After 1 year, the patient was followed-up in the dental clinic. Her mouth opening had been maintained at 20 mm and her oral hygiene was adequate. There were no signs of ORN or unhealed soft tissue.

At the discharge appointment, the patient was advised to continue using the TJMRS and wooden tongue depressors alternatively, at least twice a week, as trismus is progressive. She was also advised by the dentist to brush her teeth twice daily using a high fluoride-containing toothpaste and was educated by the dental team about the importance of maintaining good oral hygiene, particularly that developing dry mouth may complicate the use of the obturator prosthesis. She was also advised about the importance of having a regular dental review every 6 months and about symptoms of spontaneous or non-spontaneous ORN (i.e., an area of exposed necrotic bone, numbness, abnormal opening, fistula, and pain related to the jaw area) so that she could seek help if she needed it. Figure 5 shows the post-treatment clinical photographs.

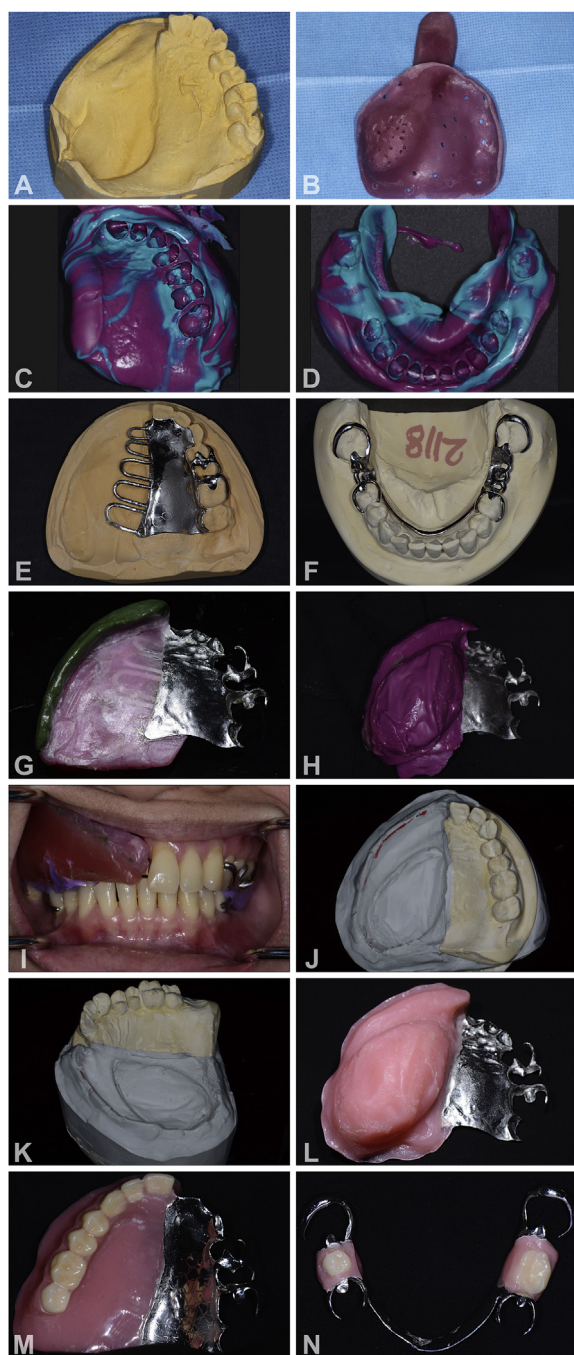
## Discussion

Trismus is common and can affect many HNC survivors post-radiotherapy,<sup>11</sup> affecting their oral function and QoL adversely.<sup>1</sup> It profoundly affects various aspects of

activities of daily living, such as nutrition consumption, grinding ability, chewing problems, practising adequate oral hygiene, attending dental appointments, and speech. A systematic review concluded that early treatment is crucial for successful results.<sup>17</sup>

In the present case, the patient had trismus (12 mm) that developed following upper right partial maxillectomy surgery and radiotherapy. The patient was educated to use TJMRS and wooden tongue depressors alternately to help reduce muscular fibrosis and increase open bite gradually.

TJMRS was developed based on the idea of constant passive motion and stretching, which has proven to be an effective way to arrange and restore the motion of the jaw muscles.<sup>18</sup> Therefore, it can be utilised to limit the effect of trismus by application during chemotherapy or radiation therapy, in order to subdue already existing trismus. It is recommended that the treatment protocol with TJMRS should be determined according to the therapeutic condition of the patient and underlying cause.<sup>19</sup> For example, it is necessary to notice that exercise therapy for trismus in HNC survivors using TJMRS with/without wooden tongue depressors leads to muscle fatigue and/or pain. Muscle fatigue following exercise sessions is not uncommon, and patients should be informed about this consequence, which should reduce gradually following further exercise sessions.<sup>19</sup> However, it is advisable to avoid or decrease the exercise time if there is an increase in pain, as it can result in muscle guarding, which may undermine the effectiveness of the treatment and decrease patient compliance. Constant monitoring and examination are crucial for this type of treatment, which was why the progression of treatment and the patient's compliance was reviewed by the prosthodontist weekly to ensure safe dental care.



**Figure 4:** (A) Primary dental cast, (B) special tray, (C) upper secondary impression, (D) lower secondary impression, (E) upper metal framework, (F) lower metal framework, (G) border moulding of the upper partial denture, (H) the definitive impression for the structural defect, (I) jaw relation, (J/K) upper dental casts with the structural defect, (L) upper obturator prosthesis (palatal surface), (M) upper obturator prosthesis (occlusal surface), and (N) lower partial denture.

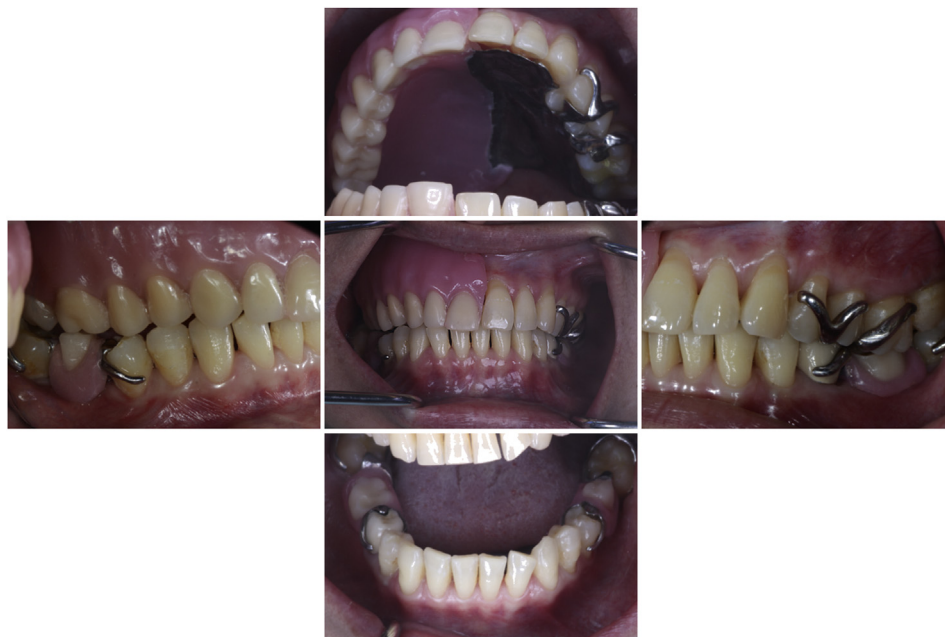A recent prospective study including 20 patients with trismus after maxillofacial operations found that TJMRS increased mouth opening significantly in 4 weeks; therefore, this improved HNC survivors' QoL, and their pain level

reduced dramatically.<sup>19</sup> In this case report, the patient was educated to use TJMRS alternatively with wooden tongue depressors, and her mouth opening increased from 12 mm to 20 mm in 6 weeks. This was comparable with the reported time required to increase mouth opening. The current case showed that patient education on TJMRS and wooden tongue depressors usage was essential to achieve a successful result. A multi-centre, formal-evaluative qualitative retrospective study of 21 HNC patients found that clear exercise instructions were important for patient compliance.<sup>10</sup> The dental team is advised to record the differences in mouth opening regularly, in order to assess potential difficulties faced by the patient during exercise therapy; hence this will also help raise patients' motivation and compliance.

Constructing the obturator prosthesis was a crucial "happiness step" after achieving a satisfactory mouth opening for the patient and the dental team. This result was in line with a recent study investigating 100 patients who received oral rehabilitation after completion of treatment for HNC survivors and confirmed that dental rehabilitation is a significant step toward enhancing the QoL after controlling the disease, including the psychological and social wellbeing of the patients.<sup>20</sup>

A retrospective study of 173 HNC survivors reported the difficulties that might be encountered with fabrication of a definitive maxillary obturator; therefore, a clear discussion between the dentist and the patient is crucial to build a clear expectation for the patient and to save the dental team time and effort.<sup>21</sup> The large size of the maxillary defect, non-stable opposing occlusion, and poor overlying tissue in the surgical area are important factors that impact the successful result of the maxillary obturator prosthesis.<sup>21</sup> Including these factors when dentists discuss the treatment plan with patients is crucial to avoid psychological distress after having unexpected results.

In the present case, the consequences of cancer therapy had a long-term negative impact on the patient's self-perception. She considered her teeth a personal pride and source of dignity; she did not wish to be seen without her teeth. Therefore, the feeling of self-esteem and confidence was a priority during prosthesis stage. Providing the obturator prosthesis significantly improved her psychological wellbeing and fulfilled her desire. It is important to note that the dental needs of HNC survivors might be neglected due to overlap with other medical appointments and follow-up clinics following cancer therapy. Other barriers were also discussed, such as patient comorbidity, poor communication, patient/family resistance, lack of time of healthcare professionals, and lack of resources.<sup>22</sup> The dental team should understand the dental needs of HNC survivors, regardless of the cost or type of dental treatment. They should also provide them with dental needs required to protect their appearance, such as replacing their missing teeth or improving their aesthetics, regardless of the stage of cancer or how many days they will live. In this case, increasing the patient's mouth opening and providing her with a temporary and definitive obturator prosthesis were challenging, costly, and time-consuming steps. However,



**Figure 5:** Post-treatment clinical photographs.

they were provided successfully to maintain the patient's dignity and wishes.

### Conclusions

We presented a case of an HNC survivor who had trismus (12 mm) as a consequence of treatment with radiotherapy. The patient's mouth opening increased from 12 to 20 mm using TJMRS and wooden tongue depressors alternatively in 6 weeks, followed by fabrication of the definitive obturator prosthesis. These were challenging and time-consuming steps. However, they have been provided successfully to the cancer patient to maintain her dignity. This case suggests that Therabite® Jaw Motion Rehabilitation System™ and wooden tongue depressors help increase mouth opening significantly if used together and alternatively.

### Recommendations

Trismus is a post-radiotherapy complication that might affect HNC survivors. It affects their oral function and QoL negatively. Dentists should understand the unmet dental needs of HNC survivors once they complete the cancer therapy and are discharged to the primary dental care. They should also be familiar with techniques that help increase mouth opening in HNC survivors with trismus post-radiotherapy, as early intervention is crucial to improve the oral function and QoL.

### Source of funding

This research did not receive any specific grant from funding agencies in the public, commercial, or not-for-profit sectors.

### Conflict of interest

The authors have no conflict of interest to declare.

### Ethical approval

Written and verbal consent was obtained from the patient.

### Authors' contributions

YEE and AAH delivered clinical care to the patient. HHA and RMS drafted the manuscript. HHA and KMA revised the manuscript critically. All authors have critically reviewed and approved the final draft and are responsible for the content and similarity index of the manuscript.

### Acknowledgment

The authors would like to thank Dr. Fahad Baabdullah, an Oral and Maxillofacial Radiologist (Faculty of Dentistry, Umm Al-Qura University, Makkah, KSA), for his valuable help with interpreting the dental radiographs.

### References

1. Abed H, Reilly D, Burke M, Daly B. Patients with head and neck cancers' oral health knowledge, oral health-related quality of life, oral health status, and adherence to advice on discharge to primary dental care: a prospective observational study. *Spec Care Dent* 2019; 39(6): 593–602.
2. Ferrari D, Ghi MG, Franzese C, Codecà C, Gau M, Fayette J. The slippery role of induction chemotherapy in head and neck cancer: myth and reality. *Front Oncol* 2020; 10(7): 1–12.
3. Abel E, Silander E, Nyman J, Bove M, Johansson L, Björk-Eriksson T, et al. Impact on quality of life of IMRT versus 3-D



- conformal radiation therapy in head and neck cancer patients: a case control study. **Pract Radiat Oncol** 2017; 2(3): 346–353.
4. Burke MC, Fenlon MR, Banerjee A. The role of the general dental practitioner in managing the oral care of head and neck oncology patients. **Dent Update** 2012; 39(10): 694–702.
  5. Nabil S, Samman N. Risk factors for osteoradionecrosis after head and neck radiation: a systematic review. **Oral Surg Oral Med Oral Pathol Oral Radiol** 2012; 113(1): 54–69.
  6. Patel V, Ormondroyd L, Lyons A, McGurk M. The financial burden for the surgical management of osteoradionecrosis. **Br Dent J** 2017; 222(3): 177–180.
  7. Marx RE. A new concept in the treatment of osteoradionecrosis. **J Oral Maxillofac Surg** 1983; 41(6): 351–357.
  8. Wali R, King R, Patel V. Osteoradionecrosis beyond the jaws: a mini case series and review of the literature. **Oral Surg** 2020; 13(2): 139–146.
  9. Kumar N. Updated clinical guidelines on the oral management of oncology patients. **Fac Dent J** 2019; 10(2): 62–65.
  10. Dijkstra P, Huisman P, Roodenburg J. Criteria for trismus in head and neck oncology. **Int J Oral Maxillofac Surg** 2006; 35(4): 337–342.
  11. Watters AL, Cope S, Keller MN, Padilla M, Enciso R. Prevalence of trismus in patients with head and neck cancer: a systematic review with meta-analysis. **Head Neck** 2019; 41(9): 3408–3421.
  12. Bhandari S, Soni BW, Bahl A, Ghoshal S. Radiotherapy-induced oral morbidities in head and neck cancer patients. **Spec Care Dent** 2020; 40(3): 238–250.
  13. Abed H, Burke M, Fenlon MR, Scambler S, Scott SE. Denture use and dental risk factors associated with developing osteoradionecrosis after head and neck radiotherapy: a retrospective analysis of hospital records. **J Dent** 2020; 99: 103410.
  14. Patel V, Patel D, Browning T, Patel S, McGurk M, Sassoon I, et al. Pre-radiotherapy presenting dental status of the three most common head and neck cancer subsites in a novel radiation era. **Fac Dent J** 2020; 11(2): 52–57.
  15. Abed H, Burke M, Scambler S, Scott SE. Denture use and osteoradionecrosis following radiotherapy for head and neck cancer: a systematic review. **Gerodontology** 2019; 37(2): 102–109.
  16. Sharka R, Abed H, Hector M. Oral health-related quality of life and satisfaction of edentulous patients using conventional complete dentures and implant-retained overdentures: an umbrella systematic review. **Gerodontology** 2019; 36(3): 195–204.
  17. Kamstra JI, van Leeuwen M, Roodenburg JL, Dijkstra PU. Exercise therapy for trismus secondary to head and neck cancer: a systematic review. **Head Neck** 2017; 39(11): 2352–2362.
  18. Montalvo C, Finizia C, Pauli N, Fagerberg-Mohlin B, Andréll P. Impact of exercise with TheraBite device on trismus and health-related quality of life: a prospective study. **Ear Nose Throat J** 2017; 96(1): 1–6.
  19. Senthilkumar S, Tarun S. A study on effectiveness of therabite exercises to improve the jaw range of motion in trismus among oral cancer patients. **Res J Pharm Technol** 2020; 13(2): 519–522.
  20. Dholam KP, Dugad JA, Sadashiva KM. Impact of oral rehabilitation on patients with head and neck cancer: a study using the liverpool oral rehabilitation questionnaire and the oral health impact profile-14. **J Prosthet Dent** 2017; 117(4): 559–562.
  21. Ahmed ZU, Flynn J, Riedel ER, Huryn JM, Rosen EB. Definitive maxillary obturator prosthesis: timelines for fabrication and follow-up. **Spec Care Dent** 2020; 40(3): 315–319.
  22. Fitzgerald R, Gallagher J. Oral health in end-of-life patients: a rapid review. **Spec Care Dent** 2018; 38(5): 291–298.

**How to cite this article:** Ezzat YE, Sharka RM, Huzaimi AA, Al-Zahrani KM, Abed HH. The role of exercise therapy in managing post-radiotherapy trismus in head and neck cancer. *J Taibah Univ Med Sc* 2021;16(1):127–133.