

Clinicopathological Features of Patients Nominated for Head and Neck Biopsies: A One-Year Series

Fawaz D. Alshammari¹, Samir Abdulkarim Alharbi², Mohamed Ahmed B. Bealy³, Khalid Abd Elmohsin Awad Elseed Idris⁴, Ali Ahmed Alqahtani⁵, Hussain G. Ahmed^{6,7}

1. Department of Clinical Laboratory, College of Applied Medical Science, University of Hail, Hail, SAU 2. Department of Clinical Laboratory, College of Applied Medical Science, Shaqra University, Shaqra, SAU 3. Department of Pathology, College of Medicine, University of Hail, Hail, SAU 4. Department of Pathology, King Salman Hospital, Hail, SAU 5. Department of Pathology, King Khalid Hospital, Hail, SAU 6. Department of Histopathology and Cytology, Faculty of Medical Laboratory Sciences, University of Khartoum, Khartoum, SDN 7. Department of Pathology, University of Hail, Hail, SAU

Corresponding author: Fawaz D. Alshammari, fawazabof@gmail.com

Abstract

Background

Head and neck lesions, which are predominantly benign, were widely reported. Some of these tumors are potentially neoplastic and others are non-neoplastic. Therefore, this study aimed to assess the clinicopathological features of patients nominated for head and neck biopsies.

Methodology

In this study, data regarding head and neck biopsies were retrieved from the Department of Pathology at King Khalid Hospital, Hail, Northern Saudi Arabia. Data referring to head and neck biopsies of patients who were diagnosed during the period from January 2018 to December 2018 were included.

Results

The initial clinical presentations were stated for 50/64 (78.1%) head and neck lesions, 12/64 (18.8%) head and neck cysts, 1/64 (1.6%) keloid, and 1/64 (1.6%) ischemia. With regard to the biopsy's site, most were taken from the nose followed by oral cavity, scalp, ear, face, and eye, constituting 19/64 (29.7%), 15/64 (23.4%), 9/64 (14.1%), 5/65 (7.8%), 4/64 (6.2%), and 3/64 (4.7%), respectively.

Conclusion

Head and neck benign lesions, predominantly inflammatory lesions, are common in Northern Saudi Arabia. Accurate identification of these lesions is important during histopathological diagnosis, as some have pathological features that mimic some potentially neoplastic lesions.

Categories: Pathology, Oncology

Keywords: head and neck, benign, saudi arabia, lesions

Introduction

Head and neck cancers (HNCs) represent a group of heterogeneous malignancies that are responsible for diverse cancer-related morbidities and mortalities worldwide. These cancers are related to numerous exposures to specific etiological factors, which usually determine the pattern of subsequent prognosis [1]. In recent years, there is an increasing incidence of HNCs, which is attributed to the prevalent existence of high-risk human papillomavirus (HPV) subtypes, besides the consumption of tobacco and alcohol in numerous communities [2,3].

Many benign head and neck lesions were widely reported. Some of these tumors are potentially neoplastic and others are non-neoplastic [4,5]. Consequently, the overall management of any head and neck tumor is deemed important for better patient outcomes.

However, there is a paucity of data regarding the epidemiology of HNCs from Saudi Arabia. Some studies from certain regions in Saudi Arabia have shown high prevalence rates of HNCs [6]. Although HNCs have bad outcomes, early detection through the implementation of prevention and control programs plays a major role in offering better outcomes and best prognosis [7]. These can be achieved by implementing educational programs as well as raising population awareness [8]. Usually, poor awareness may result in late diagnosis, poor prognosis, and eventually poor treatment outcomes [6]. As a result, we investigated a group of patients with head and neck lesions to evaluate the burden of potential neoplastic lesions in Northern Saudi Arabia.

Review began 02/06/2021

Review ended 02/25/2021

Published 03/03/2021

© Copyright 2021

Alshammari et al. This is an open access article distributed under the terms of the Creative Commons Attribution License CC-BY 4.0., which permits unrestricted use, distribution, and reproduction in any medium, provided the original author and source are credited.

How to cite this article

Alshammari F D, Alharbi S, Bealy M B, et al. (March 03, 2021) Clinicopathological Features of Patients Nominated for Head and Neck Biopsies: A One-Year Series. *Cureus* 13(3): e13666. DOI 10.7759/cureus.13666

Therefore, this study aimed to assess the clinicopathological features of patients nominated for head and neck biopsies.

Materials And Methods

In this study, data regarding head and neck biopsies were retrieved from the Department of Pathology at King Khalid Hospital, Hai'l, Northern Saudi Arabia, during the period from January 2018 to December 2018. The diagnosis of head and neck lesions was confirmed by conventional histopathology. The re-evaluation of the histopathological diagnosis of the tissue samples was completed to confirm the prior diagnosis and to categorize the classification of the lesion into benign or malignant types.

Statistical analysis

Obtained information sets were entered into Statistical Package for Social Sciences (SPSS) Version 16 (SPSS Inc., Chicago, IL, USA). The chi-square test was employed to assess the statistical significance ($p < 0.05$ was considered significant).

Ethical consent

The protocol of this study was established agreeing with the 2013 Declaration of Helsinki, and this study was approved by the Ethics Committee of the College of Medicine, University of Hail, Hai'l, Saudi Arabia.

Results

This series of patients included 64 patients who underwent head and neck biopsies for histopathology diagnosis. The patients included 31(48.4%) males and 33(51.6%) females, aged 3 to 79 years, with a mean age of 34 years.

The initial clinical impression was stated for 50/64 (78.1%) head and neck lesions, 12/64 (18.8%) head and neck cysts, 1/64 (1.6%) keloid, and 1/64 (1.6%) ischemia, as shown in Figure 1.

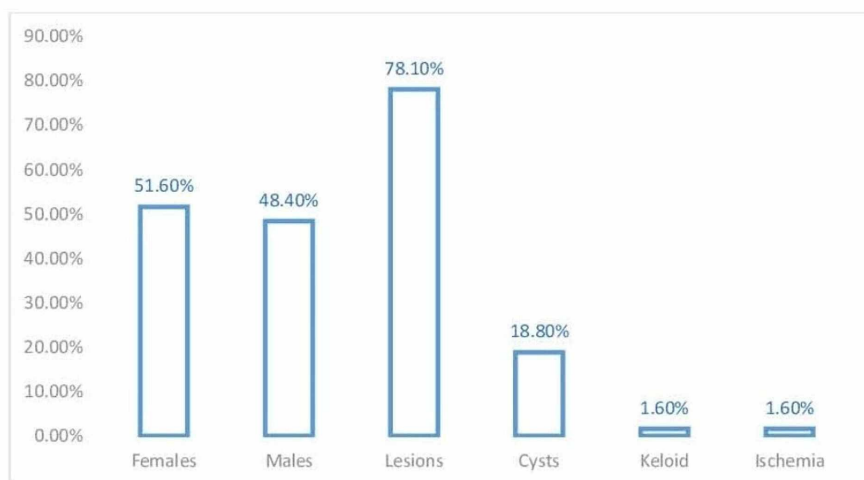


FIGURE 1: Description of patients by sex and initial clinical presentation

Concerning the biopsy's site, most were taken from the nose followed by oral cavity, scalp, ear, face, and eye, constituting 19/64 (29.7%), 15/64 (23.4%), 9/64 (14.1%), 5/64 (7.8%), 4/64 (6.2%), and 3/64 (4.7%), respectively as indicated in Figure 2.

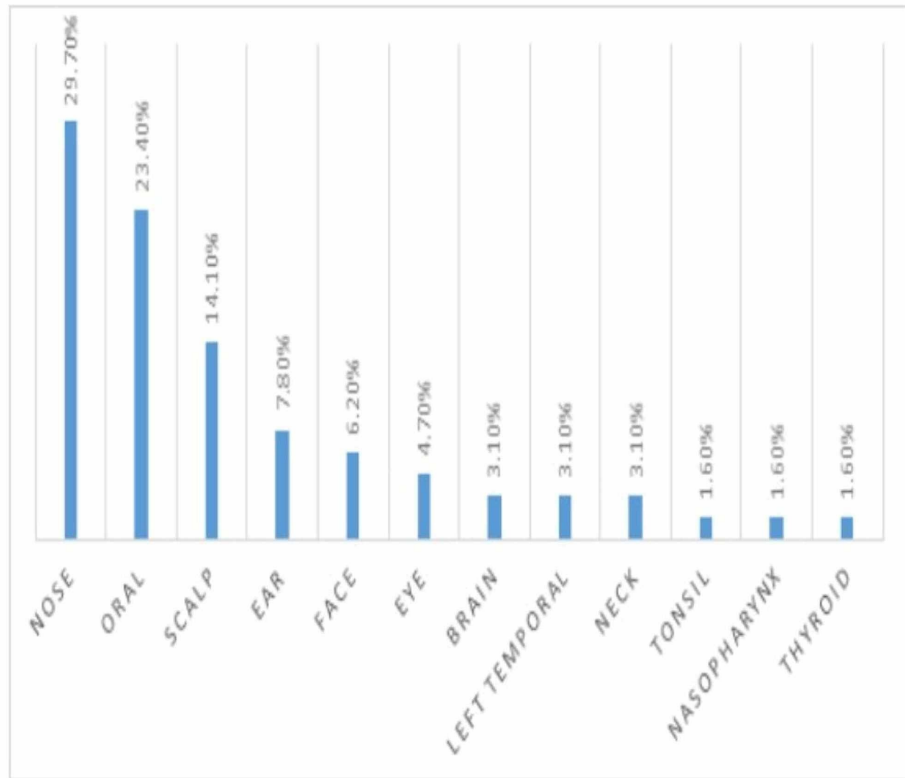


FIGURE 2: Description of patients by biopsy site

A number of these biopsies were characterized as chronic inflammation (20/64 [31.2%]) followed by epidermoid cysts (7 [10.9%]), trichilemmal cysts (6 [9.4%]), fibroepithelial lesions (4 [6.2%]), and others, as indicated in Figure 3.

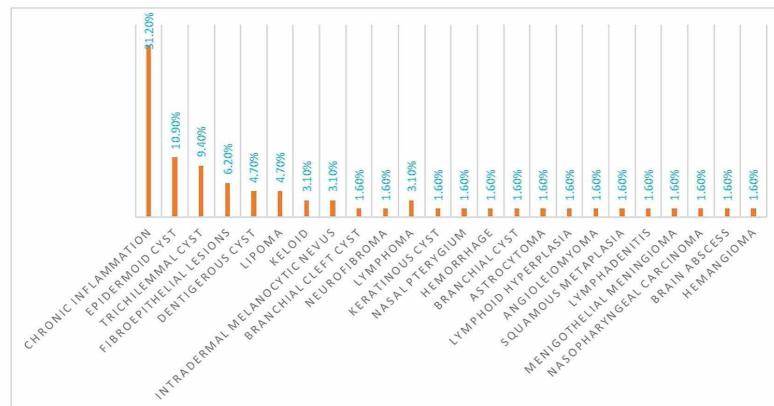


FIGURE 3: Description of patients by diagnosis

The data showing the relationship between diagnosis and sex are shown in Table 1 and Figure 4. Among those diagnosed with chronic inflammation, 12/31 (38.7%) were males and 8/33 (24.2%) were females. Epidermoid cysts were diagnosed in 4/31 (13%) males and 3/33 (9%) females. All cases of lipoma were seen among females.

Diagnosis	Males	Females	Total
Epidermoid cyst	4	3	7
Trichilemmal cyst	3	3	6
Dentigerous cyst	1	2	3
Chronic inflammation	12	8	20
Fibroepithelial lesions	2	2	4
Lipoma	0	3	3
Others	9	12	21
Total	31	33	64

TABLE 1: Diagnosis by sex

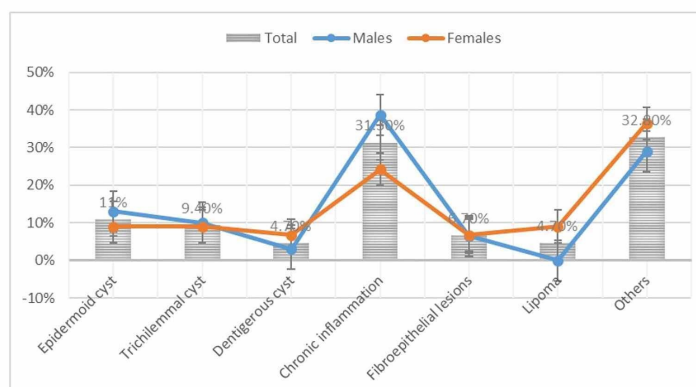


FIGURE 4: Percentages of diagnosis by sex

As summarized in Table 2 and Figure 5, epidermoid cyst, trichilemmal cyst, dentigerous cyst, chronic inflammation, and lipoma was frequently seen in under the age of 29 years, ≥ 50 years, ≤ 18 years, < 29 years, ≥ 40 years, and < 29 years, in this order, representing 4/7 (57%), 3/6 (50%), 2/3 (67%), 9/20 (45%), 4/4 (100%), and 3/3 (100%) patients, respectively.

Diagnosis	≤ 18 years	19-29 years	30-39 years	40-49 years	≥ 50 years	Total
Epidermoid cyst	2	2	1	1	1	7
Trichilemmal cyst	0	1	1	1	3	6
Dentigerous cyst	2	0	0	0	1	3
Chronic inflammation	5	4	3	5	3	20
Fibroepithelial lesions	0	0	0	2	2	4
Lipoma	1	2	0	0	0	3
Others	5	4	3	5	4	21
Total	15	13	8	14	14	64

TABLE 2: Diagnosis by age

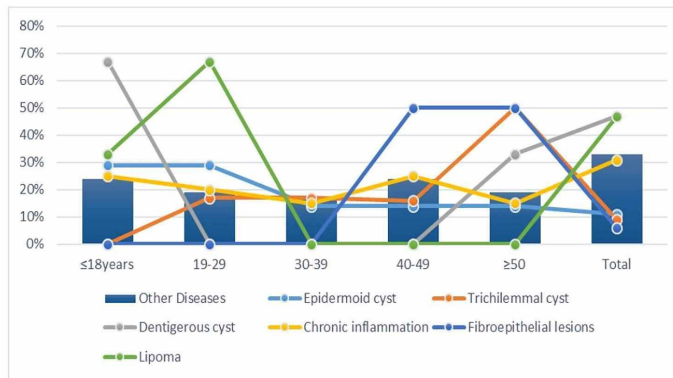


FIGURE 5: Diagnosis by age within the entire pathological condition

The common anatomical sites for epidermoid cyst, trichilemmal cyst, dentigerous cyst, chronic inflammation, and lipoma were oral, scalp, oral, nose, oral, and scalp, in that order, constituting 2/5 (40%), 5/6 (83%), 3/3 (100%), 14/18 (78%), 4/4 (100%), and 2/2 (100%), respectively, as shown in Table 3 and Figure 6.

Diagnosis	Nose	Oral	Scalp	Ear	Face	Total
Epidermoid cyst	0	2	1	1	1	5
Trichilemmal cyst	0	0	5	1	0	6
Dentigerous cyst	0	3	0	0	0	3
Chronic inflammation	14	4	0	0	0	18
Fibroepithelial lesions	0	4	0	0	0	4
Lipoma	0	0	2	0	0	2
Others	5	2	1	3	3	14
Total	19	15	9	5	4	52

TABLE 3: Diagnosis by the most common head and neck sites

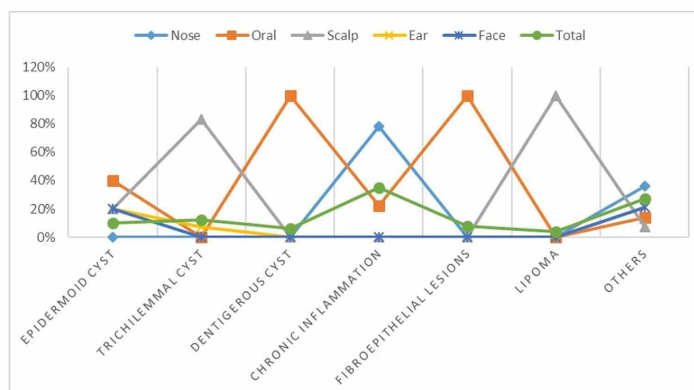


FIGURE 6: Diagnosis by the most common head and neck sites within the entire disease group

As shown in Table 4, most conditions presented in the form of lesions (50/62 [81%]) and few in the form of cysts (12/62 [19%]). Frequent cysts clinical presentations were in epidermoid cyst, trichilemmal cyst, and dentigerous cyst conditions, representing 4/7 (57%), 3/6 (50%), and 2/3 (67%), respectively.

Diagnosis	Cysts	lesions	Total
Epidermoid cyst	4	3	7
Trichilemmal cyst	3	3	6
Dentigerous cyst	2	1	3
Chronic inflammation	1	19	20
Fibroepithelial lesions	0	4	4
Lipoma	0	3	3
Others	2	17	19
Total	12	50	62

TABLE 4: Diagnosis by the most common clinical presentations

Discussion

HNCs represent one of the major health problems. Consequently, in this study, we investigated a series of patients with head and neck lesions to explore their potentiality, as some have pathological features that mimic some potentially neoplastic lesions.

In this study, around 78.1% of the patients presented with clinically non-specific head and neck lesions. As head and neck lesions, most of these lesions happened in the nose followed by oral cavity and scalp, constituting 29.7%, 23.4%, and 14.1%, respectively. Oral and maxillofacial sites are the most frequent sites for head and neck lesions, as widely reported [9].

Around 31.2% of patients in this study were diagnosed with chronic inflammation. Majority of the cases were found in the nose and oral cavity. Several conditions have been identified that induce inflammatory events in head and neck sites, particularly the oral cavity [10]. Moreover, most head and neck potential neoplastic and malignant tumors tend to promote inflammatory reactions [11]. Thus, these findings might be attributed to the lesion potentiality. Moreover, the common exposure of some head and neck sites such as oral and nasal cavities to the inflammatory conditions, besides the possibility of HPV infection can also support these findings [11-13]. Moreover, inflammatory changes were more common among males and those under 30 years. However, there is a lack of data regarding the correlation between head and neck inflammatory changes and age or sex. Most of these inflammatory lesions were seen in the nose (77.8%) followed by oral site (22.2%). The nose is frequently affected by non-neoplastic inflammatory lesions, which are categorized into infectious conditions, chronic rhinosinusitis, and autoimmune conditions [14]. Other inflammatory conditions of the nose include granulomatous vasculitis Wegener's, sarcoidosis, relapsing polychondritis, and nasal perforation [15].

All of the fibroepithelial lesions were found in the oral cavity and among patients over 40 years. Several studies have reported that fibroepithelial hyperplasia is the most frequent oral non-neoplastic lesion, particularly fibroepithelial polyp [16,17]. The link of these lesions in the older population was previously supported in the literature [18].

Around 83% of the trichilemmal cysts were found in the scalp and the remaining 17% in the ear site. Although this cyst can occur in head and neck sites, it is commonly reported to be on the scalp [19].

With regard to the clinical presentation of the patients in this study, 57% of the patients with epidermoid cyst presented with lesions in form of cysts, while the remaining 43% presented in form of lesions. The epidermoid cyst can present in different forms mimicking solid lesions [20] and can occur in different parts of the body [21].

Nevertheless, most (81%) of the benign head and neck lesions present in the form of solid lesions and only 19% present in the form of cysts. However, the everyday practice supports the findings of this study that most head and neck tumors present in the form of solid lesions rather than cysts, particularly inflammatory lesions, which represent the majority in this study.

Although our study provided useful information regarding head and neck benign lesions, it has some limitations including its retrospective setting and lack of some biological indicators due to the absence of direct patient assessment.

Conclusions

Head and neck benign lesions, predominantly inflammatory lesions, are common in Northern Saudi Arabia. Accurate identification of these lesions is important during histopathological diagnosis, as some have pathological features that mimic some potentially neoplastic lesions.

Additional Information

Disclosures

Human subjects: Consent was obtained or waived by all participants in this study. College of Medicine, University of Hail issued approval EC00069. Ethics committee approval letter Date: 10 April 2019 Ref No.: EC-00069/CM/UOH.04/19 Approval of the study protocol: "EC-00069". Title of the Protocol: Clinico-pathological features of one year's series of patients denoted to head and neck biopsies Principle investigator: Dr. Fawaz D Alshammari The Institutional Ethics committee (Ethics Committee College of Medicine UOH) has reviewed and discussed your application to conduct the above mentioned study. The Following documents have been reviewed and approved: List of the all the documents which are submitted to EC Sr. No Name of the Documents Version No. & Date 1 Project Approval Letter -NA- 2 Subject recruitment inclusion & exclusion criteria. yes 3 Application letter for ethics committee 10 April 2019 4 Questionnaire & consent form yes The members of the Ethics committee have approved your proposed protocol at the meeting held on. 04/03/2019. The committee approved the study to be conducted in the presented form. None of the Investigator and co-investigator participating in this study took part in the decision making and voting procedure for this study. The Institutional Ethics committee expects to be informed about the progress of the study, any modification occurring in the course of the study, any revision in the protocol and patient information/informed consent and ask to be provided a copy of the final report This Ethics committee is working accordance to ICH-GCP, guidelines and other applicable regulation. .

Animal subjects: All authors have confirmed that this study did not involve animal subjects or tissue.

Conflicts of interest: In compliance with the ICMJE uniform disclosure form, all authors declare the following: **Payment/services info:** All authors have declared that no financial support was received from any organization for the submitted work. **Financial relationships:** All authors have declared that they have no financial relationships at present or within the previous three years with any organizations that might have an interest in the submitted work. **Other relationships:** All authors have declared that there are no other relationships or activities that could appear to have influenced the submitted work.

References

- Cohen N, Fedewa S, Chen AY: Epidemiology and demographics of the head and neck cancer population . *Oral Maxillofac Surg Clin North Am.* 2018 Nov, 30:381-395. [10.1016/j.coms.2018.06.001](https://doi.org/10.1016/j.coms.2018.06.001)
- Mourad M, Jetmore T, Jategaonkar AA, Moubayed S, Moshier E, Urken ML: Epidemiological trends of head and neck cancer in the United States: a SEER population study. *J Oral Maxillofac Surg.* 2017, 75:2562-2572. [10.1016/j.joms.2017.05.008](https://doi.org/10.1016/j.joms.2017.05.008)
- Song JS, Vallance P, Biron V, Jeffery CC: Epidemiological trends of head and neck Cancer survivors in Alberta: towards improved understanding of the burden of disease. *J Otolaryngol Head Neck Surg.* 2020, 49:46. [10.1186/s40463-020-00443-4](https://doi.org/10.1186/s40463-020-00443-4)
- Kansara S, Bell D, Johnson J, Zafereo M: Head and neck inflammatory pseudotumor: case series and review of the literature. *Neuroradiol J.* 2016, 29:440-446. [10.1177/1971400916665377](https://doi.org/10.1177/1971400916665377)
- Chen CH, Sun CH: Multifocal head and neck amyloidosis as a diagnostic clue of systemic lupus erythematosus (SLE): a case report. *Medicine (Baltimore).* 2019, 98:16830. [10.1097/MD.00000000000016830](https://doi.org/10.1097/MD.00000000000016830)
- Alhazzazi TY, Alghamdi FT: Head and neck cancer in Saudi Arabia: a systematic review . *Asian Pac J Cancer Prev.* 2016, 17:4043-4048.
- Alhazzazi TY: Evaluation of head and neck cancer awareness and screening status in Jeddah, Saudi Arabia . *Asian Pac J Cancer Prev.* 2016, 17:1135-1139. [10.7314/apjcp.2016.17.3.1135](https://doi.org/10.7314/apjcp.2016.17.3.1135)
- Alattas MT: Cancer control priorities and challenges in Saudi Arabia: a preliminary projection of cancer burden. *Gulf J Oncolog.* 2019, 1:22-30.
- Dive AM, Bodhade AS, Mishra MS, Upadhyaya N: Histological patterns of head and neck tumors: an insight to tumor histology. *J Oral Maxillofac Pathol.* 2014, 18:58-68. [10.4103/0973-029X.131912](https://doi.org/10.4103/0973-029X.131912)
- Andersson BÅ, Löfgren S, Lewin F, Nilsson M, Laytragoon-Lewin N: Impact of cigarette smoking and head and neck squamous cell carcinoma on circulating inflammatory biomarkers. *Oncology.* 2020, 98:42-47. [10.1159/000502651](https://doi.org/10.1159/000502651)
- Yang X, Cheng H, Chen J, et al.: Head and neck cancers promote an inflammatory transcriptome through coactivation of classic and alternative NF- κ B pathways. *Cancer Immunol Res.* 2019, 7:1760-1774. [10.1158/2326-6066.CIR-18-0832](https://doi.org/10.1158/2326-6066.CIR-18-0832)
- Zhang Y, Peng C, Tian Z, Cao W, Yang X, Ji T: Inflammatory myofibroblastic tumor in the head and neck-a neoplasm with both tumor features and inflammation. *Oral Surg Oral Med Oral Pathol Oral Radiol.* 2020, 130:316-323. [10.1016/j.oooo.2020.02.008](https://doi.org/10.1016/j.oooo.2020.02.008)
- Devins KM, Tetzlaff MT, Baloch Z, LiVolsi VA: The evolving landscape of HPV-related neoplasia in the head and neck. *Hum Pathol.* 2019, 94:29-39. [10.1016/j.humpath.2019.09.001](https://doi.org/10.1016/j.humpath.2019.09.001)
- Montone KT, LiVolsi VA: Inflammatory and infectious lesions of the sinonasal tract . *Surg Pathol Clin.* 2017,

- 10:125-154. [10.1016/j.path.2016.11.002](https://doi.org/10.1016/j.path.2016.11.002)
15. Helliwell TR: Non-infectious inflammatory lesions of the sinonasal tract. *Head Neck Pathol.* 2016, 10:32-39. [10.1007/s12105-016-0689-6](https://doi.org/10.1007/s12105-016-0689-6)
 16. Sengüven B, Bariş E, Yildirim B, et al.: Oral mucosal lesions: a retrospective review of one institution's 13-year experience. *Turk J Med Sci.* 2015, 45:241-245. [10.3906/sag-1312-9](https://doi.org/10.3906/sag-1312-9)
 17. Monteiro LS, Albuquerque R, Paiva A, de la Peña-Moral J, Amaral JB, Lopes CA: A comparative analysis of oral and maxillofacial pathology over a 16-year period, in the north of Portugal. *Int Dent J.* 2017, 67:38-45. [10.1111/idj.12258](https://doi.org/10.1111/idj.12258)
 18. Monteiro L, Delgado ML, Garcês F, et al.: A histological evaluation of the surgical margins from human oral fibrous-epithelial lesions excised with CO2 laser, diode laser, Er:YAG laser, Nd:YAG laser, electro-surgical scalpel and cold scalpel. *Med Oral Patol Oral Cir Bucal.* 2019, 24:271-280. [10.4317/medoral.22819](https://doi.org/10.4317/medoral.22819)
 19. Tan LA, Harbhajanka A, Kasliwal MK, Nag S, Munoz LF: Giant trichilemmal cyst of the scalp. *Neurol India.* 2016, 64:357-358. [10.4103/0028-3886.177589](https://doi.org/10.4103/0028-3886.177589)
 20. Ben Naftali Y, Shoufani A, Krausz J, Hershko D: Unusual presentation of epidermoid cyst mimicking breast cancer involving the areola-case report. *Int J Surg Case Rep.* 2018, 51:17-20. [10.1016/j.ijscr.2018.08.010](https://doi.org/10.1016/j.ijscr.2018.08.010)
 21. Santos HB, Rolim LS, Barros CC, Cavalcante IL, Freitas RD, Souza LB: Dermoid and epidermoid cysts of the oral cavity: a 48-year retrospective study with focus on clinical and morphological features and review of main topics. *Med Oral Patol Oral Cir Bucal.* 2020, 25:364-369. [10.4317/medoral.23388](https://doi.org/10.4317/medoral.23388)