

CASE REPORT

**OPEN ACCESS**

Full open access to this and thousands of other papers at <http://www.la-press.com>.

## Traumatic Abdominal Wall Hernia: A Case Report of High-Energy Type without Surgical Repair

Hideyuki Ajisaka<sup>1,2</sup>, Seiichiro Okura<sup>1</sup> and Masahiro Wakasugi<sup>1</sup>

<sup>1</sup>Department of Emergency and Critical Care Medicine, Toyama Prefectural Central Hospital, Toyama, Japan.

<sup>2</sup>Department of Surgery, Toyama Prefectural Central Hospital, Toyama, Japan.

Corresponding author email: [h-ajihide@yobouigaku.jp](mailto:h-ajihide@yobouigaku.jp)

---

**Abstract:** Repair of traumatic abdominal wall hernia (TAWH) has been reported to be necessary. Reported here is one case of TAWH without repair. A 27-year-old man was accidentally sandwiched between a rock and a truck and admitted to our emergency department. There was a swelling of 10 cm in the right upper quadrant of the abdomen. The enhanced computed tomographic scan demonstrated a large abdominal wall muscular defect, transverse colon protrusion, and the presence of subcutaneous emphysema at the site. Based on these findings, lacerated transverse colon entrapped in TAWH was diagnosed. The patient underwent emergency laparotomy for laceration of the transverse colon, duodenum and pancreas, and open book fracture of the pelvis. Repair of the hernia was not performed because of the possibility of abscess formation by stool contamination. However, the hernia disappeared and the patient is doing well without recurrence of hernia 16 months after injury.

**Keywords:** traumatic abdominal wall hernia, high-energy type, surgical repair

---

*Clinical Medicine Insights: Case Reports* 2011:4 35–38

doi: [10.4137/CCRep.S7425](https://doi.org/10.4137/CCRep.S7425)

This article is available from <http://www.la-press.com>.

© the author(s), publisher and licensee Libertas Academica Ltd.

This is an open access article. Unrestricted non-commercial use is permitted provided the original work is properly cited.

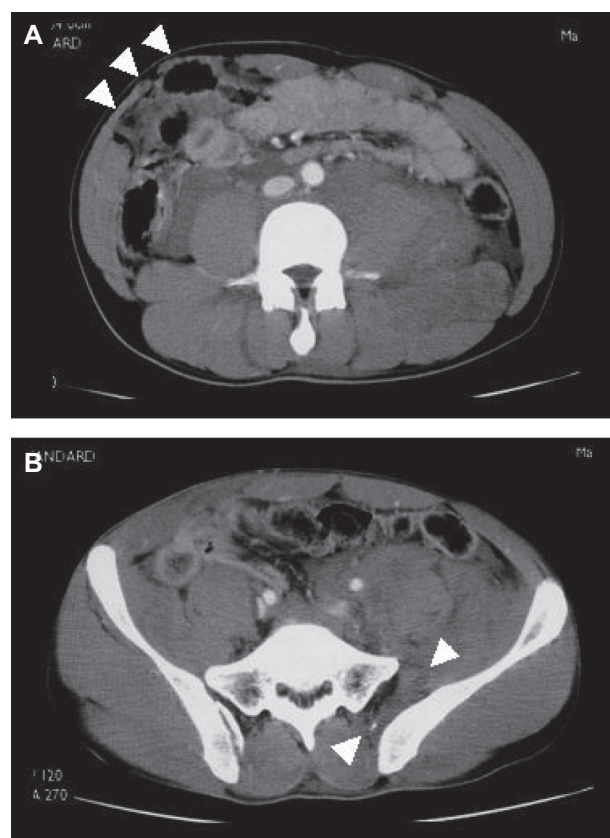
## Introduction

Traumatic Abdominal Wall Hernia (TAWH) is a rare injury. Although the management can vary substantially due to differences in presentation,<sup>1</sup> surgical repair of the hernia has been reported to be necessary sooner or later.<sup>2-4</sup> We describe a case of TAWH that disappeared without the repair.

## Patient

A 27-year-old Japanese man at work was accidentally sandwiched between a rock and a truck. He was admitted to our emergency department with the acute onset of peritoneal signs and shock. On examination, systolic blood pressure was 58 mmHg, pulse was 120 beats/min, and body temperature was 34.9 °C. There was a swelling of 10 cm in the right upper quadrant of the abdomen. The swelling was soft and slightly tender. Laboratory data showed leukocytosis (white blood cell counts 26100/mm<sup>3</sup>), anemia (red blood cell counts 3.80 × 10<sup>6</sup>/mm<sup>3</sup>, serum hemoglobin 11.6 g/dl, hematocrit 33.8%) and acidosis (pH 7.338, base excess -6.1 mmol/l). Following stabilization of vital signs with volume infusion, the patient underwent computed tomographic (CT) scan of the abdomen. The enhanced CT scan demonstrated a large disruption of the abdominal lateral muscles (transversus abdominis muscle, abdominal internal oblique muscle, and abdominal external oblique muscle), transverse colon protrusion, and the presence of subcutaneous emphysema at the site (Fig. 1A). Based on these findings, lacerated transverse colon entrapped in TAWH was diagnosed. Furthermore, CT scan showed liver injury, lacerations of the duodenum and head of the pancreas, and open book pelvic fracture associated with retroperitoneal hematoma (Fig. 1B).

Emergency laparotomy was performed via a midline incision extending from the xiphoid to below the umbilicus. A loop of transverse colon was found to have herniated in a split of peritoneum, muscle and fascia, and was lacerated. The duodenum and head of pancreas were lacerated in the retroperitoneal space. Right hemicolectomy with ileostomy and pancreatoduodenectomy were accomplished (Fig. 2A, B). At this initial surgery, debridement and drainage were performed for TAWH, because of concern about abscess formation due to gross contamination by stool. At the same time, only external fixation for pelvic fracture



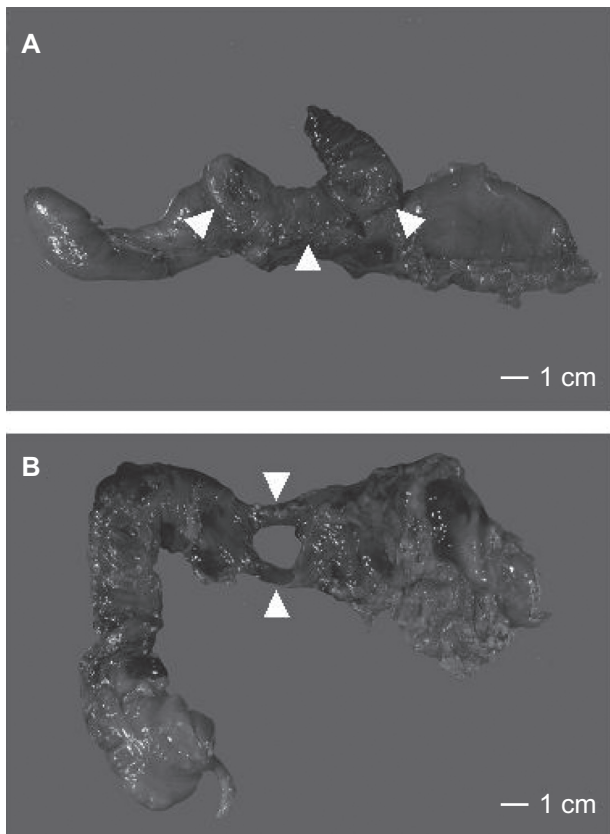
**Figure 1.** CT scan showing lacerated transverse colon entrapped in the traumatic abdominal wall hernia (arrows) (A) and open book pelvic fracture (arrows) associated with retroperitoneal hematoma (B).

was performed, because there was no active bleeding in the retroperitoneal hematoma in the pelvis.

CT scan on the seventh postoperative day showed abscess formation with intramuscular spread in the abdominal wall (Fig. 3). The drainage tube of the hernia could be removed on the fourteenth postoperative day. The patient underwent internal fixation of the pelvic fracture on the nineteenth postoperative day and was discharged in good general condition one month later. Finally repair of TAWH was not performed because TAWH disappeared on physical examination. Signs of the hernia were not confirmed even by the ultrasonography in the outpatient afterwards. The patient is doing well without recurrence of hernia 16 months after injury.

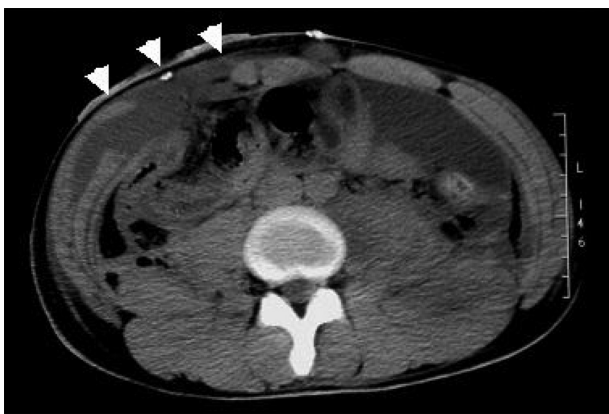## Discussion

Criteria for TAWH were defined in the 1930s and have been subsequently simplified. The essential features include protrusion of abdominal contents through



**Figure 2.** Resected specimen of right hemicolectomy (A) and pancreateoduodenectomy (B). The transverse colon and duodenum were lacerated (arrows).

disrupted abdominal wall musculature and fascia, without skin penetration and without preexisting hernia at the site, following blunt trauma.<sup>5,6</sup> TAWH is thought to be caused by shear stress associated with acute elevation of intraabdominal pressure. The shear stress is transferred to the peritoneum, fascia



**Figure 3.** CT scan on the seventh postoperative day showing abscess formation with intramuscular spread in the abdominal wall (arrows).

and muscle fibers followed by tissue rupture.<sup>3</sup> It was reported that these injuries were mostly located below the umbilicus due to weaker musculature since the rectus sheath is present only above the arcuate line.<sup>4</sup> When traumatic insult to the abdominal wall is mainly due to shearing stresses or tensile forces, intraabdominal injuries are extremely uncommon.<sup>7</sup> However, TAWH is often associated with other injuries that are often critical, because it may follow various types of blunt trauma. TAWHs have been classified on the basis of the mechanism of trauma into low- and high-energy types.<sup>1</sup> Low-energy type is the result of impact on a small blunt object such as a bicycle handlebar or the blunt end of a gardening tool handle. Most of this type does not require emergency laparotomy, because it is almost focal hernia and hardly associated with intraabdominal injuries.<sup>8</sup> On the other hand, most of high-energy type, that is the result of high force such as motor vehicle accidents or falls from height, requires emergency laparotomy. This emergency laparotomy was usually indicated for the treatment of associated intraabdominal injuries and not the hernia itself.<sup>9</sup> Though there are a few reports about disappearance of low-energy type without the surgical repair,<sup>10,11</sup> the repair of high-energy type has been reported to be necessary sooner or later to avoid incarceration and strangulation of the bowel.<sup>2-4</sup> A reapproximation of the muscle layers has been stressed in the repair,<sup>2</sup> while the use of prosthetic mesh was recently reported to prevent occasional recurrence.<sup>3,4</sup> There was also a report that insertion of prosthetic mesh is not advisable due to potential contamination of the hernia.<sup>12</sup> In our case, emergency laparotomy was performed because of not only peritonitis due to laceration of the colon in TAWH but also lacerations of the duodenum and head of the pancreas and open book pelvic fracture, causing septic and hemorrhagic shock. Repair of the hernia was not performed because there was high risk of infection due to laceration of the transverse colon. Thereafter, the hernia disappeared. This origin is unknown but cell regeneration, fibrosis and wound healing may be a concern.<sup>13</sup> This result suggests that it may not always be necessary to repair TAWH. Especially, when peritonitis is associated, debridement and drainage must be prior to repair.



## Conclusion

TAWH is sometimes associated with critical injuries. We should perform CT scan with contrast media to correctly diagnose both TAWH itself and the associated injuries. If critical injuries are associated, treatment of these injuries may be necessary prior to TAWH repair. Furthermore, it may not always be necessary, or advisable, to acutely repair TAWH because of the potential for contamination at the hernia site.

## Disclosure

This manuscript has been read and approved by all authors. This paper is unique and is not under consideration by any other publication and has not been published elsewhere. The authors and peer reviewers of this paper report no conflicts of interest. The authors confirm that they have permission to reproduce any copyrighted material.

## References

1. Lane CT, Cohen AJ, Cinat ME. Management of traumatic abdominal wall hernia. *Am Surg*. 2003;69:73–6.
2. Malangoni MA, Condon RE. Traumatic abdominal wall hernia. *J Trauma*. 1983;23:356–7.
3. Wood R, Ney A, Bubrick M. Traumatic abdominal hernia: a case report and review of the literature. *Am Surg*. 1988;54:648–51.
4. Gill I, Toursarkissian B, Johnson S, Kearney P. Traumatic ventral abdominal hernia associated with small bowel gangrene: case report. *J Trauma*. 1993;35:145–7.
5. Holland J. Hernia from the compensation insurance standpoint. *N Engl J Med*. 1933;209:579–85.
6. McWhorter G. Inguinal hernia due to direct trauma: technique of operation. *Am J Surg*. 1939;45:316–9.
7. Damschen DD, Landercasper J, Cogbill TH, Stolee RT. Acute traumatic abdominal hernia: case report. *J Trauma*. 1994;36:273–6.
8. Netto FA, Hamilton P, Rizoli SB, et al. Traumatic abdominal wall hernia: epidemiology and clinical implications. *J Trauma*. 2006;61:1058–61.
9. Kubalak G. Handlebar hernia: case report and review of literature. *J Trauma*. 1994;36:438–9.
10. Matsuo S, Okada S, Matsumata T. Successful conservative treatment of a bicycle-handlebar hernia: report of a case. *Surg Today*. 2007;37:349–51.
11. Litton K, Izzidien AY, Hussien O, et al. Conservative management of a traumatic abdominal wall hernia after a bicycle handlebar injury (case report and literature review). *J Pediatr Surg*. 2008;43:31–2.
12. Brenneman F, Boulanger B, Antonyshyn O. Surgical management of abdominal wall disruption after blunt trauma. *J Trauma*. 1995;39:539–44.
13. Richard N Mitchell, Ramzi S Cotran. Repair: cell regeneration, fibrosis, and wound healing. Basic Pathology, 6th ed. WB Saunders company, Philadelphia; 1988:47–59.

**Publish with Libertas Academica and every scientist working in your field can read your article**

*“I would like to say that this is the most author-friendly editing process I have experienced in over 150 publications. Thank you most sincerely.”*

*“The communication between your staff and me has been terrific. Whenever progress is made with the manuscript, I receive notice. Quite honestly, I’ve never had such complete communication with a journal.”*

*“LA is different, and hopefully represents a kind of scientific publication machinery that removes the hurdles from free flow of scientific thought.”*

### Your paper will be:

- Available to your entire community free of charge
- Fairly and quickly peer reviewed
- Yours! You retain copyright

<http://www.la-press.com>