

Lung Diseases after Bone Marrow Transplantation

Results of a Clinical, Radiological, Histological, Immunological and Lung Function Study*

H. Link¹, U. Reinhard¹, E. Walter², P. Wernet¹, E.M. Schneider¹, H. Fischbach³, M. Blaurock¹, K. Wilms¹, D. Niethammer⁴, and P. Ostendorf¹

¹ Medizinische Klinik, ² Medizinisches Strahleninstitut, ³ Pathologisches Institut, ⁴ Kinderklinik
Eberhard Karls Universität Tübingen

Summary. The case histories of 72 subsequently treated patients – 44 with acute leukemia, 10 with chronic myeloid leukemia, 16 with severe aplastic anemia and 2 with neuroblastoma – were analyzed after bone marrow transplantation (BMT) with respect to pulmonary diseases. Thirty-eight patients suffered from a total of 51 pulmonary complications, which led to death in 20. Of 13 patients, 3 died of bacterial pneumonia, all of them during granulocytopenia; 2 of 6 patients died of fungal pneumonia and 2 out of 3 of a mixed bacterial-mycotic infection. Adult respiratory distress syndrome (ARDS) led to death in 2 patients. A granulocyte count under 500/ μ l correlated significantly ($P < 0.002$) with the fatal outcome of bacterial, fungal and ARDS pneumonia as well as with bronchitis. Viral pneumonia led to death in 8 of 9 patients; in each there was a significant correlation ($P < 0.05$) with graft-versus-host disease (GvHD). Patients with repeated episodes of pulmonary illness had significantly more chronic GvHD ($P < 0.05$); several of these patients displayed a reduction in helper T cells and an increase in suppressor T cells in the peripheral blood. The natural killer (NK)

cells were reduced and the percentage of activated NK cell level lay between 6% and 69%. B-cells were absent or deficient. These findings explain in part the absence of specific antibody reactivity. Five of these patients also contracted GvHD-associated obstructive bronchiolitis, which did not respond to therapy. Pulmonary infiltrates of unknown origin (including idiopathic interstitial pneumonia) occurred in 8 of the patients (11.1%), with a fatal outcome in 3 patients. Significant changes ($P < 0.05$) in lung function after BMT appeared in the form of reduced vital capacity (VC) increased residual volume (RV) and an increase in RV expressed as the percentage of total lung capacity. Pulmonary diseases were the most common complication and cause of death in our patients after BMT.

Key words: Lung diseases – Bone marrow transplantation – Clinic – Radiology – Histology – Immunology – Lung function

* Supported in part by SFB 120, A2, B1, C1, F2

Abbreviations: AEL=acute erythroid leukemia; AHTCG=anti-human T-cell globulin; ALL=acute lymphoblastic leukemia; AML=acute myeloid leukemia; ARDS=adult respiratory distress syndrome; AUL=acute undifferentiated leukemia; BMT=bone marrow transplantation; CR=complete remission; CML=chronic myeloid leukemia; CMV=cytomegalovirus; Ext.=extensive; GvHD=graft versus host disease; Lim.=limited; PR=partial remission; Rel.=relapse; SAA=severe aplastic anemia; VZV=varicella zoster virus. *Lung function tests:* DLCO=single-breath CO-diffusion capacity; FEV₁=forced expiratory volume in 1 s KCO=Krogh's constant; MBC=maximal breathing capacity; RAW=airway resistance; RV=residual volume; SRAW=specific airway resistance; TGV=thoracic gas volume; TLC=total lung capacity; VC=vital capacity

Pulmonary complications after bone marrow transplantation (BMT) lead to considerable morbidity and mortality. Along with leukemic relapse [24, 77] and graft-versus-host disease (GvHD) [21], they represent one of the most common causes of death after BMT [12, 17]. In addition to bacterial pneumonia, infections are often observed which are caused by opportunistic pathogens, viruses, fungi and protozoa [40, 43]. Interstitial idiopathic pneumonia (IP), where the infectious agent cannot be identified with certainty, occur particularly frequently after high radiation doses (> 8Gy), single-dose total-body irradiation and high dosage rates [6, 11, 65]. Adult respiratory distress syndrome (ARDS) [17] and the related capillary leak syn-

drome [57] can be caused, among other factors [14], by sepsis during granulocytopenia, by histoincompatibility between donor and recipient, and by treatment with cyclosporin A. Obstructive bronchiolitis is frequently correlated with chronic GvHD and has not yet been etiologically classified [5, 36, 37, 50].

This paper presents a study of the clinical, radiological, histological immunological, and functional pulmonary changes in all 72 patients subsequently transplanted in Tübingen and observed from 9 June 1976 to 31 December 1984.

Patients and Methods

Patients

The clinical histories of 72 patients, aged 4–43 (median 17 years), were analyzed. Diagnoses were as follows (for details see Table 2): acute myeloid leukemia (AML): 20 patients in complete remission, 2 in partial remission, 1 in relapse; acute erythroleukemia (AEL): 1 in complete remission; acute lymphatic leukemia (ALL): 13 in complete remission, 5 in relapse; acute undifferentiated leukemia (AUL): 1 in complete remission and 1 in relapse; chronic myeloid leukemia (CML) in the chronic phase: 10 patients; severe aplastic anemia (SAA): 16 patients; stage IV neuroblastoma: 1 patient in complete and 1 in partial remission. A total of 69 patients received bone marrow from siblings who were completely matched in the HLA-A, B, C, DR system and had negative mixed lymphocyte cultures (MLC). In one instance, the patient's mother fulfilled these prerequisites and served as donor (patient no. 4). One patient (no. 2) received marrow from a donor who was identical only in one haplotype. One neuroblastoma patient (no. 50) received autologous bone marrow that had been cytostatically pretreated *ex vivo*.

Pretreatment (Conditioning) and Bone Marrow Transplantation (Fig. 1)

Patients with acute leukemia (AL) and CML were treated on 2 consecutive days with 60 mg cyclophosphamide/kg body weight. The neuroblastoma patients (nos. 50, 66) received 30 mg melphalan twice intravenously. After that, 35 of these patients were administered a total-body irradiation of 10 Gy from a linear accelerator at a dose rate of 7 cGy/min (patients 1, 3, 4, 7, 8, 10–12, 14, 17–30, 32–35, 37, 38, 42, 44, 45, 47–49). The lung dose was limited to 8 Gy. Twenty-one patients with leukemia were given a fractionated total-body irradiation of 6×2 Gy or 5×2.5 Gy, with a maximal lung dose of 10 Gy. From patient 38 on, the radiation dose of the ribs was saturated to 10 Gy with supplementary electron irradiation. For immune suppression 15 patients with SAA each received 50 mg cyclophosphamide/kg body weight on 4 consecutive days, followed by a total-body irradiation with 3 Gy in 6 patients, screening the lung completely. One patient (no. 2) was treated intravenously four times with antithymocytoglobulin for immune suppression, whilst the other SAA patients received buffy coat transfusions from their donors after BMT [60]. The bone marrow was filtered to produce a single-cell suspension; it was incubated with anti-human-T-cell-globulin beforehand, if the cell count was above 2×10^8 mononuclear cells/kg [51]. All patients were decontaminated enterally and topically to prevent infections. From the day of transplantation onwards, the patients were isolated for 4–5 weeks in a laminar air-flow unit (reverse isolation) [70]. All patients received cotrimoxazole (30 mg/kg) p.o. as prophylaxis against infections with *Pneumocystis carinii*. The schedule for conditioning and GvHD prophylaxis can be seen in Fig. 1. The clinical parameters for diagnosing and grading GvHD follow those described by Storb et al. [60].

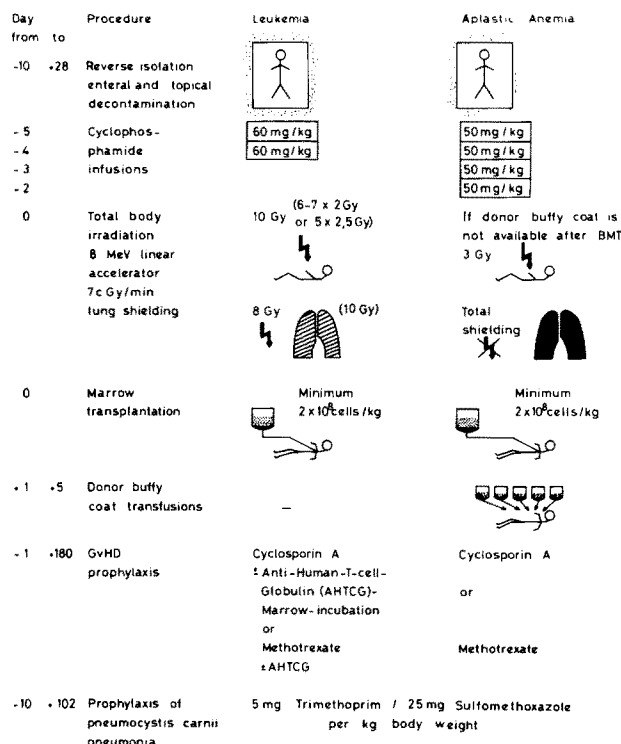


Fig. 1. Protocol for bone marrow transplantation; AHTCG: anti-human-T-cell globulin [51]

Supportive Therapy

The hemoglobin level was kept above 10.0 g/dl with leukocyte- and platelet-poor erythrocyte concentrates and the thrombocyte level over 25,000/ μ l with thrombocyte concentrates. Granulocyte transfusions were indicated only when there was a documented infection or sepsis with fever over 38.5° C and granulocytopenia under 500/ μ l at the same time, when adequate treatment with antibiotics for at least 24 h failed.

Patients 47–72 received 1 ml/kg anti-cytomegalovirus hyperimmune globulin (Cytotect®, Biotest) every 21 days until the 93rd day after BMT, since a controlled, randomized multicenter study in which we had participated had shown that this results in a significant drop in the incidence of CMV pneumonia [35]. From patient 49 on, 4 \times 200 mg acyclovir was given from day –10 until day +100 as prophylaxis against herpes simplex and varicella zoster infections.

X-ray Examinations

Radiograms of the lungs were made from two planes at regular intervals before and after BMT. (During reverse isolation they were only made with an anterior-posterior ray path.)

Cultures and Serological Tests

During reverse isolation, bacterial and mycotic cultures were made at regular intervals and whenever clinically indicated. Virus cultures and standard serological tests for viral and fungal infections were only carried out if these pathogens were suspected clinically.

Histological Studies

Biopsy and autopsy material was examined under a light microscope using the following stains: hematoxylin and eosin, elastic-van Gieson, Masson-Goldner, PAS and silver impregnation.

Bronchoscopy

If indicated, fiber-optic bronchoscopies were carried out; also, bronchial lavage and transbronchial lung biopsies performed to obtain material for cultures and histological studies.

Lung Function Tests

At irregular intervals before and after BMT and depending on the patient's clinical condition, static and dynamic lung volumes were determined using body plethysmography and diffusion capacity was

ascertained. The following parameters were measured with a total-body plethysmograph (Fenyves and Gut, Basel, Switzerland): inspiratory vital capacity (VC); residual volume (RV); thoracic gas volume (TGV); total lung capacity (TLC); RV in % TLC; forced expiratory volume in 1 s (FEV₁); FEV₁ % VC; maximal breathing capacity (MBC); airway resistance (RAW); specific airway resistance (SRAW); single breath CO-diffusion capacity (DLCO); Krogh's constant (KCO).

Using the normal values of Rühle and Mathys [52], the measurements are stated as percentages of the predicted values. For technical reasons, only part of the program could be carried out on some patients.

Surface Markers of Mononuclear Blood and Bone-Marrow Cells

The mononuclear cells of heparinized venous blood or bone marrow aspirate were concentrated by density-centrifuging on Ficoll [69]. The following monoclonal antibodies were used to define the cellular subclasses:

OKT 11 or T 28 or Lyl 3	T-cells (E-rosettes)
OKT 3	Mature and antigen-specific T-cells
OKT 4	Helper-inducer T-cells
OKT 8/Tü 102	Suppressor, cytotoxic T-cells
Leu 8 or H-N 1	Autoreactivity-controlling T-cells
Leu 7 or H-N2	Natural killer cells
Tü 35 or Tü 39 or YD1/63.410 or Ia-011	Ia (HLA-DP and DR) positive cells
Leu 12 or Tü1	B-cells (mature and immature)
Leu M2 or H-M2 or M1-70 or OKM 1	Monocytes

Classification of Pulmonary Complications

1. Bacterial Pneumonia (B)

This diagnosis was based on cultural or histological identification of the pathogen in bronchial secretions, sputum or lung tissue. In some patients, the diagnosis was indicated by the clinical course, for example, by fever, productive cough, dyspnea, rales and the regression of pulmonary infiltrates after treatment with antibiotics [72].

2. Fungal Pneumonia (F)

Diagnosis was made after cultural or histological proof of fungus in bronchial secretions or a rise of 2 levels in serum titer and simultaneous clinical and radiological evidence.

3. Pneumonia Caused by Bacteria and Fungus (BF)

Evidence of (1) and (2) are found simultaneously at the onset of the infection.

4. Interstitial Viral Pneumonia (V)

This diagnosis was made if viruses could be cultured from lung tissue or if histological changes typical of viruses were found, for example, cytomegalovirus (CMV). A varicella zoster (VZV) pneumonia was diagnosed on the basis of the typical skin rash and a simultaneous rise of more than 2 titer levels.

5. Pulmonary Infiltrates of Unknown Origin (IP/IF)

If other causes had been ruled out, this diagnosis was made as proposed by Meyers et al. [40] in a large study of 525 patients with nonbacterial and nonfungal pulmonary infiltrates after allogeneic marrow grafting. There were two quite different clinical courses: one (IP) with rapid clinical deterioration within hours, with fever, dry unproductive cough, dyspnea, absence of rales, cyanosis and hypoxia, showing typical interstitial pulmonary infiltrates with homogeneous opacity on the radiogram; and the other (IF) with radiologically documented nonspecific infiltrates only partially correlated with discrete clinical symptoms and never leading to death.

6. Mycoplasma Pneumonia (M)

Clinical or radiological evidence of pneumonia and a rise of more than 2 titer levels.

7. Bronchitis (BR)

As in definition 1, but with the infection predominantly affecting the bronchi.

8. Obstructive Bronchiolitis (O)

This illness is correlated with acute or chronic GvHD [37, 50] and characterized by increasing dyspnea, coughing, cyanosis, pulmonary emphysema, a decrease in VC, FEV₁ and DLCO and an increase in RV and SRAW; trapped air is evident.

Histological studies showed a typical bronchiolitis obliterans.

9. Adult Respiratory Distress Syndrome (A)

This histological designation was chosen for the pulmonary changes in which typical hyaline membranes, interstitial edema and vascular thrombosis were found, although no pathogen could be identified. The typical clinical picture was of increasing dyspnea with the development of global respiratory insufficiency in four phases.

Causes of Death

Several patients contracted more than one of these diseases, such as pneumonia, sepsis, enteritis or GvHD, either simultaneously or in rapid succession. In such instances, the disease which was decisive for the lethal outcome was stated as the cause of death. When GvHD and viral pneumonia occurred together, for example, the pulmonary disease was defined as the cause of death.

Statistical Tests

Four-fold tables were evaluated using the four-fold chi-square test and Fisher's Exact Test. All *P* values were determined using Fisher's Exact Test. Groups means were compared using Student's *t*-test with a significance level of 5% for the two-sided test.

Results

In 38 (53%) of 72 transplanted patients, there were 51 episodes of pulmonary complications, leading to death in 20 (28%) patients. Table 1 shows the distribution by diagnosis. In Table 2, the pulmonary complication, the pathogen, the radiological and histological findings, the cause of death and the intensity of GvHD are given for each patient.

Other causes of death were as follows: 10 leukemia patients died of leukemic relapse, 2 leukemia patients and 1 SAA patient of septic complications during GvHD and 1 SAA patient of an intra-abdominal aneurysmal hemorrhage.

1. Bacterial Pneumonia (B)

Sixteen bacterial pneumonias were observed in 13 patients with a fatal outcome in 3 patients. The following pathogens were isolated: *Pseudomonas aeruginosa* (twice), *Klebsiella* (twice), *Proteus* (twice), *Acinetobacter lwoffii* (once), β -hemolytic *Streptococci* (once), and a mixed flora of *Pseudo-*

Table 1. Total number of transplanted patients and of patients with pulmonary complications after BMT; total number of episodes of observed pulmonary complications and subsequent mortality

Diagnosis	Acute leukemia in remission <i>n</i>	Acute leukemia in relapse <i>n</i>	CML <i>n</i>	SAA <i>n</i>	Neuroblastoma IV <i>n</i>	Total number <i>n</i>
Total numbers of patients	37	7	10	16	2	72
Patients with pulmonary complications	21	4	4	7	2	38
Episodes of pulmonary complications	30	4	5	10	2	51
Death from pulmonary complications	8	4	3	4	1	20

monas, *Klebsiella* and *Enterobacter* (once). In 7 pneumonias no pathogen could be identified. Three patients died in a very poor general condition during granulocytopenia (nos. 1–3). The typical pneumonic infiltrates were not visible on the radiograms until granulocyte transfusions were given or the patients' own granulocyte production began. In patients 11 and 12, who had contracted a bacterial pneumonia during the primary leukemia therapy long before BMT, the same species of bacteria (*P. aeruginosa* and *Proteus mirabilis*, respectively) were isolated as the cause of the pneumonia after BMT.

2. Fungal Pneumonias (F)

Candida albicans and *Torulopsis glabrata* were each found once (patients 29 and 34; Fig. 2a).

Of the four patients suffering from *Aspergillus* pneumonia, two (nos. 31, 37) died after a fulminant spread of the infection. Another patient (no. 16) died later of a pulmonary hemorrhage in an *Aspergillus abscess*. There was great variation in the radiographic findings (Fig. 2b and c). None of *Aspergillus* pneumonias could be established histologically before biopsy (patients 16, 21) or autopsy (patients 31, 37) (Fig. 2d).

3. Bacterial and Fungal Pneumonias (BF)

In three patients (nos. 4, 5, 14) it had to be assumed that bacteria and fungi were the joint causes of the infection. Only one patient (no. 14) could be treated successfully (see Table 2).

4. Interstitial Viral Pneumonia (V)

A total of nine viral pneumonias (12.5%) developed, eight of which led to death. Five patients (nos. 12, 28, 33, 38, 44) died of CMV pneumonias, which were all suspected clinically but yielded negative serological tests and could only be proven post mortem either histologically or by culturing

viruses. Typical radiological and histological findings are depicted in Fig. 3a and b. Three patients (nos. 9, 11, 47) contracted a fatal VZV pneumonia following a typical herpes zoster generalisatus. Clinically, all of the patients had high fever, rapidly increasing dyspnea and a slight dry cough. Usually, only a few nonspecific rales and sharper breath sounds could be auscultated. An attempt to treat CMV pneumonia with acyclovir and anti-CMV-hyperimmune serum proved as unsuccessful as the attempted treatment of VZV pneumonia (patient no. 11) with α -interferon. All of the patients but one (no. 47) were administered artificial respiration because of rapidly progressing global respiratory insufficiency, at the end with O₂ concentrations of over 60% and positive respiration pressures of up to 60 cm H₂O. Four patients (nos. 9, 12, 28, 38) also had an obstructive bronchiolitis (see below page 605), which made mechanical respiration considerably more difficult because lung and cutaneous emphysemas and pneumothorax developed (Fig. 5a).

Histologically, typical CMV inclusion bodies were found post mortem in pneumonic tissue from another patient who had died of sepsis during GvHD (pat. 25).

5. Pulmonary Infiltrates of Unknown Origin (IP/IF)

These kinds of pneumonia were diagnosed in eight (11.1%) patients, seven with leukemia in remission (nos. 7, 10, 17, 23, 27, 53, 68) and one with neuroblastoma (no. 66). The radiological findings (Fig. 4) showed an increase in interstitial markings distributed over the lung but concentrated in the lower areas. Three of the patients (nos. 10, 23, 68) died of the severe form of this pneumonia. All of the others had the clinically mild form. One further patient (no. 17) developed a fatal adenoviral encephalitis during or after the pneumonia; no histological evidence of interstitial pneumonia could be found post mortem.

Table 2. Synopsis of clinical, microbiological, radiological and histological data of lung diseases after BMT

Patient no. Diagnosis	GvHD		Age (years) Sex (M/F)	Survival (months) as of 31.12.84	Cause of death	Pulmo- nary compli- cation	Month of onset	Pathogen	Chest radiogram	Histology
	Acute (0-IV°)	Chronic (0/Lim./Ext.)								
1 ALL Rel.	-	-	21 M	0.5	B+A	B+A	0.2	?	Poorly defined spotty alveolar infiltrates	ARDS; pneumonia with granulocytes
2 SAA	-	-	34 F	2.6	B+A	B	1.4	<i>Pseudomonas aeruginosa</i>	Faint opacity located in right supradiaphragmatic lung	-
3 AML Rel.	-	-	34 M	0.4	B+	B	0.3	<i>Klebsiella</i>	Spotty and patchy infiltrates, poorly defined; possibly also edema	ARDS; necrotizing bronchiolitis
4 AML Rel.	-	-	20 M	0.7	BF	BF	0.3	<i>Klebsiella</i> , <i>Escherichia coli</i> , <i>Candida albicans</i>	Distinct opacity in right lung	Nonreactive necrosis; hemorrhage
5 SAA	IV°	-	24 M	1.1	GvHD, sepsis	B	0.2	?	Pulmonary infiltration of reticular pattern, later intra-alveolar infiltration too	ARDS, nonreactive necrosis
6 SAA	-	-	10 M	0.4	A	A	0.3	?	Spotty, poorly defined alveolar infiltrates, right lower lobe	-
7 ALL 2nd CR	0	0	11 M	>64.0		IP	3.0	?	Patchy, poorly defined intra-alveolar infiltrates, right upper lobe	Hemorrhage, edema; macrophages and granulocytes in alveoli, acute bronchitis
8 AML 2nd CR	I°	0	7 M	31.1	Relapse	B	4.4	?	Spotty inhomogeneous, i.e., intra-alveolar infiltrates in the entire right lung	ARDS
9 SAA	I°	Ext	12 m			O	6.3	<i>Ps. aeruginosa</i>	Pulmonary infiltrates of interstitial pattern	-
10 AML 1st CR	0	0	19 F	10.1	V	O+V	9.3	<i>Varicella zoster</i>	Poorly defined spotty alveolar infiltrates, right lower lobe	-
11 AML 1st CR	I/II°	Ext.	25 F	2.1	IP	IP	0.8	?	Emphysema; Interstitial infiltrates (reticular-nodular pattern)	-
						B	0.3	<i>Ps. aeruginosa</i>	Pulmonary infiltrates of reticular pattern	-
						V	5.4	<i>Varicella zoster</i>	Patchy, poorly defined intra-alveolar infiltrates right middle and lower lobe	-
						V+B	5.8	<i>Varicella zoster</i> , <i>Klebsiella</i> <i>Ps. aeruginosa</i> , <i>Enterobacter cloacae</i>	Reticular and alveolar spotty infiltrates in both entire lungs	-
				7.0	V+B	V+B				

Table 2 (continued)

Patient no. Diagnosis	GvHD		Age (years) Sex (M/F)	Survival (months) as of 31.12.84	Cause of death	Pulmo- nary compli- cation	Month of onset	Pathogen	Chest radiogram	Histology
	Acute (0-IV°)	Chronic (0/Ext.)								
28 CML	I°	Ext.	15 F			O	3.5	Non-hemolytic streptococci; <i>C. albicans</i>	Reticular and patchy infiltrates in apex areas of both lungs	—
				4.9	V	O+V	3.8	CMV	Increasing reticular pattern, i.e. interstitial infiltrates; peribronchial opacities, pulmonary emphysema, cutaneous and mediastinal emphysema, (Fig. 5a)	Necrotizing and obliterative bronchiolitis, focal interstitial fibrosis focal atelectasis, CMV, edema
29 AML 3rd CR	I°	0	24 F	>35		BR	0.9	<i>Ps. aerug.</i>	Peribronchially located inhomogeneous opacities	—
						F	2.3	<i>C. albicans</i>	Homogeneous opacity retrosternally located; tomogram: no calcification, 2 cm diam., partially surrounded by air, no sharp demarcation	—
31 SAA	—	—	5 M	0.3	F	F	0.16	<i>A. fumigatus</i>	Opacity of the right lung, with reticular pattern areas; parahilar edema in the left lung, (Fig. 2c)	—
32 ALL 2nd CR			25 F	>32		BR	3.2	?	Discrete peribronchial infiltrates, basal area of right lung	—
33 ALL 3rd Rel.	IV°	Ext.	26 F	2.6	V	V	1.8	CMV	Reticular, i.e. interstitial infiltrates, later also intra-alveolar infiltrates, in lower lobes, bilateral	—
34 AML 1st CR	I°	0	20 M	>30		F	2.4	<i>Torulopsis glabrata</i>	Reticular pattern, i.e., interstitial infiltrates	—
37 AML 2nd CR	0	—	30 F	0.8	F	F	0.15	<i>A. fumigatus</i>	Reticular pattern, i.e., interstitial infiltrates in right lung more than left	Nonreactive necrosis with <i>A. fumigatus</i> ; ARDS
38 AML 1st CR	II/III°	Ext.	43 F			V	1.7	CMV, <i>Serratia marcescens</i> , <i>Citrobacter freundii</i>	Transitory interstitial infiltrates, especially left upper area	Bronchiolitis obliterans, focal indurative atelectasis, interstitial fibrosis; (Fig. 5b) ARDS
				4.8	V	V+O	4.0	Enterococci	Poorly defined interstitial infiltrates; mediastinal, cutaneous, cervical emphysema	—

39	SAA	I°	0	8 M	>26	B	1.2	<i>Acinetobacter lwoffii</i>	Distinct interstitial infiltrates of reticular pattern	—
44	AML 1st CR	I/II°	—	29 F	1.9	V	0.6	CMV	Continuously progressive interstitial infiltrates of reticular pattern, (Fig. 3 a)	CMV, ARDS
45	ALL 2nd CR	0	0	4 F	5.0	Hemolytic uremic syndrome	0.6	<i>Mycoplasma pneumoniae</i>	Intraalveolar, poorly defined infiltrates	—
47	CML	II°	Ext.	22 M		B	7.0	β -Hemolytic streptococci	Poorly defined patchy infiltrates, positive bronchopneumogram	—
50	Neuro-blastoma PR	0	—	10 M	0.8	A	0.4	?	Interstitial infiltrates (reticulonodular pattern)	Organizing pneumonia, bronchiolitis obliterans, herpes-virus inclusions
53	AML 2nd CR	0	Ext.	17 M	9.6	Relapse	6.0	?	Translucent opacity, sharper definition of vessels, congestion with edema; poorly defined spotty infiltrates, positive bronchopneumograms	ARDS; macrophages in alveoli
63	SAA	I°	0	20 M	>7.2	B	7.3	?	Poorly defined interstitial spotty infiltrates, peripheral lung areas, right side > left	—
65	CML	I°	0	20 M	>5.5	B	4.6	?	Poorly defined patchy alveolar infiltrates, left lower lobe	—
66	Neuro-blastoma 2nd CR	IV°	—	4 F	>5.0	IF	0.5	?	Poorly defined spotty alveolar infiltrates, right lower lobe	—
68	ALL 3rd CR	I°	—	6 F	1.5	IP	1.5	?	Interstitial infiltrates of reticular pattern	—
									Opacity of both lungs with reticular pattern areas	—

Definition of pneumonias: B = bacterial; F = fungal; BF = bacterial and fungal; V = viral; IP/IF = infiltrates of unknown origin; M = *Mycoplasma pneumoniae*; BR = Bronchitis; O = Obstructive bronchiolitis; A = adult respiratory distress syndrome (ARDS); “—” = not evaluable

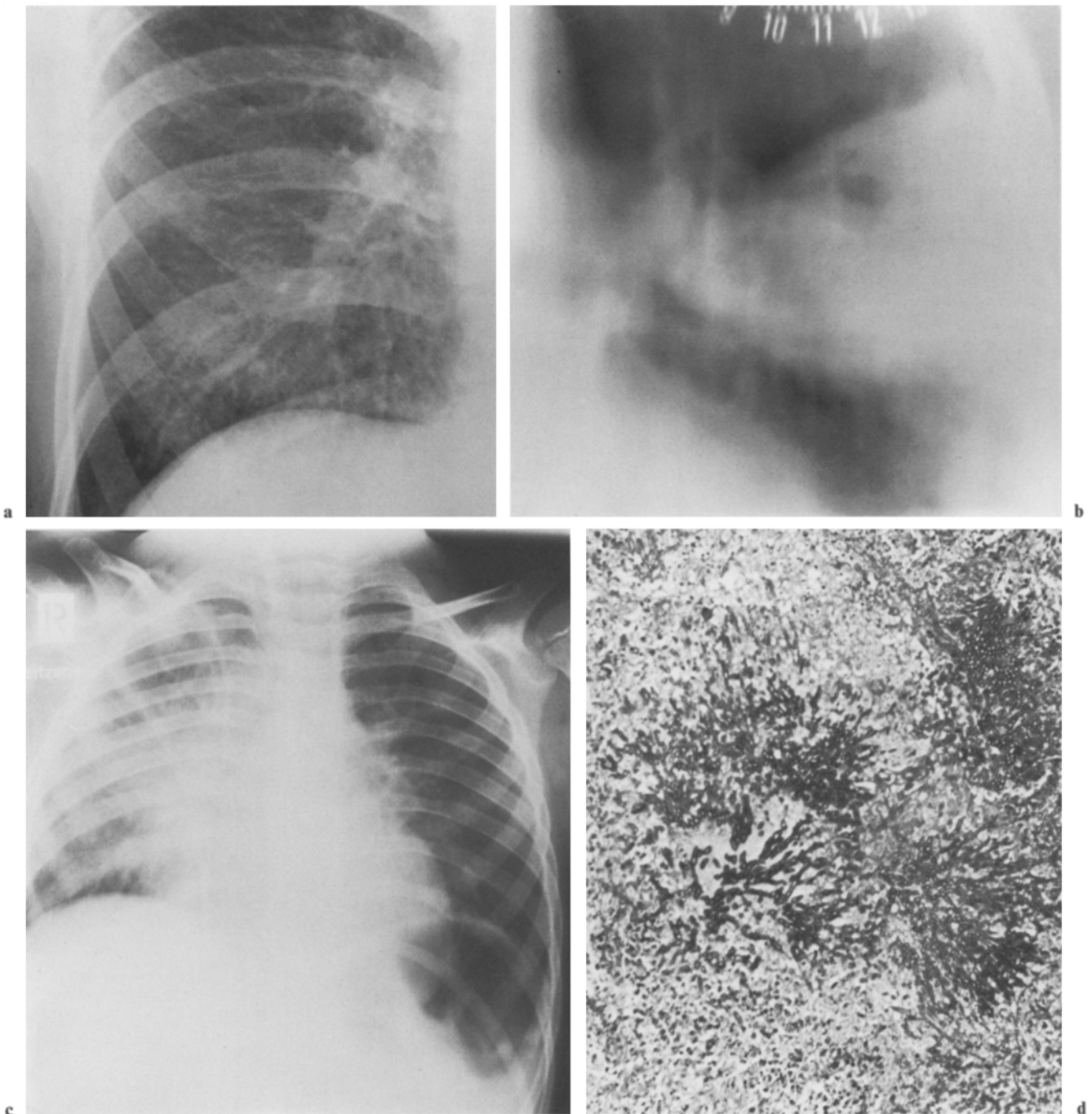


Fig. 2a-d. Fungal pneumonias, **a** Pneumonia caused by *Torulopsis glabrata*, pattern as in interstitial pneumonitis (patient no. 34). **b-d** Pneumonia caused by *Aspergillus fumigatus*: **b** abscess formation with connection to the bronchial tree (patient no. 21); **c** homogeneous opacity of the lung during the time of granulocytopenia 9 days after BMT (patient no. 31); **d** histological findings show nonreactive necrosis around *A. fumigatus*. PAS, $\times 160$ (patient no. 12)

6. *Mycoplasma Pneumonia (M)*

One patient (no. 45) developed fever of up to 41°C , cough, slight dyspnea and uncharacteristic pulmonary infiltrates. The titer rise against mycoplasma led to the diagnosis and treatment with erythromycin proved successful. The patient died

4 months later from the sequelae of an etiologically unclear hemolytic uremic syndrome.

7. *Bronchitis (BR)*

Four patients (nos. 25, 26, 29, 32) developed acute bronchitis, which might have been one of the con-

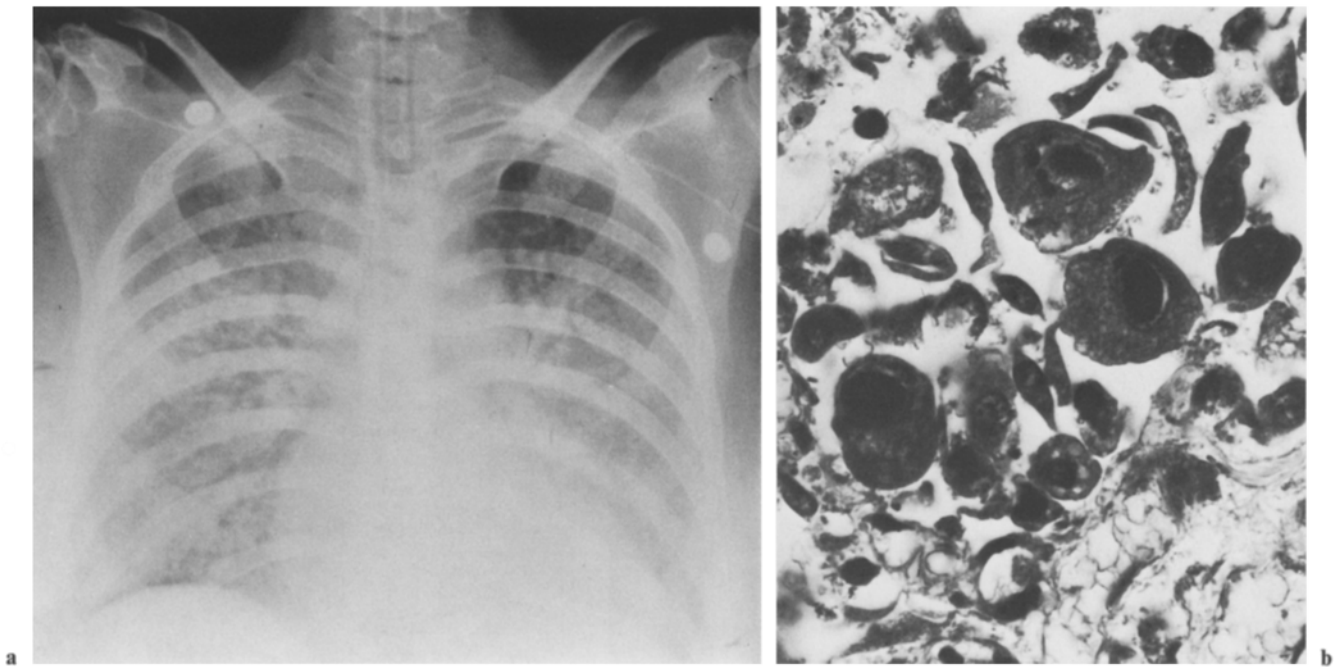


Fig. 3. a Radiographic pattern of CMV pneumonia (patient no. 44); **b** typical CMV inclusions in histology (patient no. 12). Masson Goldner, $\times 800$

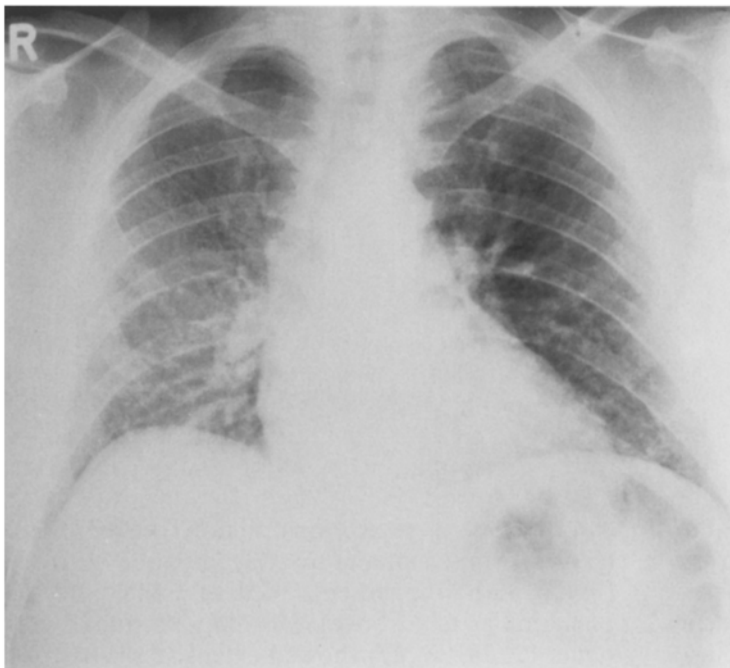


Fig. 4. Severe form of pulmonary infiltrates of unknown origin (patient no. 23)

tributing causes of death in one patient (no. 26). *Ps. aeruginosa* and *Staph. epidermis* were each identified once as the pathogen (patients 25, 26) but the pathogen could not be established in the other patients.

8. Obstructive Bronchiolitis (O)

Four patients (no. 9, 12, 28, 47) with chronic GvHD and one patient (no. 38) with acute GvHD contracted obstructive bronchiolitis in the period

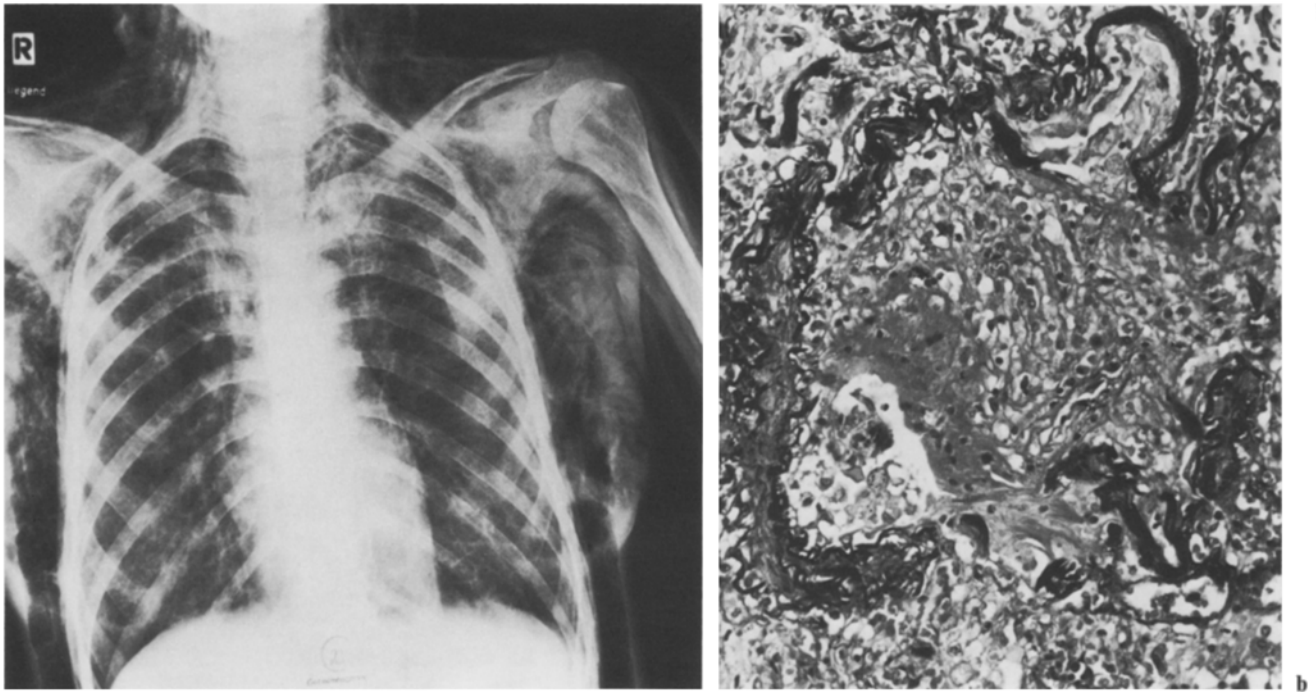

Fig. 5a, b. Obstructive bronchiolitis during chronic GvHD. **a** Chest radiogram with emphysema, pneumothorax and cutaneous emphysema (patient no. 28); **b** necrotizing and obliterative bronchiolitis (patient no. 38). Elastica van Gieson, $\times 200$

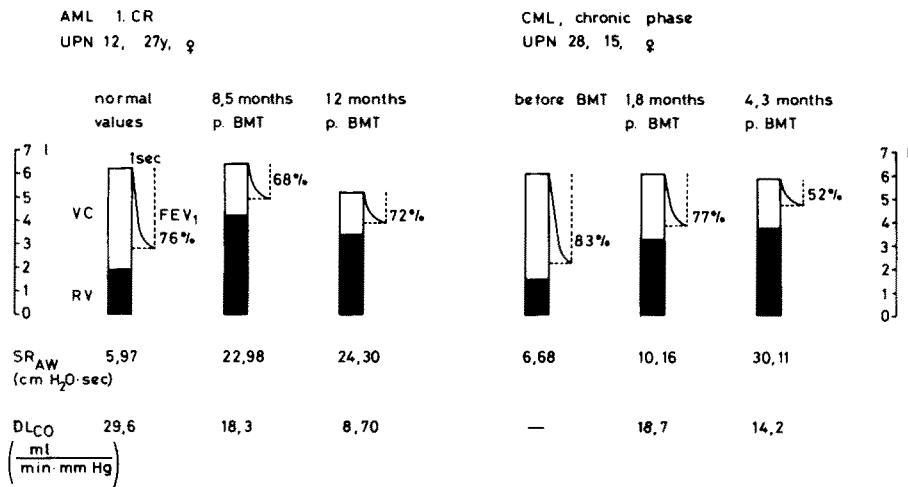


Fig. 6. Lung function tests of two patients with obstructive bronchiolitis

between 1.8 and 8 months after BMT. The radiograms of three of the patients showed a pronounced pulmonary emphysema and recurrent pneumothorax with distinct cutaneous emphysema (Fig. 5a). The capillary pO₂ values fell to 50–70 mm Hg. *Ps. aeruginosa* (patient no. 9), *Prot. mirabilis* (patient no. 12), nonhemolytic streptococci (patient no. 28), *Serratia marcescens*, *Citrobacter freundii* and *enterococci* (patient no. 38) were detected in the sputum or bronchial secretion cultures.

The lung function results indicated pulmonary

emphysema, a severe obstruction of the bronchioles, trapped air and severely impaired diffusion (Fig. 6). All five patients died of CMV or VZV pneumonias (see above). Histological studies (patients 12, 28, 38, 47) showed extensive obstruction of the lumina of the small bronchi and bronchioles by nonspecific granulation tissue or by fibrous scar tissue (Fig. 5b). The bronchial and bronchiolar walls were so severely inflamed that they were often barely recognizable as such. The lung tissue was scarred over extensive regions (indurated atelectasis) and was emphysematous in other parts.




Fig. 7. Occurrence of 51 episodes with pulmonary complications in 38 patients in relation to diagnosis and time after BMT; B = bacterial pneumonia, F = fungal pneumonia, BF = bacterial and fungal pneumonia, V = viral pneumonia, IP/IF = pulmonary infiltrates of unknown origin, M = pneumonia by mycoplasma pneumoniae, BR = bronchitis, O = obstructive bronchiolitis, A = adult respiratory distress syndrome (ARDS); □ Acute leukemia in remission, △ Acute leukemia in relapse, ◇ chronic myeloid leukemia, ○ Severe aplastic anemia, ▽ Neuroblastoma. Closed symbols denote fatal complications

9. Adult Respiratory Distress Syndrome – ARDS (A)

Two patients (nos. 6 and 50) contracted a highly febrile (>40° C) pneumonia with rapidly increasing dyspnea during bone marrow aplasia 5 and 13 days after BMT, respectively. The radiograms did not reveal interstitial and alveolar infiltrates until 2–4 days after the onset of the disease. The patients died 2 days and 10 days later, respectively. Histology revealed an interstitial and alveolar edema, hyaline membranes, fibrin thromboses and thrombocyte aggregates in the small vessels. No pathogens could be found. In three other patients (nos. 1–3) who died after bacterial pneumonias during granulocytopenia, the histological diagnosis of ARDS could only be made post mortem, as was also true in one patient (no. 37) with *Aspergillus* pneumonia and two patients with CMV pneumonia (no. 38, 44).

Correlation with Granulocyte Count

Since the risk of infection increases when the granulocyte count drops below the critical value of 500/μl [45], we recorded how many bacterial, fungal and ARDS-type pneumonias and bronchitis cases resulted in death with and without granulocytopenia. Of 12 episodes of these complications, 8 resulted in death with granulocyte levels under 500/μl, but only 1 of 18 when the granulocyte count was above 500/μl (significant difference, $P=0.002$).

Correlation Between Primary Disease and Pulmonary Complication

The risk of viral interstitial pneumonia in patients surviving more than 14 days was 8:43 with leukemia and 1:13 with SAA ($P=0.75$, not significant).

The probability of these patients developing an idiopathic interstitial pneumonia was 6:45 with leukemia and 0:14 with SAA (no significant difference; $P=0.44$). There was no correlation between smoking or drinking alcohol and the occurrence of certain lung diseases.

Correlation with Graft-versus Host Disease

Only the 60 patients who were at risk of developing GvHD were taken into account. Therefore, the 12 patients without bone marrow take and those undergoing syngeneic or autologous BMT were excluded, as well as those who died within 14 days after BMT. None of the 35 patients without severe acute (>I°) or chronic GvHD contracted a virus pneumonia. In contrast, there were 9 viral pneumonias among the 24 patients with acute GvHD II–IV° or chronic GvHD ($P<0.001$, significant difference). Obstructive bronchiolitis was likewise observed only with acute GvHD II–IV° or chronic GvHD. There was no positive or negative correlation between bacterial, fungal, mixed pneumonia or pneumonia of unknown origin and GvHD.

Nine patients suffered two or more episodes of pulmonary complications each (patients 5, 9, 11, 12, 25, 28, 29, 38, 47). Only one of them (no.

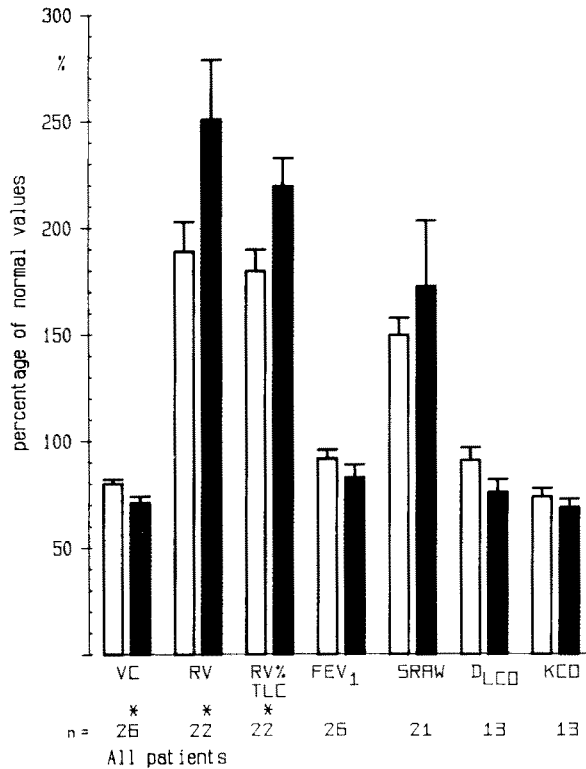


Fig. 8. Comparison of lung function tests before and 1–6 months after BMT in patients with leukemia and severe aplastic anemia. □ before BMT, ■ after BMT, mean values with SEM, * significant difference

29) had neither acute GvHD $>I^{\circ}$ nor chronic GvHD (significant difference, $P=0.01$). All 8 patients with multiple pneumonias during GvHD died, 7 of them of pulmonary diseases.

Time Dependence of Pulmonary Complications after BMT

After a peak in the first 4–8 weeks, the frequency of pulmonary complications decreased (Fig. 7), but pneumonias were observed as long as 58 weeks after BMT (Table 2). Such an incidence has changed increasingly as a result of more rigorous patient selection, fractionated radiation therapy and the use of cyclosporin A instead of methotrexate, so that fatal pneumonias in the first 4 weeks are now rare. In two patients (nos. 63, 65), chronic bronchitis must be assumed to be the cause of the pneumonia.

Lung Function Tests

We were able to examine 26 patients after BMT. The test results are shown in Fig. 8 for the period before BMT and the period from 1–6 months after BMT.

Vital capacity (VC) and Krogh's constant (KCO) were below the normal range even before BMT, while residual volume (RV), RV % total lung capacity (TLC) and specific airway resistance (SRAW) were elevated.

After BMT there were significant changes: VC was lower and RV higher, as was RV % TLC. The other parameters examined did not change significantly.

Profile of the Surface Markers on Mononuclear Blood and Bone-Marrow Cells

In Fig. 9 the distribution of mononuclear cells that were identified with monoclonal antibodies is shown. Patients 9, 11 and 47 had a VZV pneumonia; the others had CMV pneumonia. In five evaluable cases the number of helper/inducer T cells in the blood was reduced, while the number of suppressor T cells was raised (patients 12, 25, 28, 38, 44). Similar results were obtained from the bone marrow (patients 25, 28, 38). The autoreactivity-controlling T-cells in the blood were reduced (patients 12, 25, 44). Except in patient no. 44, the number of NK cells lay below the normal range. Activated NK cells were low in the blood of five patients (nos. 12, 25, 28, 44, 47). In five of the patients examined no B-cells could be detected in the blood (nos. 9, 11, 25, 33, 44) and in another only 2% (patient no. 47).

All of these patients had acute or chronic GvHD at the time of marker determination and of pneumonia.

Discussion

Gram-negative bacteria were the primary cause of pneumonias during granulocytopenia in the early post-transplant period. Patients who were transplanted in advanced leukemic relapse or, with SAA, in a poor general condition all died of pneumonia [70]. Granulocytopenia meant a significantly higher risk of death for patients who contracted bacterial or mycotic pneumonia or ARDS during this phase. The poor results and the similar experience of other centers [61] were among the reasons that prompted us to carry out BMT for leukemia only on patients in complete remission and in a good physical condition [10, 62]. After this, there were no more cases of early death from bacterial pneumonia, results which correspond with the observations of Winston et al. [74]. Other important factors were the early administration of broad-spectrum antibiotic combination therapy [62, 74] to patients with temperatures over 38.5° C, as well

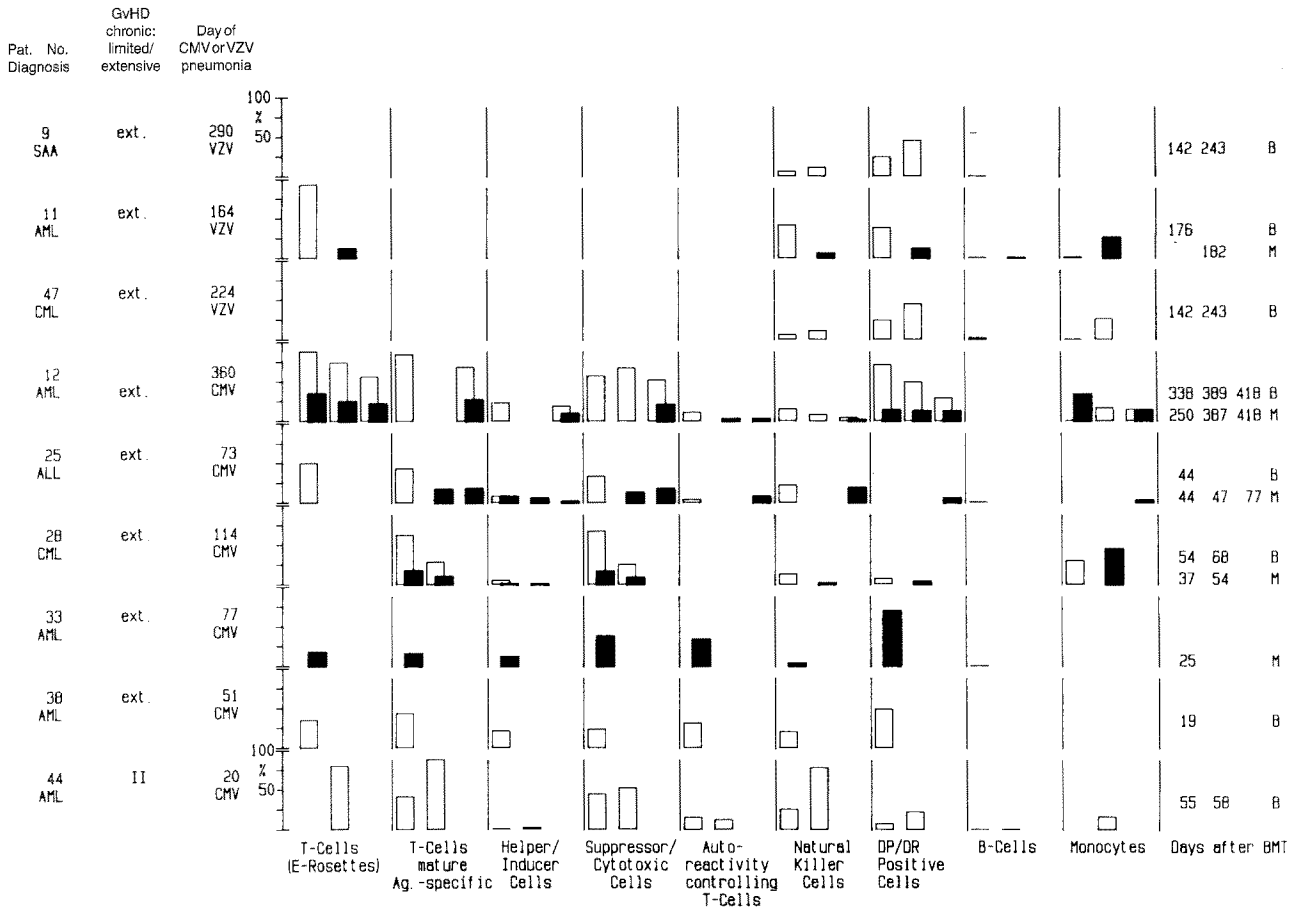


Fig. 9. Surface marker profile of mononuclear blood and bone marrow cells after BMT, before or during VZV or CMV pneumonia; all of the patients had chronic or acute GvHD, □ Peripheral blood (B), ■ Bone marrow (M)

as rigid measures for the prevention of infections [15, 16]. In addition, the use of cyclosporin A for prophylaxis of GvHD brought about an earlier rise in the number of granulocytes and less mucosal damage, which meant less bacterial penetration from the gastrointestinal tract than with the methotrexate used earlier. It was striking that bacterial pneumonias during granulocytopenia were extremely difficult to recognize on the radiograms. Only after granulocyte transfusions or during granulocyte regeneration did the typical pulmonary infiltrates appear, making diagnosis possible. The same observation was made by Karp et al. [31]. When our patients without GvHD became ill after the granulocytopenic phase, gram-positive cocci could sometimes be identified, but often no pathogens were found at all. At a later stage after BMT, two patients with extensive chronic GvHD repeatedly contracted pneumonia caused by the same gram-negative organism, so we must assume a latent bacterial infection even after the patients were clinically cured. The impaired immune regulation accompanying chronic GvHD facilitates the

reactivation of these infections [2–4, 54]. Chronic GvHD was also correlated significantly with recurrent pulmonary infections in our patients, as has been reported by others [4].

The mycotic pneumonias could be diagnosed by culturing after bronchioalveolar lavage, but never on the basis of the radiograms (see Figs. 2a and 4). The massive mycotic colonization of the gastrointestinal tract of these patients suggests that enterogenic sepsis was the cause of these fungal pneumonias. Both patients were treated successfully with a combination of amphotericin B (0.3 mg/kg per day) and 5-fluorocytosine (150 mg/kg per day) [38]. In three other patients, a simultaneous pulmonary infection with *C. albicans* and bacteria had to be treated with antibiotics as well. Two different courses were taken by two *Aspergillus* pneumonias, each depending on whether they appeared during or after granulocytopenia. Without granulocytes homogenous, opaque infiltrates appeared on the radiograms and spread over both lungs within 1–2 days. Both patients died soon afterwards. The two *Aspergillus* pneumonias that ap-

peared when the granulocyte levels were normal began as soft, spotty infiltrates, which slowly increased in size, and some of these infiltrates developed into pulmonary cavities. The antimycotic therapy described caused the infiltrates to recede and led to the absence of clinical symptoms in both of these patients. It was only possible to diagnose these four patients histologically, in two cases after transbronchial lung biopsies and in two cases after post-mortem examination. In none of these patients was it possible to find the initial focus. Other centers have had similar experiences [67, 72]. Because the paranasal sinuses are suspected to be the initial focus, Watson [67] recommended irrigation before BMT whenever the sinuses display radiological abnormalities. The bad prognosis with *Aspergillus* pneumonia makes prompt antimycotic therapy with amphotericin B advisable whenever lung infiltrates continue to increase despite treatment with antibiotics. Furthermore, we emphasize the need for fiber-optic bronchoscopy with bronchial lavage and transbronchial lung biopsies in these patients. A marked reduction in invasive *Aspergillus* infections can be attained by using filtered air with HEPA recirculation filters in sickrooms [67]. We did use these, but our patients stayed at most 6 weeks in the laminar air-flow system with filtered air.

Interstitial pneumonias from cytomegalo- or varicella zoster viruses appeared only with acute GvHD II–IV° or chronic GvHD and led to death in eight of nine patients in our patient group. Other centers report similar results, with 60%–90% mortality after CMV pneumonia [40, 67] as well as a higher risk for older patients. The pathogenesis of CMV pneumonia after BMT, which can appear in a miliary and a diffuse form [8], is the subject of controversy. The first form might result from hematogenous dissemination into the lung from an extrapulmonary source; the second form possibly develops from the gradual spread or the activation of an endogenous intrapulmonary virus [8]. Our histological and clinical findings fit better with the miliary form, although in some patients only a few of the typical owl's-eye cells were present.

It is generally believed that CMV-infected patients usually succumb to their infections after BMT if they are not able to develop CMV-specific cytotoxicity, but only a nonspecific, natural and antibody-dependent cytotoxicity [46]. Like the GvHD reaction [3, 23, 27], CMV infections cause a reversal of the ratio of helper (OKT 4⁺) to suppressor (OKT 8⁺) T-cells, with an absolute decline in the number of helper T-cells. In all of our patients with CMV or VZV pneumonia, this reversed

ratio was likewise present, with a marked reduction of helper cells. The NK cells or their precursors (Leu 7⁺) were reduced in five patients. Activated NK cells (HLA-DP⁺/DR⁺) in the blood made up 6%–48%, whereas B-cells were absent or extremely reduced in six patients. This considerable drop in helper cells noted in our cases prevented a specific immune response to viral antigens. Besides, NK cells or their precursors differentiated only partially to activated T-cells, as assessed on the basis of their HLA-DR/DP positivity. It is conceivable that this differentiation defect stems from the absence of the interleukin 2 normally produced in sufficient quantities by the helper cells [68], which are reduced here. In addition, a humoral immune response was not possible in several patients because of the absence of B-cells. This impaired immune regulation could be caused by the suppressive effect of the GvHD present in all of the patients [3, 22, 53], by the GvHD therapy often carried out, or by the virus infection itself [30, 33, 39, 53, 64], all conditions allowing the diseases to spread rapidly and lead to death.

CMV viruses can be transmitted by blood transfusions; the leukocytes are probably the source of the infection. Thus, fewer CMV infections occurred after BMT if CMV-seronegative recipients were not given granulocyte transfusions [28, 42]. Since no means of successfully treating CMV infections exist at present [41, 66, 75], the effective prophylaxis provided by anti-CMV hyperimmune globulin becomes all the more important [19, 34, 42, 71, 75]. In our own experience, CMV pneumonias can be prevented for as long as prophylactic measures are being taken. However, some questions remain to be answered. Which minimum globulin dose is sufficient in view of the high costs? Should patients with GvHD be treated beyond day 100? One of our patients with GvHD, for example, contracted a CMV pneumonia only when anti-CMV prophylaxis was stopped [35].

One patient with VZV pneumonia was treated unsuccessfully with acyclovir, although theoretically that substance should have been effective [25]. On the other hand, once we began to administer oral acyclovir prophylactically, no more VZV infections were observed during the therapy phase.

Only 11.1% of our patients contracted pneumonia of unknown etiology, which includes idiopathic interstitial pneumonia. Unfortunately, the diagnosis was not confirmed histologically. Other centers have reported an incidence of interstitial pneumonia of 10% (Royal Marsden, London) [7], 11%–13%–20% (Seattle) [1, 40, 43], or 20% (In-

ternational Bone Marrow Transplant Registry, Los Angeles) [11, 72]. The etiology of idiopathic interstitial pneumonia is still unknown, but there is a statistically significant correlation with total-body irradiation [6, 11, 26, 32, 40, 49, 56, 63, 65].

In our experience, none of the patients with SAA contracted interstitial pneumonia, indicating a direct causal link with radiation therapy, because in contrast to the leukemia patients, none of the SAA patients received lung irradiation. The Seattle group has also published similar findings [1, 40]. In addition, the earlier cytostatic therapy for leukemia could damage the lungs severely [18] and encourage the development of idiopathic interstitial pneumonia after total-body irradiation. The reason for our low incidence of IP is very likely the low irradiation dose rate (7 cGy/min) [7, 11, 49, 63], the restriction of the lung dose to 8 Gy with single-dose or 10 Gy with fractionated total-body irradiation [6, 32, 56, 63] and the use of fractionated irradiation [26, 56, 65].

In contrast to other reports [40] we found no correlation between pneumonia of unknown etiology and GvHD.

ARDS, which was the only pulmonary complication in two of our patients and which was diagnosed in six others in addition to pneumonia, can be produced by sepsis, viral lung infections and shock, among many other factors [14, 48]. In all of our patients, on the basis of the clinical course we must assume that an infection was the cause. The pathogenesis of ARDS after BMT is still unclear [14]. It is conceivable that it is encouraged by endothelial damage to the pulmonary vessels from total-body irradiation [59, 73] and the activation of complement by granulocyte transfusions [31]. Radiograms sometimes showed diffuse, opaque infiltrates, but more often revealed spotty, relatively well-defined infiltrates of varying intensity. A correlation of ARDS with cyclosporin A therapy [57] was not observed in our patients, thus supporting the report of Braude et al. [14].

Since we [37] and Roca et al. [50] first reported on obstructive bronchiolitis during chronic GvHD, several centers have confirmed our observations [5, 13, 29, 36, 47]. These findings agreed regarding a correlation with chronic GvHD, the gradual clinical onset with dyspnea on exertion and with coughing, the decrease in vital capacity and increase in residual volume, airway obstruction, increasing emphysema and recurrent pneumothorax and, in the advanced stage, cutaneous or mediastinal emphysemas. Histological studies similarly revealed fibrosis and a patchy scattering of bronchiolitis obliterans with peribronchial infiltrates,

but no lymphocytic bronchitis [13]. Other authors have described a distal, mixed inflammatory reaction and fibrosis, diffuse alveolar damage with exudative and organizing components, intra-alveolar fibrin deposits and isolated hyaline membranes in some patients, and lymphocytic infiltrates around the terminal bronchiolus with necroses of the bronchiolar epithelium in others [29, 47]. In further reports, one can read of a reduction in the number of alveolar sacs, bronchioli filled with macrophages, focal obliteration of the bronchiolar walls, atelectasis, emphysema, and interstitial fibrosis, but there is no evidence concerning lymphocytic bronchitis or bronchiolitis [36, 50]. The presence of lymphocytic infiltrates is important because Beschoner et al. [8] have interpreted them as evidence of acute bronchial GvHD, although this has been contradicted [44] and the infiltrates have instead been viewed as a nonspecific inflammatory reaction. There was no sign of lymphocytic bronchitis in our five patients. It is unclear what role GvHD plays in the pathogenesis of obstructive bronchiolitis, but the fact that it only appears during GvHD, and chiefly only in its chronic form, suggests a causal involvement. The following factors are held to be ultimately responsible: a low IgA level with a subsequent lack of mucous membrane protection by the secretory immune system, damage to the mucociliary apparatus by the GvHD-associated Sicca syndrome [54], and a general reduction in the humoral and cellular immune reaction [47, 76]. Therapy with prednisolone did not improve the condition of the three patients with the most severe clinical symptoms, nor did the use of spasmolytics, bronchodilators, mucolytics or antibiotics. Other authors have reported marked subjective and (sometimes) objective improvement, especially when prednisolone was administered as soon as the first symptoms appeared [29, 47]. Thus, it is advisable to monitor lung function in GvHD patients regularly and, if necessary, to begin prednisolone therapy at the first sign of a bronchiolar obstruction.

Lung function tests after BMT revealed a significant incidence of pulmonary hyperinflation and reduction in vital capacity. In contrast to other authors [17, 55], we found an increase rather than a reduction in RV and TLC and no restrictive changes. To date there is no explanation for these findings. Diffusion capacity dropped in our patients somewhat, but not significantly, in contrast to other studies [20, 58]. However, if only the leukemia patients are considered, as in the two studies just cited, then the DLCO reduction in our patients was also statistically significant (data not shown).

Whether this difference is due to the antileukemic chemotherapy given beforehand or primarily to the total-body irradiation of leukemia patients is not yet clear [17, 55].

Pulmonary diseases represent the most important complication and the most common cause of death after BMT in our patients. Some of the predisposing factors are known and must be combated with intensive prophylactic measures, because the therapeutic possibilities are often limited. The prevention of chronic GvHD, which is almost always the basis for viral pneumonias, obstructive bronchiolitis and recurring pneumonias, is of vital importance. Bacterial pneumonias can be reduced by shortening the duration of granulocytopenia and fungal pneumonias by painstaking prevention of exposure and accurate diagnosis. It is possible to reduce the risk of idiopathic interstitial pneumonia by adjusting radiation techniques, but efforts should be directed toward lessening its frequency even further because of the high mortality rate.

Acknowledgment. The authors gratefully acknowledge the assistance of Miss Heidrun Leitermann.

References

- Appelbaum FR, Meyers JD, Fefer A, Flournoy N, Cheever MA, Greenberg PD, Hackman R, Thomas ED (1982) Non-bacterial nonfungal pneumonia following marrow transplantation in 100 identical twins. *Transplantation* 33:265-268
- Atkinson K, Storb R, Prentice RL, Weiden TL, Witherspoon RP, Sullivan K, Noel D, Thomas ED (1979) Analysis of late infections in 89 long-term survivors of bone marrow transplantation. *Blood* 4: 720-731
- Atkinson K, Hansen JA, Storb R, Goehle S, Goldstein G, Thomas ED (1982) T-cell subpopulations identified by monoclonal antibodies after human marrow transplantation. I. Helper-inducer and cytotoxic-suppressor subsets. *Blood* 59:1292-1298
- Atkinson K, Farewell V, Storb R, Tsoi MS, Sullivan KM, Witherspoon RP, Fefer A, Clift R, Goodell B, Thomas ED (1982) Analysis of late infections after human bone marrow transplantation: role of genotypic nonidentity between marrow donor and recipient and of nonspecific suppressor cells in patients with chronic graft-versus-host disease. *Blood* 60:714-720
- Atkinson K, Bryant D, Biggs J, Concannon A, Dodds A (1984) Obstructive airways disease: a rare but serious manifestation of chronic graft-versus-host disease after allogeneic marrow transplantation in humans. *Transplant Proc* 16:1030-1033
- Barrett A (1982) Total body irradiation (TBI) before bone marrow transplantation in leukemia - a cooperative study from the European Group for Bone Marrow Transplantation. *Br J Radiol* 55:562-567
- Barrett A, Depledge MH, Powles RL (1983) Interstitial pneumonitis following bone marrow transplantation after low dose rate total body irradiation. *Int J Radiat Oncol Biol Phys* 9:1029-1034
- Beschorner WE, Saral R, Hutchins GM, Tutschka PJ, Santos GW (1978) Lymphocytic bronchitis associated with graft versus host disease in recipients of bone marrow transplants. *N Engl J Med* 299:1030-1036
- Beschorner WE, Hutchins GM, Burns W, Saral R, Tutschka PJ, Santos GW (1980) Cytomegalovirus pneumonia in bone marrow transplant recipients: miliary and diffuse patterns. *Am Rev Respir Dis* 122:107-114
- Blume KG, Beutler E, Bross KJ, Chillar RK, Ellington OB, Fahey JL, Farbstein MJ, Forman SJ, Schmidt GM, Scott EP, Spruce WE, Turner MA, Wolf JL (1980) Bone-marrow ablation and allogeneic marrow transplantation in acute leukemia. *N Engl J Med* 302:1041-1046
- Bortin MM, Kay HEM, Gale RP, Rimm AA (1982) Factors associated with interstitial pneumonitis following bone marrow transplantation for acute leukaemia. *Lancet* I:437-439
- Bortin MM, Gale RP, Kay HEM, Rimm AA (1983) Bone marrow transplantation for acute myelogenous leukemia. Factors associated with early mortality. *JAMA* 249:1166-1175
- Bradstock KF, Coles R, Despas R, Tivver K, Koutts J, Hoghes WG (1984) Fatal obstructive airways disease after bone marrow transplantation. *Transplant Proc* 16:1034-1036
- Braude S, Krausz T, Apperley J, Goldman JM, Royston D (1985) Adult respiratory distress syndrome after allogeneic bone-marrow transplantation: evidence for a neutrophil-independent mechanism. *Lancet* I:1239-1242
- Buckner CD, Clift RA, Sanders JE, Meyers JD, Counts GW, Vernon VT, Thomas ED (1978) Protective environment for marrow transplant recipients. *Ann Intern Med* 89:893-901
- Buckner CD, Clift RA, Thomas ED, Hersman J, Sanders JE, Stewart PS, Wade JC, Murphy M, Counts G, Meyers JD (1983) Early infectious complications in allogeneic marrow transplant recipients with acute leukemia: effects of prophylactic measures. *Infection* 11:243-250
- Buckner CD, Meyers JD, Springmeyer SC, Sullivan KM, Hackman RC, Flournoy N, Clift R, Storb R, Witherspoon RP, Petersen FB, Thomas ED (1984) Pulmonary complications of marrow transplantation. Review of the Seattle experience. *Exp Hematol [Suppl 15]* 12:1-5
- Collis CH (1980) Lung damage from cytotoxic drugs. *Cancer Chemother Pharmacol* 4:17-27
- Condie RM, O'Reilly RJ (1984) Prevention of cytomegalovirus infection by prophylaxis with an intravenous, hyperimmune, native, unmodified cytomegalovirus globulin. A randomized trial in bone marrow transplant recipients. *Am J Med* 76:134-141
- Depledge MH, Barrett A, Powles RL (1983) Lung function after bone marrow grafting. *Int J Radiat Oncol Biol Phys* 9:145-151
- Editorial (1984) Graft versus host disease after marrow transplantation. *Lancet* I:491-492
- Favrot M, Tidman JN, Blacklock H, Lopez E, Bofill M, Lampert I, Morgenstein G, Powles R, Prentice HG, Hoffbrand AV (1983) T cell regeneration after allogeneic bone marrow transplantation. *Clin Exp Immunol* 54:59-72
- Friedrich W, O'Reilly RJ, Koziner B, Gebhard DF, Good RA, Evans RL (1982) T-lymphocyte reconstitution in recipients of bone marrow transplants with and without GvHD: imbalances of T-cell subpopulations having unique regulatory and cognitive functions. *Blood* 59:696-701
- Gale RP, Champlin RE (1984) How does bone-marrow transplantation cure leukemia? *Lancet* II:28-29
- Gluckman E, Lotsberg J, Devergie A, Zhao M, Melo R, Gomez-Morales M, Nebout T, Mazeron MC, Perol Y

- (1983) Prophylaxis of herpes infection after bone-marrow transplantation by oral Acyclovir. *Lancet* II:706–708
26. Gooden AWG, Goldman JM, Kam KC, Dunn PA, Baughan ASJ, McCarthy DM, Worsley AM, Gordon Smith EC, Samson D, Catovsky D, Galton DAG (1983) Fractionation of whole body irradiation before bone marrow transplantation for patients with leukemia. *Br J Radiol* 56:245–250
 27. Gratama JW, Naipal A, Olijans P, Zwaan FE, Verdonck LF, Witte de T, Vossen JMJJ, Bolhuis RLH, de Gast GC (1984) T lymphocyte repopulation and differentiation after bone marrow transplantation. Early shifts in the ratio between T4⁺ and T8⁺ T lymphocytes correlate with the occurrence of acute graft versus host disease. *Blood* 63:1416–1423
 28. Hersman J, Meyers JD, Thomas ED, Buckner CD, Clift R (1982) The effect of granulocyte transfusion on the incidence of cytomegalovirus infection after allogeneic marrow transplantation. *Ann Intern Med* 96:149–152
 29. Johnson FL, Stokes DC, Ruggiero M, Dallapozza L, Callihan TR (1984) Chronic obstructive airways disease after bone marrow transplantation. *J Pediatr* 105:370–376
 30. Jordan MC (1983) Latent infection and the elusive cytomegalovirus. *Rev Infect Dis* 5:205–215
 31. Karp DD, Ervin TJ, Tuttle S, Gorgone BC, Lavin P, Yunis EJ (1982) Pulmonary complications during granulocyte transfusions: incidence and clinical features. *Vox Sang* 42:57–61
 32. Keane TJ, van Dyk J, Rider WD (1981) Idiopathic interstitial pneumonia following bone marrow transplantation: the relationship with total body irradiation. *Int J Radiat Oncol Biol Phys* 7:1365–1370
 33. Kirchner H (1983) Immunobiology of infection with human cytomegalovirus. *Adv Cancer Res* 40:31–105
 34. Kubanek B, Ernst P, Schäfer U, Ostendorf P, Wolf H (1984) A controlled trial of intravenous hyperimmunoglobulin in the prevention of cytomegalovirus infection in bone marrow transplant recipients. *Exp Hematol [Suppl 15]* 12:111–112
 35. Kubanek B, Ernst P, Ostendorf P, Schäfer U, Wolf H (1985) Preliminary data of a controlled trial of intravenous hyperimmune globulin in the prevention of cytomegalovirus infection in bone marrow transplant recipients. *Transplant Proc* 17:468–469
 36. Kurzrock R, Zander A, Kanojia M, Vellekoop L, Spitzer G, Jaganath S, Schell S, Peters L, Dicke K (1984) Obstructive lung disease after allogeneic bone marrow transplantation. *Transplantation* 37:156–160
 37. Link H, Reinhard U, Niethammer D, Krüger GRF, Waller HD, Wilms K (1982) Obstructive ventilation disorder as a severe complication of chronic graft versus host disease after bone marrow transplantation. *Exp Hematol [Suppl 10]* 10:92–93
 38. Medoff G, Kobayashi GS (1980) Strategies in the treatment of systemic fungal infections. *N Engl J Med* 302:145–155
 39. Meyers JD, Flournoy N, Thomas ED (1980) Cytomegalovirus infection and specific cell-mediated immunity after marrow transplant. *J Infect Dis* 142:816–824
 40. Meyers JD, Flournoy N, Thomas ED (1982) Nonbacterial pneumonia after allogeneic marrow transplantation: a review of ten years' experience. *Rev Infect Dis* 4:1119–1131
 41. Meyers JD, McGuffin RW, Bryson YJ, Cantell K, Thomas ED (1982) Treatment of cytomegalovirus pneumonia after marrow transplant with combined Vidarabine and human leukocyte interferon. *J Infect Dis* 146:80–84
 42. Meyers JD, Leszczynski J, Zaia JA, Flournoy N, Newton B, Snyderman DR, Wright GG, Levin MJ, Thomas ED (1983) Prevention of cytomegalovirus infection by cytomegalovirus immune globulin after marrow transplantation. *Ann Intern Med* 98:442–446
 43. Neiman PE, Reeves W, Ray G, Flournoy N, Lerner KG, Sale GE, Thomas ED (1977) A prospective analysis of interstitial pneumonia and opportunistic viral infections among recipients of allogeneic BM grafts. *J Infect Dis* 136:754–767
 44. O'Brien KD, Hackman RC, Sale GE, Prentice R, Deeg J, Thomas ED, Storb R (1984) Lymphocytic bronchitis unrelated to acute graft-versus-host disease in canine marrow graft recipients. *Transplantation* 37:233–238
 45. Pizzo PA, Commers J, Cotton D, Gress J, Hathorn J, Hiemenz J, Longo D, Marshall D, Robichaud KJ (1984) Approaching the controversies in antibacterial management of cancer patients. *Am J Med* 76:436–449
 46. Quinnan GV, Kirmani N, Rook AH, Manischewitz JF, Jackson L, Moreschi G, Santos GW, Saral R, Burns WH (1982) Cytotoxic T cells in cytomegalovirus infection: HLA-restricted T-lymphocyte and non-T-lymphocyte cytotoxic responses correlate with recovery from cytomegalovirus infection in bone marrow-transplant recipients. *N Engl J Med* 307:7–13
 47. Ralph DD, Springmeyer SC, Sullivan KM, Hackman RC, Storb R (1984) Rapidly progressive air-flow obstruction in marrow transplant recipients – possible association between obliterative bronchiolitis and chronic graft-versus-host disease. *Am Rev Respir Dis* 129:641–644
 48. Rinaldo JE, Rogers RM (1982) Adult respiratory-distress syndrome. Changing concepts of lung injury and repair. *N Engl J Med* 306:900–909
 49. Ringden O, Baryd I, Johansson B, Gahrton G, Groth CG, Lundgren G, Lonnqvist B (1983) Increased mortality by septicemia, interstitial pneumonitis and pulmonary fibrosis among bone marrow transplant recipients receiving an increased mean dose of total irradiation. *Acta Radiol Oncol Rad Phys B* 22:423–428
 50. Roca J, Granena A, Rodriguez-Roisin R, Alvarez P, Agusti-Vidal A (1982) Fatal airway disease in an adult with chronic graft versus host disease. *Thorax* 37:77–78
 51. Rodt H, Kolb HJ, Netzel B, Haas RJ, Wilms K, Bender-Götze C, Link H, Thierfelder S (1981) Effect of anti-T-cell globulin on GvHD in leukemic patients treated with BMT. *Transplant Proc* 13:257–261
 52. Rühle KH, Matthys H (1976) Kritische Auswahl von Sollwerten für ein Computer-Programm zur Routine-Lungenfunktionsdiagnostik. *Pneumologie* 153:223–233
 53. Schroff RW, Gale RP, Fahey JL (1982) Regeneration of T cell subpopulations after bone marrow transplantation: cytomegalovirus infection and lymphoid subset imbalance. *J Immunol* 129:1926–1930
 54. Shulman HM, Sullivan KM, Weiden PL, McDonald GB, Striker GE, Sale GE, Hackman T, Tsoi MS, Storb R, Thomas ED (1980) Chronic graft versus host syndrome in man, a long-term clinicopathologic study of 20 Seattle patients. *Am J Med* 69:204–212
 55. Serota FT, August CS, Koch PA, Fox W, D'Angio GJ (1984) Pulmonary function in patients undergoing bone marrow transplantation. *Med Pediatr Oncol* 12:137–143
 56. Shank B, Chu FCH, Dinsmore R, Kapoor N, Kirkpatrick D, Teitelbaum H, Reid A, Bonfiglio P, Simpson L, O'Reilly RJ (1983) Hyperfractionated total body irradiation for bone marrow transplantation: results in seventy leukemia patients with allogeneic transplantation. *Int J Radiat Oncol Biol Phys* 9:1607–1612
 57. Sloane JP, Depledge MH, Powels RL, Morgenstern GR, Trickey BS, Dady PJ (1983) Histopathology of the lung after bone marrow transplantation. *J Clin Pathol* 36:546–554

58. Sørensen PG, Ernst P, Panduro J, Møller J (1984) Reduced lung function in leukemia patients undergoing bone marrow transplantation. *Scand J Haematol* 32:253–257
59. Springmeyer SC, Kopecky KJ, Deeg J, Whitehead J, Altman LC, Storb R (1984) Pulmonary bronchoalveolar cell and protein kinetics in dogs given total-body irradiation, autologous marrow grafts, and Methotrexate. *Transplantation* 37:336–339
60. Storb R, Prentice RL, Buckner CD, Clift RA, Appelbaum F, Deeg J, Doney K, Hansen JA, Mason M, Sanders JE, Singer J, Sullivan KM, Witherspoon RP, Thomas ED (1983) Graft-versus host disease and survival in patients with aplastic anemia treated by marrow grafts from HLA-identical siblings. *N Engl J Med* 308:302–307
61. Thomas ED, Storb R, Clift RA, Fefer A, Johnson FL, Neiman PE, Lerner KG, Glucksberg H, Buckner CD (1975) Bone-marrow transplantation (first of two parts). *N Engl J Med* 292:832–843
62. Thomas ED, Buckner CD, Banaji M, Clift RA, Fefer A, Flournoy N, Goodell BW, Hickman RO, Lerner KG, Sale GE, Sanders JE, Singer J, Stevens M, Storb R, Weidel PL (1977) One hundred patients with acute leukemia treated by chemotherapy, total body irradiation, and allogeneic marrow transplantation. *Blood* 49:511–533
63. Torres J, Bross D, Lam W, Wharam M, Santos G, Order S (1982) Risk factors in interstitial pneumonitis following allogeneic bone marrow transplantation. *Int J Radiat Oncol Biol Phys* 8:1301
64. Verdonck LF, de Gast GC (1984) Is cytomegalovirus infection a major cause of T cell alterations after (autologous) bone-marrow transplantation? *Lancet* I:932–935
65. Vitale V, Bacigalupo A, van Lint MT, Frassoni F, Ricci G, Siracusa G, Marziano G, Vitali ML, Scielzo, Tomassini A, Bistolfianda F, Marmont AM (1983) Fractionated total body irradiation in marrow transplantation for leukaemia. *Br J Haematol* 55:547–554
66. Wade JC, McGuffin RW, Springmeyer SC, Newton B, Singer JW, Meyers JC (1983) Treatment of cytomegalovirus pneumonia with high-dose-Acyclovir and human leukocyte interferon. *J Infect Dis* 148:557–562
67. Watson JG (1983) Problems of infection after bone marrow transplantation. *J Clin Pathol* 36:683–692
68. Welte K, Ciobanu N, Moore MAS, Gulati S, O'Reilly RJ, Mertelsmann R (1984) Defective interleukin 2 production in patients after bone marrow transplantation and in vitro restoration of defective T lymphocyte proliferation by highly purified interleukin-2. *Blood* 64:380–385
69. Wernet P, Ostendorf P, Sigg M, Muller CP, Uchanska-Ziegler B, Waller HD et al. (1986) Sequential expression of MHC class II allo-antigens for HLA-DP, DR and DQ on the surface of leukemic blast cells apparently correlating with lineage independent differentiation states. *Leuk Res* (in press)
70. Wilms K, Link H, Meyer P, Ostendorf P, Schüch K, Waller HD, Wernet P, Niethammer D, Dopfer R, Schneider W, Schunter F, Breitling G, Frommhold W, Seeger G, Voss AC (1982) Knochenmarktransplantation bei Patienten mit Leukämien. *Klin Wochenschr* 60:1279–1287
71. Winston DJ (1982) Cytomegalovirus immune plasma in bone marrow transplant recipients. *Ann Intern Med* 97:11–18
72. Winston DJ, Gale RP, Meyer DV, Young LS (1979) Infectious complications of human bone marrow transplantation. *Medicine* 58:1–31
73. Winston DJ, Territo MC, Ho WG, Miller MJ, Gale RP, Golde DW (1982) Alveolar macrophage dysfunction in human bone marrow transplant recipients. *Am J Med* 73:859–866
74. Winston DJ, Ho WG, Champlin RE, Gale RP (1984) Infectious complications of bone marrow transplantation. *Exp Hematol* 12:205–215
75. Winston DJ, Ho WG, Lin CH, Budinger MD, Champlin RE, Gale RP (1984) Intravenous immunoglobulin for modification of cytomegalovirus infections associated with bone marrow transplantation Preliminary results of a controlled trial. *Am J Med* 76:128–133
76. Witherspoon RP, Storb R, Ochs HD, Flournoy N, Kopecky KJ, Sullivan KM, Deeg HJ, Sosa R, Noel DR, Atkinson K, Thomas ED (1981) Recovery of antibody production in human allogeneic marrow graft recipients: influence of time posttransplantation, the presence or absence of chronic graft-versus-host disease, and antithymocyte globulin treatment *Blood* 58:360–368
77. Zwaan FE, Hermans J, Barrett AJ, Speck B (1984) Bone marrow transplantation for acute nonlymphoblastic leukemia: a survey of the European Group for Bone Marrow Transplantation (E.G.B.M.T.) *Br J Haematol* 56:645–654

Received: August 20, 1985

Returned for revision: October 10, 1985

Accepted: January 16, 1986

Dr. Hartmut Link
 Medizinische Hochschule Hannover
 Abteilung Hämatologie-Onkologie
 Konstanty-Gutschowstr. 8
 D-3000 Hannover 61