

MYORG-related disease is associated with central pontine calcifications and atypical parkinsonism

Viorica Chelban, MD, MSc, MRCP, Miryam Carecchio, MD, PhD, Gillian Rea, MD, Abdalla Bowirrat, MD, PhD, Salman Kirmani, MD, Luca Magistrelli, MD, Stephanie Efthymiou, MSc, Lucia Schottlaender, MD, PhD, Jana Vandrovцова, PhD, Vincenzo Salpietro, MD, Ettore Salsano, MD, Davide Pareyson, MD, Luisa Chiapparini, MD, Farida Jan, MD, Shahnaz Ibrahim, MD Prof, Fatima Khan, MD, Zul Qarnain, MD, Stanislav Groppa, MD, PhD, Nin Bajaj, MD, PhD, Bettina Balint, MD, Kailash P. Bhatia, MD Prof, Andrew Lees, FMedSci, FRCP, Patrick J. Morrison, CBE, MD, DSc, Nicholas W. Wood, MD, PhD, Barbara Garavaglia, MD, PhD, and Henry Houlden, MD, PhD

Correspondence

Dr. Chelban
v.chelban@ucl.ac.uk
or Dr. Garavaglia
barbara.garavaglia@istituto-besta.it

Neurol Genet 2020;6:e399. doi:10.1212/NXG.0000000000000399

Abstract

Objective

To identify the phenotypic, neuroimaging, and genotype-phenotype expression of *MYORG* mutations.

Methods

Using next-generation sequencing, we screened 86 patients with primary familial brain calcification (PFBC) from 60 families with autosomal recessive or absent family history that were negative for mutations in *SLC20A2*, *PDGFRB*, *PDGFB*, and *XPR1*. In-depth phenotyping and neuroimaging investigations were performed in all cases reported here.

Results

We identified 12 distinct deleterious *MYORG* variants in 7 of the 60 families with PFBC. Overall, biallelic *MYORG* mutations accounted for 11.6% of PFBC families in our cohort. A heterogeneous phenotypic expression was identified within and between families with a median age at onset of 56.4 years, a variable combination of parkinsonism, cerebellar signs, and cognitive decline. Psychiatric disturbances were not a prominent feature. Cognitive assessment showed impaired cognitive function in 62.5% of cases. Parkinsonism associated with vertical nuclear gaze palsy was the initial clinical presentation in 1/3 of cases and was associated with central pontine calcifications. Cerebral cortical atrophy was present in 37% of cases.

Conclusions

This large, multicentric study shows that biallelic *MYORG* mutations represent a significant proportion of autosomal recessive PFBC. We recommend screening *MYORG* mutations in all patients with primary brain calcifications and autosomal recessive or negative family history, especially when presenting clinically as atypical parkinsonism and with pontine calcification on brain CT.

From the Department of Neuromuscular Diseases (V.C., S.E., L.S., J.V., V.S., N.W.W., H.H.), UCL Queen Square Institute of Neurology; National Hospital for Neurology and Neurosurgery (V.C., S.E., L.S., J.V., V.S., N.W.W., H.H.), Queen Square, London, UK; Department of Neurology and Neurosurgery (V.C., S.G.), Institute of Emergency Medicine, Chisinau, Republic of Moldova; Department of Neuroscience (M.C.), University of Padua, Italy; Northern Ireland Regional Genetics Service (G.R., P.J.M.), Belfast City Hospital, UK; Department of Neuroscience (A.B.), Interdisciplinary Center (IDC) Herzliya, Israel; Department of Paediatrics & Child Health (S.K., F.J., S.I., F.K., Z.Q.), Aga Khan University, Karachi, Pakistan; Department of Neurology (L.M.), Eastern Piedmont University, Novara, Italy; Department of Neurology (E.S., D.P.) and Department of Neuroradiology (L.C.), Fondazione IRCCS Istituto Neurologico Carlo Besta, Milan, Italy; Department of Clinical Neurology (N.B.), University of Nottingham, UK; Department of Clinical and Movement Neurosciences (B.B., K.P.B., N.W.W.), UCL Queen Square Institute of Neurology, London, UK; Department of Neurology (B.B.), Heidelberg University Hospital, Germany; Reta Lila Weston Institute (A.L.), UCL Queen Square Institute of Neurology, London, UK; and Medical Genetics and Neurogenetics Unit (B.G.), Fondazione IRCCS Istituto Neurologico Carlo Besta, Milan, Italy.

Go to [Neurology.org/NG](https://www.neurology.org/NG) for full disclosures. Funding information is provided at the end of the article.

The Article Processing Charge was funded by the authors.

This is an open access article distributed under the terms of the Creative Commons Attribution License 4.0 (CC BY), which permits unrestricted use, distribution, and reproduction in any medium, provided the original work is properly cited.

Glossary

DAT = dopamine active transporter; **gnomAD** = Genome Aggregation Database; **MMSE** = Mini-Mental State Examination; **PFBC** = primary familial brain calcification.

Primary familial brain calcification (PFBC) is a genetic neurodegenerative condition characterized by calcium deposition in the basal ganglia and other brain regions usually presenting with a combination of movement disorders, migraine, psychiatric, and cognitive impairment. The exact prevalence of PFBC is unknown, but population-based genomic analysis indicates that it is underestimated and underdiagnosed,¹ with a molecular diagnosis achieved in only up to 50% of PFBC cases.² The pathogenesis of PFBC involves calcium and phosphate homeostasis via mutations in *SLC20A2* (OMIM: 158378) and *XPR1* (OMIM: 605237) and endothelial integrity and function affecting the blood-brain barrier via mutations in *PDGFB* (OMIM: 190040) and *PDGFRB* (OMIM: 173410). Among these, mutations in *SLC20A2* account for approximately 45% of all autosomal dominant and de novo reported familial cases from diverse ethnicities.³ However, a large proportion of autosomal recessive PFBC remain undiagnosed.⁴ Recently, biallelic mutations in *MYORG* (OMIM: 618255) have been implicated in the pathogenesis of autosomal recessive PFBC in families of Chinese⁵ and French⁶ ethnicity. Here, we report a large multicentric cohort of ethnically diverse patients with biallelic variants in *MYORG* and broaden the phenotypic spectrum related to *MYORG* mutations.

Methods

Patients

Patients with an autosomal recessive or negative family history and confirmed clinical and radiologic diagnosis of PFBC were recruited from multiple centers. Genetic testing was performed on stored blood samples of patients with unidentified etiologies of PFBC. Ethnically, the families were of British, Italian, Irish, Pakistani, and Israeli origin. Secondary causes of brain calcification were excluded in all cases. All cases were negative for other PFBC-related genes (*SLC20A2*, *PDGFRB*, *PDGFB*, and *XPR1*) and had comprehensive phenotyping performed by neurogenetics specialists.

In cases with biallelic *MYORG* variants, the results from additional investigations were retrospectively analyzed based on chart review where available: neuroimaging with CT in all reported cases (n = 8), brain MRI (n = 4), dopamine active transporter (DAT) scan (n = 2), and fluorodeoxyglucose-PET (n = 2). Cognitive impairment was assessed by formal psychometry.

Genetic testing

DNA was extracted from peripheral blood. Whole-exome sequencing was performed in all families. An Illumina HiSeq4000 instrument (Illumina, San Diego, CA) was used to generate

100 bp paired-end reads. Alignment was performed using BWA (bio-bwa.sourceforge.net/)⁷ with GRCH38 as a reference. Variants were called using the GATK^{8–11} UnifiedGenotyper-based pipeline^{8–10} workflow. All variants were annotated using ANNOVAR¹² and filtered using custom R scripts. Only novel or very rare variants with a minor allele frequency of <0.01 in the 1000 Genomes Project¹³ and Genome Aggregation Database (gnomAD)¹⁴ or known pathologic mutations were included. Variants were filtered for homozygous, compound heterozygous, highly deleterious, rare mutations segregating with the disease. Except for families 1 and 7, segregation was confirmed in all other families.

For every rare *MYORG* variant identified (ENST00000297625, GenBank transcript ID NM_020702), we determined pathogenicity and novelty. Pathogenicity was assessed using the American College of Medical Genetics and Genomics and the Association for Molecular Pathology recommendations for variant classification.¹⁵ Only pathogenic and likely pathogenic variants were included here. All pathogenic and likely pathogenic variants were confirmed with bidirectional Sanger sequencing. Primers are available in table e-1 (links.lww.com/NXG/A227).

Standard protocol approvals, registrations, and patient consents

The individuals included in this study were recruited along with unaffected family members under ethics-approved research protocols (UCLH: 04/N034) with informed consent.

Data availability

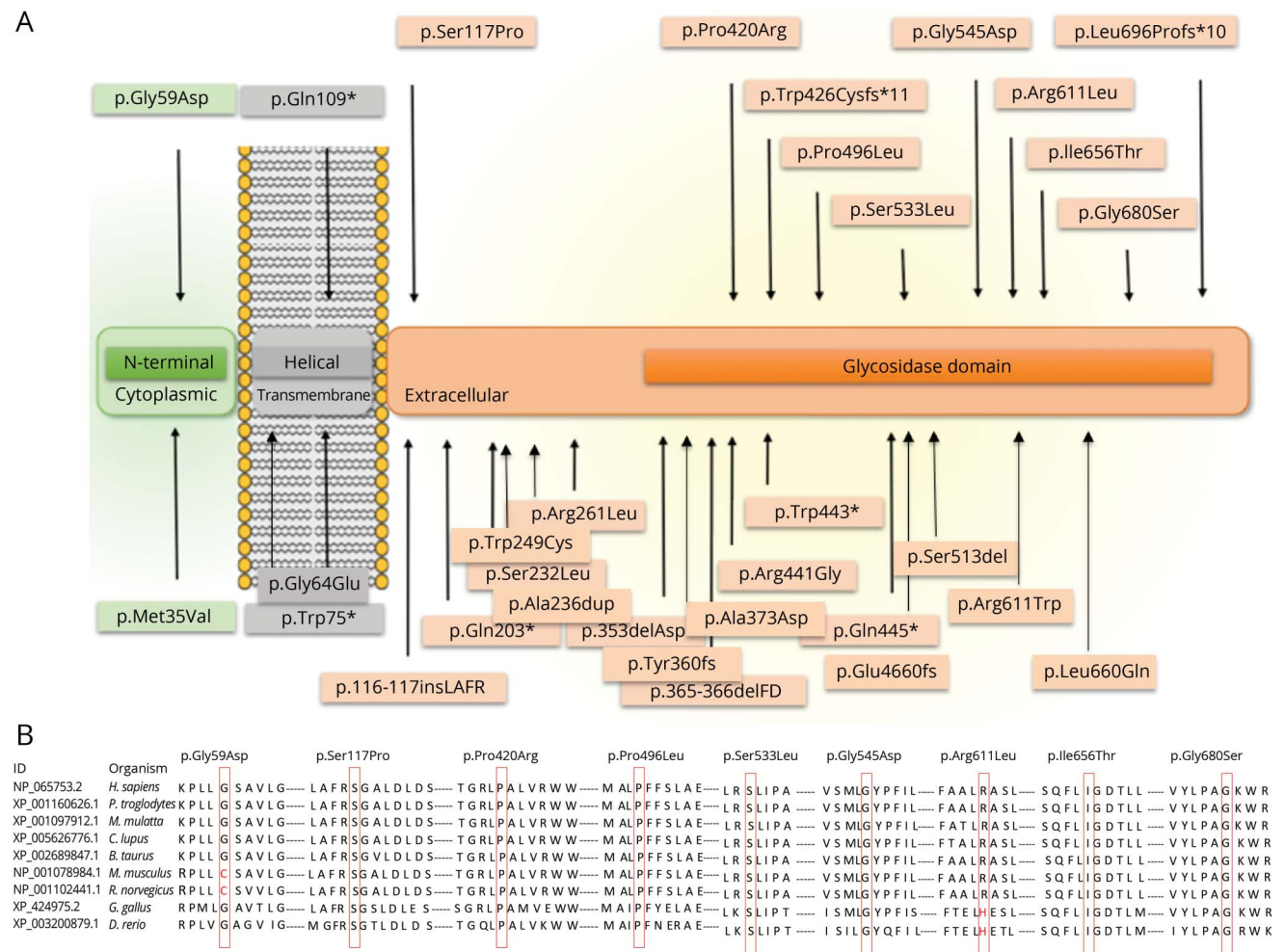
Anonymized data used for this study are available from the corresponding authors on reasonable request. A data access agreement needs to be signed.

Results

Genetic spectrum

We screened 86 cases from 60 families with PFBC that were negative for pathogenic variants in *SLC20A2*, *PDGFB*, *PDGFRB*, and *XPR1* and had a recessive or negative family history. We identified pathogenic and likely pathogenic homozygous and compound heterozygous variants in *MYORG* (ENST00000297625, GenBank transcript ID NM_020702) in 8 cases from 7 families (figure e-1, links.lww.com/NXG/A227). Overall, biallelic *MYORG* mutations accounted for 11.6% (7/60) of PFBC families in our cohort. We identified 12 distinct mutations, of which 4 were novel (figure 1A) and 8 were present in gnomAD with very low allele frequency in the heterozygous state and absent in the homozygous state (table

Figure 1 Genetic spectrum of *MYORG* mutations



(A) Schematic representation of *MYORG* with all the mutations identified in our study and those reported to date. The *MYORG* functional domains and their cellular localization are indicated: green, N-terminal sequence (cytoplasmic); gray, helical (transmembrane); orange, glycosidase domain (extracellular). The mutations reported in this cohort are plotted on top of the gene; mutations previously reported are below the gene. (B) Conservation across species for novel missense *MYORG* variants. The variants are marked with red boxes for the corresponding amino acid.

e-2). With the exception of 1 variant (p.Ile656Thr), none of the variants presented here have been previously reported in *MYORG*-related brain calcifications. Apart from copy number variants, all types of mutations have been found in this cohort (1 nonsense, 1 frameshift deletion, 1 insertion, and 9 missense variants). All missense variants were located in conserved and highly conserved amino acid positions (figure 1B). The 12 mutations identified in this study were located throughout the gene with no obvious mutational hotspots. Two mutations were inherited in the homozygous state in the 2 consanguineous families; the 5 nonconsanguineous families presented with compound heterozygous variants.

Phenotype spectrum

In our cohort, *MYORG* mutation carriers presented with a high phenotypic variability. The average age at onset was 59.1 years (median 56.4 years, range 39 years to incidental finding at 87 years). Symptoms at onset varied from parkinsonism (37.5%), ataxia and/or dysarthria (37.5%), and headache (12.5%).

Insidious onset with brain calcifications found incidentally was in 12.5% of cases. Table 1 and table e-3 (links.lww.com/NXG/A227) present clinical details of all *MYORG*-related cases included in this study.

An initial progressive parkinsonism associated with supranuclear gaze palsy phenotype was identified in 1/3 of cases at disease onset. Case 1 presented at the initial clinical examination age 40 years with profound facial hypomimia with a staring expression, reduced up and down gaze, associated with profound bilateral bradykinesia, rigidity, reduced arm swings, and a combination of ataxia and freezing. She had poor response to levodopa. Case 5 presented at age 56 years with asymmetric parkinsonism and supranuclear gaze palsy with poor response to levodopa. Progressive deterioration of motor function, dysarthria, dysphagia, and gait ataxia became evident over the following years. Case 8 presented at age 62 years with parkinsonism, frequent falls, staring gaze with vertical gaze palsy that progressed over 16 years along with gait ataxia, cognitive

Table 1 Phenotype description of all *MYORG* mutations reported in this study

Case number	Case 1	Case 2	Case 3	Case 4	Case 5	Case 6	Case 7	Case 8
Family number	1	2		3	4	5	6	7
Ethnicity/ country	Caucasian	Middle East		Caucasian				
cdNA sequence	c.176G>A	c.1611C>T	c.1611C>T	c.1634G>A, c.1598C>T	c.2211_2212del, c.349T>C	c.2162G>A, c.1383C>G	c.325C>T, c.1832G>T	c.1401_1402insCGCTGGTG, c.1967T>C
Amino acid change	p.Gly59Asp	p.Pro496Leu	p.Pro496Leu	p.Gly545Asp, p.Ser533Leu	p.Leu696Profs*10, p.Ser117Pro	p.Gly680Ser, p.Pro420Arg	p.Gln109Ter, p.Arg611Leu	p.Trp426Cysfs*11, p.Ile656Thr
Zygoty	Homozygous	Homozygous		Compound heterozygous	Compound heterozygous	Compound heterozygous	Compound heterozygous	Compound heterozygous
Sex (male/ female)	Female	Male	Male	Female	Female	Female	Male	Female
Age at examination (y)	41	52	46	87	72	81	67	68
Age at onset (y)	39	51	45	Incidental finding at 87 y	56	73	62	62
Disease duration	3 y	1 y	1 y	Unknown	16 y	8 y	5 y	6 y
Disability	Requires assistance with most tasks	Normal independent daily living	Normal independent daily living	Normal independent daily living	Bedridden	Requires support for walking	Independent	Bedridden and needs assistance for self-care
Symptom at onset	Parkinsonism and ataxia	Headache	Ataxia and dizziness	Unknown	Parkinsonism	Progressive dysarthria	Progressive dysarthria and dysphagia	Parkinsonism
Phenotype								
Parkinsonism	Yes	Yes	No	Yes	Yes	Yes	Yes	Yes
Cerebellar syndrome	Gait ataxia and dysarthria	Dysarthria	Limb ataxia	Mild dysdiadochokinesia; wide-based gait	Dysarthria and ataxia	Dysarthria	Dysarthria	Dysarthria
Pyramidal syndrome	Yes	No	No	No	Yes	No	No	No
Dystonia	Yes	No	No	No	No	No	No	No
Eye movements and cranial nerves	Supranuclear gaze palsy	Normal	Normal	Normal	Supranuclear gaze palsy, dysarthria, and dysphagia	No	Dysphagia and dysarthria	Supranuclear gaze palsy and dysphagia
Psychiatric symptoms	No	No	No	No	Depression	No	No	Depression

Continued

Table 1 Phenotype description of all *MYORG* mutations reported in this study (continued)

Case number	Case 1	Case 2	Case 3	Case 4	Case 5	Case 6	Case 7	Case 8
Other	No	Headache	Headache and vertigo	No	Urinary incontinence	No	No	Rhinolalia and urinary incontinence
Cognitive function	Reduced verbal fluency, poor Luria, and concrete verbal reasoning	Mild memory impairment MMSE 27/30	MMSE 28/30	Normal	Dementia and executive dysfunction	Normal	MCI (MOCA 21/30)	MMSE 23/30
CT results								
Calcification localization	Symmetrical, bilateral basal ganglia, cerebellar folia, and subcortical white matter	Symmetrical, bilateral basal ganglia, thalamus, and subcortical white matter	Symmetrical, bilateral basal ganglia and subcortical white matter	Symmetrical, bilateral basal ganglia, thalami, and cerebellar hemispheres	Symmetrical, bilateral basal ganglia, thalami, cerebellar hemispheres, and pons	Symmetrical, bilateral basal ganglia, cerebellar hemispheres, and subcortical white matter	Symmetrical, bilateral basal ganglia, thalami, cerebellar hemispheres, and pons	Symmetrical, bilateral basal ganglia, thalami, cerebellar hemispheres, and pons
Atrophy	Bilateral frontotemporal and cerebellar atrophy	No	No	No	No	Bilateral frontotemporal atrophy	Cerebellar, pontine and midbrain atrophy	No

Abbreviations: cDNA = complementary DNA; MCI = mild cognitive impairment; MMSE = Mini-Mental State Examination; MOCA = Montreal Cognitive Assessment.

decline, urinary incontinence, and pyramidal signs. All cases presenting with parkinsonism and supranuclear gaze palsy had associated cognitive impairment characterized by executive dysfunction, poor verbal fluency, and concrete verbal reasoning with low scores on Mini-Mental State Examination (MMSE). Two of the 3 patients had a reduced tracer uptake on DAT scan consistent with symmetrical, bilateral marked loss of pre-synaptic dopaminergic neurons (particularly in the putamen).

A cerebellar-bulbar syndrome of variable severity was present in all our cases ranging from very mild (case 4) to moderate dysarthria and dysphagia affecting mainly speech and swallowing (cases 2, 6, and 7). Severe gait and limb ataxia was present in 3/8 of cases (cases 1, 3, and 5). Parkinsonism was detectable in 7 of 8 cases, often associated with other features including supranuclear gaze palsy, early frequent falls, early cognitive decline, and lack of response to levodopa.

One associated extrapyramidal sign in *MYORG*-related disease was limb dystonia. This was clinically presenting as dystonic posturing in the upper limb precipitated by walking. A third of our patients had bilateral pyramidal signs in the lower limbs. Other associated clinical features were headache (2 cases), urinary incontinence (2 cases), and cramps in the lower limbs (1 case).

Neuropsychiatric evaluation revealed 2 cases with depression. Cognitive assessment showed impaired cognitive function in 62.5% of cases, with different degrees of severity. *MYORG* patients showed reduced verbal fluency and poor verbal reasoning in the first year of disease (cases 1 and 3), mild memory impairment (case 2, MMSE 27/30) with progression over the following years (case 7, Montreal Cognitive Assessment 21/30 and case 8, MMSE 23/30) to a diagnosis of dementia (case 5).

Response to levodopa in cases with parkinsonian phenotype was poor to moderate and proved particularly ineffective in patients with parkinsonism associated with supranuclear gaze palsy. Case 1 with confirmed DAT scan abnormality had some modest benefit from levodopa in the first year of treatment. However, the response to treatment was short lived and faded in the next 2 years of disease.

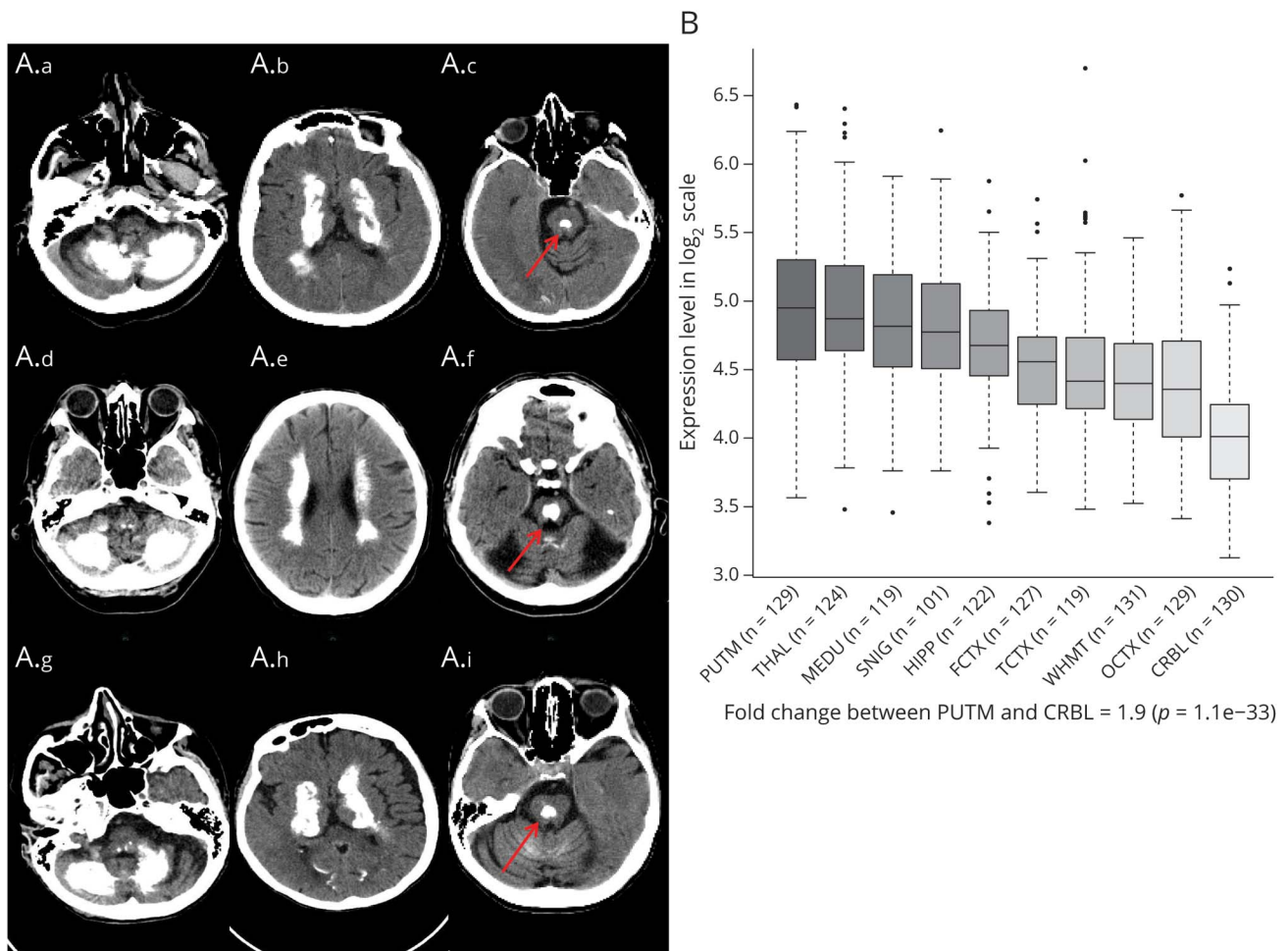
Neuroimaging spectrum

All patients showed extensive brain calcifications regardless of disease duration. Basal ganglia (putamen, internal globus pallidus, and caudate nucleus) were involved in all cases, whereas cerebellar hemispheres (folia and dentate nuclei) were involved in 75% of cases. Half of the cases also showed calcification of subcortical white matter. Extensive central pontine calcification was present in 3 cases. Cerebral cortical atrophy was observed in 37% of cases (figure 2A).

Discussion

In this study, we screened *MYORG* mutations in 86 cases from 60 unrelated, autosomal recessive PFBC families. We identified 7

Figure 2 Neuroimaging spectrum in *MYORG* cases



(A) Neuroimaging spectrum in *MYORG* cases. Cases 5 (A.a-A.c), 7 (A.d-A.f), and 8 (A.g-A.i) showed similar calcification pattern distribution with extensive involvement of cerebellar dentate nuclei and hemispheres, basal ganglia, thalami, and subcortical white matter; a characteristic central pontine calcification (red arrow) is present in all cases; frontotemporal and cerebellar atrophy was present in case 7; case 6: calcification of the internal globus pallidus, subcortical white matter, and dentate nuclei, with minimal involvement of thalami bilaterally. Severe frontotemporal and cerebellar atrophy is also detectable. (B) *MYORG* clinical spectrum correlates with *MYORG* gene expression in different brain areas. *MYORG* gene expression in different brain areas in adult pathologically normal human brains.²⁵ *MYORG* is expressed in all 10 brain regions with highest expression detected in the putamen. CRBL = cerebellum; FCTX = frontal cortex; HIPP = hippocampus; MEDU = medulla; OCTX = occipital cortex; PUTM = putamen; SNIG = substantia nigra; TCTX = temporal cortex; THAL = thalamus; WHMT = white matter.

new families of different ethnic backgrounds with disease-causing *MYORG* variants. Biallelic *MYORG* mutations were associated with PFBCs in 11.6% of families from our cohort. We identified 12 distinct mutations, suggesting that recurrent *MYORG* mutations are infrequent. Most of the initial reported cases came from consanguineous families.^{5,6} Here, we present a cohort largely lacking in known consanguinity, with the majority of mutations inherited in the compound heterozygous state.

Our data suggest that the majority of cases have a disease onset in late adulthood with a combination of dysarthria, ataxia, parkinsonism, and cognitive decline consistent with the phenotypes previously reported in *MYORG* mutations^{5,6,16-19} and other autosomal dominant PFBC-causing genes.²⁰ However, parkinsonism with supranuclear gaze palsy was frequently observed (37.8% of cases) in our cohort and has not been previously described in *MYORG* mutation carriers. Therefore, this

further extends the phenotypic spectrum of *MYORG*-related disease. Of interest, central pontine calcification was present in over 1/3 of cases, which seems to be a radiologic diagnostic clue for *MYORG* mutation carriers, as this anatomic region is typically not affected in other genetic PFBC cases.⁶ As physiologic brain calcifications in this age group are reported in up to 20%,^{21,22} an association of calcifications, supranuclear gaze palsy, and parkinsonism with atypical features such as ataxia or rapid cognitive decline should prompt physicians to test for *MYORG* mutations in this subgroup of patients. We show that next-generation sequencing can contribute to the diagnosis of late-onset, mildly affected or asymptomatic cases, therefore providing a more comprehensive understanding of the genetic architecture of brain calcifications.

The exact mechanism leading to disease in *MYORG* mutations is still unknown. On a cellular level, the gene is

expressed in astrocytes localized to the endoplasmic reticulum⁵ and playing a role as glycosyl hydrolase.²³ Although gene expression (Genotype-Tissue Expression²⁴) is reported highest in the basal ganglia (nucleus accumbens and caudate) after the skeletal muscle, gene expression data in BRAINEAC²⁵ suggest that the putamen and the thalamus express the most *MYORG* messenger RNA followed by the medulla and the substantia nigra (figure 2B). These areas are mirrored in the clinical phenotype and calcification distribution on neuroimaging assessment in our cohort. Calcifications localized in the basal ganglia structures (100%), followed by the cerebellum in 75% of our cases, subcortical white matter (50%), and the thalamus (50%).

The phenotype observed in individuals with biallelic deleterious *MYORG* variants suggests a high variability among and within families with a disease severity ranging from insidious, incidental findings to severe, rapidly progressing disease course. Asymptomatic cases with biallelic *MYORG* mutations⁵ and heterozygous mutation carriers with punctate calcifications on the brain CT have been reported^{5,6,16}). Our data together with previous reports suggest a dose-dependent phenotype based on the effect of mutations on the enzymatic activity of *MYORG*; however, no study has evaluated the enzymatic activity in *MYORG* mutations.

We show that biallelic *MYORG* mutations represent a significant proportion of PFBC cases without mutations in other known disease-causing genes. Here, we reported 12 distinct *MYORG* variants associated with brain calcifications and extended the phenotypic spectrum of this disease including atypical parkinsonism with pontine calcification. We recommend screening *MYORG* mutations in all patients with primary brain calcifications and autosomal recessive or negative family history.

Acknowledgment

The authors thank the participants and their families for their essential help with this work. They also acknowledge C. Panteghini, C. Reale, and F. Invernizzi (Neurogenetics Unit, Fondazione IRCCS Istituto Neurologico Carlo Besta) for their support in sample management.

Study funding

This work was supported by The Wellcome Trust (Synaptopathies strategic award [104033]) and the Medical Research Council (MRC UK International Centre and project grants). The Association of British Neurologists' Academic Clinical Training Research Fellowship and MSA Trust funded V.C. The authors acknowledge the "Cell lines and DNA Bank of Pediatric Movement Disorders and Mitochondrial Diseases" of the Telethon Network of Genetic Biobanks (grant GTB12001J), the EuroBioBank Network, and the Pierfranco and Luisa Mariani Foundation.

Disclosure

The authors report no disclosures. Go to Neurology.org/NG for full disclosure.

Publication history

Received by *Neurology: Genetics* September 16, 2019. Accepted in final form December 17, 2019.

Appendix Authors

Name	Location	Role	Contribution
Viorica Chelban, MD, MSc, MRCP	UCL Queen Square Institute of Neurology, London, UK	Author	Designed and conceptualized the study; acquisition of data; analyzed the genetic and clinical data; and drafted the manuscript for intellectual content
Miryam Carecchio, MD, PhD	University of Padua, Italy	Author	Acquisition of data; interpreted the imaging data; and revised the manuscript for intellectual content
Gillian Rea, MD	Belfast City Hospital, UK	Author	Acquisition of data and revised the manuscript for intellectual content
Abdalla Bowirrat, MD, PhD	An-Najah National University, Albiar Village, Nablus, Palestine	Author	Acquisition of data and revised the manuscript for intellectual content
Salman Kirmani	Aga Khan University, Karachi, Pakistan	Author	Acquisition of data and revised the manuscript for intellectual content
Luca Magistrelli, MD	Eastern Piedmont University, Novara, Italy	Author	Acquisition of data and revised the manuscript for intellectual content
Stephanie Efthymiou	UCL Queen Square Institute of Neurology, London, UK	Author	Acquisition of data and revised the manuscript for intellectual content
Lucia Schottlaender, MD, PhD	UCL Queen Square Institute of Neurology, London, UK	Author	Acquisition of data and revised the manuscript for intellectual content
Jana Vandrovцова, PhD	UCL Queen Square Institute of Neurology, London, UK	Author	Analysis of data and revised the manuscript for intellectual content
Vincenzo Salpietro, MD	UCL Queen Square Institute of Neurology, London, UK	Author	Acquisition of data and revised the manuscript for intellectual content
Ettore Salsano, MD	Fondazione IRCCS Istituto Neurologico Carlo Besta, Italy	Author	Acquisition of data and revised the manuscript for intellectual content

Continued

Appendix (continued)

Name	Location	Role	Contribution
Daive Pareyson, MD	Fondazione IRCCS Istituto Neurologico Carlo Besta, Italy	Author	Acquisition of data and revised the manuscript for intellectual content
Luisa Chiapparini, MD	Fondazione IRCCS Istituto Neurologico Carlo Besta, Italy	Author	Acquisition of data and revised the manuscript for intellectual content
Farida Jan, MD	Aga Khan University, Karachi, Pakistan	Author	Acquisition of data and revised the manuscript for intellectual content
Shahnaz Ibrahim	Aga Khan University, Karachi, Pakistan	Author	Acquisition of data and revised the manuscript for intellectual content
Fatima Khan	Aga Khan University, Karachi, Pakistan	Author	Acquisition of data and revised the manuscript for intellectual content
Zul Qarnain	Aga Khan University, Karachi, Pakistan	Author	Acquisition of data and revised the manuscript for intellectual content
Stanislav Groppa, PhD	Institute of Emergency Medicine, Chisinau, Republic of Moldova	Author	Acquisition of data and revised the manuscript for intellectual content
Nin Bajaj, MD, PhD	University of Nottingham, UK	Author	Acquisition of data and revised the manuscript for intellectual content
Bettina Balint, MD	UCL Queen Square Institute of Neurology, London, UK	Author	Acquisition of data and revised the manuscript for intellectual content
Kailash P. Bhatia	UCL Queen Square Institute of Neurology, London, UK	Author	Acquisition of data and revised the manuscript for intellectual content
Andrew Lees, FMedSci, FRCP	UCL Queen Square Institute of Neurology, London, UK	Author	Acquisition of data and revised the manuscript for intellectual content
Patrick J. Morrison, CBE, MD, DSc	Belfast City Hospital, UK	Author	Acquisition of data and revised the manuscript for intellectual content
Nicholas W. Wood, PhD	UCL Queen Square Institute of Neurology, London, UK	Author	Acquisition of data and revised the manuscript for intellectual content
Barbara Garavaglia, PhD	Fondazione IRCCS Istituto Neurologico Carlo Besta, Italy	Author	Acquisition of data and revised the manuscript for intellectual content

Appendix (continued)

Name	Location	Role	Contribution
Henry Houlden, PhD	UCL Queen Square Institute of Neurology, London, UK	Author	Acquisition of data; revised the manuscript for intellectual content; and supervision of the entire process

References

- Nicolas G, Charbonnier C, Campion D, Veltman JA. Estimation of minimal disease prevalence from population genomic data: application to primary familial brain calcification. *Am J Med Genet B Neuropsychiatr Genet* 2018;177:68–74.
- Ramos EM, Carecchio M, Lemos R, et al. Primary brain calcification: an international study reporting novel variants and associated phenotypes. *Eur J Hum Genet* 2018;26:1462–1477.
- Westenberger A, Klein C. The genetics of primary familial brain calcifications. *Curr Neurol Neurosci Rep* 2014;14:490.
- Taglia I, Bonifati V, Mignarri A, Dotti MT, Federico A. Primary familial brain calcification: update on molecular genetics. *Neurol Sci* 2015;36:787–794.
- Yao XP, Cheng X, Wang C, et al. Biallelic mutations in MYORG cause autosomal recessive primary familial brain calcification. *Neuron* 2018;98:1116–1123.e5.
- Grangeon L, Wallon D, Charbonnier C, et al. Biallelic MYORG mutation carriers exhibit primary brain calcification with a distinct phenotype. *Brain* 2019;142:1573–1586.
- Li H, Durbin R. Fast and accurate long-read alignment with Burrows-Wheeler transform. *Bioinformatics (Oxford, England)* 2010;26:589–595.
- McKenna A, Hanna M, Banks E, et al. The Genome Analysis Toolkit: a MapReduce framework for analyzing next-generation DNA sequencing data. *Genome Res* 2010;20:1297–1303.
- Van der Auwera GA, Carneiro MO, Hartl C, et al. From FastQ data to high confidence variant calls: the Genome Analysis Toolkit best practices pipeline. *Curr Protoc Bioinformatics* 2013;43:11.10.1–11.10.33.
- DePristo MA, Banks E, Poplin R, et al. A framework for variation discovery and genotyping using next-generation DNA sequencing data. *Nat Genet* 2011;43:491–498.
- Danecek P, McCarthy SA. BCFtools/csq: haplotype-aware variant consequences. *Bioinformatics (Oxford, England)* 2017;33:2037–2039.
- Yang H, Wang K. Genomic variant annotation and prioritization with ANNOVAR and wANNOVAR. *Nat Protoc* 2015;10:1556–1566.
- Auton A, Auton A, Brooks LD, et al. A global reference for human genetic variation. *Nature* 2015;526:68–74.
- Lek M, Karczewski KJ, Minikel EV, et al. Analysis of protein-coding genetic variation in 60,706 humans. *Nature* 2016;536:285–291.
- Richards S, Aziz N, Bale S, et al. Standards and guidelines for the interpretation of sequence variants: a joint consensus recommendation of the American College of Medical Genetics and Genomics and the Association for Molecular Pathology. *Genet Med* 2015;17:405–424.
- Arkadir D, Lossos A, Rahat D, et al. MYORG is associated with recessive primary familial brain calcification. *Ann Clin Transl Neurol* 2019;6:106–113.
- Chen Y, Fu F, Chen S, et al. Evaluation of MYORG mutations as a novel cause of primary familial brain calcification. *Mov Disord* 2019;34:291–297.
- Forouhdeh Y, Müller K, Ruf W, et al. A biallelic mutation links MYORG to autosomal-recessive primary familial brain calcification. *Brain* 2019;142:e4.
- Peng Y, Wang P, Chen Z, Jiang H. A novel mutation in MYORG causes primary familial brain calcification with central neuropathic pain. *Clin Genet* 2019;95:433–435.
- Batla A, Tai XY, Schottlaender L, Erro R, Balint B, Bhatia KP. Deconstructing Fahr's disease/syndrome of brain calcification in the era of new genes. *Parkinsonism Relat Disord* 2017;37:1–10.
- König P. Psychopathological alterations in cases of symmetrical basal ganglia sclerosis. *Biol Psychiatry* 1989;25:459–468.
- Yamada M, Asano T, Okamoto K, et al. High frequency of calcification in basal ganglia on brain computed tomography images in Japanese older adults. *Geriatr Gerontol Int* 2013;13:706–710.
- Datta K, Guan T, Gerace L. NET37, a nuclear envelope transmembrane protein with glycosidase homology, is involved in myoblast differentiation. *J Biol Chem* 2009;284:29666–29676.
- GTEX Consortium. Human genomics. The genotype-tissue expression (GTEx) pilot analysis: multitissue gene regulation in humans. *Science* 2015;348:648–660.
- Ramasamy A, Trabzuni D, Gueffi S, et al. Genetic variability in the regulation of gene expression in ten regions of the human brain. *Nat Neurosci* 2014;17:1418–1428.