

Contents lists available at [ScienceDirect](https://www.sciencedirect.com)

International Journal of Surgery Case Reports

journal homepage: www.casereports.com

Surgical management of wide intrabony defect underlying midline diastema using Whale's tail flap technique: A Case Report

Avita Rath*, Bennete A. Fernandes, Preena Sidhu, Priyadarshini HR

Faculty of Dentistry, SEGi University, No. 9 Jalan Teknologi, PJU5, 47810 Kota Damansara, Selangor, Malaysia

ARTICLE INFO

Article history:

Received 21 June 2018

Accepted 6 July 2018

Available online 11 July 2018

Keywords:

Gingival recession

Diastema

Surgical flaps

Aesthetics

Guided tissue regeneration

Case report

ABSTRACT

INTRODUCTION: Management of wide midline diastemas accompanying an underlying osseous defect is cumbersome which sometimes yields unpredictable results. However, regenerative therapy of these highly aesthetic zones using a Whale's tail flap technique obtains a maximum papilla fill after placement of the bone graft. This case report illustrated the utilisation of Whale's tail technique of flap for a large interdental defect.

CASE PRESENTATION: A young healthy 31-year-old male patient presented with maxillary midline diastema. Probing depth of 6 mm was also noted over the mesial aspect of the same teeth with localised osseous defect radiographically which lead to a diagnosis of localized chronic periodontitis in relation to those teeth. A Whale's tail technique flap for papilla preservation was performed together with a regenerative procedure using bone graft and GTR membrane.

DISCUSSION: Midline diastema is a common reported complaint in dentistry due to both aesthetic and functional reasons. Following the treatment, 12 months postoperatively, patient had a probing depth reduction of 3 mm and a gain in clinical attachment of 2 mm. The surgical technique allowed regeneration of wide intrabony defects involving the maxillary anterior teeth with notable interdental diastemas.

CONCLUSION: This lead to significant improvement of the hard and soft tissue contour as well as it recreated a functional reattachment which was documented up to 12 months postoperatively.

© 2018 The Authors. Published by Elsevier Ltd on behalf of IJS Publishing Group Ltd. This is an open access article under the CC BY-NC-ND license (<http://creativecommons.org/licenses/by-nc-nd/4.0/>).

1. Introduction

The classical approach to periodontal regeneration has always been the use of bone grafts in repairing periodontal bone defects where the association of guided tissue regeneration with graft materials reported with success for many years [1].

Among various patient, site, and medical factors that influence the clinical outcomes, a critical issue in periodontal regenerative procedures in obtaining and maintaining primary closure over the treated area to ensure adequate protection of the healing events [2,3].

Different surgical procedures have been proposed to preserve the interdental papillary structure during the early and late phases of wound healing to prevent contamination of the regenerating area and subsequent wound failure [4,5]. These procedures, especially the novel minimally invasive techniques, aim to provide greater stability to the blood clot to enhance the regenerative potential [6].

However, the methods as mentioned earlier, carry a possible risk of dissection the papilla that may jeopardise the volume and integrity of interdental tissues [7].

From an anatomical point of view, incision of the defect-associated papilla entails a risk of wound failure, especially in the treatment of deep and wide bony defects that will end with a rather large area that lacks blood supply from periodontal ligament or alveolar bone [1]. In 2009, Bianchi and Bassetti described the "Whale's tail" technique, which was designed to overcome this particular risk, especially in the treatment of deep intrabony defects in the aesthetic zone [8].

This case report revisits this approach of combing a large interdental osseous defect with midline diastema by the successful application of 'the Whale's tail technique' and thereby aid in regeneration. The work has been reported in line with the SCARE criteria [9].

2. Case description

A healthy 31-year-old Indian Malaysian male reported to our institute (March 2017) with a chief complaint of spacing between his maxillary right and left central incisors as well bleeding on brushing concerning his left maxillary central incisor. A comprehensive periodontal examination using William's Periodontal

* Corresponding author.

E-mail addresses: drathavita@yahoo.com (A. Rath), drben17@yahoo.com (B.A. Fernandes), sidhu.preena@gmail.com (P. Sidhu), reachdocpriya@rediffmail.com (P. HR).

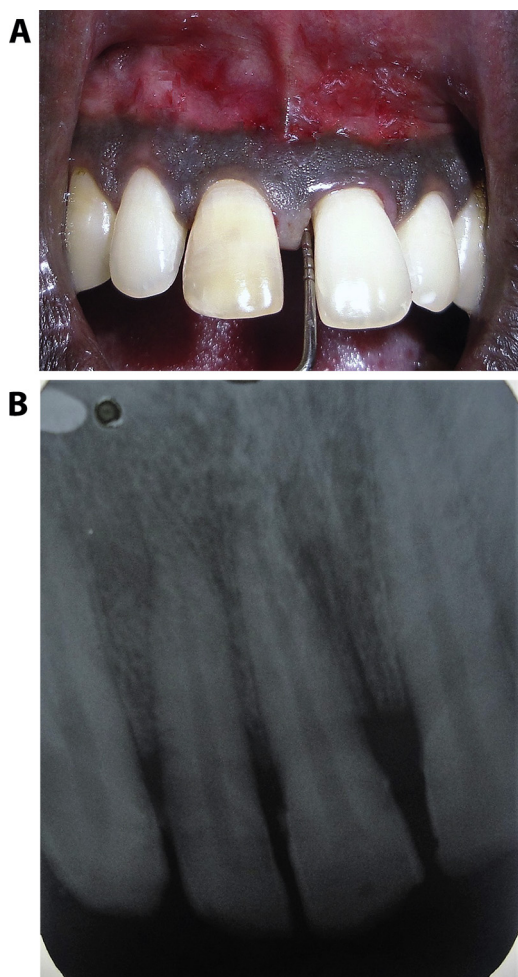


Fig. 1. (A) Clinical examination demonstrated a probing pocket depth of 6 mm 21 facial aspect. (B) Radiographic examination revealed loss of bone levels in relation to 21 and 11.

probe revealed a narrow Miller’s class I gingival recession over the mid-facial surface of tooth 21 and 11. Bleeding on probing along with midline diastema as well as a gingival type frenal attachment was noted. Also, 4 mm and 6 mm probing depth were detected distal to 11 and mesial to 21 respectively along with clinical attachment loss of 8 mm (Fig. 1a). The patients had never visited a dentist before and gave no significant drug and family history. Radiographic examination revealed horizontal bone loss mesial to 21 (Fig. 1b), which gave the diagnosis of localised chronic periodontitis for 21 and 11. The treatment plan was discussed with the patient and the surgical technique opted was a Whale’s tail flap procedure for 21 and 11 based on the bone defect size and the inter-papillary width. It was further decided to combine the technique with bone graft and GTR membrane for a more predictable regenerative outcome. Patient gave his informed and written consent to the same.

Two weeks after the non-surgical therapy of scaling and root planing and pre-emp antibiotic regimen of 500 mg Amoxicillin TID for 5 days, on the day of the surgery after local anaesthesia was administered, incision points were marked at 21 and 11 region, following which two vertical full-thickness incisions were made from the mucogingival line to the distal margin of the tooth neighbouring the defect on the buccal surface. Finally, a Whale’s tail-shaped horizontal incision joined the apical margins of the first two incisions. Crevicular incisions were made in the mesiobuccal, interproximal, and palatal aspects of 21 and 11 (Fig. 2). A full thickness mucoperiosteal flap was reflected from the buccal to the

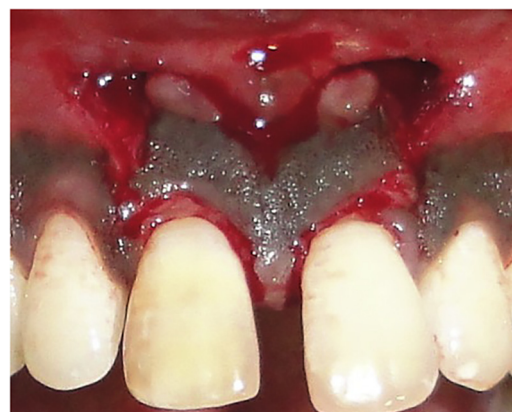

Fig. 2. Whale’s tail full-thickness mucoperiosteal flap elevated in relation to 21 and 11.

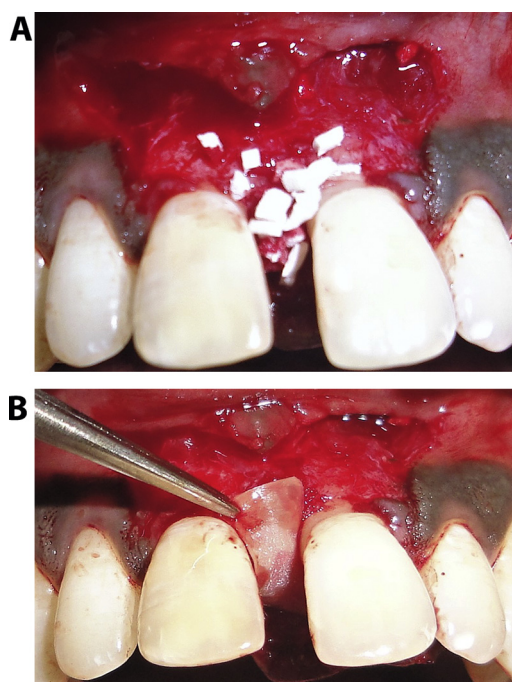


Fig. 3. (a) Management of the recipient site. Bone graft placed. (b) Management of the recipient site. GTR membrane placed.

palatal side following which complete removal of granulation tissue and scaling and root planning was done. Bone graft (Perioglas®) was placed along with GTR membrane (Healiguide®) covering the defect (Fig. 3a, b), following which flap was repositioned back. 4-0 Ethicon, non-resorbable, perimeter sutures were placed, without tension, away from the margins (Fig. 4). The periodontal dressing was placed. Postoperative instructions and prescription for 0.12% Chlorhexidine mouthrinse were given for 15 days. The patient was recalled after two weeks for suture removal, and post-op follow up to 12 months duration.

Following the treatment, six months postoperatively, probing depth reduced by 3 mm and gain in the clinical attachment of 2 mm. The result was stable and aesthetically satisfactory (Fig. 5a) until 12 months. A slight increase in bone height was also noted radiographically (Fig. 5b) when examined at 12 months post-op.

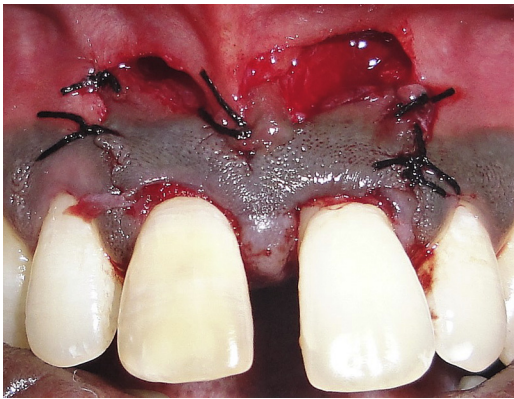

Fig. 4. Perimeter sutures placed and the Whale's tail flap secured for primary closure.

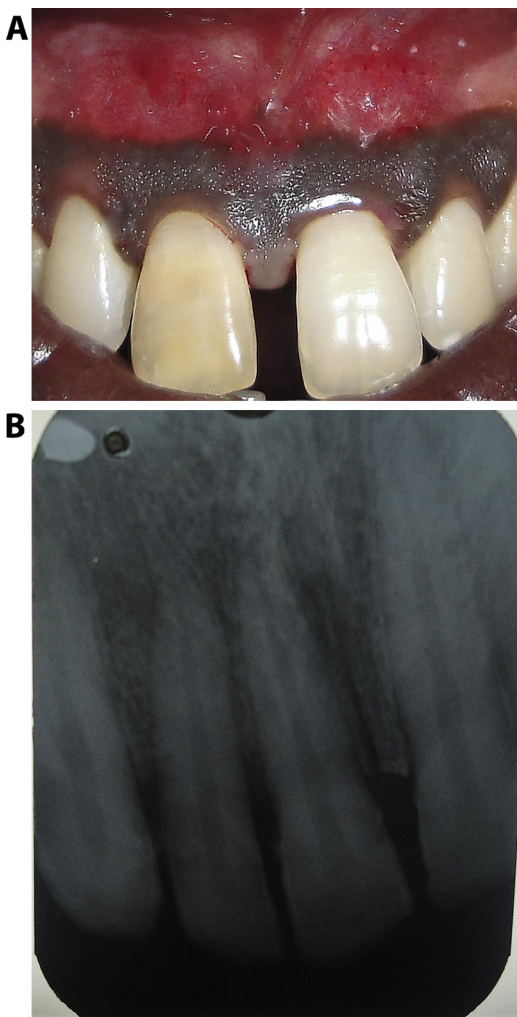


Fig. 5. (a) Healing of the recipient site 12 months postoperatively. (b) Radiographic examination after 12 months post-op revealing bone fill.

3. Discussion

This case report demonstrated a successful utilization of 'Whale-tail technique' procedure for management of wide osseous defect at an aesthetic area. The clinical outcome was documented to be stable for 12 months. Aesthetic considerations always pose therapeutic dilemmas in the selection of the appropriate surgical technique in the maxillary anterior region to prevent or minimize

aesthetic problems such as loss of interdental papilla or increased tooth length without compromising the primary goal of periodontal surgery [10]. Preservation of papillary integrity is essential for maintaining aesthetics [11]. Long-term evaluation period after the use of papilla preservation technique, revealed stable results, although a partial exposure of the buccal root surface of some teeth did occur [10].

This limitation was addressed in the Whale's tail technique, by elevation of a large buccal flap, which allowed the preservation of a significant amount of soft tissue as well as facilitating access and visualization of the defect [8]. Clinical findings obtained with this technique in terms of CAL gain (2 mm) and PPD reduction (3 mm) and radiographic bone fill were comparable with the results achieved with other clinical studies in which the same technique was adopted [8,12,13]. Soft tissue healing is dependent on many factors: incision technique, flap design, tissue manipulation, post-surgical follow-up, and patient cooperation [14]. In this case, the systematic use of incisions distant from the defects and biomaterial margins drastically reduced the percentage of flap dehiscence due to bacterial colonization. Furthermore, the handling of the interdental papilla was easier and more convenient than the conventional technique [4]. Moreover, the patient was also satisfied as aesthetically there was no visible scar formation as well teeth felt more stable and there was no discomfort reported post-surgery.

4. Conclusion

The purpose of this case report was to describe the efficacy of Whale's tail technique to the specialists and clinicians to achieve primary closure and thereby aid in regeneration of an interdental osseous defect between maxillary central incisors where esthetic is the main concern. More extensive long-term clinical trials are needed to evaluate patient comfort and predictability of this approach with similar bone defects in the esthetic zone.

Conflicts of interest

None to be declared.

Funding

None.

Ethical approval

SEGi Health sciences ethical committee has exempted this technique from any ethical approval as it not the first in-man study provided patients gives the consent for it. This is a better modification of papilla preservation technique but on diastema and bigger defects.

Consent

Written informed consent was obtained from the patient for publication of this case report and accompanying images. A copy of the written consent is available for review by the Editor-in-Chief of this journal on request.

Author contributions

Dr. Avita Rath: case conceptualization and design, follow up of the patient, drafting of the manuscript.

Dr. Bennete Fernandes: case follow up, revising it critically for important intellectual content.

Dr. Preena Sidhu: revising of the manuscript and final approval of the version.

Dr Priyadarshini HR: critical evaluation and revising of the manuscript and final approval of the version.

Registration of research studies

NA.

Guarantor

Avita Rath.

Acknowledgement

None.

References

- [1] S. Aslan, N. Buduneli, P. Cortellini, Entire Papilla Preservation Technique: a novel surgical approach for the regenerative treatment of deep and wide intrabony defects, *Int. J. Periodontics Restorative Dent.* 37 (2017) 227–233.
- [2] K.S. Kornman, P.B. Robertson, Fundamental principles affecting the outcomes of therapy for osseous lesions, *Periodontol.* 2000 22 (2000) 22–43.
- [3] R. Farina, A. Simonelli, A. Rizzi, M. Pramstraller, A. Cucchi, L. Trombelli, Early postoperative healing following buccal single flap approach to access intraosseous periodontal defects, *Clin. Oral Investig.* 17 (2013) 1573–1583.
- [4] H.H. Takei, T.J. Han, F.A. Carranza Jr., E.B. Kenney, V. Lekovic, Flap technique for periodontal bone implants. Papilla preservation technique, *J. Periodontol.* 56 (1985) 204–210.
- [5] P. Cortellini, G. Pini Prato, M.S. Tonetti, Periodontal regeneration of human intrabony defects with titanium reinforced membranes. A controlled clinical trial, *J. Periodontol.* 66 (1995) 797–803.
- [6] G. Pellegrini, G. Pagni, G. Giulio Rasperini, Surgical approaches based on biological objectives: GTR versus GBR techniques, *Int. J. Dent.* 2013 (2013), 521547.
- [7] C.A. Damante, A.C.P. Sant'Ana, M.L.R. de Rezende, S.L. Aguiar Gregghi, E. Passanezi, Guided tissue regeneration and papilla preservation with the "Whale's tail" flap, *JSM Dent.* 1 (2013) 1017.
- [8] A. Bianchi, A. Bassetti, Flap design for guided tissue regeneration surgery in the esthetic zone: the "Whale's tail" technique, *Int. J. Periodontics Restorative Dent.* 29 (2009) 153–159.
- [9] R.A. Agha, A.J. Fowler, A. Saetta, I. Barai, S. Rajmohan, D.P. Orgill, for the SCARE group, The SCARE statement: consensus-based surgical case report guidelines, *Int. J. Surg.* (2016).
- [10] L. Checchi, M. Montevicchi, V. Checchi, G.A. Bonetti, A modified papilla preservation technique, 22 years later, *Quintessence Int.* 40 (2009) 303–311.
- [11] N.D. Jampani, V.M. Songa, L. Buggapati, S. Mittapally, Bone grafting with novel flap design and management of midline diastema: an interdisciplinary perio-ortho approach, *J. NTR Univ. Health Sci.* 5 (2016) 70–74.
- [12] M.M. Deshpande, S.J. Jarde, R.S. Wilson, A. Chatterjee, Whale's tail technique: a case series, *J. Indian Soc. Periodontol.* 20 (2016) 460–463.
- [13] A. Kuriakose, A. Majo, J. Jacob, P. John, Modified Whale's tail technique for the management of bone-defect in anterior teeth, *J. Indian Soc. Periodontol.* 19 (2015) 103–106.
- [14] M.S. Tonetti, G.P. Prato, P. Cortellini, Factors affecting the healing response of intrabony defects following guided tissue regeneration and access flap surgery, *J. Clin. Periodontol.* 23 (1996) 548–556.

Open Access

This article is published Open Access at [sciencedirect.com](https://www.scienceopen.com). It is distributed under the [IJSCR Supplemental terms and conditions](#), which permits unrestricted non commercial use, distribution, and reproduction in any medium, provided the original authors and source are credited.