

# Open Abdomen Negative Pressure Device Applied for Two-stage Closure of Enterocutaneous Fistula

Kou Fujisawa, MD, PhD  
Maki Kitatsuji, MD  
Yusuke Yamamoto, MD

**Summary:** Enterocutaneous fistula (ECF), which is an abnormal connection between the gastrointestinal tract and skin, is a serious complication of abdominal surgery, and a multidisciplinary approach is required for its treatment. Here, we report the case of a 46-year-old woman who had a large ECF measuring 6 × 12 cm that was successfully treated with a 2-stage surgery. After the first surgery of intestinal wall reconstruction, an abdominal negative pressure wound therapy (NPWT) device was administered to facilitate the reexploration of the abdominal cavity. On postoperative day 5, intestinal perforation and abdominal cavity infection were found during dressing change and were immediately repaired. Subsequently, after 10 days of abdominal NPWT, the second surgery comprising abdominal wall reconstruction was performed using a pedicled anterolateral thigh flap (8 × 19 cm) combined with the fascia lata (12 × 20 cm). The defective rectus sheath and skin were uneventfully closed with the fascia lata and flap skin paddle, respectively. In the follow-up after 7 months, ECF had not recurred. The abdominal NPWT device enabled easy reentry of the abdominal cavity and reduced the size of the flap needed to cover the defect. Moreover, open abdominal management can be performed consistently, independent of the surgeon's expertise. Therefore, this report suggests that 2-stage surgery with abdominal NPWT management is a useful strategy for ECF treatment. (*Plast Reconstr Surg Glob Open* 2020;8:e3369; doi: 10.1097/GOX.0000000000003369; Published online 1 February 2021.)

## INTRODUCTION

Enterocutaneous fistula (ECF), which is defined as an abnormal connection between the intestinal tract and a skin wound, is one of the most critical complications of abdominal surgery. A multidisciplinary approach is required for its treatment including nutritional support, electrolyte control, and wound care.<sup>1-3</sup> Despite the advances in clinical management and surgical reconstruction technique, treating ECF is still challenging for plastic surgeons, and the reported mortality rates of ECF are over 10%.<sup>1,4</sup>

Recently, the abdominal dressing negative pressure system has emerged as a useful option of negative pressure wound therapy (NPWT) for open abdomen management.<sup>5</sup> This system includes a nonadhesive visceral protective layer, which prevents sponge adherence, and direct negative pressure to

intra-abdominal vital organs. Although abdominal NPWT is suggested to be a versatile tool that is applicable in several indications, only a few cases have been reported.<sup>6</sup> Here, we present a case of ECF that was successfully treated with a combination of abdominal NPWT and perforator flap surgery.

## CASE REPORT

A 46-year-old woman presented with a large ECF measuring 6 × 12 cm (Fig. 1). Her medical history was notable for a colon resection and colostomy due to ulcerative colitis at 15 years of age. Three years previously, she underwent enucleation of a smooth muscle tumor in the uterus and partial resection of the small intestine, which adhered to the tumor. One month later, enterectomy was performed for postoperative adhesive intestinal obstruction. However, postoperative anastomotic leakage and skin wound dehiscence resulted in a large ECF. Subsequently, a large pouch covering the fistula and an ostomy bag had been always necessary. Additionally, the uterine tumor had gradually recurred. Therefore, tumor resection and abdominal wall reconstruction were planned.

Partial hysterectomy, removal of tumor adhesion to the small intestine, and intestinal tract reconstruction were performed first (Fig. 2). Considering abdominal

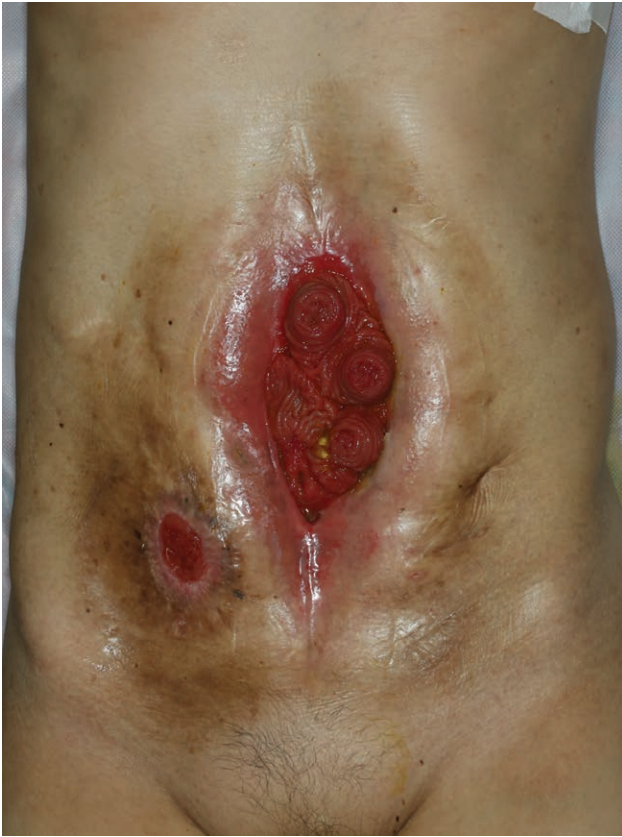From the Department of Plastic Surgery, Shizuoka General Hospital, Shizuoka, Japan.

Received for publication October 11, 2020; accepted November 23, 2020.

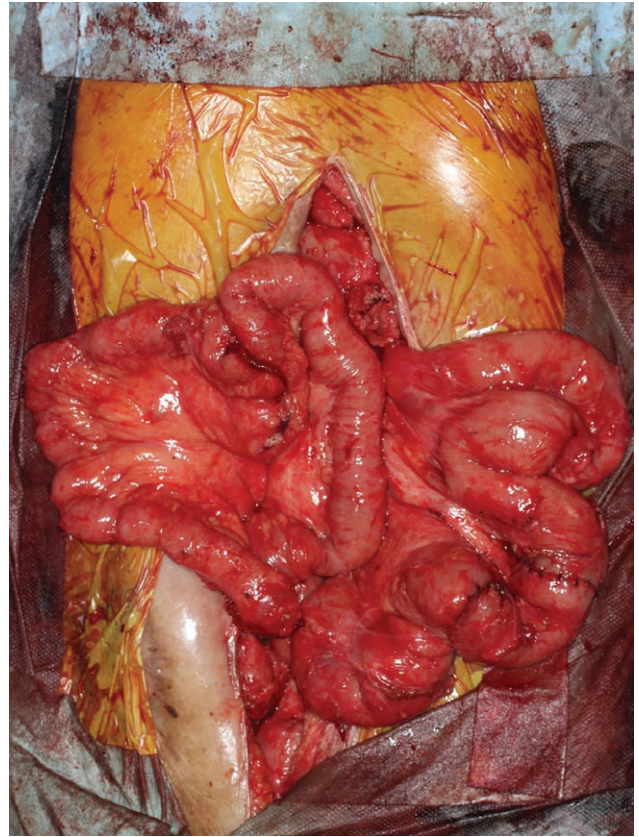
Copyright © 2021 The Authors. Published by Wolters Kluwer Health, Inc. on behalf of The American Society of Plastic Surgeons. This is an open-access article distributed under the terms of the Creative Commons Attribution-Non Commercial-No Derivatives License 4.0 (CCBY-NC-ND), where it is permissible to download and share the work provided it is properly cited. The work cannot be changed in any way or used commercially without permission from the journal.

DOI: 10.1097/GOX.0000000000003369

**Disclosure:** The authors have no financial interest to declare in relation to the content of this article.



**Fig. 1.** Enterocutaneous fistula along the midline of the abdominal wall and a stoma in the lower right abdomen.



**Fig. 2.** Reconstructed small intestine.

postoperative complications, open abdomen management was chosen after the surgery using the abdominal NPWT system (ABThera; KCI) (Fig. 3). Continuous  $-125$  mm Hg negative pressure was applied to the abdominal cavity, and the dressing was changed every 2 to 3 days.

On postoperative day 5, intraperitoneal contamination due to an intestinal perforation was observed. The perforated site was not in contact with the visceral protective layer. The perforation was closed by suturing, and the abdominal cavity was lavaged thoroughly. Open abdomen management was uneventful in the subsequent week. On postoperative day 15, abdominal wall reconstruction using a perforator flap was performed. A pedicled left anterolateral thigh (ALT) flap ( $8 \times 19$  cm) with the fascia lata ( $12 \times 20$  cm) was harvested and moved to the abdomen through the subcutaneous tunnel. The fascia of the flap was tightly fixed on the anterior rectus sheath, and the skin defect was covered with the flap skin paddle. After 7 months of follow-up, there was no recurrence of fistula, and the pouch covering the fistula was not needed (Fig. 4).

## DISCUSSION

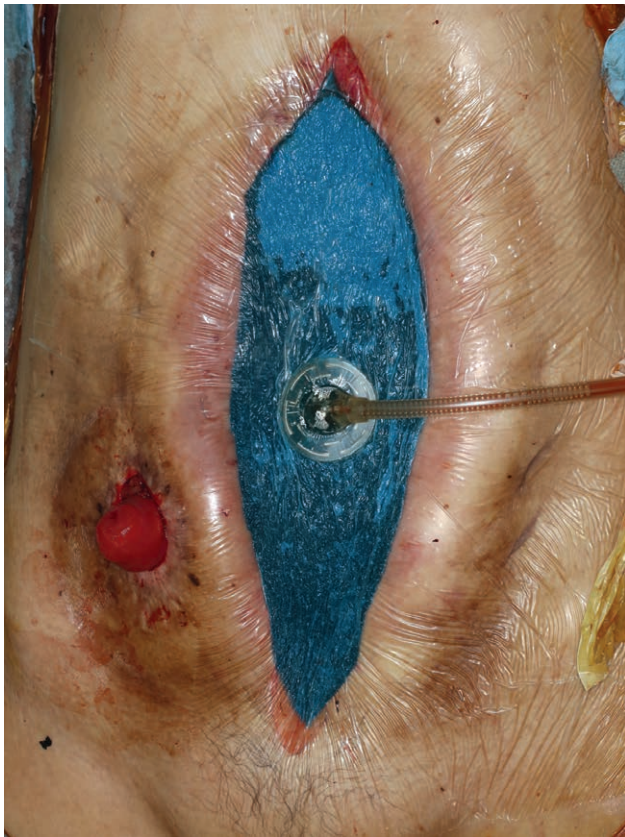In this report, we have described the 2-stage surgery for the treatment of large ECF. The first and second surgeries were the reconstruction of the intestinal wall and abdominal wall using pedicled ALT flap, respectively.

Open abdomen management using an abdominal NPWT device played a pivotal role in the 2 surgeries.

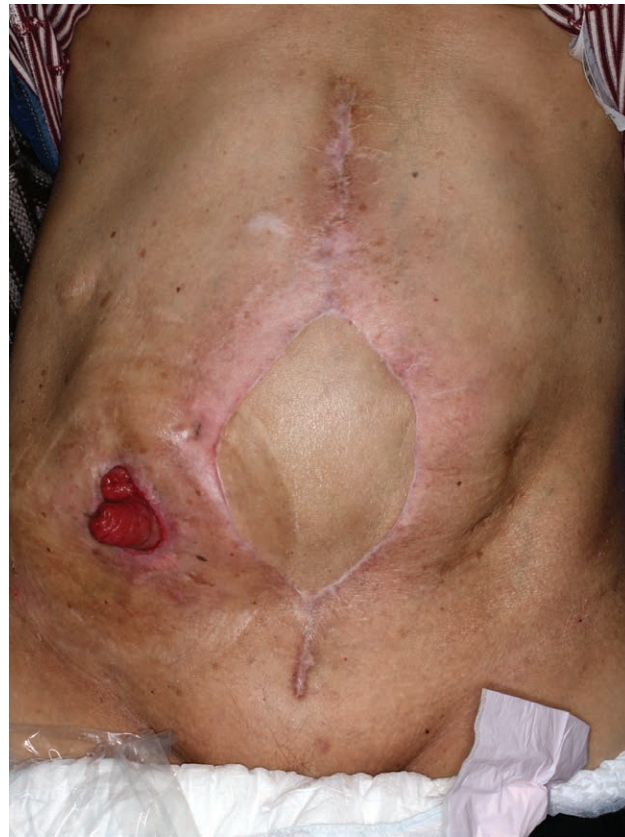Although open abdomen management is mostly used for abdominal trauma, nontrauma applications are increasingly becoming common.<sup>2,7,8</sup> Major indications of open abdomen management include controlling abdominal compartment syndrome, infection, hemorrhage, or the need for a second-look procedure.<sup>8</sup> In this case, the risk for postsurgical abdominal complications was expected to be high because the patient had a medical history of several abdominal surgeries, postoperative intestinal obstruction, and anastomotic leakage. Therefore, open abdominal management was applied to deal with these problems. As expected, an intestinal perforation occurred, and the open abdomen management facilitated reentry of the abdominal cavity, early detection of the intestinal perforation, and repair surgery.

The use of abdominal NPWT has several advantages for abdominal wall reconstruction. First, the negative pressure of this system prevents lateral retraction of the abdominal sheath and skin wound edge.<sup>9</sup> Abdominal wall traction helps to reduce the size of the flap skin paddle and fascia needed to cover the defect and minimize the donor-site morbidity. Second, the blood flow and survival of a pedicled ALT flap can be secured. Because abdominal NPWT actively removes intraperitoneal fluid,<sup>9</sup> the abdominal wall is free from hematoma or edema, which leads to thrombosis of the pedicle vessels. Finally, because all components of this method are commercially manufactured, consistent treatment and





**Fig. 3.** Dressing drape and foam covering the abdominal cavity.



**Fig. 4.** Abdomen at 7 months postoperative.

dressing changes can be achieved in a time-saving manner independent of the surgeon's experience and skill.<sup>8</sup>

Open abdomen management and abdominal NPWT are associated with several problems, such as fluid and protein loss, malnutrition, and prolonged hospital stay. One of the most serious complications is an enteroatmospheric fistula, which is caused by an intestinal perforation.<sup>2</sup> In this case, although the intestinal perforation was identified, the perforated site was not exposed to the visceral protective layer. Therefore, it is improbable that the perforation was caused by abdominal NPWT. The most probable explanation for the perforation was the intestinal wall injury that occurred in the first surgery. Although the incidence of enteroatmospheric fistula is lower in abdominal NPWT than in conventional open management,<sup>10</sup> these complications should be kept in mind.

**Kou Fujisawa, MD, PhD**

Department of Plastic Surgery  
Shizuoka General Hospital  
4-27-1 Kita Ando, Aoi-ku, Shizuoka City  
Shizuoka Prefecture 420-8527, Japan  
E-mail: kofujisawa@gmail.com

### ACKNOWLEDGMENTS

The authors would like to thank Kou Ohata, Kyota Tatsuta, and the staff of Department of Surgery at Shizuoka General Hospital for technical support.

Statement of Conformity: This study was conducted in accordance with the Declaration of Helsinki.

### REFERENCES

1. Mawdsley JE, Hollington P, Bassett P, et al. An analysis of predictive factors for healing and mortality in patients with enterocutaneous fistulas. *Aliment Pharmacol Ther.* 2008;28:1111–1121.
2. Demetriades D, Salim A. Management of the open abdomen. *Surg Clin North Am.* 2014;94:131–153.
3. Quinn M, Falconer S, McKee RF. Management of enterocutaneous fistula: outcomes in 276 patients. *World J Surg.* 2017;41:2502–2511.
4. Misky A, Hotouras A, Ribas Y, et al. A systematic literature review on the use of vacuum assisted closure for enterocutaneous fistula. *Colorectal Dis.* 2016;18:846–851.
5. Zuriarrain A, Shay A, Demarest G. The sentinel placement of an open abdomen negative pressure unit. *Int J Surg Case Rep.* 2011;2:4–5.
6. Kocaaslan FND, Ozkan MC, Akdeniz Z, et al. Use of abdominal negative pressure wound therapy in different indications: a case series. *J Wound Care.* 2019;28:240–244.
7. Boele van Hensbroek P, Wind J, Dijkgraaf MG, et al. Temporary closure of the open abdomen: a systematic review on delayed primary fascial closure in patients with an open abdomen. *World J Surg.* 2009;33:199–207.
8. Fernández LG. Management of the open abdomen: clinical recommendations for the trauma/acute care surgeon and general surgeon. *Int Wound J.* 2016;13(suppl 3):25–34.
9. Montori G, Allievi N, Coccolini F, et al. Negative Pressure Wound Therapy versus modified Barker Vacuum Pack as temporary abdominal closure technique for Open Abdomen management: a four-year experience. *BMC Surg.* 2017;17:86.
10. Hougaard HT, Ellebaek M, Holst UT, et al. The open abdomen: temporary closure with a modified negative pressure therapy technique. *Int Wound J.* 2014;11(suppl 1):13–16.