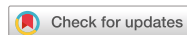

Case Report



Echovirus-7 Infection in Children with Unusual Severe Manifestation: A Case Report

Antonius Hocky Pudjiadi ¹, Ungke Antonjaya ², Khin Saw Myint ³, and Fatima Safira Alatas ¹

¹Department of Child-Health, Cipto Mangunkusumo Hospital, Faculty of Medicine Universitas Indonesia, Jakarta, Indonesia

²Eijkman Oxford Clinical Research Unit, Eijkman Institute for Molecular Biology, Jakarta, Indonesia

³Emerging Virus Research Unit, Eijkman Institute for Molecular Biology, Jakarta, Indonesia

OPEN ACCESS

Received: Jul 25, 2020

Accepted: Dec 14, 2020

Corresponding Author:

Antonius Hocky Pudjiadi, MD, PhD

Department of Child-Health, Cipto Mangunkusumo Hospital, Faculty of Medicine Universitas Indonesia, Jl. Salemba Raya No. 6, Jakarta 10430, Indonesia.

Tel: +622131930373

Fax: +62213912477

E-mail: ahpudjiadi@gmail.com


Copyright © 2021 by The Korean Society of Infectious Diseases, Korean Society for Antimicrobial Therapy, and The Korean Society for AIDS

This is an Open Access article distributed under the terms of the Creative Commons Attribution Non-Commercial License (<https://creativecommons.org/licenses/by-nc/4.0/>) which permits unrestricted non-commercial use, distribution, and reproduction in any medium, provided the original work is properly cited.


ORCID iDs

Antonius Hocky Pudjiadi 

<https://orcid.org/0000-0002-5675-195X>

Ungke Antonjaya 

<https://orcid.org/0000-0002-5649-9002>

Khin Saw Myint 

<http://orcid.org/0000-0002-2087-7331>

Fatima Safira Alatas 

<https://orcid.org/0000-0003-1299-7154>

Conflict of Interest

No conflict of interest.

ABSTRACT

We report a rare laboratory-confirmed, clinical case of Echovirus-7 infection in an immuno-competent child with central nervous system and systemic manifestation. Echovirus infection is usually mild, however in this case we identified echovirus-7 infection with 91% homology with the Echovirus-7 strain previously isolated in neighbouring country with severe manifestation.

Keywords: Echovirus-7; Enterovirus; Encephalitis; Sepsis; qRT-PCR

INTRODUCTION

Echovirus is a non-polio Enterovirus of B-species that is once thought to be a harmless, orphan virus. Ubiquitously found, Echovirus-7 accounts for 4% of Enterovirus infection in the United States [1]. Although very rare, severe manifestation of Echovirus-7 infection had been reported in neonates and infants [2-4]. Recent reports showed that Echovirus-7 could also infect older children, ranging from a milder manifestation of hand foot mouth disease (HFMD) up to a more severe form of meningoencephalomyelitis [5, 6].

Enteroviruses infections in Indonesia, although considered slender, are rarely supported by laboratory evidence due to limited virology testing capability. Hence most cases are diagnosed based on clinical findings and in correlation to an occurring outbreak in neighboring South East Asian countries. Human Enterovirus-71 (HEV-71) is the most common Enterovirus attributed to severe and fatal cases, within the region.

Recently, we performed virology testing for Enterovirus panel (Enterovirus group and HEV-71) from 4 patients with various severe clinical symptoms (severe diarrhea, sepsis, central nervous system infections) and found one confirmed case of Echovirus-7 infection. In this report, we present a fatal case of Echovirus-7 infection, supported by laboratory evidence for the first time in Indonesia with the aim to increase awareness of the existence of severe and systemic Echovirus-7 infections.

Author Contributions

Conceptualization: PAH, AFS. Data curation: AFS. Formal analysis: PAH, AFS. Investigation: PAH, AU, MKS, AFS. Methodology: AU, MKS. Project administration: AFS. Supervision: PAH, AFS. Writing - original draft: PAH, AU, AFS. Writing - review & editing: PAH, MKS, AFS.

CASE REPORT

Our case was a healthy two years eight months old boy, presenting with high fever and seizure to the Emergency Room of Dr. Cipto Mangunkusumo Hospital. Allo-anamnesis suggested that patient had generalized tonic-clonic seizure lasting for about 5 minutes at home around 30 minutes prior to second episode of seizure with the same characteristic at the emergency room, in which patient was unconscious in between seizure episodes. Upon admission the Glasgow Coma Scale was 9, work of breathing was increased with a respiratory rate of 60/min, heart rate of 175/min, cold extremities, capillary refill time (CRT) >2 seconds, blood pressure 90/60 mmHg, and rectal temperature of 40°C. Both pupils were isochoric (3 mm/3 mm), the conjunctiva was pale. Lung auscultation revealed rales on both lungs. Meningeal signs were negative, and focal neurological deficit was not found. The remaining physical examination findings were unremarkable. There was no history of severe illness, nor a family history of similar disease. The patient was resuscitated and got an early cephalosporin injection (cefotaxime 4 x 600 mg) as suggested by the surviving sepsis campaign [7]. Phenobarbital and valproic acid were given to control seizures.

Laboratory examinations revealed normal Blood Gas Analysis (BGA), anemia (Hemoglobin (Hb) 7.7 g/dL), thrombocytopenia (81,000/mm³), leukopenia (2,560/mm³) with differential count showing mild neutrophilia (78.5%). Lactate was increased (3.1 mmol/L) and procalcitonin was spiking (95.47 ng/mL). The electrolyte analysis result showed hypokalemia (2.56 mEq/L). Samples from blood, urine, sputum, and cerebrospinal fluid were collected for microbial investigation. Urinalysis revealed normal. CSF analysis showed the following characteristics: clear, colorless, total cell count was 30/mm³ (segmented neutrophil 27/mm³ and lymphocytes 3/mm³), protein 7 g/dL and glucose 76 mg/dL, with negative Nonne and Pandy tests. Radiographic findings showed minimal lung pathology.

Sputum culture was positive for *Pseudomonas aeruginosa* and was sensitive to cephalosporin given. No growth was found for urine, blood and CSF cultures. Serial peripheral blood, BGA, electrolyte analysis were performed along with coagulation analysis, liver, and kidney function tests. The child was unstable. Later on his liver function deteriorated, (ALT (Alanine aminotransferase) 520 U/L and AST (Aspartate aminotransferase) 505 U/L) most likely attributed to his septic condition.

On day-35 of hospitalization, he developed an acute gastrointestinal injury. The abdomen was distended, with no bowel sound, and bilious gastric tube. On day 37 he developed disseminated intravascular coagulation (DIC) with excessive bleeding from the upper gastrointestinal tract (hematemesis). Hemoglobin level was decreased to 8.56 g/dL, and platelets count was reduced to 87,200/uL, prothrombin time (PT) and activated partial thromboplastin (aPTT) time were prolonged. On day 39 the patient eventually succumbed to illness due to severe bleeding from DIC (disseminated intravascular coagulation).

1. Pathogen Identification

With a differential diagnosis of Enterovirus infection, a set of sample (nasal swab, throat, and rectal swab) collected five days after admission stored in viral transport medium as well as CSF were sent to Eijkman Institute for Molecular Biology for viral testing and tested by real-time reverse transcriptase polymerase chain reaction (qRT-PCR) for Enterovirus group and Enterovirus 71 following published methods [8, 9]. RNA from polio virus (OPV) was used as positive control for Enterovirus panel assay. Results revealed no detectable cycle threshold

(Ct) for Enterovirus 71 in all samples. For Enterovirus group, Ct for rectal swab, nasal swab, throat swab and CSF were 22.7, 29.6, 30.89 and 35.26 respectively showing amplification for Enterovirus genome.

Sequencing of VP1 gene was performed using method previously described by Leitch et al [10]. An amplification of 946 bases was produced and sequenced. Results revealed the virus genome sequence shared 91% homology with the Echovirus-7 strain previously isolated in Malaysia [6]. We then administered our nucleotide sequence under GenBank Accession number MK993376.

DISCUSSION

This is the first case report of Echovirus-7 systemic infection involving CNS in Indonesia. In addition to encephalitis, the patient had multisystem involvement including sepsis, pneumonia, acute gastrointestinal injury, and coagulopathy. A similar case of Echovirus-7 meningoencephalitis encephalomyelitis with close identity to our stain was recently reported in Malaysia [6]. CNS involvement of Echovirus-7 was reported as far as five decades ago in India and Sweden [11, 12]. The qRT-PCR in our study detected more positives from the rectal and respiratory swabs than CSF with low viral titers [13]. In EV suspected CNS infections, it is suggested to test at least one respiratory specimen with throat swab recommended as the single most useful specimen [14].

Our patient runs into encephalitis, pneumonia and septic shock with hyperthermia, tachycardia, tachypnea, low blood pressure, cold extremities, prolonged capillary refill time, high lactate, coagulopathy, abnormal leukocyte counts, and high procalcitonin levels. Similar cases were reported by Lum et al [6] in which two out of three cases with Echovirus-7 encephalomyelitis developed sepsis during infection. DIC was evident from bleeding manifestation, including epistaxis, hematemesis, and hematochezia along with thrombocytopenia, increased PTT and aPTT. A similar case was reported by Tancabelic J et al [15]. on coagulopathy in a neonate due to systemic Echovirus-7 infection most likely due to an immunocompromised state. However, coagulopathy due to Echovirus-7 infection has never been reported in older patients. Liver failure could aggravate uncontrolled bleeding due to impaired procoagulant synthesis.

Although gastrointestinal bleeding could be a DIC manifestation, abdominal distention with decreased bowel sounds along with bilious gastric tube suggested the presence of acute gastrointestinal injury. Castro reported a similar presentation on Echovirus-7 infection in a premature infant [2]. The initial diagnosis of this case was necrotizing enterocolitis, but exploratory laparotomy revealed focal hemorrhage within the intestinal wall, which explained the bloody stool.

We report a fatal case of two and half year old boy with Echovirus-7 infection presenting with unusual and severe clinical manifestations. Echovirus-7 is a ubiquitous Enterovirus that was once deemed non-infectious or only manifested as a mild respiratory tract illness. Recently, several cases of neonatal and infant fatal manifestation of Echovirus-7 are reported [2-4]. The clinical severity may be explained by genetic drift of Echovirus-7 as previously postulated by Yao et al [5] who performed a phylogenetic study that mapped Echovirus-7 genome as a recombinant of coxsackie virus B4 and Echovirus-7 Wallace strain from a child with hand-

foot-mouth-disease. Coxsackie virus B4 was noted for its 9.8% fatality rate and association with severe CNS and respiratory syndromes [5]. A complete genomic sequence of the Indonesian Echovirus-7 is not available for analysis, however it is possible that similar genetic drift had occurred, as our patient did not have any history of foreign travel hence suggesting that the virus was contracted locally.

To our knowledge, Echovirus-7 infection has never been reported in Indonesia. Furthermore, a severe manifestation of Echovirus-7 infection in an older and immunocompetent child is rarely reported. We hope that this case report can raise the clinical awareness of possible systemic involvement of Echovirus-7, for early recognition and treatment to increase the likelihood of patient's survival.

ACKNOWLEDGMENTS

We would like to acknowledge Stephanie Wijaya, M.D, M.Res for collecting the patient's data and helping with proofreading of the article, Decy Subekti, Ph.D the Head of Virology Unit of Eijkman Oxford Laboratory, and finally the patient and family for their willingness to share the clinical data for this case report. We would also like to thank Medical Faculty Universitas Indonesia and Eijkman Institute for providing the facility and information needed for this article.

REFERENCES

1. Khetsuriani N, Lamonte-Fowlkes A, Oberst S, Pallansch MA; Centers for Disease Control and Prevention. Enterovirus surveillance--United States, 1970-2005. *MMWR Surveill Summ* 2006;55:1-20.
[PUBMED](#)
2. Castro R. Echovirus 7 infection and necrotizing enterocolitis-like symptoms in a premature infant. *J Perinatol* 2000;20:558-61.
[PUBMED](#) | [CROSSREF](#)
3. Kazzi NJ, Cepeda EE, Budev H. Fatal echovirus type 7 in a premature infant. *Am J Perinatol* 1988;5:236-8.
[PUBMED](#) | [CROSSREF](#)
4. Wreghitt TG, Sutehall GM, King A, Gandy GM. Fatal echovirus 7 infection during an outbreak in a special care baby unit. *J Infect* 1989;19:229-36.
[PUBMED](#) | [CROSSREF](#)
5. Yao X, Bian LL, Mao QY, Zhu FC, Ye Q, Liang ZL. Echovirus 7 associated with hand, foot, and mouth disease in mainland China has undergone a recombination event. *Arch Virol* 2015;160:1291-5.
[PUBMED](#) | [CROSSREF](#)
6. Lum LC, Chua KB, McMin PC, Goh AY, Muridan R, Sarji SA, Hooi PS, Chua BH, Lam SK. Echovirus 7 associated encephalomyelitis. *J Clin Virol* 2002;23:153-60.
[PUBMED](#) | [CROSSREF](#)
7. Barochia AV, Cui X, Eichacker PQ. The surviving sepsis campaign's revised sepsis bundles. *Curr Infect Dis Rep* 2013;15:385-93.
[PUBMED](#) | [CROSSREF](#)
8. Beld M, Minnaar R, Weel J, Sol C, Damen M, van der Avoort H, Wertheim-van Dillen P, van Breda A, Boom R. Highly sensitive assay for detection of enterovirus in clinical specimens by reverse transcription-PCR with an armored RNA internal control. *J Clin Microbiol* 2004;42:3059-64.
[PUBMED](#) | [CROSSREF](#)
9. Khanh TH, Sabanathan S, Thanh TT, Thoa le PK, Thuong TC, Hang Vt, Farrar J, Hien TT, Chau Nv, van Doorn HR. Enterovirus 71-associated hand, foot, and mouth disease, Southern Vietnam, 2011. *Emerg Infect Dis* 2012;18:2002-5.
[PUBMED](#) | [CROSSREF](#)

10. Leitch EC, Harvala H, Robertson I, Ubillos I, Templeton K, Simmonds P. Direct identification of human enterovirus serotypes in cerebrospinal fluid by amplification and sequencing of the VP1 region. *J Clin Virol* 2009;44:119-24.
[PUBMED](#) | [CROSSREF](#)
11. Madhavan HN, Sharma KB. Enteroviruses from cases of encephalitis in Pondicherry. *Indian J Med Res* 1969;57:1607-10.
[PUBMED](#)
12. Andersson SO, Björkstén B, Burman LA. A comparative study of meningoencephalitis epidemics caused by echovirus type 7 and coxsackievirus type B5. Clinical and virological observations during two epidemics in northern Sweden. *Scand J Infect Dis* 1975;7:233-7.
[PUBMED](#) | [CROSSREF](#)
13. Landry ML, Garner R, Ferguson D. Rapid enterovirus RNA detection in clinical specimens by using nucleic acid sequence-based amplification. *J Clin Microbiol* 2003;41:346-50.
[PUBMED](#) | [CROSSREF](#)
14. Ooi MH, Solomon T, Podin Y, Mohan A, Akin W, Yusuf MA, del Sel S, Kontol KM, Lai BF, Clear D, Chieng CH, Blake E, Perera D, Wong SC, Cardoso J. Evaluation of different clinical sample types in diagnosis of human enterovirus 71-associated hand-foot-and-mouth disease. *J Clin Microbiol* 2007;45:1858-66.
[PUBMED](#) | [CROSSREF](#)
15. Tancabelic J, Haun SE. Management of coagulopathy with recombinant factor VIIa in a neonate with echovirus type 7. *Pediatr Blood Cancer* 2004;43:170-6.
[PUBMED](#) | [CROSSREF](#)