

Diagnosing oral lesions in immunocompromised individuals: A case report with a review of literature

Amritha James, Nandhini Gunasekaran, Dineshkumar Thayalan, Rajkumar Krishnan, Ramya Mahalingam

Department of Oral Pathology and Microbiology, SRM Dental College, Chennai, Tamil Nadu, India

Abstract

Oral lesions are often the first tell-tale sign for human immunodeficiency virus infections (HIV). Numerous oral lesions have been associated with HIV infections, some lesions such as candidiasis being more common than others. Regular oral screening can aid in identifying such lesions allowing for the early diagnosis of HIV and help in monitoring the progression of HIV in such individuals. We report a case of a family who manifested with oral lesions consistent with HIV. A review of literature on diagnosing immunocompromised individuals in clinical practice has also been summarized.

Keywords: Clinical practice, diagnosis, HIV, oral manifestation

Address for correspondence: Dr. Amritha James, Department of Oral Pathology, SRM Dental College, Bharathi Salai, Ramapuram, Chennai - 600 089, Tamil Nadu, India.

E-mail: amrithajames94@gmail.com

Submitted: 07-Aug-2021, **Accepted:** 05-Sep-2021, **Published:** 28-Feb-2022

INTRODUCTION

Acquired immunodeficiency syndrome (AIDS) is a manifestation of infection with the human immunodeficiency virus (HIV). It is the fourth leading cause of death worldwide and has been a pandemic since the 1980s. Although decades have passed since its first inception, early diagnosis of the disease is often challenging. The HIV viral load and CD4+ lymphocyte count are the most commonly used methods for diagnosing HIV. However, there is often a delay in diagnosis, as patients remain asymptomatic or show self-limiting manifestations such as fever, sore throat, headache, myalgia and arthralgia during the initial acute phase of the disease which is often mistaken for common viral infections. There is also a lack of viral antibodies in bodily fluids during the window of infectivity, further delaying diagnosis.^[1]

Oral lesions are often the first tell-tale sign for HIV infections. Oral lesions are seen in 70%–90% of all individuals with HIV. Numerous oral lesions have been associated with HIV infections, some lesions such as candidiasis being more common than others. Regular oral screening can aid in identifying such lesions allowing for early diagnosis of HIV and help in monitoring the progression of HIV in such individuals. We report a case of a family who manifested with oral lesions consistent with HIV. A review of literature on diagnosing immunocompromised individuals in clinical practice has also been summarized.

CASE REPORT

A 42-year-old male came to the Department of Oral Medicine, with a chief complaint of growth and pain on

This is an open access journal, and articles are distributed under the terms of the Creative Commons Attribution-NonCommercial-ShareAlike 4.0 License, which allows others to remix, tweak, and build upon the work non-commercially, as long as appropriate credit is given and the new creations are licensed under the identical terms.

For reprints contact: WKHLRPMedknow_reprints@wolterskluwer.com

How to cite this article: James A, Gunasekaran N, Thayalan D, Krishnan R, Mahalingam R. Diagnosing oral lesions in immunocompromised individuals: A case report with a review of literature. *J Oral Maxillofac Pathol* 2022;26:S139-42.

Access this article online

Quick Response Code:



Website:

www.jomfp.in

DOI:

10.4103/jomfp.jomfp_281_21

the lower lip for the past 1 year along with the burning sensation of the oral mucosa. History revealed that the patient had a habit of chewing tobacco three times a day for the past 15 years. The patient had a habit of forming a quid and placing it in the lower labial vestibule for 15 min before spitting. The past medical and dental history was insignificant. On general examination, the patient appeared malnourished and poorly built.

On extraoral and intraoral examination, a single yellowish white cauliflower such as growth was evident on the left side of the lower lip extending mediolaterally, 2 cm away from the midline of the lower lip to the left commissure of the lower lip. The lesion extended intraorally into the labial mucosa and the labial vestibule extending anteroposteriorly from the mesial aspect of 32 to the distal aspect of 33 [Figure 1]. The growth appeared sessile, was irregular in shape and roughly measured 5 cm × 3 cm in dimension. The mucosa over the growth also showed numerous papillary projections while the surrounding mucosa appeared normal. On palpation, the growth was mildly tender, had a rough texture and was firm in consistency. The left submandibular and submental lymph nodes were palpable, nontender and fixed.

A single irregular white patch was also evident on the right side of the lower labial mucosa in relation to 41, 42. On palpation, the lesion was nontender, nonscrapable and was slightly elevated from the surrounding normal mucosa.

Based on the history and clinical features, the lesion on the lip and labial mucosa was provisionally diagnosed as verrucous carcinoma. The differential diagnoses such as proliferative verrucous leukoplakia, verrucous hyperplasia and oral squamous cell carcinoma (OSCC) were also suggested. The lesion on the right lower labial mucosa was provisionally diagnosed as chronic hyperplastic candidiasis/leukoplakia.

Exfoliative cytology revealed PAS-positive hyphae admixed with exfoliated epithelial cells suggestive of candida hyphae. The patient was advised routine blood investigation along

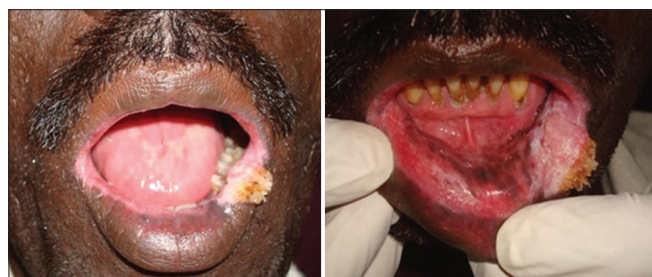

Figure 1: Exophytic growth on the lower lip and labial mucosa

with testing for HIV I and II. Blood investigation showed reduced white blood cell count and reduced lymphocyte percentage in the differential count. The patient was also found positive for HIV I and II.

An excisional biopsy was also carried out for the patient under local anesthesia to rule out the possibility of OSCC and the excised tissue was submitted for histopathological examination.

On histopathological examination, the section showed hyperplastic parakeratinized stratified squamous epithelium overlying a mass of connective tissue. The surface epithelium exhibited numerous surface projections that were covered by a thick parakeratin layer and also exhibited keratin plugging. The rete pegs were broad and tubular and had pushing borders extending deep into the underlying connective tissue. Mild dysplastic features were noticed without frank infiltration. The histopathology of the lesion was suggestive of verrucous carcinoma [Figure 2].

On confirming the diagnosis of HIV, we then called upon the patient family for the examination. On general examination, the patient spouse appeared malnourished and poorly built. On intraoral examination, numerous diffuse white plaques were evident on the dorsal surface and lateral borders of the tongue [Figure 3]. On palpation, the lesion was scrapable and nontender. Diffuse grayish white plaques admixed with red areas were also evident on the anterior part of the hard palate [Figure 3]. On palpation, the lesion was nontender and scrapable. On examination of the gingiva, diffuse erythema was also noted in the marginal gingiva of both maxillary and mandibular teeth [Figure 4].

Based on the history and clinical features, the lesion on the tongue was provisionally diagnosed as pseudomembranous

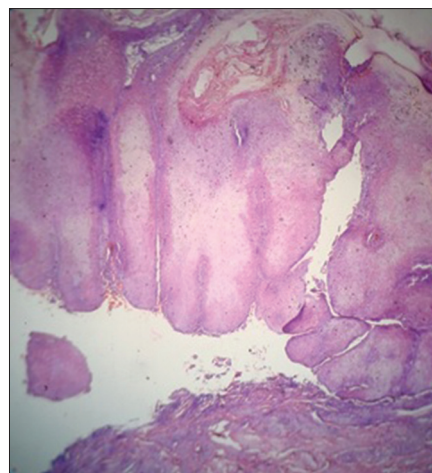


Figure 2: Broad bulbous rete peg (Histopath, ×10)

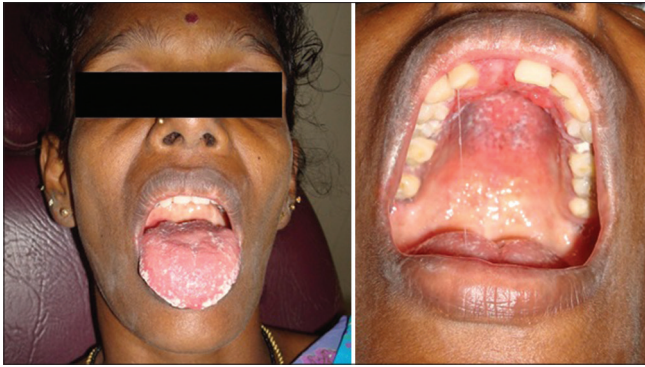

Figure 3: Pseudomembranous candidiasis involving tongue and palate

candidiasis, while the lesion on the palate was diagnosed as chronic multifocal candidiasis. The lesion on the gingiva was diagnosed as linear gingival erythema. The intraoral findings were consistent with the oral manifestation of AIDS, which raised our suspicion of the possibility of HIV infection.

Exfoliative cytology was carried out, which revealed the presence of thin slender PAS-positive hyphae confirming the diagnosis of candidiasis. The patient's wife has also advised of routine blood investigations and HIV screening, which revealed reduced lymphocyte count and positive reaction for HIV antibodies.

Both patients have advised antifungal medications for the management of candidiasis and were referred to a general physician for the management of immunodeficiency. The patients were under our follow-up for 1-year.

DISCUSSION

AIDS is an indicator of infection with HIV and is characterized by worsening immune response which leads to a plethora of clinical manifestations including opportunistic infections, secondary neoplasms and neurological signs and symptoms. Clinical manifestation often depends on the degree of immunosuppression. Patients with a CD4+ count >500 cells/mm³ often remain asymptomatic, whereas patients who fall below this range develop symptomatic HIV infection. AIDS is diagnosed when the CD4+ count falls below 200 cells/mm³.^[2]

Oral manifestations are often the earliest signs of HIV infection and because of the ease of examination of the oral cavity; they serve as ideal indicators for not only diagnosing HIV but also aid in predicting the progression of the infection. Studies have shown that 90% of all individuals with AIDS will manifest with at least one oral lesion during the course of the infection.^[3,4]

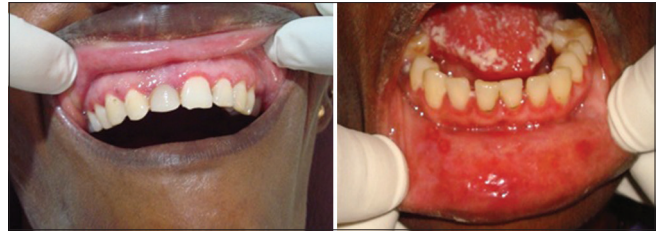

Figure 4: Linear gingival erythema

The most common oral lesion associated with HIV is oral candidiasis and seen in almost 90% of HIV-positive individuals. Oral candidiasis can have a wide spectrum of manifestations ranging from pseudomembranous to erythematous and hyperplastic forms. Pseudomembranous candidiasis has also been associated with declining immune status and is considered a forerunner of severe immunodeficiency in patients with CD4+ counts <200 cells/mm³ and can thus aid in predicting the prognosis and progression of the infection.^[5] In our case as well, the female patient showed extensive manifestation of pseudomembranous candidiasis involving the tongue and palate and was correlated with failing immune status.

Periodontal manifestations are seen in close to 80% of individuals with HIV.^[6] Periodontal lesions include linear gingival erythema and necrotizing gingivitis/periodontitis. Diagnosing such lesions at the earliest is necessary to avoid disastrous repercussions such as necrotizing stomatitis. Dentists are often the first to encounter these lesions and can thus aid in diagnosing HIV in undiagnosed patients and prevent subsequent consequences.^[7] In the current case, linear gingival erythema served as a clue in diagnosis.

Oral hairy leukoplakia (OHL) caused by Epstein-Barr virus is prominently seen on the lateral borders of the tongue as vertical corrugated white streaks. These lesions are seen in 50% of individuals with AIDS and are more often noted in homosexual men. The presence of OHL positively correlates with disease progression and is often noted during the later stages of the disease.^[8]

Kaposi's sarcoma is a hematological malignancy that is most commonly encountered in AID and is caused by HHV8 infection. It is usually seen as reddish-purple macules or nodules involving the palate and gingiva. These lesions may be seen in any stage of the disease.^[9] Non-Hodgkin's lymphoma is the second most common malignancy seen in AIDS. It is noted as a rapidly growing mass commonly seen on the gingiva, palate and tongue.^[10] A biopsy is necessary for the definitive diagnosis of both these lesions.

Recurrent aphthous ulcers are idiopathic ulcers often seen on the nonkeratinized mucosa of the oral cavity and may show a wide range of clinical manifestations varying from minor aphthae, major aphthae to herpetiform ulcerations. Aphthous ulceration in HIV-positive individuals is often extensive involving multiple sites or are often larger and irregular. These lesions are noted in patients with a CD4+ count <100 cells/mm³ and are markers of HIV disease progression.^[11]

Other viral infections associated with AIDS include herpes infections, human papillomavirus (HPV) infections and CMV infections. Herpes zoster infections manifest as unilateral blisters or ulcerations on the keratinized mucosa of the oral cavity. CMV infections are seen as nonspecific ulcers of the oral cavity and often require a biopsy of definitive diagnosis. HPV infections can be seen in the form of lesions such as focal epithelial hyperplasia, verruca vulgaris, and condyloma acuminatum. These lesions arise due to defective innate and acquired immune responses to the viral pathogens in patients with AIDS.^[12]

OSCC has also been reported in patients with AIDS. Impaired immunosurveillance is thought to contribute to the development of cancer.^[13] In the current case, the patient had verrucous carcinoma which is low-grade warty variant of OSCC. However, a direct link to HIV infection cannot be established as the patient has a habit of pouching tobacco quid.

Other lesions less commonly associated include melanotic pigmentation and xerostomia which are often the consequences of the therapeutic drugs taken for the treatment of AIDS.

CONCLUSION

Dentists are often the first health-care providers to encounter lesions within the oral cavity and all oral manifestations of HIV, whether present individually or along with other lesions, must be looked upon with a high degree of suspicion and diagnostic investigations must be prompted. Early recognition and treatment can reduce morbidity and mortality in such patients. This case report highlights the most common finding in HIV-positive individuals to help the general dentist recognize and diagnose such lesions at the earliest.

Declaration of patient consent

The authors certify that they have obtained all appropriate patient consent forms. In the form the patient (s) has/have given his/her/their consent for his/her/their images and other clinical information to be reported in the journal. The patients understand that their names and initials will not be published and due efforts will be made to conceal their identity, but anonymity cannot be guaranteed.

Financial support and sponsorship

Nil.

Conflicts of interest

There are no conflicts of interest.

REFERENCES

- Ramírez-Amador V, Esquivel-Pedraza L, Sierra-Madero J, Anaya-Saavedra G, González-Ramírez I, Ponce-de-León S. The changing clinical spectrum of human immunodeficiency virus (HIV)-related oral lesions in 1,000 consecutive patients: A 12-year study in a referral center in Mexico. *Medicine (Baltimore)* 2003;82:39-50.
- Sivapathasundharam B, Rajendran A. *Shafer's Textbook of Oral Pathology*. 7th ed. India: Elsevier; 2012.
- Sen S, Mandal S, Bhattacharya S, Halder S, Bhaumik P. Oral manifestations in human immunodeficiency virus infected patients. *Indian J Dermatol* 2010;55:116-8.
- Begg MD, Lamster IB, Panageas KS, Mitchell-Lewis D, Phelan JA, Grbic JT. A prospective study of oral lesions and their predictive value for progression of HIV disease. *Oral Dis* 1997;3:176-83.
- Kerdpon D, Pongsiriwet S, Pangsomboon K, Iamaroon A, Kampoo K, Sretrirutchai S, *et al.* Oral manifestations of HIV infection in relation to clinical and CD4 immunological status in northern and southern Thai patients. *Oral Dis* 2004;10:138-44.
- Agbelusi GA, Eweka OM, Umezudike KA, Okoh M. Oral manifestations of HIV. *Current Perspectives in HIV Infection*. 2013:209.
- Robinson PG. The significance and management of periodontal lesions in HIV infection. *Oral Dis* 2002;8 Suppl 2:91-7.
- Rathee M, Jain P. Hairy Leukoplakia. *StatPearls [Internet]*. 2021.
- Gonçalves PH, Uldrick TS, Yarchoan R. HIV-associated Kaposi sarcoma and related diseases. *AIDS* 2017;31:1903-16.
- Grogg KL, Miller RF, Dogan A. HIV infection and lymphoma. *J Clin Pathol* 2007;60:1365-72.
- MacPhail LA, Greenspan D, Feigal DW, Lennette ET, Greenspan JS. Recurrent aphthous ulcers in association with HIV infection. Description of ulcer types and analysis of T-lymphocyte subsets. *Oral Surg Oral Med Oral Pathol* 1991;71:678-83.
- Tugizov SM, Webster-Cyriaque JY, Syrianen S, Chattopadhyay A, Sroussi H, Zhang L, *et al.* Mechanisms of viral infections associated with HIV: Workshop 2B. *Adv Dent Res* 2011;23:130-6.
- Chen CH, Chung CY, Wang LH, Lin C, Lin HL, Lin HC. Risk of cancer among HIV-infected patients from a population-based nested case-control study: Implications for cancer prevention. *BMC Cancer* 2015;15:133.