

Dexamethasone intravitreal implant in cystoid macular edema secondary to paclitaxel therapy



Barbara Burgos-Blasco*, Samuel Hernandez-Ruiz, Lorenzo Lopez-Guajardo, Juan Donate-Lopez

Ophthalmology Department, Hospital Clinico San Carlos, Madrid, Spain

ARTICLE INFO

Keywords:

Cystoid macular edema
Paclitaxel
Intravitreal dexamethasone implant

ABSTRACT

Purpose: To report the first case of cystoid macular edema (CME) induced by nabpaclitaxel treated with intravitreal dexamethasone implant.

Observations: A 67 year-old man diagnosed with unresectable pancreatic cancer presented with decreased vision in both eyes while receiving nab-paclitaxel. He was diagnosed with CME and intravitreal dexamethasone implants were administered in both eyes. Central retinal thickness (CRT) of both eye decreased 1 month after the implant but CME persisted. 2 months after Ozurdex implant nabpaclitaxel was discontinued, improving central macular thickness and the CME significantly in both eyes.

Conclusion and importance: Cessation of nab-paclitaxel could lead to resolution of CME more than intravitreal dexamethasone implant, although intravitreal dexamethasone implant achieved some reduction in central macular thickness.

1. Introduction

Taxane agents, such as paclitaxel, disrupt the microtubule network within cells that are essential for mitosis, ultimately resulting in cell death. Nab-paclitaxel combined with gemcitabine has showed activity and efficacy in metastatic pancreatic cancer and is used as first-line treatment. Frequently reported side effects of paclitaxel include alopecia, sensory neuropathy, fatigue, neutropenia, arthralgia, fluid retention ...^{1,2}

Ophthalmological side effects secondary to paclitaxel has been reported in 10% of the patients, causing a decrease in visual acuity in 4%.³ Cystoid macular edema (CME) has also been described. However, only case reports of CME can be found in the literature and its real incidence is unclear. Discontinuation of the compound has proved effective in CME resolution, although actual treatment has not been established yet. We describe the findings of a nabpaclitaxel-induced maculopathy and the changes after dexamethasone intravitreal implant.

2. Case report

A 67 year-old man diagnosed with unresectable pancreatic cancer (stage IV) received gemcitabine plus albuminbound paclitaxel (nab-PTX; Abraxane) therapy. 6 months after nab-PTX therapy was initiated,

he presented with a progressive decreased vision in both eyes. By that time, he had received 6 series of treatment (nab-paclitaxel 125mg/m²). He had no relevant past medical or ocular history.

On admission, his visual acuity was 20/50 in both eyes. Anterior segment examination was unremarkable and intraocular pressure was 14 mmHg in both eyes. Biomicroscopic examination was normal, but the fundus examination showed decreased foveal light reflex in both eyes.

Optical coherence tomography (OCT2; OCT Spectralis. Heidelberg Engineering, Germany) revealed CME with marked cystoid spaces predominantly involving the outer and inner nuclear layers in both eyes with a central thickness of 627µm in the right eye (OR) and 632µm in the left eye (OS) (Fig. 1). Fluorescein angiography showed no leakage and optical coherence tomography angiography (OCTA; Plex Elite, Zeiss, Germany) revealed no microvascular dilations, microaneurysmal lesions or shunts in both the superficial and deep retinal capillary plexus (Fig. 2). CME was evident on the en face images, black hyporespectral cavities in the deep slabs demonstrating the cysts.

Due to no other probable cause, the patient was diagnosed with CME secondary to nabpaclitaxel use. A dexamethasone intravitreal implant (Ozurdex; Allergan, Dublin, Ireland) was injected in each eye. One month later, the patient continued with the same nab-PTX regime. His visual acuity was 20/40 in both eyes and central thickness was 543µm in OR and 558µm in OS. After consulting with the oncologist, he

* Corresponding author. Hospital Clinico San Carlos, C/ Prof Martin Lagos s/n. 28040, Madrid, Spain.

E-mail address: bburgos171@hotmail.com (B. Burgos-Blasco).

<https://doi.org/10.1016/j.ajoc.2020.100653>

Received 4 November 2019; Received in revised form 8 December 2019; Accepted 4 March 2020

Available online 07 March 2020

2451-9936/ © 2020 Published by Elsevier Inc. This is an open access article under the CC BY-NC-ND license

(<http://creativecommons.org/licenses/by-nc-nd/4.0/>).

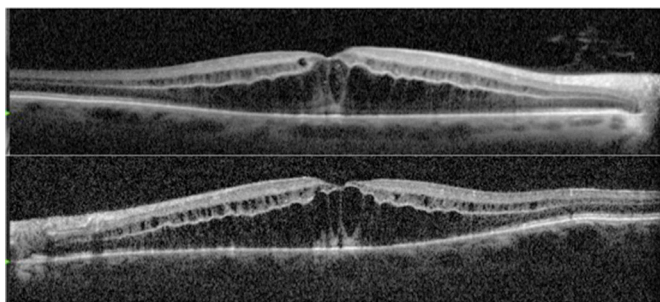


Fig. 1. Optical coherence tomography angiography (OCT) at diagnosis.

discontinued the nab-PTX therapy 2 months after Ozurdex implant. 4 months after diagnosis, his visual acuity improved to 20/25 on follow-up and central thickness was 272 μ m in OR and 265 μ m in OS. The CME finding on OCT was completely resolved (Fig. 3).

3. Discussion

CME secondary to paclitaxel is a rare side effect, which can develop from two months to three and a half years after initiating chemotherapy and is usually bilateral. Its exact pathogenesis remains unclear, hindering the finding of an effective treatment. Although it may not always be recommended and consultation with the oncologist is required, discontinuation of the drug is normally the only definite treatment for CME resolution.^{4,5}

Diagnosis is based on OCT and fluorescein angiography, where the absence of leakage on the latter suggests that its mechanisms may be different from those of CME of other etiology. CME without fluorescein leakage is rare, being its most common causes juvenile X-linked retinoschisis, Goldmann-Favre syndrome and niacin toxicity.⁶

Taxanes affect the cytoskeleton of the retinal pigment epithelium which could prevent proper absorption, but the Bruch membrane remains unaltered, explaining the lack of leakage.^{7,8} Also, OCT images suggest that cysts are made of high viscosity fluid, which could act as an obstacle to fluorescein diffusion.⁹ Several authors have suggested that taxanes can act directly on Müller cells, which are responsible for maintaining osmotic gradients within the neurosensory retina. This produces ion dysregulation, resulting in intracellular fluid accumulation and extracellular fluid leakage.^{10,11} Furthermore, mean central macular thickness has been found to increase with taxane treatment (mean difference of +2.22 μ m; $p = 0.001$) implying these mechanisms may act on all patients although only some may develop CME.¹²

Different approaches to treat taxane-associated macular edema have been described, but they include a few cases as case reports. Treatment with a topical carbonic anhydrase inhibitor (topical Dorzolamide 2% three times daily) appears to be useful in some cases in the literature, although its benefit is still controversial.^{5,13–15} Oral therapy with acetazolamide has been reported to induce a rapid improvement of visual acuity and a complete regression of the macular edema after 8 weeks, despite continued chemotherapy.¹⁶

Rahman et al. administered intravitreal bevacizumab bilateral injections on a monthly basis. The patient's visual acuity remained stable and although the neuroepithelial detachment improved, the CME persisted in both eyes.¹⁷ The lack of improvement with this option suggests that vascular endothelial growth factor is not the main mechanism implicated in this type of CME. This is supported by cases of development of CME secondary to paclitaxel where systemic bevacizumab was

also being administered.¹⁸ Other options, such as topical nonsteroidal anti-inflammatory drugs (ketorolac) have had little to no effect.¹¹

Because the fluid retention syndrome associated with docetaxel is generally controlled through a course of steroids before the beginning of a treatment cycle, Teitelbaum suggested the consideration of topical, intravitreal or periocular steroids.⁶ Matsuoka et al. hypothesized that sub-Tenon injections of triamcinolone acetonide could improve CME in these cases. However, their patient presented a decrease in CRT after the first injection, but there were no changes in visual acuity and no further decrease in CRT after a second injection.¹⁹

Intravitreal dexamethasone has proved effective in the treatment of CME of multiple etiologies. Corticosteroids have a stabilizing effect on vascular permeability and reduce inflammatory reactions, which are both involved in CME secondary to taxanes.

To the best of our knowledge, this is the first published case of paclitaxel-associated macular edema treated with dexamethasone intravitreal implant. In our case, the patient's changes were similar to those of Matsuoka, presenting only an initial improvement of macular central thickness but persistence of CME. It seems ocular steroids can help reduce CME but fail in its complete resolution.

Because nabpaclitaxel was discontinued shortly after the intravitreal implant and the latter has been shown to continue its effect a few months, the resolution of the CME could be a result of both actions. However, the dexamethasone implant seems a possible approach in those patients where nab-paclitaxel is strongly advised.

4. Conclusions

Cessation of nab-paclitaxel could lead to resolution of CME more than intravitreal dexamethasone, although it appears that the implant had some effect. Therefore, it seems to be an option in patients where the nab-paclitaxel cannot be suspended. Since nab-paclitaxel has been recently approved for treating more types of malignancies, the number of the patients with this CME is expected to increase in the near future. Although further research is required, this case report is a promising treatment strategy and outcome for this rare nonresolving nabpaclitaxel side effect.

Acknowledgements and disclosures

Patient consent

The patient consented to publication of the case orally. This report does not contain any personal information that could lead to the identification of the patient.

Funding

No funding or grant support.

Authorship

All authors attest that they meet the current ICMJE criteria for authorship.

Declaration of competing interest

The authors have no financial disclosures.

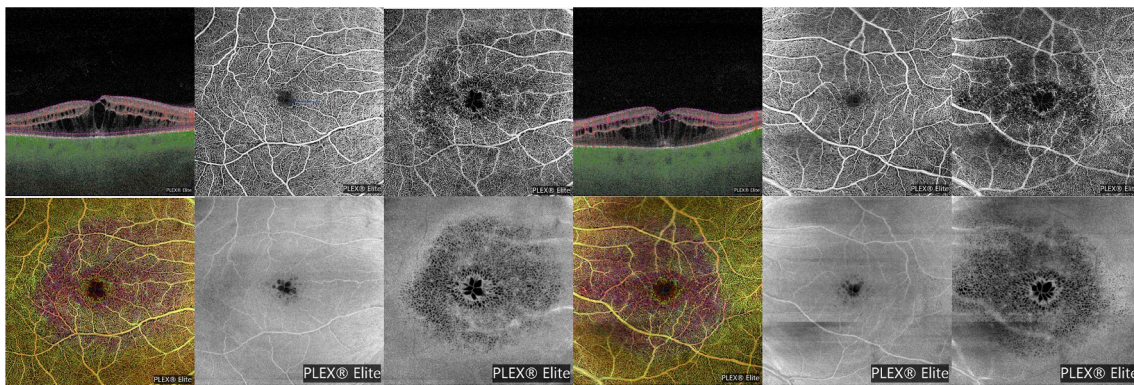


Fig. 2. Optical coherence tomography angiography (OCTA) at diagnosis showing superficial and deep capillary plexus with their en face scan.

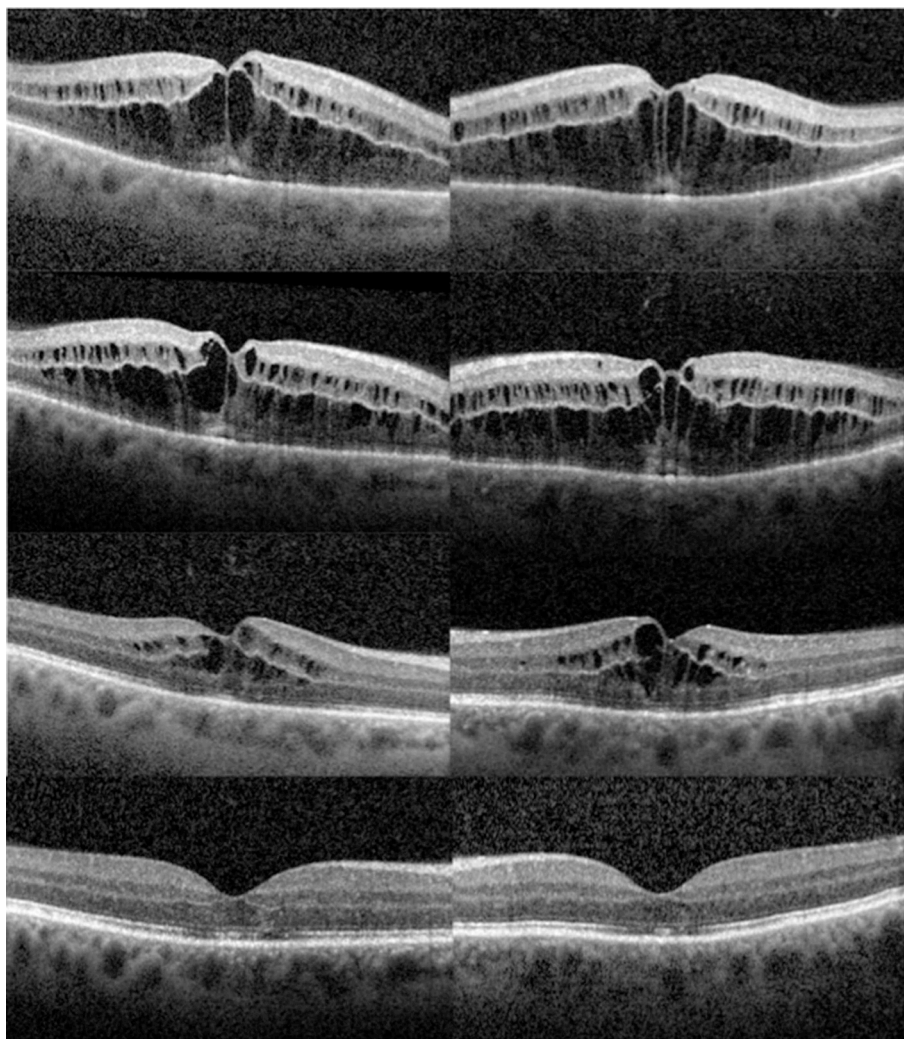


Fig. 3. Serial images of optical coherence tomography (OCT). On first visit, OCT revealed prominent cystoid macular edema (A). One month later, there was still prominent macular edema with a slight improvement (B). Two months later, the macular edema significantly decreased in both eyes (C). The macular edema resolved in both eyes after four months (D).

Acknowledgements

None.

References

1. Giordano G, Pancione M, Olivieri N, et al. Nano albumin bound-paclitaxel in pancreatic cancer: current evidences and future directions. *World J Gastroenterol.* 2017;23(32):5875–5886.
2. Gradishar WJ, Tjulandin S, Davidson N, et al. Phase III trial of nanoparticle albumin-bound paclitaxel compared with polyethylated castor oil-based paclitaxel in women with breast cancer. *J Clin Oncol.* 2005;23(31):7794–7803.
3. Noguchi Y, Kawashima Y, Maruyama M, et al. Risk factors for eye disorders caused by paclitaxel: a retrospective study. *Biol Pharm Bull.* 2018;41(11):1694–1700.
4. Enzoly A, Kammerer K, Nemeth J, Schneider M. Bilateral cystoid macular edema following docetaxel chemotherapy in a patient with retinitis pigmentosa: a case report. *BMC Ophthalmol.* 2015;15:32.

5. Chang S, Tsai SH, Chen L, Chan W. Paclitaxel-induced cystoid macular oedema. *Acta Ophthalmol.* 2018;96(5):e649–e650.
6. Teitelbaum BA, Tresley DJ. Cystic maculopathy with normal capillary permeability secondary to docetaxel. *Optom Vis Sci.* 2003;80(4):277–279.
7. Shih C, Lee Y. Impaired retinal pigment epithelium in paclitaxel-induced macular edema: a case report. *Medicine (Baltim).* 2018;97(26):e11229.
8. Freitas-da-Costa P, Brandão E, Bragança T, Falcão-Reis F, Carneiro A. Multimodal imaging in paclitaxel-induced macular edema: the microtubule dysfunction. *Cutan Ocul Toxicol.* 2015;34(4):347–349.
9. Kuznetcova TI, Cech P, Herbolt CP. The mystery of angiographically silent macular oedema due to taxanes. *Int Ophthalmol.* 2012;32(3):299–304.
10. Joshi MM, Garretson BR. Paclitaxel maculopathy. *Arch Ophthalmol.* 2007;125(5):709–710.
11. Georgakopoulos CD, Makri OE, Vasilakis P, Exarchou A. Angiographically silent cystoid macular oedema secondary to paclitaxel therapy. *Clin Exp Optom.* 2012;95(2):233–236.
12. Chelala E, Arej N, Antoun J, et al. Central macular thickness monitoring after a taxane-based therapy in visually asymptomatic patients. *Chemotherapy.* 2017;62(3):199–204.
13. Hassall MM, Andrew NH. Single-eye trial of a topical carbonic anhydrase inhibitor versus intravitreal bevacizumab for the treatment of taxane drug-induced cystoid macula oedema. *BMJ Case Rep.* 2016. <https://doi.org/10.1136/bcr-2015-212733> 2016.
14. Dwivedi R, Tirumal S. Possible efficacy of topical dorzolamide in the treatment of paclitaxel-related cystoid edema. *Retin Cases Brief Rep.* 2018;12(1):75–79.
15. Ehlers JP, Rayess H, Steinle N. Topical dorzolamide therapy for taxane-related macular oedema. *Eye.* 2013;27(1):102–104.
16. Meyer KM, Klink T, Ugurel S, Bröcker E-B. Regression of paclitaxel-induced maculopathy with oral acetazolamide. *Graefes Arch Clin Exp Ophthalmol.* 2012;250(3):463–464.
17. Rahman HT, Yeh S, Bergstrom CS. Cystoid macular edema without leakage secondary to nab-Paclitaxel (Abraxane): clinical experience with intravitreal bevacizumab. *J Ocul Pharmacol Therapeut.* 2013;29(3):360–362.
18. Yokoe T, Fukada I, Kobayashi K, et al. Cystoid macular edema during treatment with paclitaxel and bevacizumab in a patient with metastatic breast cancer: a case report and literature review. *Case Rep Oncol.* 2017;10(2):605–612.
19. Matsuoka N, Hasebe H, Mayama T, Fukuchi T. Sub-tenon injections of triamcinolone acetonide had limited effect on cystoid macular edema secondary to nanoparticle albumin-bound-paclitaxel (Abraxane). *Case Rep Ophthalmol Med.* 2015;2015:181269.