

Case Report

Subglottic stenosis imitating the carina – a case report of airway mimicry

H. Trageser,¹ C. Lott,² K. Epp¹ and N. Pirlich²

1 Trainee, 2 Consultant, Department of Anaesthesiology, University Medical Centre of the Johannes-Gutenberg University Mainz, Mainz, Germany

Summary

We present a case of awake tracheal intubation with flexible bronchoscopy which resulted in incorrect tracheal tube placement. The presence of a stenotic subglottic lesion with an appearance similar to the carina led to the tube being positioned with only the tip within the trachea whilst the cuff was located between the vocal cords. A capnography trace was identified before induction of anaesthesia; however, visual confirmation of the carina was undertaken in a rushed manner due to the patient becoming agitated. Once the incorrect tracheal tube placement was identified, the decision was made to wake the patient. Thereafter, a more experienced operator successfully performed awake tracheal intubation with flexible bronchoscopy using a smaller tracheal tube, which easily passed through the subglottic stenosis. This report emphasises the importance of performing the 'two-point check' every time awake tracheal intubation is undertaken: to confirm correct tube placement, both a capnography trace and view of the tracheal lumen including the carina and main bronchi is required. This must be properly performed before induction of anaesthesia; safety should not be compromised by a stressful environment or time pressure.

Correspondence to: N. Pirlich

Email: pirlich@uni-mainz.de

Accepted: 10 December 2020

Keywords: difficult airway algorithm; failed intubation: treatment; predictors of difficult intubation

Introduction

Awake tracheal intubation using flexible bronchoscopy (ATI:FB) is a commonly used technique in difficult airway management due to its a high success rate and a favourable safety profile [1, 2]. We perform approximately 1000 ATI:FB procedures annually at our institution and all anaesthetists are trained in this technique. Our institutional approach to ATI:FB includes applying lidocaine 10% spray twice onto the oropharyngeal mucosa, including from the tip to the base of the tongue. Patients are then asked to gargle the lidocaine in their mouth for as long as possible and an intravenous (i.v.) sufentanil bolus is given before the flexible bronchoscope is inserted into the patient's mouth. Supplemental oxygen is administered at a flow rate of 3 l.min⁻¹ via a nasal cannula. After inserting a bronchoscope airway, a spray-as-you-go technique is performed for topical airway anaesthesia, using lidocaine 2% 5 ml plus air 5 ml in a 10 ml syringe sprayed through the working channel of the flexible bronchoscope. Finally, after further advancing the flexible bronchoscope into the trachea and viewing the carina, an armoured tracheal tube is railroaded over the flexible bronchoscope into the trachea. Anaesthesia is induced once the position of the tube is confirmed by the 'two-point check' [2].

According to the Difficult Airway Society guidelines, the two-point check for ATI:FB comprises "(1) visualisation of the tracheal lumen... and (2) capnography to exclude oesophageal intubation". Furthermore, the guideline states that "once the flexible bronchoscope is in the trachea, the carina should be identified before advancing the tracheal tube to

minimise the risk of misplacement" [2]. In this case report, the carina was misidentified, leading to incorrect tube placement.

Report

A 65-year-old man was scheduled for an elective panendoscopy for investigation of progressive dysphagia. His symptoms were thought to be due to recurrence of a hypopharyngeal carcinoma which had been treated with surgery, radiotherapy and a tracheostomy 2 years previously, following which the tracheostomy had been reversed after 6 months. A difficult airway was thought to be likely and ATI:FB, which is the standard approach to airway management for patients receiving a panendoscopy at our institution, was planned.

Topical airway anaesthesia was performed according our standard approach (above), and sufentanil 10 µg was administered i.v. On insertion of the flexible bronchoscope (5.2 mm outer diameter × 65 cm length; Karl-Storz GmbH, Tuttlingen, Germany), landmarks including the uvula, epiglottis, glottic inlet and trachea were easily viewed. The carina and the two main bronchi were then identified, and insertion of a 7.0-mm internal diameter armoured tracheal tube (Rüsch Flex, Teleflex, Athlone, Ireland) was commenced. At this point, airway secretions and coughing impaired the bronchoscopic view significantly. Inserting the tracheal tube increased the patient's coughing. Given the poor view, it was falsely assumed that a linear light reflection (Fig. 1) was the carina. The tube was inserted against some resistance to a depth of 24 cm at the angle of the patient's mouth and a capnographic trace was seen. Given the patient's distress, general anaesthesia was promptly induced using propofol 200 mg i.v.

Whilst securing the tracheal tube, it became apparent that it was coiled within the patient's mouth. The flexible bronchoscope was advanced through the tube, revealing that the actual position of the carina was distant from the end of the tube. Inserting the bronchoscope orally with careful retraction of the tube demonstrated that only the tip of the tube had been placed into the trachea, with the cuff located between the vocal cords. Although the tube was placed incorrectly, ventilation was sufficient and it was decided to wait for the patient to emerge from anaesthesia before removing the tube and re-attempting ATI:FB. This was subsequently performed by a more experienced operator using a smaller (6.0-mm internal diameter) tracheal tube, which successfully traversed a previously undiagnosed subglottic stenosis that had both obstructed tracheal intubation and created the linear light reflection in the first attempt (Fig. 1). The tracheal tube was inserted to 22 cm at the corner of the patient's mouth and general anaesthesia was once again induced. No complications, such as hypoxia, aspiration or mucosal injury were observed at any time.

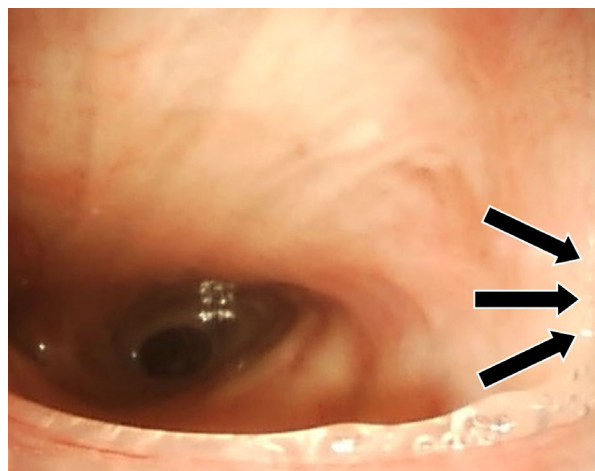


Figure 1 Flexible bronchoscopic view into the trachea. The linear reflection caused by subglottic stenosis (black arrows) was assumed to be the carina.

Discussion

This case indicates out how a team of well-trained physicians can respond in an unexpected critical situation, even though appropriate preparatory measures for an anticipated difficult airway had been undertaken.

Airway management is difficult in nearly 16% of cases involving general anaesthesia for patients with a history of airway malignancy [3]. Our standard institutional approach is therefore to regard all such patients as having a potentially difficult airway and therefore perform ATI:FB in cases where general anaesthesia is required [1]. Awake tracheal intubation with flexible bronchoscopy is an established procedure and is successful in 88–100% of patients presenting with predicted difficult airway management [1–3]. In addition to performing ATI:FB for patients scheduled for panendoscopy to mitigate the risks of difficult airway, it also allows for evaluation of the upper aerodigestive tract and serves to provide regular training opportunities for clinical staff.

Awake tracheal intubation is associated with the greatest operator-related physical, mental and psychological stress of all elective airway management interventions [4]. These stressors may be associated with the suboptimal performance of procedural steps. In this report for example, the agitation and coughing experienced by the patient resulted in the team feeling a pressure to rapidly induce general anaesthesia despite sub-optimal conditions, to relieve the patient's discomfort. As a consequence, the two-point check was not thoroughly done. On reflection, if the procedure had been paused and the topical anaesthesia of the patient's airway had been improved, these stressors could have been avoided.

Though capnography has been reported to be 100% sensitive and specific for detection of tracheal intubation when the patient's lungs are being artificially ventilated [5, 6], in the context of a spontaneously breathing patient an appropriate capnography trace may also be seen with a supraglottic tube [2]. Furthermore, the capnography trace does not yield any useful information regarding the depth of insertion of the tracheal tube. In this case, although the carina was initially thought to have been identified, the coughing and distress experienced by the patient caused this view to be lost and the bronchoscope to migrate. This, combined with the presence of excess airway secretions, prevented us from re-establishing a proper visual confirmation of the tracheal lumen immediately before inserting the tracheal tube. Instead, we assumed a linear reflection from an unexpected subglottic stenosis to be the carina.

This patient was not known to have subglottic stenosis; however, his previous tracheostomy was a risk-factor. In Germany, approximately 39,000 temporary tracheostomies are performed each year and benign tracheal stenosis (including subglottic stenosis) occurs in 1–20% of patients and is the most frequently occurring long-term complication [7]. Because the passage of the tracheal tube was obstructed, a gentle force was applied when attempting to advance it. Therefore, the tube coiled within the patient's oral cavity, leading to the appearance of an appropriate depth of insertion when measured at the angle of the patient's mouth. In this case, tube insertion was performed by an anaesthetic nurse, not the anaesthetist, who needed to use both hands to keep control of the bronchoscope due to the patient's agitation. Though some resistance to advancing the tube was not unexpected given the patient's coughing, it is possible that a practitioner who was more experienced in tracheal tube insertion may have noticed abnormal tactile feedback when undertaking this part of the procedure.

After identifying the incorrect tracheal tube position, a second experienced anaesthetist was consulted [1], and possible rescue strategies were discussed:

- 1 Replacement of the 7.0mm internal diameter tracheal tube with a smaller tracheal tube using an airway exchange catheter;
- 2 Tracheal extubation and insertion of a supraglottic airway device;
- 3 Tracheostomy by opening the pre-existing tracheostomy scar; or
- 4 Allow the patient to emerge from general anaesthesia and repeat the ATI: FB with a smaller tracheal tube.

We decided against attempting tracheal tube exchange because its success may have been hampered by the tracheal tube tip impinging on laryngeal structures, the risk of which may have been increased due to abnormal anatomy following surgery and radiotherapy. We also decided against insertion of a supraglottic airway device because it would have meant abandoning a 'can ventilate' situation without any guarantee of satisfactory supraglottic airway device placement or ventilation. We decided not to perform a tracheostomy because the procedure is invasive and was not otherwise indicated. We therefore decided to wait for the return of spontaneous breathing and emergence from general anaesthesia. Though there was a theoretical risk of a vocal cord injury due to the misplaced tube cuff, we deemed that this was minimal given the short time period involved. A further option that may have been useful in order to facilitate re-intubation under general anaesthesia is transnasal humidified rapid-insufflation ventilatory exchange (THRIVE), which has been shown to increase apnoea time and the time for potential further airway management manoeuvres [8]. However, this was not available in our institution.

Well-performed awake tracheal intubation is a complex interaction of appropriate case selection, good patient preparation and technical expertise. In this report, operator-related stress caused by an agitated patient in combination with an unexpected

subglottic stenosis led to an avoidable tube misplacement. This case highlights the importance of undertaking a thorough two-point check for every awake tracheal intubation [2].

Acknowledgements

Published with the written consent of the legal guardian of the patient. No external funding or competing interests declared.

References

1. Piepho T, Cavus E, Noppens R, et al. Guidelines on airway management: guideline of the German Society of Anesthesiology and Intensive Care Medicine. *Anaesthesist* 2015; **64**: 27–40.
2. Ahmad I, El-Boghdadly K, Bhagrath R, et al. Difficult Airway Society guidelines for awake tracheal intubation (ATI) in adults. *Anaesthesia* 2020; **75**: 509–28.
3. Roissant RWC, Zwißler B, Werner C. *Die Anästhesiologie*. Berlin: Springer-Verlag, 2019.
4. Weinger MB, Vredenburgh AG, Schumann CM, et al. Quantitative description of the workload associated with airway management procedures. *Journal of Clinical Anesthesia* 2000; **12**: 273–82.
5. Silvestri S, Ladde JG, Brown JF, et al. Endotracheal tube placement confirmation: 100% sensitivity and specificity with sustained four-phase capnographic waveforms in a cadaveric experimental model. *Resuscitation* 2017; **115**: 192–8.
6. Grmec Š. Comparison of three different methods to confirm tracheal tube placement in emergency intubation. *Intensive Care Medicine* 2002; **28**: 701–4.
7. Lopez-Pastorini A, Kraja O, Ludwig C, et al. Reduction of tracheotomy associated tracheal stenosis by surgical closure of the tracheostomy. *Pneumologie* 2015; **69**: 335–40.
8. Patel A, Nouraei SA. Transnasal Humidified Rapid-Insufflation Ventilatory Exchange (THRIVE): a physiological method of increasing apnoea time in patients with difficult airways. *Anaesthesia* 2015; **70**: 323–9.