

# Transanastomotic Tube in Intestinal Atresia: How Beneficial Are They?

Nitin Sharma, M. Amin Memon<sup>1</sup>, Shipra Sharma<sup>2</sup>, Mini Sharma<sup>3</sup>, Basant Chaurasia<sup>4</sup>, Sewak Ram Verma<sup>4</sup>

Department of Paediatric Surgery, CM Hospital, Pt JNM Medical College and Associated Dr BRAM/DKS Hospital, <sup>1</sup>Department of Paediatric Surgery, Pt JNM Medical College and Associated Dr BRAM/DKS Hospital, <sup>2</sup>Department of General Surgery, Pt JNM Medical College and BRAM Hospital, <sup>3</sup>Department of Community Medicine, Pt JNM Medical college, Raipur, <sup>4</sup>Department of Anaesthesia, CM Hospital and Associated Medical College, Bhilai, Chhattisgarh, India

## Abstract

**Introduction:** Intestinal atresia requires multiple surgeries and long hospital stay. We tried managing these cases by primary anastomosis with transanastomotic tube (TAT) for early feeding. **Aims:** The aim of the study was to analyse the outcomes in patients of intestinal atresia who underwent primary anastomosis with a TAT. **Materials and Methods:** The records between June 2014 and November 2017 were analysed. Those with incomplete data or unclear final outcome were excluded. Patients managed by primary anastomosis with TAT (Group A) or without TAT (Group B) were included. The TAT was kept for 6 weeks. Oral feeds were started after 2 weeks in all the cases.  $P < 0.05$  was considered as statistically significant. **Results:** Forty-eight cases were included. There were two duodenal atresia, 29 jejunal atresia and 17 ileal atresia. The mean age at surgery was 2 days (range: 1–16 days). There were 42 cases in Group A (with TAT) and six in Group B (without TAT). The average duration of start of feeds was 78 h (range: 72–96 h) in Group A and 402 h (range: 360–504 h) in Group B ( $P = 0.01$ ). The mean duration of hospital stay was 7 days (range: 5–15 days) and 27 days (range: 19–48 days) in Group A and B, respectively ( $P = 0.02$ ). The overall survival was 38 (91%) and 3 (50%) in Group A and B, respectively ( $P = 0.01$ ). Reexploration was required in 2/42 and 2/6 cases in Group A and B, respectively ( $P = 0.4$ ). Total parental nutrition was required in 2/42 and all cases in Group A and B, respectively. **Conclusion:** Primary repair in intestinal atresia with a TAT is a practical option. The overall outcome is better.

**Keywords:** Intestinal atresia, tapering enteroplasty, total parental nutrition, transanastomotic tube, Witzel's principle

## INTRODUCTION

Intestinal atresia is one of the common congenital anomalies that requires multiple surgeries and long hospital stay in cases where primary anastomosis is done. If the disease is associated with other comorbidities such as low-birth weight and other congenital anomalies, the stay becomes further prolonged.<sup>[1]</sup> Primary anastomosis is associated with longer total parental nutrition (TPN) time and delayed start of the oral feed; it often becomes difficult to manage these cases in a limited facility setup. We tried managing these cases by primary anastomosis with a transanastomotic tube (TAT) inserted for feeding in all these cases. The study aimed to analyse the outcomes in patients of intestinal atresia who underwent primary anastomosis with a TAT.

## MATERIALS AND METHODS

The records of patients presenting with intestinal atresia operated between June 2014 and November 2017 were analysed. The data consisted of patient operated at CM Hospital and Pt JNM Medical College, Raipur. Those with incomplete data or where the final outcome was not clear were excluded from the study. The patients managed by primary anastomosis with or without TAT were included. Those cases where TAT came out incidentally within 72 h of insertion were considered in the group of anastomosis without TAT for analysis. We did the primary anastomosis with imbrications tapering(10) over

**Address for correspondence:** Dr. Nitin Sharma, Department of Paediatric Surgery, Pt. JNM Medical College and Associated Dr BRAM/DKS hospital, Raipur - 492 001, Chhattisgarh, India. E-mail: nitinsharma4you@hotmail.com

Received: 24-12-2017 Revised: 26-02-2018 Accepted: 30-04-2019 Available Online: 16-09-2020

### Access this article online

#### Quick Response Code:



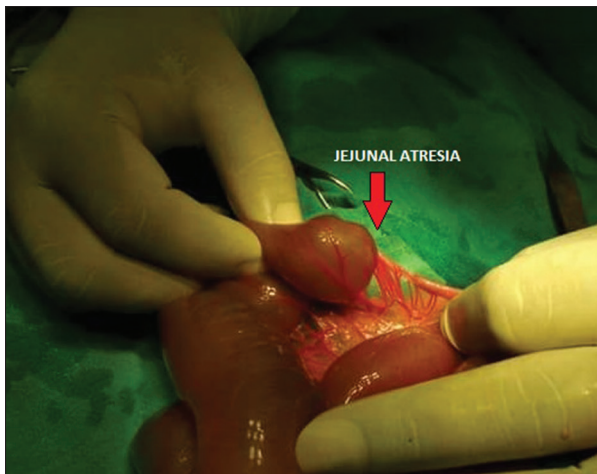
**Website:**  
www.afripaedurg.org

**DOI:**  
10.4103/ajps.AJPS\_101\_17

This is an open access journal, and articles are distributed under the terms of the Creative Commons Attribution-NonCommercial-ShareAlike 4.0 License, which allows others to remix, tweak, and build upon the work non-commercially, as long as appropriate credit is given and the new creations are licensed under the identical terms.

**For reprints contact:** WKHLRPMedknow\_reprints@wolterskluwer.com

**How to cite this article:** Sharma N, Memon MA, Sharma S, Sharma M, Chaurasia B, Verma SR. Transanastomotic tube in intestinal atresia: How beneficial are they? Afr J Paediatr Surg 2019;16:29-32.

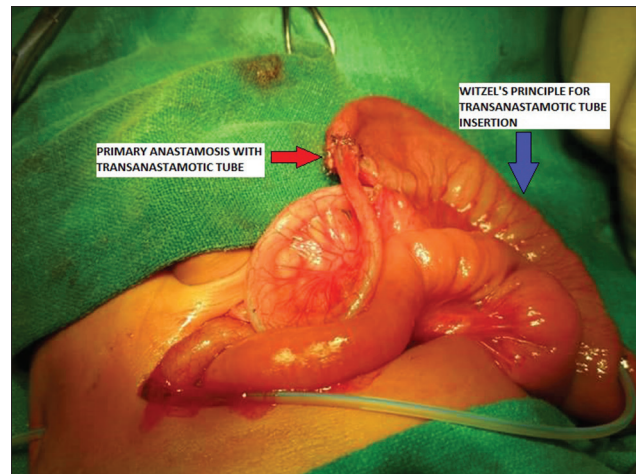


**Figure 1:** Typical case of jejunal atresia (Type 2)

a number five infant feeding tube (as transanastomotic stent). The anastomosis was done using single layer vicryl 5-0 interrupted sutures with imbrications tapering of the proximal dilated segment using vicryl 5-0 suture in two layers [Figures 1 and 2]. TAT was inserted from the imbricated bowel on Witzel's principle of feeding jejunostomy (exteriorised through the parietal wall). Number five infant feeding tube was used as a TAT for feeding in all the cases. Feeding was started as soon as the bowel sound returned with the beginning amount of 2 ml 2 hourly and gradually built up to the required amount. Infusion pumps were not used in the purpose of feeding in any of the cases; relatives were made familiar with the feeding process and hygiene by counselling with the volunteer relatives of the previously operated patient with their consent. The TAT was kept *in situ* for a minimum of 6 weeks. Oral feeds were started after 2 weeks in all the cases (with or without TAT) and this was gradually built-up. TAT was kept clamped and strapped even if feeds were tolerated orally as stand by for rescue situation. The outcome in terms of average stays in the hospital, feeding and other parameters were analysed. The data analysis was done using STATA software version 11 (Stata Corp LP, Texas, USA). The statistical tests considered were Chi-square test and Wilcoxon signed-rank test. *P* value was calculated using Fisher's exact test (owing to the sample size) and the value  $< 0.05$  was considered as statistically significant.

## RESULTS

A total of 48 cases operated during the study duration for the anomalies were included. There were 29 male and 19 female. There were two duodenal atresia, 29 jejunal atresia and 17 ileal atresia. The mean age at surgery was 2 days (range: 1–16 days). Mean operating time was 48 min (range: 30–72 min). There were 6 cases in which the anastomosis was done either without a TAT or the tube came out accidentally within 72 hours of the surgery. In the remaining 42 cases the TAT remain in situ. The average duration of start of feeds was 78 h (range: 72–96 h) in the TAT group, while it was 402 h (range: 360–504 h) in the anastomosis



**Figure 2:** Primary anastomosis with tapering jejunoplasty (red arrow) with transanastomotic tube insertion on Witzel's principle (blue arrow)

without TAT group ( $P = 0.01$ ). The mean duration of hospital stay in the TAT group was 7 days (range: 5–15 days), while in the primary anastomosis without TAT group, the hospital stay was 27 days (range: 19–48 days) ( $P = 0.02$ ). The overall survival in the TAT group was 38 (91%), while in the primary anastomosis group, it was 3 (50%) ( $P = 0.01$ ) [Tables 1 and 2]. Re-exploration was required in 2/42 cases in the TAT group due to complications like bowel perforation at the tip of the TAT. In patients without TAT, the re-exploration was required in 2/6 cases ( $P = 0.4$ ), where anastomosis had to be dismantled, and the stoma was made due to none functioning anastomosis. TPN was required in 2/42 cases (where perforation was seen) in the TAT group while was required in the all cases of group without TAT. Features of sepsis requiring prolonged antibiotics were seen in two cases of TAT group, while sepsis was seen in two cases of the non-TAT group also.

## DISCUSSION

Intestinal atresia is common neonatal anomaly dealt by paediatric surgeons. The natural history of the disease is always such that there is a gross discrepancy in the calibre of the proximal bowel and the distal atretic segment. This discrepancy may range up to the tune of 100:1. There are various proposed management options which include stoma such as Mikulicz, Santulli or divided stoma.<sup>[2]</sup> As the Closure of these stomas remain again a challenge in the later period, there is an inclination for primary anastomosis, whenever feasible and management on TPN till the anastomosis becomes functional. Masumoto *et al.*<sup>[3]</sup> showed that there is a hypoplasia of the intramural nerves and pacemaker cells in the proximal segment of the atretic bowel; they proposed that this may contribute to the post-operative dysmotility which they labelled as disturbed intestinal transit.

Thus, the associated ineffective peristalsis was proposed to produce functional post-operative obstruction. The post-operative obstruction may be partly due to ineffective peristalsis or partly due to the luminal discrepancy. This may

**Table 1: Difference in the outcomes**

Parameters	Primary anastomosis with TA tube or Group A (n=42)	Primary anastomosis without TA tube or Group B (n=6)	P
Type of the anomaly			
Duodenal atresia	2	0	NA
Jejunal atresia	27	2	NA
Ileal atresia	13	4	NA
Associated congenital anomalies	12	3	NA
Average duration of start of feed (h)	78	402	0.001
Average hospital stay (days)	7	27	0.02
Overall survival (%)	38 (91)	3 (50)	0.001

NA: Not available, TA: Transanastomotic

**Table 2: Morbidity in the cases of intestinal atresia**

Morbidity parameters	Primary anastomosis with TA tube or Group A (n=42)	Primary anastomosis without TA tube or Group B (n=6)
Re-exploration	2	2
TPN	2	6
Sepsis	2	2

TPN: Total parental nutrition, TA: Transanastomotic

subsequently lead to a delay in the starting of oral feeding and subsequently longer hospital stay.<sup>[4,5]</sup> On the other hand, if the entire dilated proximal jejunal segment is resected, it may result into short bowel syndrome.<sup>[6,7]</sup> Various treatment methods were described to combat this intestinal dysmotility, which ranged from resection of the dilated bowel by Nixon<sup>[8]</sup> to resection and tapering by Howard and Othersen.<sup>[9]</sup> Howard and Othersen observed the return of peristalsis in the tapered jejunum radiographically. de Lorimier and Harrison<sup>[10]</sup> modified the procedure of resection with infolding and tapering. They plicated the antimesenteric portion of the dilated bowel instead of resecting it. We used their principle in anastomosis and could anastomose primarily in all the cases. Our additional effort was to add feeding jejunostomy through a TAT for early enteral feeding. Due to logistics, infant feeding tube was used as a TAT in all the cases. We used longitudinal Witzel technique<sup>[11]</sup> and added a subserosal tunnel with the insertion of TAT. TATs are routinely used in the management of duodenal atresia and their benefit is well established,<sup>[12]</sup> but their role in Jejunal and ileal atresia needs validation. Doing anastomosis in intestinal atresia is technically a challenge because there is a gross discrepancy between the proximal and the distal bowel making the anastomosis difficult; the anastomosis is always single layer with doubtful vascularity of the vessel making the possibility of leak in the post-operative period. The redundancy of the dilated proximal bowel remains even after the anastomosis

leading to delayed emptying through the anastomosis and requirement of long-term support like TPN.

TPN in the paediatric age group is also associated with its problems and logistics. In situation, there are issues such as

1. Lack of the availability of small calibre central venous catheter or peripherally inserted central catheter lines for the administration of the TPN
2. If proper aseptic precautions are not taken, it may be a source of sepsis
3. There is an issue of financial constrains making TPN/central line and long ICU stay not feasible for a majority of the population.

In a limited facility setup like ours, the main aim becomes reducing the stay and less dependence on the intravenous assess. Apart from the logistics poor economic status of the parents and lack of availability of the central line makes the situation further challenging. We thus tried to evolve with a protocol to reduce the duration of stay of these cases and also to start enteral feeds as early as possible. However, we faced the problem that the material of the infant feeding tube used as a TAT became stiff after 2 weeks of stay, and unfortunately, we observed complication in the form of intestinal perforation in two unfortunate cases. We feel that an analysis of the type of tube that could be used as TAT can be done to find the ideal material suiting the purpose. When we compared our outcome in a patient with TAT with those without tube, we found a significant difference in their results. We thus feel that this protocol can be used routinely in all the cases with atresia, especially in a challenging situation like ours.

## CONCLUSION

Primary repair in intestinal atresia with a TAT is a good and practical option. The overall outcome in these cases is better in those operated without TAT.

## Financial support and sponsorship

Nil.

## Conflicts of interest

There are no conflicts of interest.

## REFERENCES

1. Ozturk H, Ozturk H, Gedik S, Duran H, Onen A. A comprehensive analysis of 51 neonates with congenital intestinal atresia. *Saudi Med J* 2007;28:1050-4.
2. Grosfeld JL. Jejunoileal atresia and stenosis. In: Grosfeld JL, O'Neill JA, Coran AG, editors. *Pediatric Surgery*. 6<sup>th</sup> ed.. Philadelphia: Mosby, Elsevier; 2006. p. 1269-87.
3. Masumoto K, Suita S, Nada O, Taguchi T, Guo R. Abnormalities of enteric neurons, intestinal pacemaker cells, and smooth muscle in human intestinal atresia. *J Pediatr Surg* 1999;34:1463-8.
4. Eltayeb AA. Different surgical techniques in management of small intestinal atresia in high risk neonates. *Ann Pediatr Surg* 2009;5:31-5.
5. Shahjahan K, Ferdous N, Mitul AR, Islam MK. Management of jejunoileal atresia: Our 5 year experience. *Chattagram Maa O Shishu Hosp Coll J* 2013;12:52-5.
6. Stollman TH, de Blaauw I, Wijnen MH, van der Staak FH, Rieu PN, Draaisma JM, *et al.* Decreased mortality but increased morbidity in

- neonates with jejunoileal atresia; a study of 114 cases over a 34-year period. *J Pediatr Surg* 2009;44:217-21.
7. Shakya VC, Agrawal CS, Shrestha P, Poudel P, Khaniya S, Adhikary S, *et al.* Management of jejunoileal atresias: An experience at Eastern Nepal. *BMC Surg* 2010;10:35.
  8. Nixon HH. Intestinal obstruction in the newborn. *Arch Dis Child* 1955;30:13-22.
  9. Howard ER, Othersen HB Jr. Proximal jejunoplasty in the treatment of jejunal atresia. *J Pediatr Surg* 1973;8:685-90.
  10. de Lorimier AA, Harrison MR. Intestinal plication in the treatment of atresia. *J Pediatr Surg* 1983;18:734-7.
  11. Tapia J, Murguia R, Garcia G, de los Monteros PE, Oñate E. Jejunostomy: Techniques, indications, and complications. *World J Surg* 1999;23:596-602.
  12. Arnbjörnsson E, Larsson M, Finkel Y, Karpe B. Transanastomotic feeding tube after an operation for duodenal atresia. *Eur J Pediatr Surg* 2002;12:159-62.