

Atrial tachycardia arising from the distal left atrial appendage requiring high-power endocardial and epicardial ablation



Houman Khakpour, MD, FHRS, Justin H. Hayase, MD, Jason S. Bradfield, MD, FHRS, Eric Buch, MD, FHRS, Kalyanam Shivkumar, MD, PhD, FHRS

From the UCLA Cardiac Arrhythmia Center, David Geffen School of Medicine at UCLA, Los Angeles, California.

Introduction

Focal atrial tachycardias (AT) arising from the distal portion of left atrial appendage (LAA) are rare and pose unique anatomic challenges during catheter ablation. We report a case of incessant AT originating from the LAA refractory to antiarrhythmic drug therapy in which a combined endocardial and percutaneous epicardial mapping was used and that was successfully ablated only after using high-power energy in the LAA.

Case report

A 25-year-old male patient with incessant AT and presumed tachycardia-mediated cardiomyopathy was referred to our institution for catheter ablation. A prior electrophysiology study (EPS) had localized the focus of AT to the LAA and limited endocardial ablation was unsuccessful. Twelve-lead electrocardiography showed AT with P waves negative in leads I and aVL, positive and bifid in inferior leads and lead V₁, consistent with a left AT (Figure 1A).¹ Echocardiogram showed a left ventricular ejection fraction of 45% with mild global hypokinesis. EPS at our center demonstrated AT (presenting rhythm) with a cycle length range of 470–630 ms. Earliest atrial activation on the coronary sinus (CS) catheter (conventional CS catheter position with proximal electrode at the level of CS ostium) was recorded at the distal CS. Given our knowledge of the prior EPS and an unsuccessful endocardial ablation, pericardial access was planned and obtained from a percutaneous subxiphoid approach prior to anticoagulation. Following that, left atrial mapping via

KEY TEACHING POINTS

- Atrial tachycardias arising from the distal portion of the left atrial appendage (LAA) are uncommon, often incessant, and a reversible cause of cardiomyopathy.
- Such tachycardias present unique anatomic challenges during catheter ablation owing to a highly variable LAA geometry, presence of a network of pectinate muscles, and variability in tissue thickness.
- Real-time echocardiography, LAA angiography, and detailed electroanatomic mapping may identify such anatomic challenges and increase success rate.

transseptal approach using a CARTO PentaRay catheter (Biosense Webster, Diamond Bar, CA) and an irrigated contact force-sensing ablation catheter (CARTO ThermoCool SmartTouch SF; Biosense Webster) localized the focal tachycardia to the distal portion of the anterior lobe of the LAA (Figure 2A and 2B). To confirm that the entire appendage was adequately mapped, LAA angiography was performed and intracardiac echocardiography (ICE) and percutaneous intrapericardial echocardiography were used. Multiple radiofrequency (RF) applications in the LAA at the site of earliest activation (–64 ms relative to P-wave onset) with power 30 watts, contact force 15–30 grams, and duration up to 60 seconds, associated with local impedance drop of 10–12 ohms, resulted in acceleration of the tachycardia without termination (Figure 1C). Epicardial mapping with the ablation catheter localized the site of earliest activation to a relatively broad area at the distal anteromedial surface of the LAA, overlying the endocardial site (Figure 2C). High-output pacing was done with the ablation catheter in the pericardial

KEYWORDS Atrial tachycardia; High-power radiofrequency ablation; Left atrial appendage; Percutaneous epicardial ablation; Percutaneous intrapericardial echocardiography
(Heart Rhythm Case Reports 2021;7:157–161)

Disclosures: Jason Bradfield has received speaking honoraria from Abbott and Boston Scientific; other authors have nothing to disclose. Funding: Kalyanam Shivkumar is supported by NIH R01HL084261 and U01EB025138. **Address reprint requests and correspondence:** Dr Houman Khakpour, UCLA Cardiac Arrhythmia Center, 100 Medical Plaza, Suite 660, Los Angeles, CA. E-mail address: HKhakpour@mednet.ucla.edu.

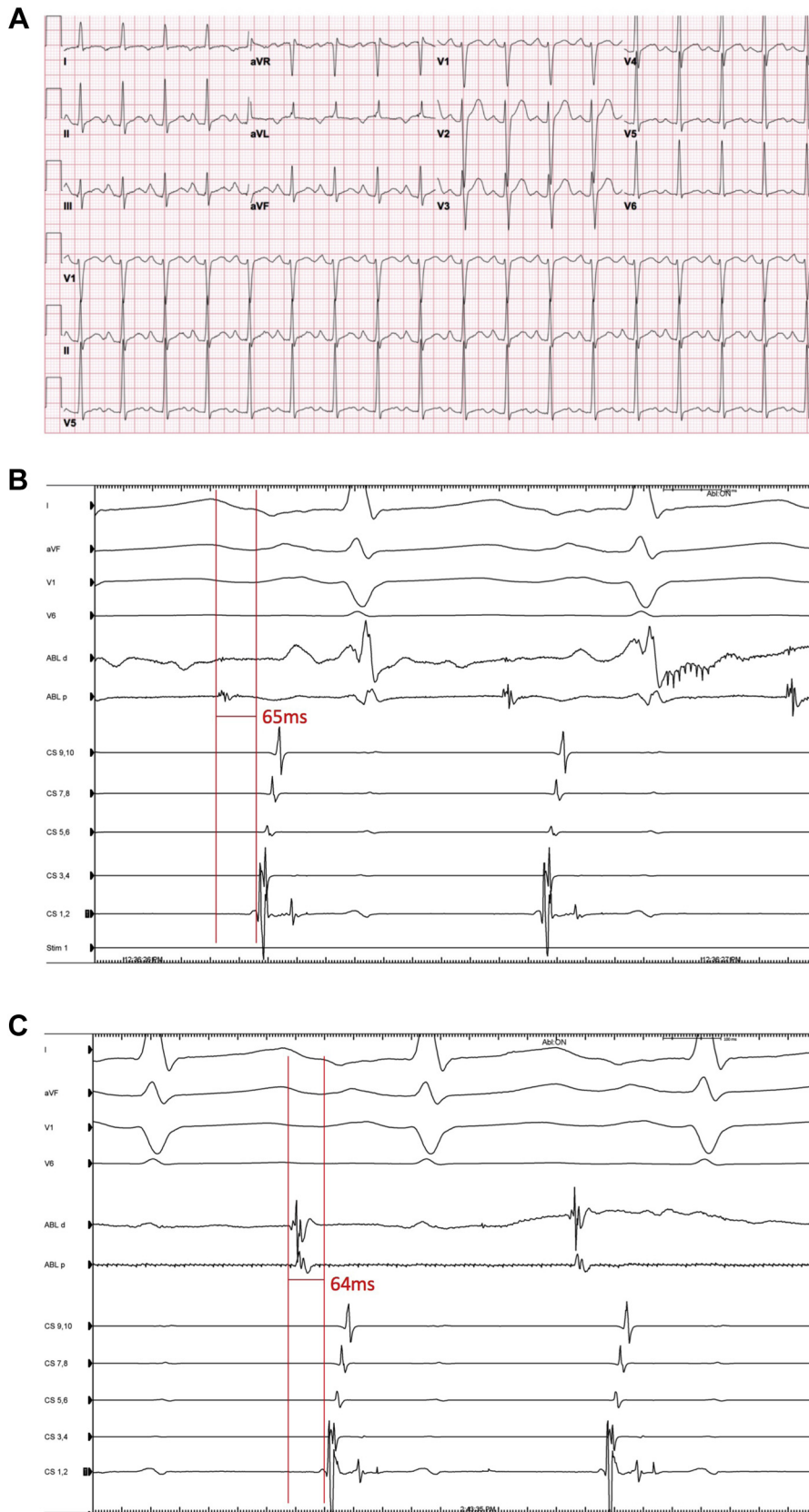

Figure 1 A: Twelve-lead surface electrocardiogram of atrial tachycardia with P waves negative in leads I and aVL, positive and bifid in inferior leads and lead V₁, consistent with a left atrial tachycardia. B: Earliest epicardial activation with ablation signal -65 ms preceding surface P wave. C: Earliest endocardial activation with ablation signal -64 ms preceding surface P wave. Ablation at this site with power of 50 W was successful in terminating tachycardia.

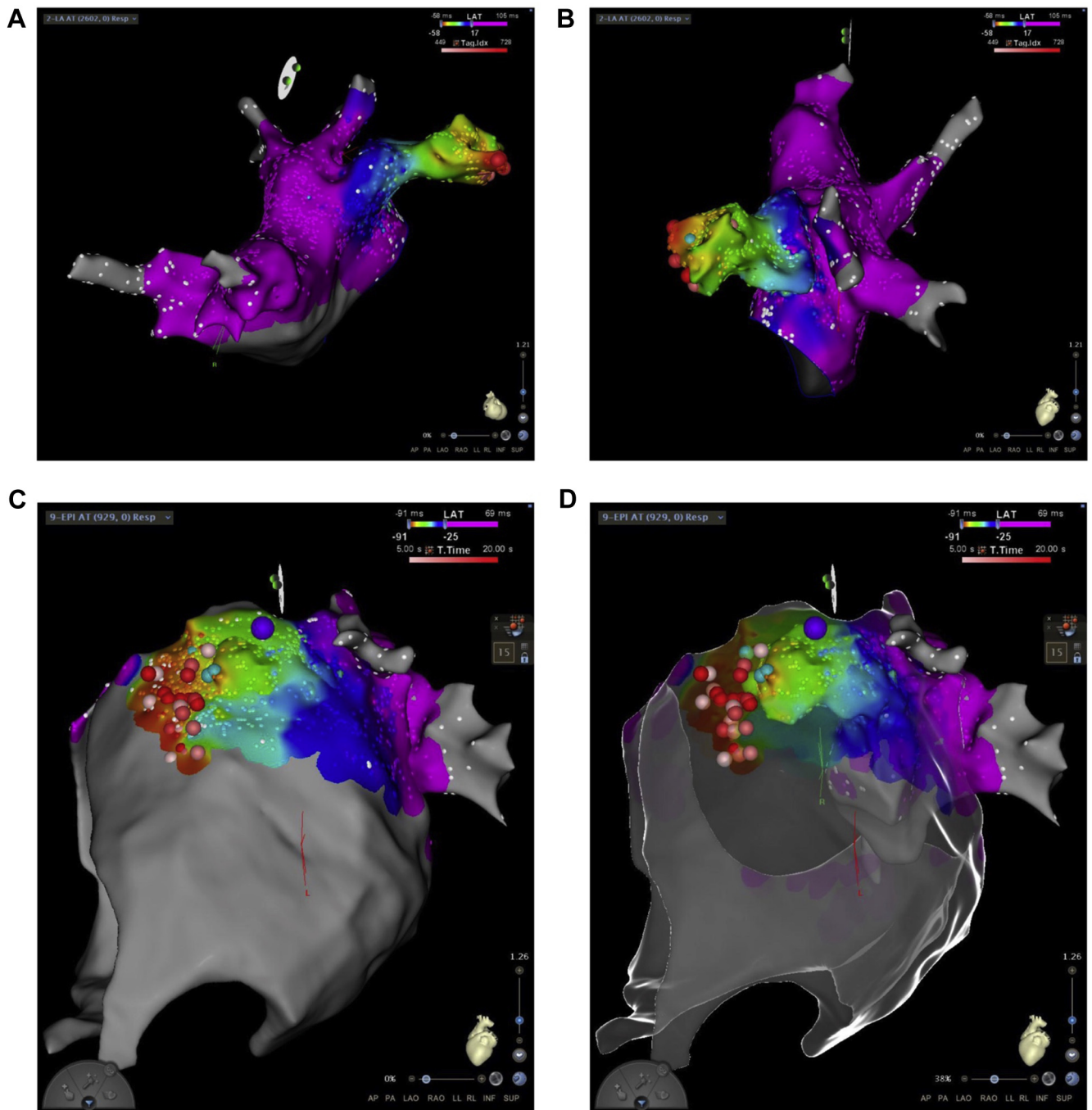


Figure 2 A, B: Right anterior oblique cranial (A) and left lateral cranial (B) view of left atrial endocardial activation map using CARTO (Biosense Webster, Diamond Bar, CA), demonstrating earliest atrial activation in the distal left atrial appendage. C: Left lateral view of epicardial activation map demonstrating a relatively broad area of early activation overlying the distal left atrial appendage. D: Superimposed epicardial and endocardial activation maps demonstrating epicardial surface overlying endocardial geometry of the left atrial appendage. Purple dot marks the site of left phrenic nerve capture.

space to identify the left phrenic nerve course and to avoid phrenic nerve injury. ICE was used to identify the location of the left main coronary artery and its proximal bifurcation, in relation to the ablation site. Epicardial ablation at this site (Figure 1B; signal preceding P-wave onset by 65 ms) with power 50 watts, for up to 60 seconds, associated with local impedance drop of 10–13 ohms, only transiently suppressed the tachycardia, despite use of a contrast-filled balloon cath-

eter (Berman angiographic catheter; Teleflex Inc, Wayne, PA) placed in the LAA on the endocardial side to provide counter-pressure support (Figure 3A). Review of percutaneous intrapericardial echocardiography of the LAA suggested presence of thick pectinate muscles near the site of ablation (Figure 3C and 3D) with endocardial-epicardial lesion separation of at least 6 mm using CARTOSOUND module (Biosense Webster, Diamond Bar, CA, USA).

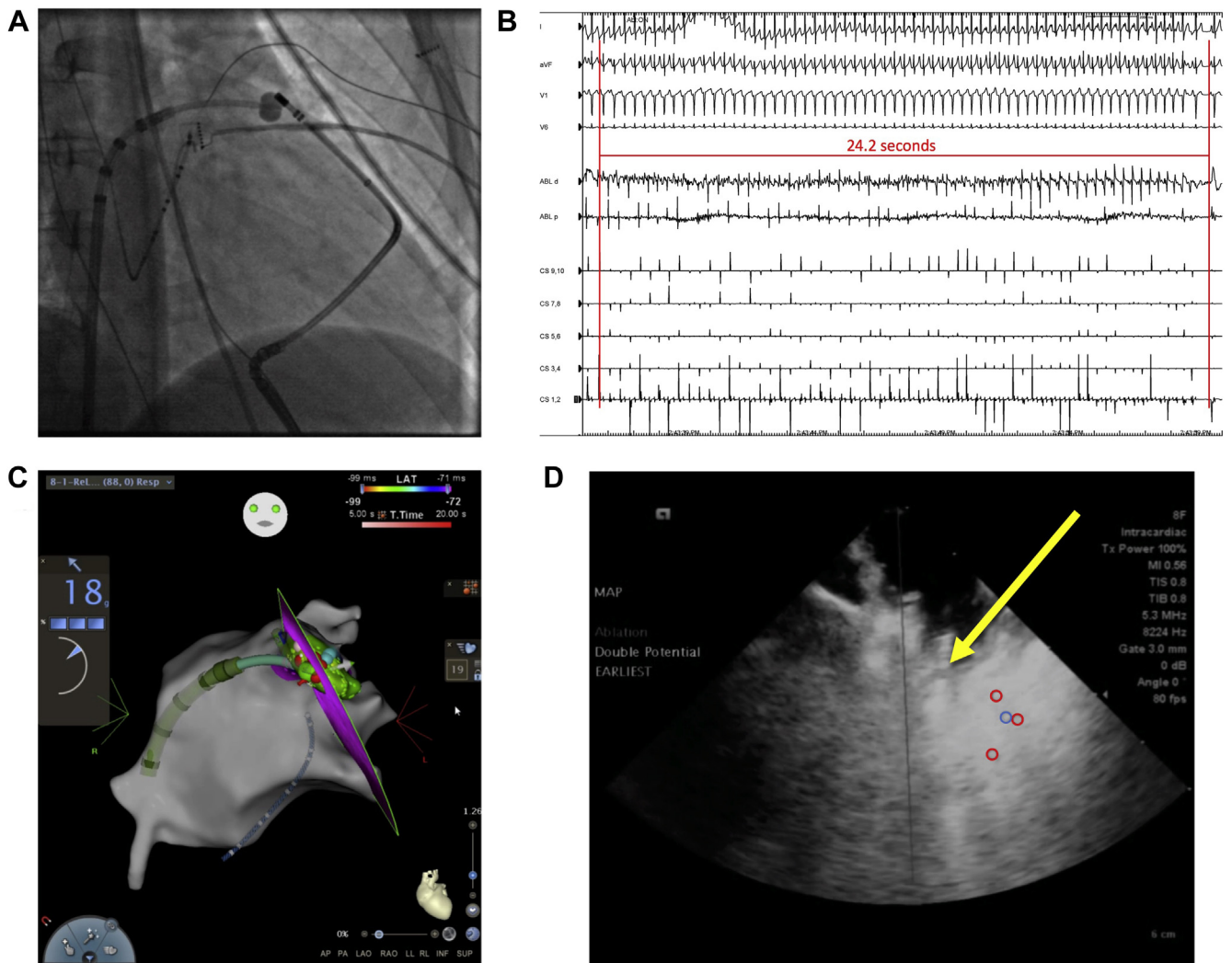


Figure 3 **A**: Fluoroscopic image in right anterior oblique view with 7F balloon-tipped Berman catheter (Teleflex Inc, Wayne, PA) placed within the distal left atrial appendage on the endocardial side for applying counter-pressure with the ablation catheter at the site of earliest epicardial activation. **B**: Successful ablation lesion from endocardial site with power titrated to 50 W with termination of tachycardia at 24.2 seconds. **C**: CARTOSOUND (Biosense Webster, Diamond Bar, CA) demonstrating ablation catheter at successful endocardial site. The ultrasound probe is in the pericardial space superior and posterior-medial to the left atrial appendage. **D**: Intracardiac percutaneous echocardiography image demonstrating ablation catheter tip (yellow arrow) within the distal left atrial appendage. Epicardial ablation lesions indicated with red open circles. Blue circle indicates annotation of an early mapping site on the epicardial side.

Endocardial ablation at the earliest site at power 50 watts, duration 60 seconds, with average contact force of 25 grams, associated with an impedance drop of 14 ohms, terminated the tachycardia 24 seconds after onset of RF delivery (Figure 3B). Additional lesions were delivered adjacent to this site at 50 watts. Tachycardia was not inducible after the ablation despite isoproterenol infusion. The patient remained free of arrhythmias on 30- and 90-day follow-ups with resolution of cardiomyopathy based on echocardiography.

Discussion

Atrial tachycardias arising from the LAAd are uncommon.² Though high success rate is reported with catheter ablation from both an endocardial and epicardial approach,²⁻⁵ they

present unique anatomic challenges including the following: (1) variations in the LAA shape and lobes and presence of reticulated pectinate muscles, which may restrict endocardial access to the distal portions^{5,6}; (2) variations in the LAA tissue thickness, including its pectinate muscles, ranging from 0.5 mm to up to 5 mm,^{5,7-9} potentially increasing perforation risk or limiting adequate lesion formation in the deeper segments; and (3) LAA proximity to the left phrenic nerve, which can have a highly variable course. Numerous tools and techniques can be employed to increase successful ablation at these locations; these include the following: (1) use of LAA angiography, echocardiography, or other imaging such as computed tomography to delineate LAA structure during the procedure (the latter 2 may provide additional information about the tissue thickness); (2) use of contact

force-sensing catheters to assess catheter-tissue contact when navigating in the LAAd; (3) epicardial mapping and use of counter-pressure support from either the endocardial or epicardial side to improve contact³; and (4) high output pacing to identify the left phrenic nerve.

In the case presented, detailed endocardial mapping facilitated by LAA angiography and echocardiography identified the earliest activation site in the LAAd with signal preceding the P wave by 64 ms. This timing is consistent with sites of successful ablation in prior studies (for example, Yang and colleagues² reported endocardial activation time of the successful RF application sites to be 47 ± 4.3 ms before P-wave onset). Epicardial mapping provided similar activation timing in a broader region overlying the endocardial site. Counter-pressure against the epicardial lesions using a contrast-filled balloon catheter placed in the LAA was applied, though that did not affect ablation results. Pressure was crudely assessed using fluoroscopy and tactile feedback. We used this approach after unsuccessful epicardial energy application, mainly owing to lack of a reliable tool for force measurement in the epicardial space. Other investigators have reported successful application of counter-pressure from the epicardial side using an ablation catheter for termination of LAAd AT.³

Utility of ICE and percutaneous intrapericardial echocardiography has been previously described.¹⁰ Combined with the electroanatomic map, percutaneous intrapericardial echocardiography provided an assessment of the tissue thickness in the LAAd as well as an estimate of the endocardial-epicardial RF lesions distance. ICE views of the LAA—for instance, obtained from the main pulmonary artery or the left atrium—would have likely provided similarly useful information. Based on these findings (wide spatial separation of earliest sites on the endocardial and epicardial sides and distal LAA thickness noted on echocardiography flanking endocardial-epicardial lesions), we postulated that the AT site of origin was within a deeper segment of the pectinate muscle. Histologic data of patients with LAAd AT undergoing surgical atrial appendectomy have pointed to presence of clusters of cells with abnormal automaticity, some within the pectinate muscles, protected by complex trabeculae geometry from both endocardial and epicardial ablation.^{5,11} High-power RF energy was applied on the endocardial aspect of

the LAAd based on these findings, which was successful in terminating the tachycardia. Ablation parameters including local impedance and catheter-tissue interface using echocardiography were closely monitored.

Alternative approaches in management of LAAd AT refractory to “conventional” ablation include surgical atrial appendectomy and electrical isolation of LAA. Surgical LAA removal was discussed with the patient prior to the procedure, but the patient opted for a percutaneous approach owing to an anticipated faster recovery, desire to avoid surgery, and operators’ experience with the percutaneous approach. LAA electrical isolation was not pursued—and the endocardial ablation did not lead to such outcome—owing to an increased thromboembolism risk after isolation and need for lifelong anticoagulation or LAA occlusion.¹²

References

1. Kistler PM, Roberts-Thomson KC, Haqqani HM, et al. P-wave morphology in focal atrial tachycardia: development of an algorithm to predict the anatomic site of origin. *J Am Coll Cardiol* 2006;48:1010–1017.
2. Yang Q, Ma J, Zhang S, Hu JQ, Liao ZL. Focal atrial tachycardia originating from the distal portion of the left atrial appendage: characteristics and long-term outcomes of radiofrequency ablation. *Europace* 2012;14:254–260.
3. Phillips KP, Natale A, Sterba R, et al. Percutaneous pericardial instrumentation for catheter ablation of focal atrial tachycardias arising from the left atrial appendage. *J Cardiovasc Electrophysiol* 2008;19:430–433.
4. Yamada T, McElderry HT, Allison JS, Kay GN. Focal atrial tachycardia originating from the epicardial left atrial appendage. *Heart Rhythm* 2008;5:766–767.
5. Guo XG, Zhang JL, Ma J, et al. Management of focal atrial tachycardias originating from the atrial appendage with the combination of radiofrequency catheter ablation and minimally invasive atrial appendectomy. *Heart Rhythm* 2014;11:17–25.
6. Kamiński R, Kosiński A, Brala M, et al. Variability of the left atrial appendage in human hearts. *PLoS One* 2015;10:e0141901.
7. Veinot JP, Harrity PJ, Gentile F, et al. Anatomy of the normal left atrial appendage. *Circulation* 1997;96:3112–3115.
8. Su P, McCarthy KP, Ho SY. Occluding the left atrial appendage: anatomical considerations. *Heart* 2008;94:1166–1170.
9. Wi J, Lee HJ, Uhm JS, et al. Complex fractionated atrial electrograms related to left atrial wall thickness. *J Cardiovasc Electrophysiol* 2014;25:1141–1149.
10. Horowitz BN, Vaseghi M, Mahajan A, et al. Percutaneous intrapericardial echocardiography during catheter ablation: a feasibility study. *Heart Rhythm* 2006;3:1275–1282.
11. de Bakker JM, Hauer RN, Bakker PF, Becker AE, Janse MJ, De Medina EOR. Abnormal automaticity as mechanism of atrial tachycardia in the human heart—electrophysiologic and histologic correlation: a case report. *J Cardiovasc Electrophysiol* 1994;5:335–344.
12. Kim YG, Shim J, Oh SK, Lee KN, Choi JI, Kim YH. Electrical isolation of the left atrial appendage increases the risk of ischemic stroke and transient ischemic attack regardless of postisolation flow velocity. *Heart Rhythm* 2018;15:1746–1753.