

Open Trillat Procedure for Recurrent Anterior Instability of the Shoulder in Elderly Patients



Victor Housset, M.D., Romain Chevallier, M.D., and Geoffroy Nourissat, M.D. Ph.D.

Abstract: Among the many different procedures available in the treatment of shoulder instability, the Trillat procedure remains indicated in case of recurrent shoulder instability in elderly patient with an irreparable cuff tear or in case of hyperlaxity. Despite the constantly increasing number of arthroscopic assisted techniques, the open procedure remains a simple, reliable and fast surgical procedure with a shorter learning curve than the arthroscopic techniques. It consists in a partial osteotomy of the anterior cortical of the coracoid process which is then tilted and fixed with a screw into the anterior part of the scapula downwards and medially to obtain a re-centering effect due to the conjoint tendon on the humeral head when rotational movement are applied. This article aims to present a stepwise approach for the open surgical technique.

The shoulder is the most mobile joint of the body, which explains the high incidence of shoulder dislocations.¹ Ninety-five percent of the instabilities are anterior, and most of them present in young patients.² However, the incidence of anterior dislocation in middle-aged and elderly patient is increasing with the continuously increasing average population age and demand for participation in leisure sports.^{3,4} Some studies demonstrate an incidence of almost 20% of shoulder dislocation for patients of 60 years of age and older.^{5,6} Previous work concluded that hyperlaxity or pathologic capsular ligamentous restraints due to a plastic deformation were not indications for a Bankart repair.^{7,8}

The Trillat procedure was first described in 1954 and consisted of a partial osteotomy of the coracoid process, which is tilted and fixed into the anterior scapular neck with a screw medially and downwards.⁹ As was demonstrated by Patte in 1981 in the concept of “triple locking” during the Bristow-Latarjet procedure, the transposition of the coracoid process leads to a modification of the

conjoint tendon to achieve a dynamic blocking function against and around the humeral head with a dynamic recentering effect.¹⁰

This procedure has been proven to be a safe one to restore the range of motion and to prevent recurrences for the treatment of anterior shoulder instability. Its efficacy has been shown to be 88% to 100% for the prevention of the recurrences.¹¹⁻¹⁴ Good functional results are also found after this procedure, including patient satisfaction, range of motion, and return to sport.^{9,11,12,15} The objective of this paper is to present the surgical technique for the open Trillat procedure step by step with specific technical notes.

Surgical Technique (With Video Illustration)

The main indications and contraindications for the open Trillat procedure are given in [Table 1](#). To perform the open Trillat procedure, the patient is positioned in a supine position under general anesthesia with the arm reposing on a separated moveable table. An interscalene block is usually performed to minimize postoperative pain. The operated upper limb must be freely accessible to allow the maximum of amplitude while performing the surgery. The head of the patient is maintained in neutral position in a regular head-fixation device.

The coracoid process is localized by palpation and marked. The skin incision is generally 4 cm in length and starts 1.5 cm proximal to the apex of the coracoid process ([Fig 1](#)). A proximal deltopectoral approach is performed with the arm in neutral position, and the coracoid process with the conjoint tendon is exposed. Dissection from the conjoint tendon is then performed

From Clinique Maussins-Nollet, Sorbonne Université, Paris, France.

The authors report that they have no conflicts of interest in the authorship and publication of this article. Full ICMJE author disclosure forms are available for this article online, as [supplementary material](#).

Received November 20, 2020; accepted January 22, 2021.

Address correspondence to Victor Housset, M.D., Clinique Maussins-Nollet, Sorbonne Université, Paris, France. E-mail: victor.housset@hotmail.fr

© 2021 THE AUTHORS. Published by Elsevier Inc. on behalf of the Arthroscopy Association of North America. This is an open access article under the CC BY-NC-ND license (<http://creativecommons.org/licenses/by-nc-nd/4.0/>).

2212-6287/201888

<https://doi.org/10.1016/j.eats.2021.01.021>

Table 1. Main Indications and Contraindications for the Open Trillat Procedure

Indications	Contraindications
<ul style="list-style-type: none"> • Elderly patient with recurrent dislocations, normal range of motion, a good subscapularis, and irreparable rotator cuff tear • Patient with hyperlaxity (external rotation over 85° with the arm at side) • Capsular distension or deficiency without major bony defect of the glenohumeral joint 	<ul style="list-style-type: none"> • Intra-articular lesion needing a surgical assessment • ISIS score <3 with no plastic capsular deficiency • Important bone lesion on the glenoid or the humeral head • Bipolar bone lesion with off-track lesion following the glenoid track concept • Pseudoparalytic shoulder

ISIS, Instability Severity Index Score.

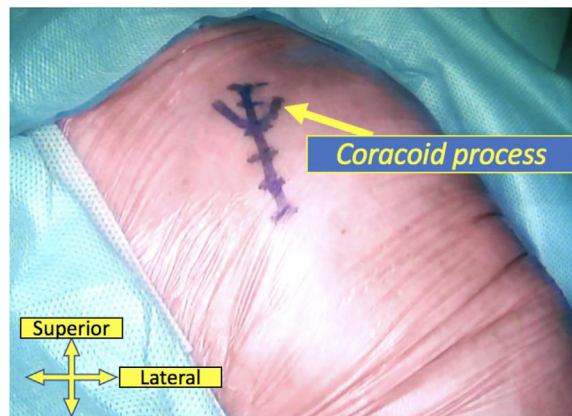


Fig 1. Visualization of the skin incision for an open Trillat procedure of approximately 4 cm centered on the coracoid process and starting 1.5 cm proximally to the coracoid apex. The patient is in the supine position and the operated upper limb must be freely accessible to allow the maximum of amplitude while performing the surgery. The superior and lateral side of the patient's body is shown.

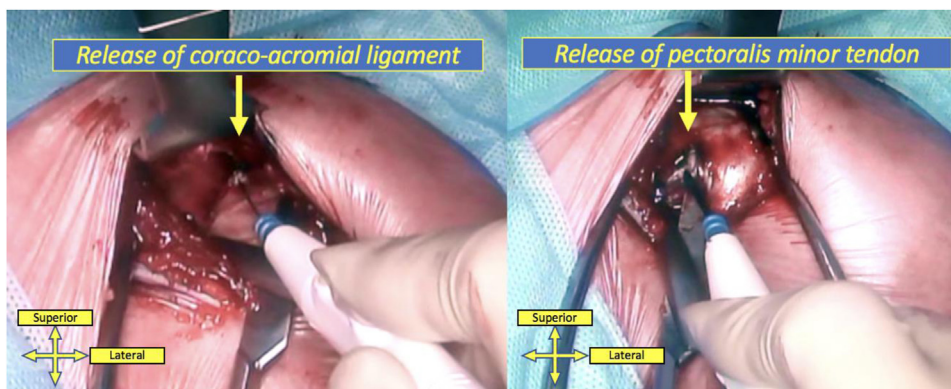


Fig 2. The open Trillat procedure requires an exposure of the coracoid process with a release of the coracoacromial ligament (on the left) and the pectoralis minor (on the right). Caution must be made to prevent any bleeding of the coracoacromial ligament artery. The superior and lateral side of the patient's body is shown.

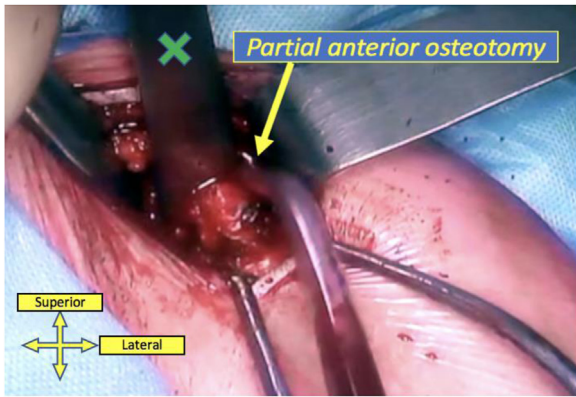


Fig 3. The open Trillat procedure requires one to perform an osteoclasia of the superior cortical of the elbow of the coracoid process with an osteotome (green cross). Caution is needed not to break the inferior cortical of the coracoid process, and an osteotomy of three quarters of the coracoid is recommended. The superior and lateral side of the patient's body is shown.

both laterally and medially with caution to prevent bleeding from the vessels localized into the fat at this level. The superior part of the coracoid process is exposed with a Hohmann retractor to obtain the best visualization during the extra-articular coracoid dissection. The lateral border of the coracoid process is released, and the coracoacromial ligament is sectioned with a special caution to prevent any bleeding of the coracoacromial ligament artery. On the medial border of the coracoid, the pectoralis minor muscle is released, as we usually do during an open Bristow-Latarjet procedure to prevent the postoperative risk of compression of the brachial plexus (Fig 2). The superior and inferior

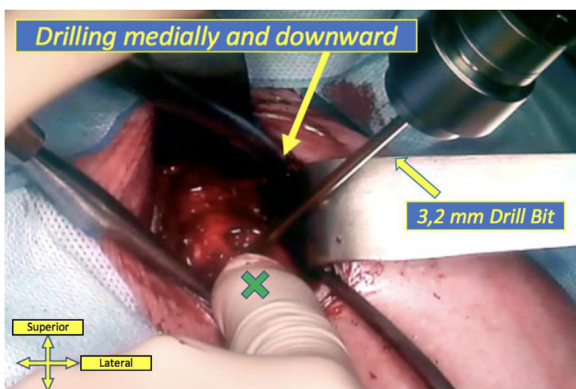


Fig 4. During the open Trillat procedure, careful control of the positioning of the coracoid process is needed. It must be tilted and maintained medially and downward (green cross). The anterior scapular neck is drilled with a 3.2-mm drill bit. The green cross shows the careful positioning of the coracoid process medially and downward with the guidewire passing through the anterior scapular neck upward the superior border of the subscapularis muscle. The arm must be placed in internal rotation to open the subcoracoid space and to prevent subscapularis subcoracoid impingement. The superior and lateral side of the patient's body is shown.

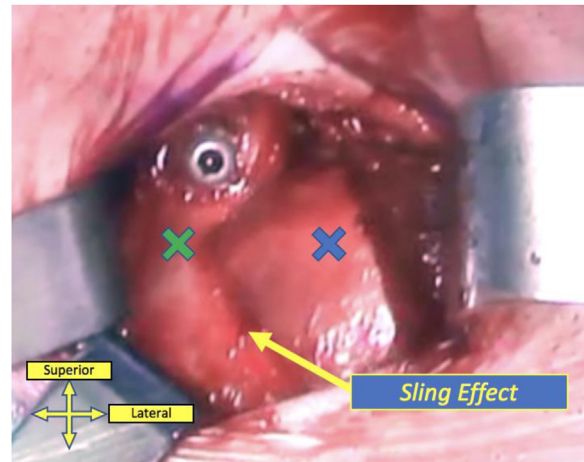


Fig 5. At the end of the open Trillat procedure, it is necessary to control the sling effect of the conjoint tendon (green cross) around the humeral head (blue cross) with rotational movements applied on the arm at the end of the procedure. The superior and lateral side of the patient's body is shown.

cortical is drilled using a 3.2-mm drill bit at the same distance from all sides of the coracoid process tip. The retractor is then replaced by the osteotome to ensure the best positioning before the osteoclasia at the superior part coracoid process. The anterior coracoid process cortical partial osteotomy is performed with specific attention not to break the inferior cortical of the elbow of the coracoid process (Fig 3). An osteotomy of three quarters of the coracoid is recommended. An electrocautery of the osteotomized bone section can be made to prevent bleeding. The coracoid process is then carefully mobilized and is tilted medially and downward (Fig 4). Once the desired positioning is obtained, always while being careful handling the coracoid, a guidewire is placed inside the drilled hole in the coracoid process

Table 2. Step-by-Step Approach of the Open Trillat Procedure

- Identification by palpation of the coracoid apex.
- Skin incision of approximately 4 cm starting 1.5 cm proximal to the coracoid apex.
- Deltopectoral approach.
- Section of the coracoacromial ligament and release of the pectoralis minor tendon.
- Identification of the anterior cortical drilling site in the middle of the coracoid process.
- Careful partial osteotomy of the anterior coracoid neck.
- Soft mobilization of the coracoid process downward and medially.
- Good maintain of the coracoid while drilling the anterior scapular neck.
- Use of a guidewire and a cannulated screw not to lose the direction of the drilled holes.
- Positioning of the arm in internal rotation during the placement of the screw.
- Control of the sling effect of the conjoint tendon on the humeral head at the end of the procedure.
- Closing the deltopectoral approach to prevent skin retraction due to subcutaneous fibrosis.

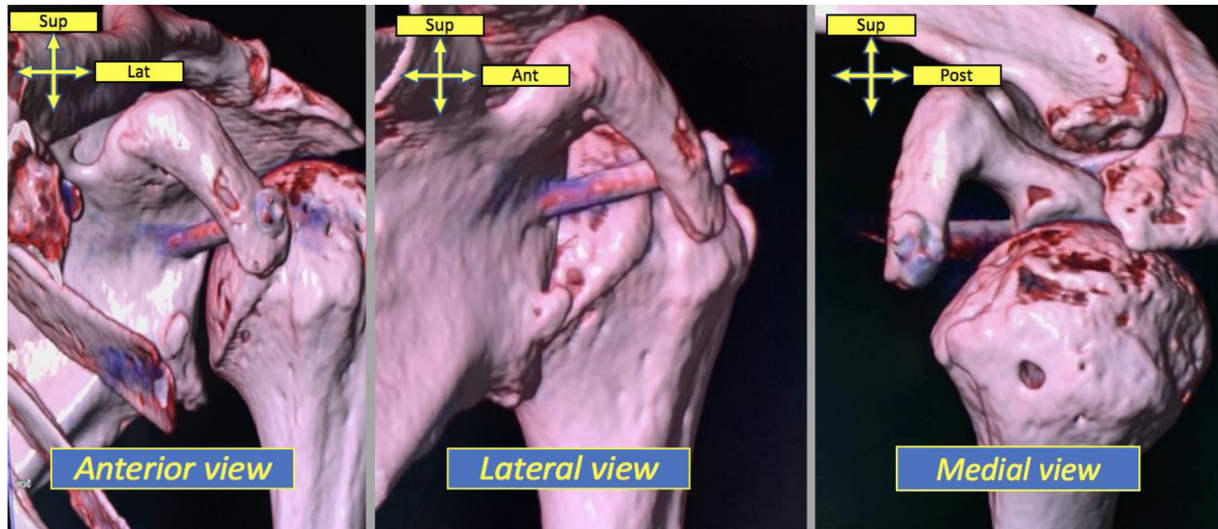


Fig 6. Three-dimensional reconstructions on controlled computed tomography at 6 months postoperatively showing a good healing of the coracoid process after an open Trillat procedure. The coracoid process has to be mobilized medially and downward. Yellow arrows show the orientation of the images. (Ant, anterior; Lat, lateral; Post, posterior; Sup, superior.)

and positioned at the anterior aspect of the scapula and upward the superior border of the subscapularis muscle to allow its sliding. The anterior and posterior cortical of the anterior scapular neck is then drilled using the same 3.2-mm drill bit device.

With the guidewire passing through both coracoid process and scapular neck, a 4-mm cannulated cancellous screw (DePuy Synthes, Warsaw, IN) is tightened carefully without any compression to avoid over-tensioning between the deeper part of the coracoid and the anterior aspect of the scapular neck. The arm must be placed in internal rotation to open the subcoracoid space and to prevent subscapularis subcoracoid impingement. At the end of the procedure, we visually control the sling effect of the coracoid fixation by controlling the conjoint tendon sliding around the humeral while rotation movements of the arm are applied (Fig 5). During humeral abduction and external rotation, it is possible to visualize the humeral head being pushed posteriorly. The deltopectoral space is closed to prevent the risk of subcutaneous retraction.

Postoperative cares include a shoulder immobilizer for 3 weeks with an abduction pillow and early

pendular exercises and passive rehabilitation. Active physiotherapy and the Liotard protocol are started at the third week. Clinical follow-up is performed at the third and the sixth weeks with postoperative radiographs to control the good positioning of the coracoid process and the screw. The healing of the coracoid process is evaluated at 6 months using a computed tomography scan. Return to sport and to work for heavy workers is allowed at the third month.

The surgical procedure of the open Trillat procedure is described in Video 1, and main steps are given in Table 2. The 3-dimensional reconstruction aspect of the coracoid consolidation is shown in Figure 6 at 6 months postoperatively. Main advantages and disadvantages of the open Trillat procedure compared with the arthroscopic procedure are given in Table 3.

Discussion

Several treatments are available for patients presenting a recurrent anterior shoulder instability. Arthroscopic Bankart lesion repair and open or arthroscopic Latarjet procedure remain the 2 most frequent surgeries and many elements help the surgeon to choose between

Table 3. Main Advantages and Disadvantage of the Open Trillat Procedure Compared With the Arthroscopic Trillat Procedure

Advantages	Disadvantages
<ul style="list-style-type: none"> • Fast learning curve • Intraoperative assessment of the “sling effect” of the conjoint tendon and the excursion of the subscapularis • Short time procedure and no need for arthroscopic devices • Less expensive • Precise control of the tilting of the coracoid process and soft control during the mobilization • Less risk for lesion of the brachial plexus compared with the arthroscopic procedure 	<ul style="list-style-type: none"> • No possible arthroscopic assessment of the associated lesion • No intra-articular procedure • Size of the incision and theoretical wound complication risk • Risk of missed osteoclasia at the beginning of the learning curve • More invasive procedure • Release of the pectoralis minor and possible consequences on the scapula kinetic • Risk of lesion of the musculocutaneous nerve during the procedure

these 2 procedures. For example, the Instability Severity Index Score was developed to help the surgeons decide when to prefer to perform a Latarjet procedure over a classical Bankart repair.¹⁶

In a report from a multicenter register in Norway, Blomquist et al.² found, in 404 procedures for anterior instability, no Trillat procedures, only arthroscopic Bankart, capsular shift, or open Latarjet procedures, underlying the low use of this procedure. However, the Trillat procedure still has indications, including middle-aged patients with irreparable rotator cuff disease, notably. Jouve et al.¹⁴ analyzed a retrospective series of patients operated for recurrent anterior dislocations associated with full-thickness rotator cuff tear to determine the timing of treatment of these 2 pathologies and whether both needed to be treated. Nineteen of 27 patients treated have had an isolated open stabilization with an open Trillat procedure due to a not repairable cuff or because of the will of the patient. At a mean follow-up of 73.5 months, 16% of the patients treated with an isolated open stabilization with Trillat technique had recurrence of instability (vs none for the patients with both anterior stabilization by Latarjet procedure and rotator cuff repair) and less functional scores, but it was important to notice an age of 20 years older in this group. Boileau et al.¹⁷ proposed a modified arthroscopic Bristow procedure in association with an arthroscopic Bankart for anterior shoulder instability with a deficient capsule consisting in a transfer of the conjoint tendon to reinforce a deficiency capsule by lowering the subscapularis to obtain a “sling effect” to stabilize the joint, which is similar to the classical Trillat procedure. Of the 36 patients available for the preliminary report, 92% were very satisfied or satisfied at a 1-year minimum follow-up. They included patient with hyperlaxity in their indication in association with the patients with a pathologic capsule, failed anterior instability repair, or large Hill–Sachs lesion. We similarly consider that patients with hyperlaxity (external rotation with arm at side $>85^\circ$) may be consider for the Trillat procedure in the treatment of anterior instability.

Like for almost all the shoulder stabilization procedure, current works on that surgery are nowadays concerning the arthroscopic technique of the Trillat procedure.¹⁸ As the arthroscopic Latarjet procedure, the arthroscopic Trillat procedure is technically demanding, especially since it is necessary to be extremely careful during the realization of the osteoclasis in order not to break the inferior cortical of the elbow of the coracoid process. If good results are obtained with the arthroscopic technique, it remains challenging and less invasive than the open technique. It allows the assessment of the subscapularis at the end of the procedure to prevent any infra-coracoid impingement (which may lead to a loss of external rotation) as the treatment of associated lesions.¹⁹

Labattut et al.²⁰ described an arthroscopy-assisted Trillat procedure for anterior shoulder instability in 18 patients as a simple and reproductive alternative to arthroscopic Latarjet procedure. They found at a median follow-up of 24.7 months very satisfactory clinical outcomes with 94% of satisfied or very satisfied patients and no recurrences recorded. Unfortunately, no comparison was made with classical open Trillat procedure, which led to the impossibility to conclude to a superiority of the arthroscopic Trillat procedure over the open procedure. However, because Trillat procedure is performed in our experience in elderly patients, it makes sense not to do any intra-articular Bankart repair or any other intra-articular joint procedure. Gerber et al.¹³ reported a high rate of secondary osteoarthritis after Trillat because in elderly patients the joint is already damaged and, thus, we do not recommend to do it under arthroscopy.

Conclusions

No difference in the clinical or functional results has been demonstrated between the arthroscopic and the open technique for the Trillat procedure to this day, and this surgery still has good and globally recognized indications. The open Trillat procedure and the different steps comprising it must be known by orthopaedic surgeons who specialize in shoulder surgeries because no surgical strategy can be put aside in a such complex pathology as shoulder instability.

References

1. Streubel PN, Krych AJ, Simone JP, et al. Anterior glenohumeral instability: A pathology-based surgical treatment strategy. *J Am Acad Orthop Surg* 2014;22:283-294.
2. Blomquist J, Solheim E, Liavaag S, Schroder CP, Espehaug B, Havelin LI. Shoulder instability surgery in Norway: The first report from a multicenter register, with 1-year follow-up. *Acta Orthop* 2012;83:165-170.
3. Leroux T, Wasserstein D, Veillette C, et al. Epidemiology of primary anterior shoulder dislocation requiring closed reduction in Ontario, Canada. *Am J Sports Med* 2014;42:442-450.
4. Delgrande D, Werthel JD, Lonjon G, Ciais G, Klouche S, Hardy PP. Arthroscopic Bankart repair in patients over 30 years of age. Clinical and radiologic results at more than 10 years follow-up. *Arthroscopy* 2017;33:e162.
5. Murthi AM, Ramirez MA. Shoulder dislocation in the older patient. *J Am Acad Orthop Surg* 2012;20:615-622.
6. Gumina S, Postacchini F. Anterior dislocation of the shoulder in elderly patients. *J Bone Joint Surg Br* 1997;79:540-543.
7. Cole BJ, Millett PJ, Romeo AA, et al. Arthroscopic treatment of anterior glenohumeral instability: Indications and techniques. *Instr Course Lect* 2004;53:545-558.
8. Calvo E, Granizo JJ, Fernandez-Yruegas D. Criteria for arthroscopic treatment of anterior instability of the shoulder: A prospective study. *J Bone Joint Surg Br* 2005;87:677-683.

9. Trillat A. Traitement de la luxation récidivante de l'épaule; considérations techniques [Treatment of recurrent dislocation of the shoulder; technical considerations]. *Lyon Chir* 1954;49:986-993 [in French].
10. Patte D. Shoulder anterior instability. *Cahier d'enseignement de la SOFCOT* 1981;15:55-66 [in French].
11. Landmann J, Steenblock U, Allgöwer M. Ergebnisse der Operation nach Trillat bei der habituellen Schulterluxation [Results following Trillat's surgery in habitual shoulder dislocation]. *Helv Chir Acta* 1980;47:89-92 [in German].
12. Walch G, Dejour H, Trillat AG. La luxation récidivante antérieure de l'épaule survenant après 40 ans [Recurrent anterior luxation of the shoulder occurring after the age of 40]. *Rev Chir Orthop Reparatrice Appar Mot* 1987;73:609-616 [in French].
13. Gerber C, Terrier F, Ganz R. The Trillat procedure for recurrent anterior instability of the shoulder. *J Bone Joint Surg Br* 1988;70:130-134.
14. Jouve F, Graveleau N, Nové-Josserand L, Walch G. Luxation récidivante antérieure de l'épaule et rupture de la coiffe des rotateurs: résultats du traitement chirurgical [Recurrent anterior instability of the shoulder associated with full thickness rotator cuff tear: results of surgical treatment]. *Rev Chir Orthop Reparatrice Appar Mot* 2008;94:659-669 [in French].
15. Trillat A, Leclerc-Chalvet F. *Luxation récidivante de l'épaule*. Paris: Masson, 1973.
16. Balg F, Boileau P. The instability severity index score. A simple pre-operative score to select patients for arthroscopic or open shoulder stabilisation. *J Bone Joint Surg Br* 2007;89:1470-1477.
17. Boileau P, Bicknell RT, El Fegoun AB, Chuinard C. Arthroscopic Bristow procedure for anterior instability in shoulders with a stretched or deficient capsule: The "belt-and-suspenders" operative technique and preliminary results. *Arthroscopy* 2007;23:593-601.
18. Swan J, Boileau P, Barth J. Arthroscopic Trillat procedure: A guided technique. *Arthrosc Tech* 2020;9:e513-e519.
19. Valenti P, Maroun C, Schoch B, Arango SO, Werthel JD. Arthroscopic Trillat coracoid transfer procedure using a cortical button for chronic anterior shoulder instability. *Arthrosc Tech* 2019;8:e199-e204.
20. Labattut L, Bertrand V, Reybet Degat PY, et al. Arthroscopy-assisted Trillat procedure for anterior shoulder instability: Surgical technique and preliminary clinical results. *Orthop Traumatol Surg Res* 2018;104:811-816.