

## Evaluation of intravitreal injection of pentoxifylline in experimental endotoxin-induced uveitis in rabbits

Mohammad Reza Khalili<sup>1</sup>, Amin Hossein Amini<sup>2\*</sup>, Mohammad Abbaszadeh Hasiri<sup>2</sup>, Effat Baghaei Moghaddam<sup>2</sup>, Masoomeh Eghtedari<sup>1</sup>, Mohammad Azzizadeh<sup>3</sup>, Mousa Zare<sup>1</sup>, Masood Yasemi<sup>1</sup>

<sup>1</sup> Poostchi Ophthalmology Research Center, Department of Ophthalmology, Shiraz University of Medical Sciences, Shiraz, Iran; <sup>2</sup> Department of Clinical Sciences, Faculty of Veterinary Medicine, Shiraz University, Shiraz, Iran; <sup>3</sup> Department of Clinical Sciences, Faculty of Veterinary Medicine, Ferdowsi University of Mashhad, Mashhad, Iran.

Article Info	Abstract
<b>Article history:</b> Received: 16 September 2017 Accepted: 09 January 2018 Available online: 15 September 2018	The objective of the present study was to investigate the clinical and histopathological effects of intravitreal injection of pentoxifylline (PTX) the management of an experimental model of uveitis. Fifty-two rabbits were divided randomly into six intravitreal treated groups as below: 1) Balanced salt solution (BSS), 2) <i>Salmonella typhimurium</i> lipopolysaccharide endotoxin (LPS) + BSS, 3) LPS + PTX 100 µg, 4) LPS + PTX 500 µg, 5) BSS + PTX 100 µg and 6) BSS + PTX 500 µg. Inflammation was evaluated by clinical examinations using slit lamp on days 1, 3, 5 and 7 post injections and histopathological examinations were also performed at the end of the study. Clinical examinations demonstrated a statistically significant difference between group 1 and group 2 on day 5 and day 7. Moreover, the comparison of clinical severity scores of group 1 with groups 3, 4, 5 and 6, on third, fifth and seventh post-injection days showed statistically significant differences. The mean histopathological inflammation intensity score in groups 5 and 6 was significantly higher than group 1. The mean histopathological inflammation intensity score in groups 3, 4, 5 and 6 was significantly higher than group 2. Intravitreal injection of PTX in an experimental model of uveitis in rabbits not only does not reduce inflammation but also leads to inflammation when used alone or in combination with LPS.
<b>Key words:</b> Endotoxin-induced uveitis Intravitreal injection Pentoxifylline Tumor necrosis factor-α	
© 2018 Urmia University. All rights reserved.	

### بررسی تزریق داخل زجاجیه‌ای پنتوکسی‌فیلین در یوویت تجربی ناشی از اندوتوکسین در خرگوش‌ها

#### چکیده

هدف مطالعه حاضر ارزیابی آثار بالینی و هیستوپاتولوژیکی تزریق داخل زجاجیه‌ای پنتوکسی‌فیلین در مدیریت مدل تجربی یوویت بود. پنجاه و دو عدد خرگوش به صورت تصادفی در شش گروه درمانی تجویز داخل زجاجیه‌ای به شرح زیر تقسیم شدند: (۱) محلول نمکی متعادل شده، (۲) محلول نمکی متعادل شده + اندوتوکسین لیپوپلی ساکارید سالمونلا تافی موریوم، (۳) اندوتوکسین لیپوپلی ساکارید سالمونلا تافی موریوم + ۱۰۰ میکروگرم پنتوکسی‌فیلین، (۴) اندوتوکسین لیپوپلی ساکارید سالمونلا تافی موریوم + ۵۰۰ میکروگرم پنتوکسی‌فیلین، (۵) محلول نمکی متعادل شده + ۱۰۰ میکروگرم پنتوکسی‌فیلین و (۶) محلول نمکی متعادل شده + ۵۰۰ میکروگرم پنتوکسی‌فیلین. التهاب از طریق معاینات بالینی با لامپ اسلیت در طی روزهای یک، سه، پنج و هفت پس از تزریقات مورد ارزیابی قرار گرفت و بررسی‌های هیستوپاتولوژیکی نیز در انتهای مطالعه انجام پذیرفت. ارزیابی‌های بالینی بین گروه ۱ و ۲ در روزهای پنج و هفت تفاوت آماری معناداری را نشان داد. بعلاوه، مقایسه میزان شدت علائم بالینی گروه یک با گروه‌های سه، چهار، پنج و شش در روزهای سوم، پنجم و هفتم بعد از تزریق از لحاظ آماری تفاوت معناداری را نشان داد. میانگین میزان شدت التهاب هیستوپاتولوژیکی در گروه‌های ۵ و ۶ به طور چشمگیر بیشتر از گروه ۱ بود. میانگین میزان شدت التهاب هیستوپاتولوژیکی در گروه‌های ۳، ۴، ۵ و ۶ به طور قابل ملاحظه‌ای بیشتر از گروه دوم بود. تزریق داخل زجاجیه‌ای پنتوکسی‌فیلین در مدل تجربی یوویت در خرگوش‌ها نه تنها منجر به کاهش التهاب نمی‌گردد، بلکه زمانی که همراه با لیپوپلی ساکارید یا به صورت مجزا تجویز شود باعث ایجاد التهاب می‌گردد...

**واژه‌های کلیدی:** تزریق داخل زجاجیه‌ای، پنتوکسی‌فیلین، فاکتور نکروز دهنده تومور آلفا، یوویت ناشی از اندوتوکسین

#### \*Correspondence:

Amin Hossein Amini. DVM, DVSc  
Department of Clinical Sciences, Faculty of Veterinary Medicine, Shiraz University, Shiraz, Iran.  
E-mail: [a.h.amini@shirazu.ac.ir](mailto:a.h.amini@shirazu.ac.ir)



This work is licensed under a Creative Commons Attribution-NonCommercial 4.0 International License which allows users to read, copy, distribute and make derivative works for non-commercial purposes from the material, as long as the author of the original work is cited properly.

## Introduction

Uveitis is one of the major ocular disorders that results in preventable blindness.<sup>1</sup> It contains inflammatory pathologies affecting the uveal tract of the eye and it can also involve the vitreous body, optic nerve and retina.<sup>2</sup> Uveitis can lead to cystoid macular edema among other complications resulting in reduced vision and even permanent visual loss.<sup>2</sup> Although the actual pathogenic mechanisms underlying uveitis are defectively recognized, cytokines which are thought of as essential mediators of immunologic and inflammatory reactions, seem to be associated with this disorder. Several cytokines including tumor necrosis factor- $\alpha$  (TNF- $\alpha$ ), interleukin-1 (IL-1), IL-2, IL-6 and interferon- $\gamma$  have been recognized in ocular material received from patients with uveitis.<sup>3-6</sup> A definitive or effective treatment modality for uveitis has not yet been introduced. The development of a perfect treatment modality aiming to control inflammation and reduce recurrence in patients with uveitis remains a significant research goal.<sup>7</sup>

The TNF- $\alpha$  is a significant element in the pathogenesis of uveitis<sup>8</sup> and many studies have suggested that TNF- $\alpha$  is also involved in the development of endotoxin-induced uveitis (EIU).<sup>6,9</sup>

Pentoxifylline (PTX) is a methylxanthine derivative and a non-selective phosphodiesterase inhibitor with hemorrhheological property.<sup>10</sup> The PTX has also been found to increase leukocyte deformability, inhibit neutrophil adhesion and activation and inhibit TNF- $\alpha$  production.<sup>11</sup> Furthermore, different studies have shown that PTX enhances polymorphonuclear cell motility and chemotaxis.<sup>12</sup> The mechanism of action might be multifactorial.<sup>13</sup> The PTX has garnered increased attention as it had been demonstrated to inhibit or attenuate the release of TNF- $\alpha$  induced by lipopolysaccharide (LPS) *in vitro* and *in vivo* by elevating intracellular levels of cAMP.<sup>14</sup> The TNF- $\alpha$  is an essential inflammatory mediator and is known to modulate synthesis of different cytokines and other inflammatory molecules.<sup>15</sup> Thus, inhibition of TNF- $\alpha$  could eventually result in a reduction of other inflammatory mediators such as IL-1, IL-6 and IL-8.<sup>16</sup> PTX is not merely able to prevent the release of TNF- $\alpha$ , but can also influence the secretion of IL-1B, IL-6 and IL-8.<sup>17</sup>

There are few studies that have investigated the effect of systemic treatment of PTX in uveitis in human and experimental models.<sup>18-20</sup> Therefore, in view of the inhibitory activity of PTX on TNF- $\alpha$  and the potential role of PTX in the treatment of human uveitis, the present study was designed to investigate the clinical and histopathological effects of intravitreal injection of PTX on ocular inflammation in an experimental EIU.

## Materials and Methods

The study was conducted on 52 New Zealand white rabbits from both sexes weighting between 2.50 and 3.80 kg. All rabbits were treated in accordance with the Association for Research in Vision and Ophthalmology Statement for the Use of Animals in Ophthalmic and Vision Research and all animal experiments were approved by the State Committee on Animal Ethics, Shiraz University (IACUC No: 4687/63). The animals were kept under standard laboratory conditions at 21 °C and 50.00% humidity and fed rabbit commercial food in a 12-hr light/12-hr dark cycle and water was available *ad libitum*. All rabbits were examined by slit lamp microscope and indirect ophthalmoscopy before the intravitreal injections. Only left eye of each animal was used in this experiment. The rabbits were randomly divided into six groups: the first group (n = 8) received 0.10 mL balanced salt solution (BSS) intravitreally, the second group (n = 8) received 2.00  $\mu$ g 0.05 mL<sup>-1</sup> *Salmonella typhimurium* LPS (L6511; Sigma, St. Louis, USA) plus 0.05 mL BSS, the third group (n = 12) received 100  $\mu$ g 0.05 mL<sup>-1</sup> PTX (Sigma) plus 2.00  $\mu$ g 0.05 mL<sup>-1</sup> LPS, the fourth group (n = 12) received 500  $\mu$ g 0.05 mL<sup>-1</sup> PTX plus 2.00  $\mu$ g 0.05 mL<sup>-1</sup> LPS, the fifth group (n = 6) received 100  $\mu$ g 0.05 mL<sup>-1</sup> PTX plus 0.05 mL BSS and sixth group (n = 6) received 500  $\mu$ g 0.05 mL<sup>-1</sup> PTX plus 0.05 mL BSS. Injections were made under aseptic condition 2.50 mm posterior to the limbus through a 31-gauge needle. Topical ciprofloxacin 0.30% (Sina Darou, Tehran, Iran) and timolol 0.50% (Sina Darou) were applied before and after the injections and the eyes were examined by indirect ophthalmoscopy for intra-operative complications. All injections were done by a single investigator in a masked fashion. All procedures were performed under general anesthesia with an intramuscular injection of a mixture of ketamine hydrochloride 10.00% (35 mg kg<sup>-1</sup>, Alfasan, Woerden, Netherlands) and xylazine hydrochloride 2.00% (5.00 mg kg<sup>-1</sup>, Alfasan) and acepromazine 1.00% (0.70 mg kg<sup>-1</sup>, Alfasan). Tetracaine eye drop (0.50%; Sina Darou) was used for topical anesthesia. All rabbits were observed for signs of clinical inflammation by slit-lamp biomicroscope (Sl 115; Carl Zeiss, Oberkochen, Germany) in upward position consciously without any sedation. The degree of anterior chamber inflammation was clinically assessed in a masked manner by two investigators 24 hr after the intravitreal injections and then every other day up to seventh post-injection day. Two rabbits were died maybe because of dysbiosis due to gastrointestinal stasis as a result of stress or even pain on the third and fifth post-injection days and were excluded from groups 2 and 1, respectively. All eyes were evaluated for vascular, pupillary, hypopyon and exudative inflammatory signs. The intensity of intraocular inflammation signs was graded using a clinical scoring system described previously.<sup>21</sup>

Iris hyperemia was scored for absence (0), mild (1), moderate (2) or severe (3); pupil was scored as miotic (0) or normal (1); anterior chamber flare was scored as absence (0), mild (1) or severe (2) and hypopyon was scored for none (0) or positive (1). The maximum possible uveitis score—that is the sum of the four parameter scores—was 7.

On the seventh post intravitreal injection day, the rabbits were euthanized by an intraperitoneal injected overdose of sodium pentobarbital (150 mg kg<sup>-1</sup>; Sigma). Immediately, the eyes were enucleated. Whole globes were fixed in 10% formaldehyde for three days and processed in a standard manner for light microscope using hematoxylin and eosin. Pupillo-optic sections were made through the pupillary-optic nerve axis and observed under microscope. Ophthalmic pathologist counted all infiltrating inflammatory cells in two random, noncontiguous fields at 200× magnification in both anterior (anterior chamber, iris and iris-ciliary body) and posterior segment sections (vitreous and retina). A semi-logarithmic grading scale from Verma *et al.* was used.<sup>22</sup> The grades were as follows: grade 0 = no cells per field; grade 1 = 1 to 10 cells per field; grade 2 = 11 to 30 cells per field; grade 3 = 31 to 100 cells per field and grade 4 = 101 to 300 cells per field. The mean histopathological inflammation intensity score including anterior chamber, iris, ciliary body, vitreous and retina was used for statistical analyses.

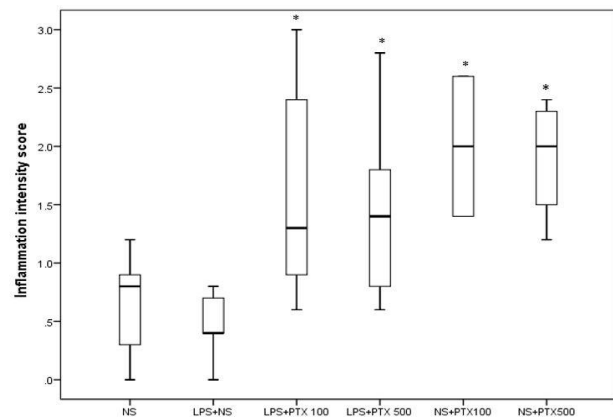
A Kruskal Wallis test was used to compare the histopathological and clinical scores and *p* value of less than 0.05 was considered significant. Mann-Whitney U test with Bonferroni correction was used to detect which pairs had significant difference and value of *p* < 0.01 was considered significant. Statistical analysis was performed using SPSS (version 21.0; SPSS Inc., Chicago, USA).

## Results

**Clinical severity score.** On the first up to seventh post-injection days in all groups except group 1, some

degrees of ocular inflammation with signs of iris hyperemia, miosis and anterior chamber flare were seen. In addition, on the first, third, fifth and seventh post-injection days, group 1 rabbits showed no clinical sign of ocular inflammation at any time point (median clinical severity scores were 0). Comparison of median clinical severity score according to slit lamp examination grading between the six groups on the first, third, fifth and seventh post-injection days is presented in Table 1. The comparison of clinical severity score between groups 1 and 2 on the fifth and seventh post-injection days showed a clinically significant difference (*p* = 0.002 and *p* = 0.001, respectively). In addition, the comparison of clinical severity score between groups 1 and 3, 1 and 4, 1 and 5 and 1 and 6, on the third, fifth and seventh post-injection days showed more severe ocular inflammation and clinically significant different inflammation (*p* < 0.01).

**Histopathological examination.** Median, first and third quartile of histopathological inflammation intensity scores in six groups are shown in Fig. 1. The mean



**Fig. 1.** Box-and whisker plot of histopathology average of inflammation intensity scores in six experimental groups are shown in box plot. NS: Normal saline; LPS: Lipopolysaccharid; PTX: Pentoxifylline. \* Asterisk indicates significant difference between main treatments vs NS and LPS+NS (*p* < 0.05).

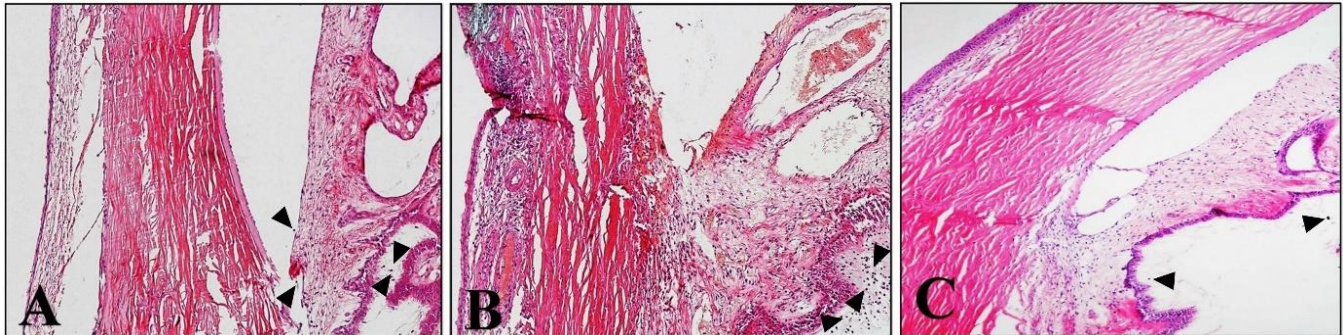
**Table 1.** Comparison of clinical uveitis scores according to slit lamp examination grading between the experimental groups. Data are presented as median (range).

Groups	Number	Day 1	Day 3	Day 5	Day 7
NS	8	0 (0 to 2)	0 (0 to 3)	0 (0 to 1)	0 (0 to 0)
NS+LPS	8	2.00 (0 to 4)	2.00 (0 to 3)	2.00 (1 to 3)	2.00 (1 to 3)
LPS+PTX 100	12	2.00 (0 to 4)	3.50 (1 to 7)	3.00 (1 to 7)	3.00 (0 to 7)
LPS+PTX 500	12	2.00 (0 to 6)	1.50 (0 to 7)	1.50 (0 to 7)	1.00 (0 to 7)
NS+PTX100	6	2.00 (2 to 3)	3.50 (2 to 4)	4.00 (3 to 5)	4.00 (2 to 5)
NS+PTX 500	6	2.00 (0 to 4)	4.00 (2 to 7)	4.00 (2 to 7)	4.00 (0 to 7)
<i>p</i> value*		0.094	0.002	0.001	0.002
<b>Pair-wise comparison †</b>					
NS vs NS+LPS				0.002	0.001
NS vs LPS+PTX 100			0.001	< 0.001	0.001
NS vs LPS+PTX 500			0.009	0.002	0.001
NS vs NS+PTX 100			0.008	0.004	0.002
NS vs NS+PTX 500			0.004	0.002	0.007

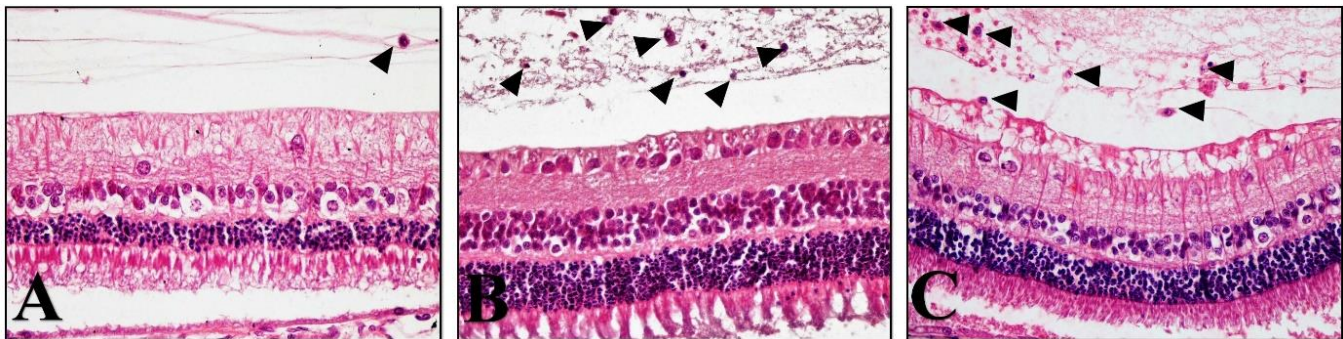
NS: Normal saline; LPS: Lipopolysaccharid; PTX: Pentoxifylline; \* Calculated by the Kruskal-Wallis test (*p* < 0.05 considered as significant); † Calculated by the Mann-Whitney U test (*p* < 0.01 considered as significant).

inflammation intensity scores including anterior chamber, iris, ciliary body, vitreous and retina in groups 5 and 6 were significantly higher than group 1 ( $p = 0.008$  and  $p = 0.01$ , respectively). In addition, the mean inflammation

intensity scores in groups 3, 4, 5 and 6 were significantly higher than group 2 ( $p = 0.001$ ,  $p = 0.007$ ,  $p = 0.001$  and  $p = 0.007$ , respectively), so histopathological examination (Figs. 2 and 3) revealed that PTX can induce



**Fig. 2.** Inflammatory cell infiltration (arrowheads) and ciliary body congestion of hematoxylin-eosin-stained photomicrographs (100 $\times$ ) from anterior chamber angle appearance in histological sections of LPS (A), PTX 500  $\mu$ g (B) and LPS+PTX 500  $\mu$ g (C) groups are noted.



**Fig. 3.** Vitreous infiltration with inflammatory cells (arrowheads) of hematoxylin-eosin-stained photomicrographs (400 $\times$ ) from retina appearance in histological sections of LPS (A), PTX 500  $\mu$ g (B) and LPS+PTX 500  $\mu$ g (C) groups are noted.

## Discussion

The EIU is a well-known animal model for evaluating the efficacy of treatment for ocular inflammation.<sup>23</sup> Although many pro-inflammatory mediators have been involved in the pathogenesis of uveitis, it has been proposed that TNF- $\alpha$  plays a critical role.<sup>24</sup> In patients with uveitis including Behcet's disease, TNF- $\alpha$  concentrations are increased in serum and aqueous humour.<sup>25</sup> Due to its critical role in inflammation, inhibition of TNF- $\alpha$  activity might be effective in the treatment of uveitis.<sup>8</sup>

Modulation of cytokines is mainly performed by applying natural inhibitors such as antibodies, receptor antagonist and soluble receptors. Another method is use of drugs that inhibit cytokine synthesis.<sup>26</sup> The PTX is a phosphodiesterase inhibitor that is also able to prevent cytokine production, because of its ability to increase cAMP levels.<sup>27</sup> This drug has been beneficially used in cerebrovascular disorders and it is proved to inhibit the production of TNF- $\alpha$ , IL-1, IL-6 and IL-8. Thus, it decreases inflammatory cytokines production by phagocytes and modulates their effects on neutrophil function.<sup>18</sup> The PTX has been identified as having many ocular effects. These include increased pulsatile ocular blood flow, increased

blood flow velocity in retinal vessels, protection against retinal ischemia/ reperfusion damage and increased choroidal perfusion in eyes with ocular hypotension.<sup>28,29</sup> Throughout the last decade, there has been much interest about using the vitreal cavity for delivery of therapeutic agents to the posterior segment of the eye. The blood-retinal barrier is bypassed and higher concentrations can be attained within the ocular tissues with little systemic exposure.<sup>30</sup> Due to inhibitory action of PTX on TNF- $\alpha$  synthesis, we evaluated clinical and histopathological effects of intravitreal injection of PTX in an experimental model of EIU. Our results revealed that PTX treatment considerably induces and exacerbates ocular inflammation. We used two different dosages of PTX to assess its effect on the severity of uveitis and evaluate whether higher dosage would have better clinical and histopathological outcomes in management of an experimental model of uveitis. According to our results, when clinical and histopathological examination scores were compared, no significant difference between different dosages of PTX was found. According to the literature, PTX was administered mostly in the systemic route for treatment of the uveitis.<sup>20,26</sup> In two studies,

improvement of anterior ocular involvement by systemic administration of PTX in control of uveitis in patients with Bechet's disease was achieved, however, De Vos *et al.* and Avunduk *et al.* have found that systemic PTX treatment has no influence on the severity of uveitis in rats.<sup>20,26</sup> One study that has evaluated intravitreal injection of PTX as a part of a study without any serial clinical and histopathological examinations for evaluation of inflammation, showed that intravitreal injection of PTX in three different doses (20 µg, 100 µg and 500 µg) in combination with LPS has aggravated the uveitis which is similar to what we observed in the current study.<sup>26</sup> To the best of our knowledge, there is no report about evaluation of clinical and histopathological effects of intravitreal injection of PTX in an experimental model of EIU in rabbits. The results of our study demonstrated that intravitreal administration of PTX does not have therapeutic effects, but inversely it induces ocular inflammation. The induction of ocular inflammation by PTX could be attributed to its effect on breakdown of blood-ocular barrier<sup>31</sup> or chemotaxis of polymorpho-nuclear leukocytes.<sup>32</sup> Other explanations such as drug-induced uveitis due to possible immunogenic effect of intra-ocular injection of PTX could be considered. Drug-induced uveitis after treatment with various TNF- $\alpha$  inhibitors has been reported previously, but their exact mechanism is not clear.<sup>33</sup> The inverse relationship between TNF- $\alpha$  and the pro-inflammatory cytokines such as interferon ( $\alpha$  and  $\gamma$ ) and changes in cytokine balance in response to TNF- $\alpha$  inhibition have been suggested to elicit immune cell activation, autoantibody formation and immune complex deposition, finally leading to the development of inflammatory effects.<sup>34,35</sup>

Although in many studies intravitreal injections of LPS and drug administrations were performed at the same time,<sup>20,26</sup> as we did, it would be more effective to inject PTX intravitreally 24 hr after LPS injection. Furthermore, equal number of participants in each group is recommended which can decrease bias on the results and conclusion. Fundoscopy was not performed, therefore there is no information about posterior segment inflammation by neither examination nor fluorescein angiography. In addition, retinal toxicity is a primary concern in case of using intravitreal drugs. Electroretinography for investigation of probable retinal toxicity of PTX on the posterior segment and fluorescein angiography for the evaluation of vasculitis as a sign of posterior segment inflammation are recommended.

In conclusion, although the result of our experiment revealed that intravitreal injection of PTX was not effective in treatment of uveitis, further preclinical and clinical studies are warranted in order to obtain a more robust conclusion about the use of systemic and intravitreal injections of PTX in management of patients with uveitis.

## Acknowledgments

We are grateful to Dr. Mahjoob Vahedi and Mr. Omid Koohi for their assistance and cooperation at the Laboratory Animal Center of Shiraz University of Medical Sciences during this study.

## Conflict of interest

The authors declare no conflict of interest.

## References

1. Siddique SS, Shah R, Suelves AM, et al. Road to remission: A comprehensive review of therapy in uveitis. *Expert Opin Investig Drugs* 2011; 20(11): 1497-1515.
2. Durrani O, Tehrani N, Marr J, et al. Degree, duration, and causes of visual loss in uveitis. *Br J Ophthalmol* 2004; 88(9): 1159-1162.
3. Franks WA, Limb GA, Stanford MR, et al. Cytokines in human intraocular inflammation. *Curr Eye Res* 1992; 11: 187-191.
4. de Boer JH, Van Haren MAC, de Vries-Knoppert W, et al. Analysis of IL-6 levels in human vitreous fluid obtained from uveitis patients, patients with proliferative intraocular disorders and eye bank eyes. *Curr Eye Res* 1992; 11: 181-186.
5. Hofman FM, Hinton DR. Tumor necrosis factor-alpha in the retina in acquired immune deficiency syndrome. *Investig Ophthalmol Vis Sci* 1992; 33(6): 1829-1835.
6. De Vos AF, Hoekzema R, Kijlstra A. Cytokines and uveitis, a review. *Curr Eye Res* 1992; 11(6): 581-597
7. Demir T, Gödekmerdan A, Balbaba M, et al. The effect of infliximab, cyclosporine A and recombinant IL-10 on vitreous cytokine levels in experimental autoimmune uveitis. *Indian J Ophthalmol* 2006; 54(4): 241-245.
8. Lindstedt EW, Baarsma GS, Kuijpers RW, et al. Anti-TNF- $\alpha$  therapy for sight threatening uveitis. *Br J Ophthalmol* 2005; 89(5): 533-536.
9. Yoshida M, Yoshimura N, Hangai M, et al. Interleukin-1 alpha, interleukin-1 beta, and tumor necrosis factor gene expression in endotoxin-induced uveitis. *Invest Ophthalmol Vis Sci* 1994; 35 (3): 1107-1113.
10. Salhiyyah K, Senanayake E, Abdel-Hadi M, et al. Pentoxifylline for intermittent claudication. *Cochrane Database Syst Rev* 2012; 18:1:CD005262. doi: 10.1002/14651858.CD005262.pub2.
11. George J, Abel PW. Pentoxifylline. In: *xPharm: The comprehensive pharmacology reference*. New York, USA: Elsevier 2011; 1-18.
12. Salyer JL, Bohnsack J, Knape WA, et al. Mechanisms of tumor necrosis factor-alpha alteration of PMN adhesion and migration. *Am J Pathol* 1990; 136(4): 831-841.

13. Bessler H, Gilgal R, Djaldetti M, et al. Effect of pentoxifylline on the phagocytic activity, cAMP levels, and superoxide anion production by monocytes and polymorphonuclear cells. *J Leukoc Biol* 1986; 40(6): 747-754.
14. Leimenstoll G, Zabel P, Schroeder P, et al. Suppression of OKT3-induced tumor necrosis factor alpha formation by pentoxifylline in renal transplant recipients. *Transplant Proc* 1993; 25(1): 561-563.
15. Fong Y, Tracey KJ, Moldawer L, et al. Antibodies to cachectin/tumor necrosis factor reduce interleukin 1 beta and interleukin 6 appearance during lethal bacteremia. *J Exp Med* 1989; 170: 1627-1633.
16. Moreira A, Sampaio EP, Zmuidzinas A, et al. Thalidomide exerts its inhibitory action on tumor necrosis factor alpha by enhancing mRNA degradation. *J Exp Med* 1993; 177: 1675-1680.
17. Neuner P, Klosner G, Schauer E, et al. Pentoxifylline *in vivo* down-regulates the release of IL-1 beta, IL-6, IL-8 and tumour necrosis factor-alpha by human peripheral blood mononuclear cells. *Immunology* 1994; 83(2): 262-267.
18. Appenzeller S, Hazel E. Pentoxifylline for the treatment of anterior uveitis in Behcet's disease: Possible alternative for TNF blockers. *Rheumatol Int* 2011; 31(11): 1511-1513.
19. Yasui K, Ohta K, Kobayashi M, et al. Successful treatment of Behçet disease with pentoxifylline. *Ann Intern Med* 1996; 124(10): 891-893.
20. Avunduk AM, Avunduk MC, Oztekin E, et al. Characterization of T lymphocyte subtypes in endotoxin-induced uveitis and effect of pentoxifylline treatment. *Curr Eye Res* 2002; 24(2): 92-98.
21. Erşanlı D, Karadayı K, Toyran S, et al. The efficacy of hyperbaric oxygen for the treatment of experimental uveitis induced in rabbits. *Ocul Immunol Inflamm* 2005; 13(5): 383-388.
22. Verma MJ, Mukaida N, Vollmer-Conna U, et al. Endotoxin-induced uveitis is partially inhibited by anti-IL-8 antibody treatment. *Invest Ophthalmol Vis Sci* 1999; 40: 2465-2470.
23. Kanai K, Ito Y, Nagai N, et al. Effects of instillation of eye drops containing disulfiram and hydroxypropyl- $\beta$ -cyclodextrin inclusion complex on endotoxin-induced uveitis in rats. *Curr Eye Res* 2012; 37: 124-131.
24. Koizumi K, Poulaki V, Doehmen S, et al. Contribution of TNF- $\alpha$  to leukocyte adhesion, vascular leakage, and apoptotic cell death in endotoxin-induced uveitis *in vivo*. *Invest Ophthalmol Vis Sci* 2003; 44(5): 2184-2191.
25. Santos Lacomba M, Marcos Martin C, Gallardo Galera J, et al. Aqueous humor and serum tumor necrosis factor- $\alpha$  in clinical uveitis. *Ophthalmic Res* 2001; 33(5): 251-255.
26. De Vos AF, Van Haren MAC, Verhagen C, et al. Systemic anti-tumor necrosis factor antibody treatment exacerbates endotoxin-induced uveitis in the rat. *Exp Eye Res* 1995; 61(6): 667-675.
27. Van Furth A, Verhard-Seijmonsbergen E, Van Furth R, et al. Effect of lisofylline and pentoxifylline on the bacterial-stimulated production of TNF- $\alpha$ , IL-1 $\beta$  and IL-10 by human leucocytes. *Immunology* 1997; 91(2): 193-196.
28. Chou PI, Chang JS, Chen JT, et al. The short-term effect of pentoxifylline on rabbit choroidal blood flow. *J Ocul Pharmacol Ther* 2000; 16(5): 455-462.
29. Schmetterer L, Kemmler D, Breiteneder H, et al. A randomized, placebo-controlled, double-blind crossover study of the effect of pentoxifylline on ocular fundus pulsations. *Am J Ophthalmol* 1996; 121(2): 169-176.
30. Yasukawa T, Ogura Y, Sakurai E, et al. Intraocular sustained drug delivery using implantable polymeric devices. *Adv Drug Deliv Rev* 2005; 57(14): 2033-2046.
31. Sen HA, Campochiaro PA. Stimulation of cyclic adenosine monophosphate accumulation causes breakdown of the blood-retinal barrier. *Invest Ophthalmol Vis Sci* 1991; 32(7): 2006-2010.
32. Krause PJ, Kristie J, Wang W, et al. Pentoxifylline enhancement of defective neutrophil function and host defense in neonatal mice. *Am J Pathol* 1987; 129(2): 217-222.
33. London NJS, Garg SJ, Moorthy RS, et al. Drug-induced uveitis. *J Ophthalmic Inflamm Infect* 2013; 3: 43. doi.org/10.1186/1869-5760-3-43.
34. Cunningham Jr ET, Pasadhika S, Suhler EB, et al. Drug-induced inflammation in patients on TNF $\alpha$  inhibitors. *Ocul Immunol Inflamm* 2012; 20(1): 2-5.
35. Viguier M, Richette P, Bachelez H, et al. Paradoxical adverse effects of anti-TNF-alpha treatment: Onset or exacerbation of cutaneous disorders. *Expert Rev Clin Immunol* 2009; 5(4): 421-431.