

## Diode laser versus scalpel in the treatment of hereditary gingival fibromatosis in a 6-year old boy

Samia Aboujaoude,<sup>1</sup>  
Antoine Cassia,<sup>2</sup> Carla Moukarzel<sup>3</sup>

<sup>1</sup>Department of Pediatric Dentistry;  
<sup>2</sup>Department of Oral Pathology and  
Diagnosis; <sup>3</sup>Department of Pediatric  
Dentistry, Lebanese University, Beirut,  
Lebanon

### Abstract

Hereditary gingival fibromatosis (HGF) is a rare disease characterized by a benign enlargement of the gingiva involving both the mandible and the maxilla. This case is about a 6-year-old child with non syndromic HGF showing a severe gingival enlargement covering almost all surfaces of the teeth, in both arches, hence causing major aesthetic, phonetic and masticatory problems. The aim of the present article is to compare the outcomes of two therapeutic approaches: i) classical surgical removal with scalpel; and ii) diode laser resection. Compared to the surgical approach, the clinical results show that the main advantages of the diode laser technique are a better visibility during the intervention, minimal post-operative discomfort combined to a better gingival recontouring.

However, the time consumption and the high cost of the laser equipment remain the main disadvantages of the systematic use of this technique.

### Introduction

Hereditary gingival fibromatosis (HGF) also known as hereditary gingival hyperplasia, idiopathic gingival fibromatosis, or hereditary gingival overgrowth is a rare disease characterized by a benign enlargement of the gingiva involving both the mandible and the maxilla.<sup>1,2</sup> It can be an isolated disease<sup>3</sup> or part of many syndromes such as Zimmerman-Laband, Murray-Puretic-Drescher, Rutherford, and Cowden.<sup>4</sup> It equally affects both genders with an incidence of 1 in 750,000.<sup>5</sup> HGF is usually transmitted through an autosomal dominant manner but autosomal recessive inheritance has also been reported.<sup>2</sup> Patients suffering from HGF present major aesthetic, phonetic and masticatory problems.<sup>2</sup> Since the enlargement takes place simultaneously with the eruption of deciduous teeth it can hinder their

exfoliation thus resulting in the delayed eruption and crowding of the underlying teeth.<sup>2</sup> The constant enlargement of the tissues can eventually lead to arch deformity and can become painful once the tissues cover the occlusal surfaces of the molars.<sup>1</sup> The affected gingiva appears as a pinkish non-hemorrhagic tissue with a firm consistency.<sup>1</sup> A multitude of treatment procedures have been described in the literature and can be summed into two main modalities: the surgical and the laser assisted resection of the hyperplastic gingiva.<sup>5,6</sup>

The purpose of the present case report is to compare the outcomes of the classical surgical removal with scalpel of gingival hyperplasia versus diode laser resection in a six-year-old patient with non-syndromic HGF.

### Case Report

A 6-year old male patient presented along with his parents to our private dental clinic complaining of swelling gums causing unfavorable aesthetic appearance as well as masticatory and speech impairment.

Intraoral examination (Figure 1) revealed severe diffuse enlargement of marginal, interdental, and attached gingiva covering almost all surfaces of the teeth in both arches. The gingival tissues were non-hemorrhagic with normal color and firm, fibrotic consistency. There was an upper anterior traumatic ulcer resulting from atypical occlusion.

Extra oral examination (Figure 2) revealed a convex profile with maxillary protrusion, incompetent lips and bushy eyebrows. Occlusal radiographs showed the presence of all anterior permanent teeth with radiolucency on the left central primary maxillary root (Figure 3).

The patient has never received any medical or surgical treatment for his condition.

There is positive family history of a younger brother affected by the same condition (Figure 4). The treatment plan was to operate under general anesthesia considering the invasive nature of the intervention and the patient's lack of cooperation. Both treatment modalities, surgical resection and laser, were planned to be used. The procedure was explained to the parents and informed consent was obtained.

A surgical resection to expose the teeth of the anterior upper and lower regions was performed: using a number 15 blade, two horizontal buccally and palatally or lingually straight incisions were made at the level of the middle third of the upper and lower gingivae, extending over the primary centrals, laterals and canines. The hypertrophied tissues were dissected using periosteal elevator and debulked.

As for the posterior regions, diode laser of 810 nm wavelength (Lasersmile®, Biolase, USA) was used at a power of 3.5 watts, in con-

Correspondence: Samia Aboujaoude, Department of Pediatric Dentistry, Faculty of Dentistry, Lebanese University. Hadath, Beirut, Lebanon. Tel.: +961.3.230353. E-mail: samofa6@hotmail.com

Key words: Diode laser; gingivectomy; gingival hyperplasia; hereditary gingival fibromatosis.

Acknowledgments: the authors would like to thank Dr. Sami Eltoun, Department of Oral Pathology and Diagnosis, Faculty of Dentistry, Lebanese University.

Conflict of interest: the authors declare no potential conflict of interest.

Received for publication: 11 September 2016.

Accepted for publication: 11 October 2016.

This work is licensed under a Creative Commons Attribution NonCommercial 4.0 License (CC BY-NC 4.0).

©Copyright S. Aboujaoude et al., 2016  
Licensee PAGEPress, Italy  
Clinics and Practice 2016; 6:895  
doi:10.4081/cp.2016.895

tinuous wave mode, with a 400- diameter fiber. The incision and shaping were performed around the cervical buccal and lingual or palatal regions of the maxillary and mandibular first and second primary molars.

The patient was discharged home the same day with a prescription of non-steroidal anti-inflammatory (Ibuprofen Profinal® Paediatric Suspension, Julphar, 5 mL Suspension; 3 times per day) and asked to rinse twice daily with chlorhexidine gluconate USP 0.12% (GUM, Paroex®, Sunstar Americas, Inc.) for three consecutive days.

Histopathology analysis of the specimen showed moderately dense collagenous connective tissue with collagen bundles arranged in a haphazard manner. Connective tissue was relatively avascular along with scanty inflammatory cell infiltrate showing dense wavy bundles of collagen fibers containing numerous fibrocytes and fibroblasts. The overlying epithelium was hyperplastic with elongated rete ridges (Figure 5). The histopathologic features were compatible with the diagnosis of idiopathic gingival fibromatosis.

At one week postoperatively, the patient showed uneventful healing with functional and aesthetic improvement (Figure 6).

### Discussion

Hereditary gingival fibromatosis is a rare condition but the most common form of gingi-

val hyperplasia. Gingival overgrowth varies from mild enlargement of isolated interdental papillae to segmental or uniform and marked enlargement affecting one or both jaws.<sup>1,7</sup>

The precise mechanism of HGF is unknown.<sup>7</sup> Several authors described this clinical enlargement as the result of the proliferation of fibroblasts and the increased production of their extracellular matrix molecules.<sup>2,3</sup> Despite its benign aspect, this condition is quite disfiguring if left untreated. The hyperplastic process affects the gingivae peripheral to the alveolar bone and spares the periodontal ligament.<sup>7</sup> The enlargement begins with the emergence of deciduous dentition and gradually increases to cover the teeth completely, delaying exfoliation of primary molars. The hypertrophied gingiva retains its normal color, texture and bleeding tendency.<sup>8,9</sup>

Hereditary gingival fibromatosis has been reported to cause severe crowding of underlying teeth, speech impairment, social isolation and difficulty in mastication.<sup>10</sup>

The optimal course of treatment for HGF is

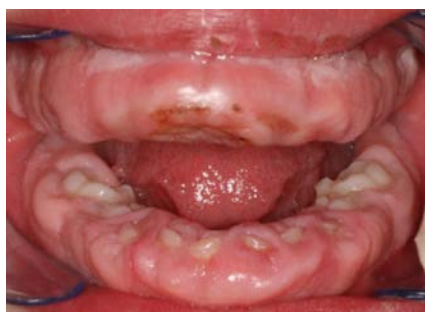

Figure 1. Intraoral view showing the severity of gingival hyperplasia in a 6-year old patient with hereditary gingival fibromatosis.

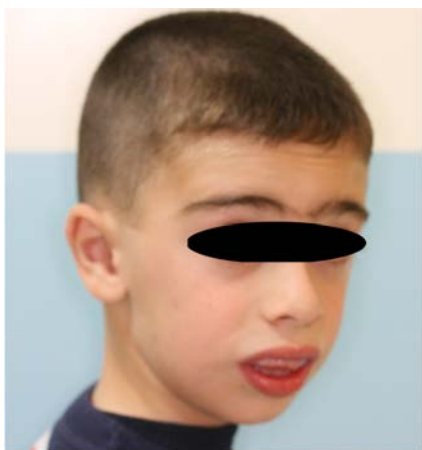

Figure 2. Extraoral view showing bushy eyebrows, maxillary protrusion and lips incompetence.

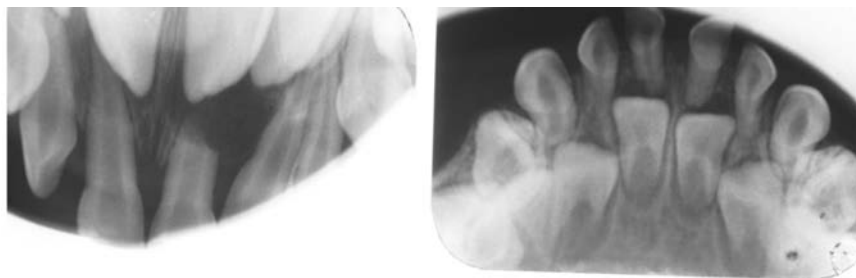


Figure 3. Occlusal radiographs showed the presence of all anterior permanent teeth with radiolucency on the left central primary maxillary root.

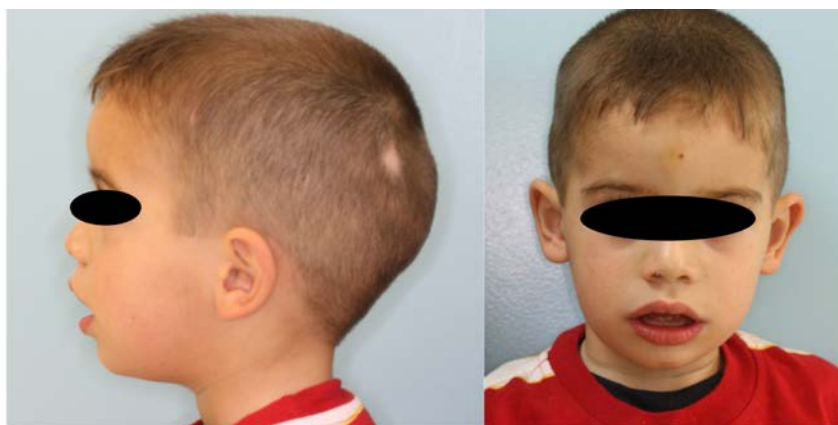

Figure 4. The patient's brother presenting similar extra-oral features.

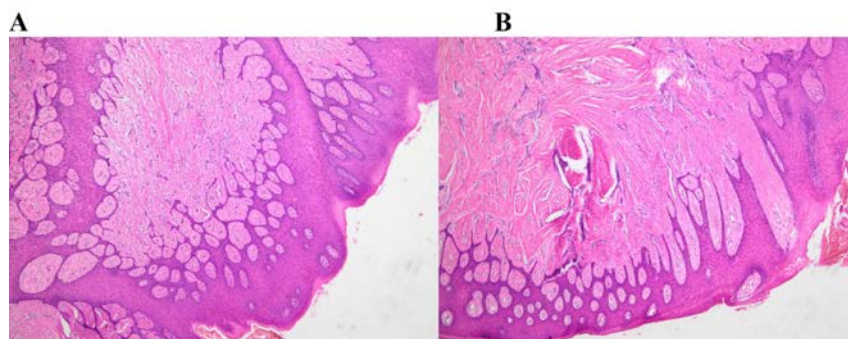


Figure 5. A, B) Histopathology analysis showing avascular connective tissue relatively along with scanty inflammatory cell infiltrate presenting wavy bundles of collagen fibers containing numerous fibrocytes and fibroblasts. The overlying epithelium is hyperplastic.

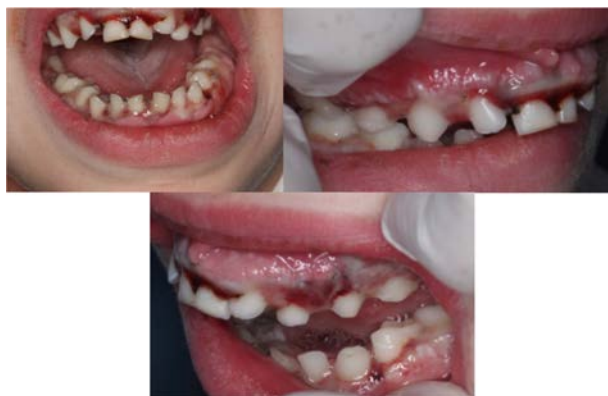

Figure 6. Buccal, left and right intra-orally views one-week post-operative.



still controversial.<sup>11,12</sup> Depending on the severity of the disease, gingivectomy, electrosurgery and laser resection have been described.<sup>6</sup> In 2006, Coletta and Graner suggested the use of CO<sub>2</sub> laser during gingivectomy for patients with HGF.<sup>13</sup> Compared to diode laser, the CO<sub>2</sub> laser has the same advantages and indication but however it has a larger console and therefore it's more difficult to transport.<sup>14</sup>

A study conducted by Jin et al. comparing the use of scalpels, Er, Cr: YSGG and diode lasers for surgery on pig oral mucosa concluded that diode laser is a worthy alternative to the two different interventions.<sup>15</sup>

Gingivectomy is one of the most conventional treatment methods for HGF treatment due to its low cost and easy access.<sup>16</sup>

In the present case, the anterior upper and lower regions gingival resections were performed with conventional surgery using scalpel. As there is, in nearly all circumstances, adequate attached gingiva, there is little fear of creating a mucogingival problem with the surgical removal technique.<sup>1</sup>

Posterior mandibular and maxillary gingival resections were achieved by diode laser, which has a wavelength of 810 nm that is absorbed by the gingival tissue with very little risk of damage to the underlying bone. The diode laser enhanced the visibility due to its hemostatic properties which facilitate the gingival recontouring and re-designing.<sup>17</sup>

The surgical technique used anteriorly was faster than laser and helped reducing the duration of the procedure, whereas the laser has the advantage of better hemostasis and hence reduced the hemorrhagic complications in the posterior region which is in close proximity to the superior palatine artery located in the maxillary tuberosity region.<sup>18</sup>

The main objective of the laser treatment is to cut, decontaminate and regenerate the soft tissue. It has been shown that a collagen secretion is initiated as early as 6 h after surgery allowing a better healing of the gum.<sup>17</sup>

As described by several authors,<sup>19,20</sup> laser technology in the present case, enabled better shaping, visibility and hemostasis during incision specially when used in the posterior palatal and lingual regions. This is in line with previous reports showing that hypertrophic soft tissues treated with laser presented minimal tissue damage, little edema and less post-operative pain compared to the surgical treated regions.<sup>17,19-21</sup> Moreover, diode laser generates superficial thermal wound reducing the inflammatory response and post-operative discomfort compared to the surgical approach.<sup>17,19,20</sup>

## Conclusions

The clinical results show that the main advantages of the diode laser technique seem to be a better visibility during the intervention, minimal post-operative discomfort combined to a better gingival recontouring. However, the time consumption and the high cost of the laser equipment remain the main disadvantages of the systematic use of this technique. Diode light equipment leads to minimal post-operative pain and adverse effects besides better aesthetic results in the HGF paediatric patients.

Therefore, future investigations with larger samples and longer follow-up are mandatory.

## References

- Jayachandran M, Kapoor S, Mahesh R. Idiopathic gingival fibromatosis rehabilitation: a case report with two-year follow up. *Case Rep Dent* 2013;2013:513513.
- Mohan R, Verma S, Argarwal N, Singh U. Non-syndromic hereditary gingival fibromatosis. *BMJ Case Rep* 2013;2013:bcr2012008542.
- Zhou M, Xu L, Meng H. Diagnosis and treatment of hereditary gingival fibromatosis case. *Chin J Dent Res* 2011;14:155-8.
- Tripathi A, Dete G, Saimbi C, Kumar V. Management of hereditary gingival fibromatosis: a 2 years follow-up case report. *J Indian Soc Periodontol* 2015;19:342-4.
- Odessey E, Cohn A, Casper F, Schechter L. Hereditary gingival fibromatosis: aggressive 2-stage surgical resection in lieu of traditional therapy. *Ann Plast Surg* 2006;57:557-60.
- Livada R, Shiloah J. Gummy smile: could it be genetic: hereditary gingival fibromatosis. *J Tenn Dent Assoc* 2012;92:23-6.
- Tiwana PS, De Kok IJ, Stoker DS, Cooper LF. Facial distortion secondary to idiopathic gingival hyperplasia: surgical management and oral reconstruction with endosseous implants. *Oral Surg Oral Med Oral Pathol Oral Radiol Endod* 2005;100:153-7.
- Arabi SR, Ebrahimzad Z, Mahdi K, Jourdehi SA. Hereditary gingival fibromatosis: a case report. *Res J Biol Sci* 2011;6:104-7.
- Babu KB, Pavankumar K, Anuradha BR,

Arora N. Hereditary gingival fibromatosis—a case report and management using a novel surgical technique. *Rev Sul Bras Odontol* 2011;8:453-8.

- Ramakrishnan T, Kaur M. Multispeciality approach in the management of patient with hereditary gingival fibromatosis: 1-year followup: a case report. *Int J Dentistry* 2010;2010:575979.
- Ramnarayan BK, Sowmya K, Rma J. Management of idiopathic gingival fibromatosis: report of a case and literature review. *Pediatr Dent* 2011;33:431-6.
- Reenesh MM, Rath CSK, Mukherjee LCM. Different surgical management modalities for a case of idiopathic generalized gingival enlargement with chronic periodontitis. *J Oral Maxillofac Surg Med Pathol* 2012;24:1-4.
- Coletta RD, Graner E. Hereditary gingival fibromatosis: a systematic review. *J Periodontol* 2006;77:753-64.
- Akbulut N, Kursen E, Tumer M, et al. Is the 810-nm diode laser the best choice in oral soft tissue therapy? *Eur J Dent* 2013;7:207-13.
- Jin JY, Lee SH, Yoon HJ. A comparative study of wound healing following incision with a scalpel, diode laser or Er, Cr: YSGG laser in guinea pig oral mucosa: a histological and immunohistochemical analysis. *Acta Odontol Scand* 2010;68:232-8.
- Camilotti RS, Jasper J, Ferreira TB, et al. Resection of gingival fibromatosis with high-power laser. *J Dent Child (Chic)* 2015;82:47-52.
- Namour S. Atlas of current oral laser surgery. Boca Raton, FL: Universal-Publishers; 2011. p 149.
- Kanagotagi S, Sidana S, Rajguru S, Padhye A. Gingival fibromatosis with distinctive facies—a three generation case report. *J Clin Diagn Res* 2015;9:05-7.
- Gontiya G, Bhatnagar S, Mohandas U, Galgali SR. Laser assisted gingivectomy in pediatric patients: a novel alternative treatment. *J Indian Soc Pedod Prev Dent* 2011;29:264-9.
- Beer F, Körpert W, Passow H, et al. Reduction of collateral thermal impact of diode laser irradiation on soft tissue due to modified application parameters. *Lasers Med Sci* 2012;27:917-21.
- Jasper J, Ferreira TB, Poli VD, Pagnoncelli RM. Resection of gingival fibromatosis with high power laser. *J Dent Child* 2015;82:47-52.