


# Neratinib-Induced Duodenal Ulcer: A Case Report

Bahar Moftakhar<sup>1</sup> , Prakash Kharel<sup>2</sup>, Sujan Niraula<sup>3</sup>, Shipra Gandhi<sup>4</sup>, Carla Falkson<sup>1</sup> and Ajay Dhakal<sup>1</sup>

<sup>1</sup>Wilmot Cancer Institute, University of Rochester, Rochester, NY, USA. <sup>2</sup>Geisinger Medical Center, Danville, PA, USA. <sup>3</sup>Institute of Applied Health Sciences (IAHS), Chittagong, Bangladesh.

<sup>4</sup>Roswell Park Comprehensive Cancer Center, Buffalo, NY, USA.

Breast Cancer: Basic and Clinical Research

Volume 14: 1–3

© The Author(s) 2020

Article reuse guidelines:

sagepub.com/journals-permissions

DOI: 10.1177/1178223420935871



**ABSTRACT:** We report a case of a 37-year-old woman who developed a duodenal ulcer while receiving adjuvant neratinib for HER2 positive breast cancer. The clinical course of abdominal pain was strongly correlated with the use of neratinib. An esophagogastroduodenoscopy (EGD) was performed and confirmed the diagnosis of a large duodenal ulcer. Neratinib was stopped, and the patient was treated with a proton pump inhibitor. Repeat EGD performed 3 months later showed complete resolution of the duodenal ulcer. Given this unexpected serious adverse event and only modest benefit of neratinib in the adjuvant setting, the decision was made to forgo further treatment with neratinib. Physicians should be aware of the gastrointestinal (GI) side effects associated with neratinib and recognize that peptic ulcer disease may be another GI toxicity associated with neratinib use.

**KEYWORDS:** Neratinib, toxicity, adjuvant, HER2, ulcer

**RECEIVED:** May 21, 2020. **ACCEPTED:** May 27, 2020.

**TYPE:** Case Report

**FUNDING:** The author(s) received no financial support for the research, authorship, and/or publication of this article.

**DECLARATION OF CONFLICTING INTERESTS:** The author(s) declared the following potential conflicts of interest with respect to the research, authorship, and/or publication of

this article: Moftakhar: No COI. Kharel: No COI. Niraula: No COI. Gandhi: Roswell Park Alliance Foundation. Falkson: Have received research funding from Roche, Genentech, Novartis, Seattle Genetics, Pfizer, and Lilly at her prior institution. Dhakal: Have received an honorarium from Daichii Sankyo.

**CORRESPONDING AUTHOR:** Bahar Moftakhar, Wilmot Cancer Institute, University of Rochester, 601 Elmwood Avenue, BOX 704 Rochester, NY 14642, USA. Email: bmoftakhar@urmc.rochester.edu

## Introduction

Neratinib (Nerlynx®) is an oral irreversible tyrosine kinase inhibitor of human epidermal growth factor receptor (HER) 1, 2, and 4 as well as epidermal growth factor receptor (EGFR) that is effective in the treatment of HER2 positive breast cancer.<sup>1</sup> Based on data from the phase III, double-blinded, placebo-controlled, randomized, multicenter trial (ExteNET), the U.S. Food and Drug Administration (FDA) has approved neratinib for the extended adjuvant treatment of patients with early-stage HER2 positive breast cancer following the completion of trastuzumab-based therapy.<sup>2</sup>

Though significant gastrointestinal (GI) side effects are reported with neratinib use, none of the neratinib trials have reported any cases of upper GI ulcers. Similarly, since the first approval of neratinib for the management of early-stage HER2 positive breast cancer, there have been no case reports of peptic ulcers with the use of neratinib. We report a case of severe abdominal pain due to duodenal ulcer associated with neratinib use.

## Case Report

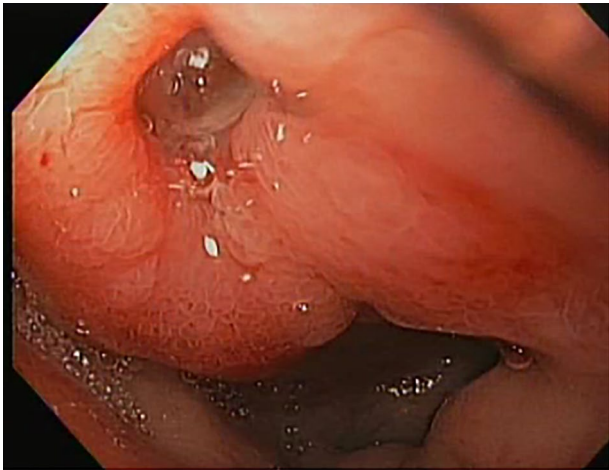
A 37-year-old woman with no past medical history was diagnosed with a left-sided breast cancer in July 2018. Her family history was significant for breast cancers in her mother and maternal aunt. After she self-palpated a left-sided breast mass, diagnostic mammogram and breast ultrasound confirmed a 2.5 cm left breast mass without axillary node involvement. A core needle biopsy diagnosed a grade 1 invasive ductal carcinoma, estrogen receptor (ER), progesterone receptor (PR), and HER2 positive. Sentinel lymph node biopsy demonstrated cancer involvement in 2 out of 3 lymph nodes. Genetic testing identified a variant of uncertain significance in the CHEK2 gene.

The patient completed six cycles of neo-adjuvant chemotherapy regimen – docetaxel, carboplatin, trastuzumab, and pertuzumab. She underwent a bilateral mastectomy with left axillary lymph node dissection and was found to have residual invasive ductal carcinoma in the left breast. The residual cancer burden score could not be accurately calculated. Final pathological staging was ypT2, N1a, M0. She was started on anti-estrogen therapy and completed 1 year of adjuvant trastuzumab and pertuzumab. One month after completion of trastuzumab and pertuzumab, she was started on extended adjuvant therapy with neratinib 240 mg daily.

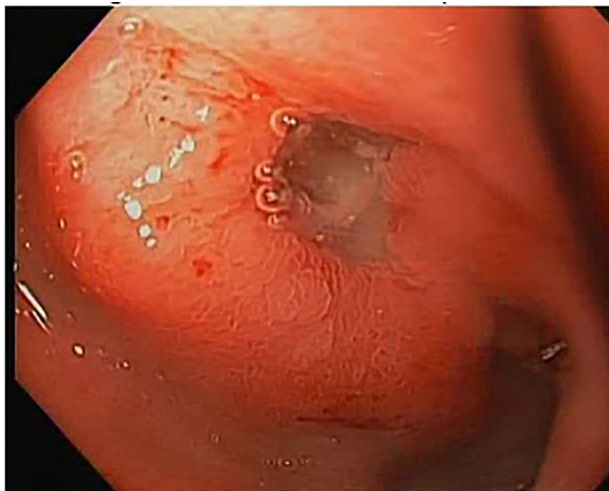
Within 2 weeks of starting neratinib, the patient developed grade 3 mucositis in the form of oral ulcers. Neratinib was held, and while the oral ulcers began to improve, the patient developed abdominal pain and nausea. Her symptoms were associated with bloating and epigastric pain radiating to the back. There was no fever or diarrhea. It was recommended that the patient continue to hold neratinib, and a trial of proton pump inhibitor (PPI) for a few days was recommended. The patient's symptoms improved within a few days of starting PPI, and neratinib was restarted at a reduced dose of 200 mg daily.

Eight days later, the patient presented to the emergency department with severe epigastric pain, similar to the previous episode. Labs, including complete blood count, liver function tests, amylase, and lipase were unremarkable. However, computed tomography (CT) scan of the abdomen showed soft tissue thickening along the uncinate process/pancreatic head and proximal duodenum concerning for groove pancreatitis or duodenitis. She underwent an esophagogastroduodenoscopy (EGD) and was found to have a large cratered clean based ulcer at the 12 o'clock position in the distal duodenal bulb with surrounding edema and





**Figure 1.** The distal duodenal bulb at the 12:00 position.



**Figure 2.** Anterior wall at the 8:00 position.

inflammation of the mucosa (Figure 1). Another small erosion was seen in the duodenal bulb along the anterior wall at the 8 o'clock position with patchy white exudate in the duodenal sweep and the second part of the duodenum (Figure 2). Biopsy of the duodenal ulcer showed gastric surface metaplasia and active inflammation with no evidence of malignancy or helicobacter pylori infection. Additional biopsies of duodenal and gastric mucosa showed no histologic abnormalities.

The patient was started on pantoprazole twice a day. Neratinib was not resumed in the interim. Three months later, the patient underwent repeat EGD. The procedure showed a normal exam and complete healing of the prior ulcers. After having a risk and benefit discussion of neratinib with the patient, the decision was made to forgo further treatment with neratinib.

## Discussion

Neratinib received approval for the treatment of early-stage HER2 positive breast cancer based on improved 5-year disease-free survival seen in the ExteNET trial.<sup>2,3</sup> While there is no overall survival data to date, neratinib is often offered to

patients with high-risk HER2 positive breast cancer as extended adjuvant treatment.

The toxicities associated with neratinib have been well established and consistent across several large trials.<sup>4</sup> In the ExteNET trial, the most commonly reported grades 3 to 4 adverse event was diarrhea at a rate of 40%.<sup>2</sup> Diarrhea was worse in the first month of therapy; however, by 12 months, 12% of patients continued to have grade 2 diarrhea. Other reported adverse events associated with neratinib are nausea, fatigue, vomiting, upper abdominal pain, stomatitis, mucous inflammation, headache, rash, decreased appetite, muscle spasms, dizziness, and arthralgia. Less common GI adverse events are abdominal hernia, cholecystitis, cholelithiasis.<sup>2,5</sup> Several trials have reported dyspepsia as another adverse event without characterizing it further.<sup>6-8</sup>

In our extensive literature review, which included a review of two available systematic reviews and meta-analyses, there was no reported case of GI ulcers associated with neratinib use, though there are extensive reports of abdominal pain, epigastric pain, and dyspepsia.<sup>9,10</sup> This is the first case of peptic ulcer associated with neratinib use. Based on the WHO-UMC criteria or the Naranjo algorithm, which are the two most widely used criteria for causality assessments of adverse drug reactions (ADR), this case of peptic ulcer is categorized as “probable” ADR of neratinib.<sup>11,12</sup> This patient did not have a history of peptic ulcer disease and was not on any other medications like non-steroidal anti-inflammatory drugs (NSAIDs) or steroids that could cause peptic ulcers. Her abdominal pain improved with holding neratinib, and starting PPI, however, worsened again after restarting neratinib. The temporal relationship provides strong evidence to attribute the duodenal ulcer to resuming neratinib. To our knowledge, neither trastuzumab nor pertuzumab have been reported to have such toxicities. While the “washout” period for trastuzumab can be up to 7 months, it is unlikely that this case represents a drug–drug interaction or delayed reaction of trastuzumab and pertuzumab maintenance therapy.<sup>13</sup>

The mechanism of peptic ulcer disease associated with neratinib is unclear and there is scarce pharmacogenomic data for neratinib that would suggest a drug–gene or drug–gene–drug interaction. Neratinib is known to cause mucous inflammation and stomatitis, and in one study, over 50% of patients had grades 1 to 2 stomatitis, and 32% had grades 1 to 2 mucous inflammation.<sup>14</sup> A similar mechanism might have contributed to the formation of peptic ulcer in this case. Pharmacokinetic data show that neratinib is better absorbed in an acidic environment, and co-administration of PPIs should be avoided to create an acidic environment.<sup>15</sup> However, this may, at the same time, increase the risk of peptic ulcer disease. Patients with peptic ulcer disease on neratinib will need PPI treatment, which may compromise the efficacy of neratinib by decreasing absorption. This creates a pharmacokinetic challenge for the continuation of neratinib. More information is needed to help guide the management of patients who have or are at risk for

developing GI ulcers and associated complications while on neratinib therapy.

### Conclusion

This is the first reported case of a duodenal ulcer associated with the use of neratinib. There are well-recognized GI toxicities, specifically diarrhea, associated with the use of neratinib. This case draws attention to another unanticipated adverse event, that if ignored, could have life-threatening consequences.

### Author Contributions

All persons who meet authorship criteria are listed as authors, and all authors certify that they have participated sufficiently in the work to take responsibility for the content, including participation in the concept, research, writing or revision of the manuscript.

### Informed Consent

This patient has provided consent for the reporting of this case.

### ORCID iD

Bahar Moftakhar  <https://orcid.org/0000-0003-0860-0441>

### REFERENCES

1. Wong KK, Fracasso PM, Bukowski RM, et al. A phase I study with neratinib (HKI-272), an irreversible pan ErbB receptor tyrosine kinase inhibitor, in patients with solid tumors. *Clin Cancer Res.* 2009;15:2552-2558.
2. Martin M, Holmes FA, Ejlertsen B, et al. Neratinib after trastuzumab-based adjuvant therapy in HER2-positive breast cancer (ExteNET): 5-year analysis of a randomised, double-blind, placebo-controlled, phase 3 trial. *Lancet Oncol.* 2017;18:1688-1700.
3. Chan A, Delaloge S, Holmes FA, et al. Neratinib after trastuzumab-based adjuvant therapy in patients with HER2-positive breast cancer (ExteNET): a multicentre, randomised, double-blind, placebo-controlled, phase 3 trial. *Lancet Oncol.* 2016;17:367-377.
4. Burstein HJ, Sun Y, Dirix LY, et al. Neratinib, an irreversible ErbB receptor tyrosine kinase inhibitor, in patients with advanced ErbB2-positive breast cancer. *J Clin Oncol.* 2010;28:1301-1307.
5. Park JW, Liu MC, Yee D, et al. Adaptive randomization of neratinib in early breast cancer. *N Engl J Med.* 2016;375:11-22.
6. Awada A, Colomer R, Inoue K, et al. Neratinib plus paclitaxel vs trastuzumab plus paclitaxel in previously untreated metastatic ERBB2-positive breast cancer: the NEfERT-T randomized clinical trial. *JAMA Oncology.* 2016;2:1557-1564.
7. Freedman RA, Gelman RS, Anders CK, et al. TBCRC 022: a phase II trial of neratinib and capecitabine for patients with human epidermal growth factor receptor 2-positive breast cancer and brain metastases. *J Clin Oncol.* 2019;37:1081-1089.
8. Ma CX, Bose R, Gao F, et al. Neratinib efficacy and circulating tumor DNA detection of HER2 mutations in HER2 nonamplified metastatic breast cancer. *Clin Cancer Res.* 2017;23:5687-5695.
9. Tao Z, Li SX, Shen K, Zhao Y, Zeng H, Ma X. Safety and efficacy profile of neratinib: a systematic review and meta-analysis of 23 prospective clinical trials. *Clin Drug Investig.* 2019;39:27-43.
10. Jiang N, Song XW, Lin JJ, et al. Risk of gastrointestinal complications in breast cancer patients treated with neratinib: a meta-analysis. *Expert Opin Drug Saf.* 2017;16:1111-1119.
11. Naranjo CA, Busto U, Sellers EM, et al. A method for estimating the probability of adverse drug reactions. *Clin Pharmacol Ther.* 1981;30:239-245.
12. The use of the WHO-UMC system for standardized case causality assessment. World Health Organization (WHO) - Uppsala Monitoring Centre. [https://www.who.int/medicines/areas/quality\\_safety/safety\\_efficacy/WHOcausality\\_assessment.pdf](https://www.who.int/medicines/areas/quality_safety/safety_efficacy/WHOcausality_assessment.pdf). Accessed May 17, 2020.
13. Quartino AL, Li H, Kirschbrown WP, et al. Population pharmacokinetic and covariate analyses of intravenous trastuzumab (Herceptin((R))), a HER2-targeted monoclonal antibody, in patients with a variety of solid tumors. *Cancer Chemother Pharmacol.* 2019;83:329-340.
14. Gandhi L, Bahleda R, Tolaney SM, et al. Phase I study of neratinib in combination with temsirolimus in patients with human epidermal growth factor receptor 2-dependent and other solid tumors. *J Clin Oncol.* 2014;32:68-75.
15. Keyvanjah K, DiPrimeo D, Li A, Obaidi M, Swearingen D, Wong A. Pharmacokinetics of neratinib during coadministration with lansoprazole in healthy subjects. *Br J Clin Pharmacol.* 2017;83:554-561.