

Recurrence Rate and Clinical Outcome of Amniotic Membrane Transplantation Combined with Mitomycin C in Pterygium Surgery: Two-Year Follow-Up

Hasan Razmjoo¹, Seyed-Abolfazl Kashfi¹, Majid Mirmohammadkhani^{2,3}, Mohsen Pourazizi¹

¹Department of Ophthalmology, Isfahan Eye Research Center, Isfahan University of Medical Sciences, Isfahan, Iran

²Social Determinants of Health Research Center, Semnan University of Medical Sciences, Semnan, Iran

³Department of Epidemiology and Biostatistics, Semnan University of Medical Sciences, Semnan, Iran

Received: 03-07-2019.
Accepted: 17-11-2019.
Published: 28-03-2020.

ABSTRACT

Objective: To evaluate the recurrence rate and outcome of pterygium surgery with amniotic membrane transplantation (AMT) and intraoperative mitomycin C (MMC). **Methods:** This prospective clinical study included patients with pterygium who were candidates for pterygium excision. After the surgical excision, intraoperative local MMC were applied in the standard protocol followed by AMT. The outcome measures were recurrence and the size change of lesion. Kaplan-Meier estimation and regression analyses were performed. **Findings:** Fifty five eyes of 55 consecutive patients including 30 male (54.5%) and 25 female (45.5%) with mean age of 47.12 ± 15.95 years were operated. The mean follow-up period was 15.21 ± 2.67 months. The overall recurrence rate was 34.5% (19/55 cases). The estimated recurrence time for larger size of pterygium before surgery was short and marginally significant (17.14 ± 0.58 month in size of ≤ 3.0 mm versus 18.56 ± 0.60 month in size of < 3 mm; $P = 0.06$). A statistically significant association was found in reduced model among the size change of the pterygium and standardized coefficient was -0.012 ($P = 0.044$) and -0.743 ($P < 0.001$) for age and size of lesion before surgery, respectively. **Conclusion:** Our findings suggest that increasing age and pterygial tissue are the risk factors for recurrence and pterygium has a substantial recurrence rate even after AMT combined with MMC.

KEYWORDS: Amniotic membrane transplantation, Mitomycin, pterygium, recurrence risk

INTRODUCTION

Pterygium is a common ocular disease characterized by triangular-shaped conjunctival overgrowth extended to cornea.^[1,2] The standard treatment of pterygium is surgical excision that is usually associated with high recurrence rates.^[2-6] Recurrence rate can be up to 89% and its severity may vary based on different approaches and preoperative characteristics.^[2,6]

To resolve the high recurrence rate of bare sclera with simply excision, various surgical procedures have been proposed, including conjunctival auto-grafting, conjunctival-limbal auto-grafting and amniotic membrane transplantation (AMT).^[7-12] Furthermore, intraoperative application of mitomycin C (MMC), an

antibiotic-antineoplastic agent which selectively inhibits the synthesis of DNA and cellular RNA have been successfully used to prevent the recurrence.^[9]

Considered at times as a serious posttreatment complication,^[5,6] the recurrence of pterygium is characterized by the presence of extensive scarring from the previous surgical procedure, excessive fibrovascular growth, and corneal thinning.^[13] Patients with recurrent pterygium often develop blurred vision due to the astigmatism that can cause long-term morbidity,

Address for correspondence:

Dr. Seyed-Abolfazl Kashfi, E-mail: drkashfi@gmail.com

This is an open access journal, and articles are distributed under the terms of the Creative Commons Attribution-NonCommercial-ShareAlike 4.0 License, which allows others to remix, tweak, and build upon the work non-commercially, as long as appropriate credit is given and the new creations are licensed under the identical terms.

For reprints contact: reprints@medknow.com

How to cite this article: Razmjoo H, Kashfi SA, Mirmohammadkhani M, Pourazizi M. Recurrence rate and clinical outcome of amniotic membrane transplantation combined with mitomycin C in pterygium surgery: Two-year follow-up. J Res Pharm Pract 2020;9:10-5.

Access this article online	
<p>Quick Response Code:</p> 	<p>Website: www.jrpp.net</p>
	<p>DOI: 10.4103/jrpp.JRPP_19_127</p>

disability, and decreased quality of life.^[14] The cause of recurrent pterygium is usually multifactorial, and encompasses patient-related factors (e.g., preoperative anatomic predisposition, medical comorbidities), and surgical factors (e.g., choice of the appropriate approach). For a successful outcome, this cause must be ascertained preoperatively.^[15,16]

Although it seems that recurrence rates with combination procedures had lower than single procedure, each procedure has its limitations and preoperative clinicoepidemiologic characteristics. Amniotic membrane (AM) functions as a new healthy substrate suitable for proper epithelization which has a strong anti-adhesive effect and is normally avascular.^[17] Furthermore, the use of MMC during surgical excision of pterygium can be effective for the prevention of regrowth of fibrovascular tissue.^[18]

The purpose of the present prospective study is to determine the outcomes of pterygium surgery with adjunctive AMT combined with MMC in terms of recurrence of the lesion and clinical outcome.

METHODS

This study was a prospective single clinical study recruited from Feiz ophthalmology referral hospital affiliated with Isfahan University of Medical Sciences (IUMS). The study was in line with the Declaration of Helsinki and its serial revisions. The study protocol was approved by the Institutional Review Board of IUMS. After a complete description of the intervention and the purpose of the study, a written informed consent was acquired from each patient.

In this study, we included the above 18-year-old healthy patients with the diagnosis of primary and recurrent pterygium who applied for surgical excision and also excluded those with poor medical conditions, dry eye syndrome, wound healing problems collagen vascular diseases, pregnancy, breast feeding, monocularly, intra ocular pressure (IOP) more than 21 mmHg, significant ocular surface disease, previous ocular surgery, current use of anticoagulation and immunosuppressive medications, history of allergy or intolerance of glucocorticosteroid, use of any topical or systemic medication or supplement.

The following withdrawal criteria were also applied: Not showing up for follow-up visits, receiving other medications agents during the study.

Before the study begins, some ophthalmological examination was conducted including assessment of visual acuity, slit-lamp microscopic examination, and IOP measurement. IOP was measured using a slit-lamp-mounted Goldman applanation tonometer.

The surgical intervention included three steps: Pterygium excision, MMC administration, and AMT. All surgical procedures were performed by the same surgeon.

Under sterile conditions, after topical anesthesia, injection of 2% lidocaine hydrochloride was performed into the body of the pterygium. The head of was separated and removed from the cornea by blunt dissection. The residual tissue over the corneal defect area was shaved with toothed forceps. Subconjunctival fibrous tissue under the pterygium was removed as much as possible avoiding damage to the underlying muscle sheath.

After pterygium excision, 0.2 mg/mL of MMC solution was applied topically using micro sponge soaked with MMC underneath the conjunctiva over the muscle tendon insertion for 2 min; then, the MMC was washed copiously with 30 mL of balanced salt solution.

After rinsing the preserved biological AM in physiological saline for 15 min, it was severed into an appropriate size with scissors and placed over the rectangular area of bare sclera. The free edge of the AM was sutured through the episcleral tissue to the edge of conjunctiva along the bare sclera border with 10-0 nylon sutures interrupted and was tightly pressed centrally to securely attach it to the bare sclera.

Postoperatively, patients were given prednisolone 1% eye drops combined with an antibiotic eye drops.

The topical corticosteroid and topical antimicrobial agents were used in fulfillment of the following protocol: Chloramphenicol and betamethasone eye drops were administered 4 times daily and if there was excessive irritation from the stitches, lubricants were also prescribed. Notably, ocular patch was removed after 48 h of the surgery, and sutures were removed after 1 week. Medication adherence was controlled by a weekly comparison of eye drop content.

The patients were followed-up at day's 1, 7, 14, and then at 3-month interval for 2 years.

The primary outcome of this study was the recurrence rate of pterygium after surgery which was defined as the regrowth of the fibrovascular proliferation tissue more than 1 mm from their origins using slit lamp (width of the lesion in millimeters). The secondary outcome measure was changing in the pterygium size. Other complications were also recorded such as pyogenic granuloma, inclusion cyst, corneal and scleral thinning, scleral melting, etc.

Considering the time to recurrence of pterygium as the main dependent variable, and regarding the sex, age, and ophthalmological characteristics of lesion as the explanatory variables, Kaplan–Meier estimates and plots

were performed to analyze and demonstrate the survival functions, and were compared using log-rank tests. A backward reduced multiple regression model also was applied to evaluate the relationship between the change of size of the lesion (as another dependent variable) and each of abovementioned explanatory variables. Incidence rates (IRs) and their 95% confidence intervals (CIs) were estimated for the recurrence of pterygium for all patients as well as subgroups defined by the explanatory variables. Rate Ratios (RRs) were reported to evaluate the association between each basic characteristics and recurrence. Survival and regression analyses were performed using SPSS 22 (IBM Corporation, New York, USA) and Stata (StataCorp.: Release 11.2. College Station, Texas 77845 USA) software was used to estimate IRs and RRs. A two-tailed $P < 0.05$ was considered as statistically significant.

RESULTS

This study included 55 operations on 55 patients with pterygium. Altogether 30 men (Aged 21–80 years; mean 48.06 ± 17.80) and 25 women (aged 27–75; mean 46.00 ± 13.66) were investigated. Table 1 depicts the patients' demographics and clinical characteristics [Table 1].

The mean follow-up period was 15.21 ± 2.67 months (range, 12–24 months). The overall recurrence rate was 34.5% (19/55 cases). The Kaplan–Meier survival analysis computed the estimated time to recurrence as 17.85 ± 0.42 months for the whole population (95% CI 17.02–18.69 months). Table 2 and Figure 1 display the estimated time to recurrence and the Kaplan–Meier survival curves for sex, age, pterygium type and size of pterygium before surgery [Table 2 and Figure 1]. The estimated time to recurrence for larger size of pterygium before surgery was shorter and marginally significant (17.14 ± 0.58 month in size of ≤ 3.0 mm versus. 18.56 ± 0.60 month in size of < 3 mm; $P = 0.06$) [Table 2].

Table 1: Preoperative clinical characteristics of the investigated patients

Variables	Mean \pm SD/N (%)
Age	
Mean \pm SD	47.12 \pm 15.95
Median (minimum-maximum)	47 (21-80)
Sex, n (%)	
Male	30 (54.5)
Female	25 (45.5)
Type of lesion, n (%)	
Primary	40 (72.7)
Recurrent	15 (27.3)

SD=Standard deviation

Fifty case (90.9%) had reduction in size of pterygium in follow-up period. Four case (7.3%) had no change in size and only one case had larger size of pterygium surgery in follow-up.

Using regression analysis among the change of size of the pterygium, we found a statistically significant association in the reduced model between change of size with age ($P = 0.044$) and size of lesion before surgery ($P < 0.001$). The standardized coefficient was -0.012 and -0.743 for age and size of lesion before surgery, respectively. The regression analysis equation was:

Change of size = (-0.01) (Age) + (-0.74) (Size of lesion before surgery) + 0.44.

The results of the primary full model and final reduced model of regression analysis are summarized in Table 3. An increase in 1 year of age was associated independently with a decrease in 0.01 mm in change of size after surgery; while an increase in 1 mm of size of pterygium before surgery was associated independently with a decrease in 0.74 mm in change of size after surgery.

Table 4 shows the IRs and RRs for recurrence of pterygium by each variables. RR for recurrence of pterygium according to sex ($P = 0.90$), age ($P = 0.90$), type of lesion ($P = 0.87$) and size of lesion before surgery ($P = 0.92$) were insignificant [Table 4].

DISCUSSION

The result of our study showed that the overall recurrence rate was 34.5% and the estimated time to the recurrence for larger size of pterygium before surgery was shorter. Furthermore, the increasing age and pterygial tissue are risk factors for recurrence.

The treatment of pterygium is a challenging condition due to possible recurrence after the single and combination therapy. Moreover, recurrent pterygium surgery is usually accompanied by more scar formation and related complications.^[2]

The reported recurrence rates with AMT vary between 3.8% and 40.9%.^[15,19] The recurrence rate of pterygium in our study was 34.5% in 2 years' follow-up. These differences may depend on the variable technical, surgical procedure and different duration of follow-up.^[20] The recurrence of pterygium after MMC usually occurred in about 12 months;^[21] but, in our study, the time of recurrences was longer. New research should focus on time of recurrence of pterygium by a long-term follow-up.

We showed there is direct relationship between age and the change of size after surgery. In other words, younger

Table 2: Estimated time to recurrence for sex, age, pterygium type, and size of pterygium before surgery

Variables	Estimated time to recurrence (months), mean±SE	95% CI (months)	P
Sex			
Male	17.59±0.62	16.36-18.82	0.60
Female	18.17±0.60	19.98-19.35	
Age (years)			
<50	18.30±0.46	17.39-19.21	0.24
≥50	16.95±0.82	15.33-18.58	
Type of lesion			
Primary	17.88±0.51	16.86-18.90	0.64
Recurrent	17.83±0.85	16.25-19.41	
Size of lesion before surgery (mm)			
<3	18.56±0.60	17.36-19.75	0.06
≥3.0	17.14±0.58	16.00-18.27	

CI=Confidence interval, SE=Standard error

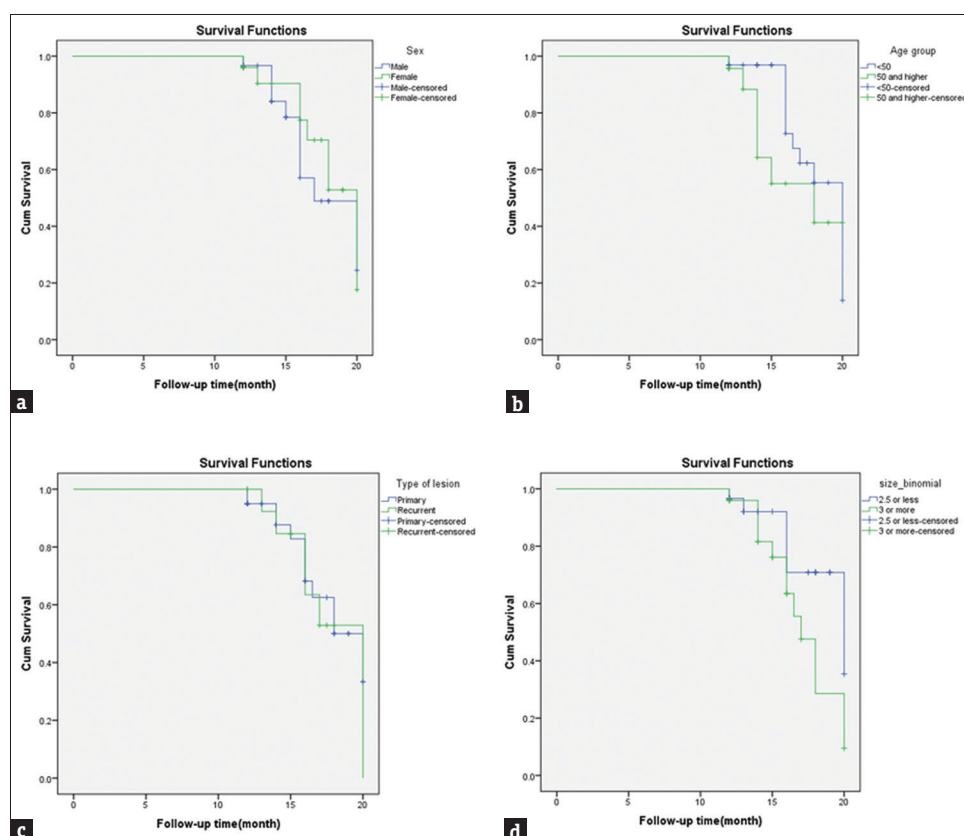


Figure 1: Kaplan–Meier curves for risk factors associated with the pterygium recurrence: (a) sex ($P = 0.60$; log-rank, Mantel–Cox), (b) age ($P = 0.24$; log-rank, Mantel–Cox), (c) primary vs. recurrent type of pterygium ($P = 0.64$; log-rank, Mantel–Cox) and (d) Size of lesion before surgery ($P = 0.06$; log-rank, Mantel–Cox)

subjects had a better response following use of AMT combined with MMC. In line with prior studies, although younger age may be implicated in pterygium growth, many of lesions did not recur.^[1,22] Those pterygiums were likely to have less fibrovascular tissue. Other studies showed that patients aged below 45 years were almost 3.5 times more likely to experience a recurrence. It seems that the wound healing process may be affected by the patient's age, though the exact mechanism is not clear.^[23,24]

We indicated that increasing in preoperative size of pterygium was associated with a decrease in change of size after surgery. That is to say, smaller lesions had a better response possible due to more complete removal of pterygium tissue. There is controversy in the literature about whether larger, or smaller pterygiums are more prone to recurrence after surgery.

In a study on 135 patients with primary pterygium, Bahar *et al.* asserted that larger pterygium contributed

Table 3: Results of regression analyses to evaluate the relationship between the change of size of the lesion and each of its predictors of interest

Model	Primary full model ^a				Final reduced model ^b			
	Coefficients		<i>t</i>	<i>P</i>	Coefficients		<i>t</i>	<i>P</i>
	<i>B</i>	SE			<i>B</i>	SE		
Constant	0.074	0.840	0.088	0.930	0.448	0.327	1.369	0.177
Age	-0.011	0.007	-1.653	0.105	-0.012	0.006	-2.065	0.044
Sex	0.063	0.195	0.323	0.748	-	-	-	-
Type of lesion	0.074	0.222	0.336	0.738	-	-	-	-
Follow-up time (month)	0.011	0.040	0.266	0.791	-	-	-	-
Size of lesion before surgery	-0.755	0.096	-7.875	<0.001	-0.743	0.090	-8.266	<0.001

^aEntered predictors: (Constant), size of lesion before surgery, sex, follow-up time (month), type of lesion, age, ^bRemained predictors after backward reduction: (Constant), size of lesion before surgery, age. SE=Standard error

Table 4: Incidence rates and rate ratios for recurrence by each variables of interest

Variables	Incidence rate (95% CI) (per month)	Rate ratio (95% CI)	<i>P</i>
Sex			
Male	0.066 (0.046-0.095)	0.96 (0.54-1.70)	0.907
Female*	0.064 (0.043-0.095)		
Age (years)			
<50	0.062 (0.044-0.088)	1.14 (0.63-2.01)	0.623
≥50*	0.071 (0.047-0.107)		
Type of lesion			
Primary	0.066 (0.048-0.091)	0.94 (0.48-1.74)	0.871
Recurent*	0.063 (0.038-0.104)		
Size of lesion before surgery (mm)			
<2.5	0.066 (0.046-0.095)	0.97 (0.54-1.71)	0.928
≥3.0*	0.064 (0.043-0.095)		
All participants	0.065 (0.050-0.085)	-	-

*Set as exposed group to estimate rate ratio. CI=Confidence interval

to an elevated risk of recurrence.^[25] Similarly, Yamada *et al.* noticed that smaller pterygium decreased the risk of recurrence.^[26] On the other hand, Varssano *et al.*, after a study on 176 pterygium patients with, emphasized that pterygia invading less into the cornea probably had more recurrences.^[27] However, we should be careful that these studies differ not only in important methodological aspects but also in follow-up period, the usage of adjuvant medication, measuring approach, etc.

MMC is a kind of antimetabolites which can prevent the cell proliferation by alkylating DNA double helix.^[28] Thus, the possible explanation for lower recurrence rate following use of MMC attributed to the effect of MMC on inhibiting fibroblast proliferation and migration.^[28]

The main limitation of this study was the lack of control group and relatively short duration of follow-up in some patients.

In conclusion, the results of our study demonstrate that increasing age and pterygial tissue are risk factors for recurrence. Thus, the early excision of pterygium is recommended to decrease the recurrence rate in young patients. Furthermore, pterygium surgery has a

substantial recurrence rate even after AMT combined with MMC.

AUTHOR'S CONTRIBUTION

Hasan Razmjoo contributed in the conception of the work, revising the draft, approval of the final version of the manuscript, and agreed for all aspects of the work. Seyed-Abolfazl Kashfi contributed to the conception and design of the work, conducting the study, approval of the final version of the manuscript and agreed for all aspects of the work. Majid Mirmohammadkhani contributed in the design of the work, contributed in data analysis, revising the draft, approval of the final version of the manuscript, and agreed for all aspects of the work. Mohsen Pourazizi contributed to the design of the work, revising the draft, approval of the final version of the manuscript, and agreed for all aspects of the work. All authors contributed the idea of research, design of study, data analysis and manuscript preparation.

Financial support and sponsorship

Nil.

Conflicts of interest

There are no conflicts of interest.

REFERENCES

- Rezvan F, Khabazkhoob M, Hooshmand E, Yekta A, Saatchi M, Hashemi H. Prevalence and risk factors of pterygium: A systematic review and meta-analysis. *Surv Ophthalmol* 2018;63:719-35.
- Hirst LW. The treatment of pterygium. *Surv Ophthalmol* 2003;48:145-80.
- Kurna SA, Altun A, Aksu B, Kurna R, Sengor T. Comparing treatment options of pterygium: Limbal sliding flap transplantation, primary closing, and amniotic membrane grafting. *Eur J Ophthalmol* 2013;23:480-7.
- Zheng K, Cai J, Jhanji V, Chen H. Comparison of pterygium recurrence rates after limbal conjunctival autograft transplantation and other techniques: Meta-analysis. *Cornea* 2012;31:1422-7.
- Song YW, Yu AH, Cai XJ. Effectiveness of amniotic membrane transplantation combined with mitomycin C in the treatment of pterygium: A meta-analysis. *Int J Ophthalmol* 2010;3:352-5.
- Fernandes M, Sangwan VS, Bansal AK, Gangopadhyay N, Sridhar MS, Garg P, *et al.* Outcome of pterygium surgery: Analysis over 14 years. *Eye (Lond)* 2005;19:1182-90.
- Bahar I, Kaiserman I, Lange AP, Slomovic A, Levinger E, Sansanayudh W, *et al.* The effect of mitomycin C on corneal endothelium in pterygium surgery. *Am J Ophthalmol* 2009;147:447-520.
- Al Fayez MF. Limbal-conjunctival vs. conjunctival autograft transplant for recurrent pterygia: A prospective randomized controlled trial. *JAMA Ophthalmol* 2013;131:11-6.
- Ma DH, See LC, Hwang YS, Wang SF. Comparison of amniotic membrane graft alone or combined with intraoperative mitomycin C to prevent recurrence after excision of recurrent pterygia. *Cornea* 2005;24:141-50.
- Solomon A, Pires RT, Tseng SC. Amniotic membrane transplantation after extensive removal of primary and recurrent pterygia. *Ophthalmology* 2001;108:449-60.
- Ti SE, Chee SP, Dear KB, Tan DT. Analysis of variation in success rates in conjunctival autografting for primary and recurrent pterygium. *Br J Ophthalmol* 2000;84:385-9.
- Mutlu FM, Sobaci G, Tatar T, Yildirim E. A comparative study of recurrent pterygium surgery: Limbal conjunctival autograft transplantation versus mitomycin C with conjunctival flap. *Ophthalmology* 1999;106:817-21.
- Yaisawang S, Piyapattanakorn P. Role of post-operative topical corticosteroids in recurrence rate after pterygium excision with conjunctival autograft. *J Med Assoc Thai* 2003;86 Suppl 2:S215-23.
- Wanzeler AC, Duarte B, de Andrade VD, Alves M. Impact of conjunctival autograft on pterygium treatment: Evaluation of related symptoms and patients' satisfaction after surgery. *Clin Ophthalmol* 2018;12:833-7.
- Kam KW, Young AL. Fifteen-year results of a randomized controlled trial comparing 0.02% mitomycin C, limbal conjunctival autograft, and combined mitomycin C with limbal conjunctival autograft in recurrent pterygium surgery. *Graefes Arch Clin Exp Ophthalmol* 2019;257:2683-90.
- Hacıoğlu D, Erdöl H. Developments and current approaches in the treatment of pterygium. *Int Ophthalmol* 2017;37:1073-81.
- Dua HS, Azuara-Blanco A. Amniotic membrane transplantation. *Br J Ophthalmol* 1999;83:748-52.
- Mastropasqua L, Carpineto P, Ciancaglini M, Enrico Gallenga P. Long term results of intraoperative mitomycin C in the treatment of recurrent pterygium. *Br J Ophthalmol* 1996;80:288-91.
- Hovanesian JA, Starr CE, Vroman DT, Mah FS, Gomes JA, Farid M, *et al.* Surgical techniques and adjuvants for the management of primary and recurrent pterygia. *J Cataract Refract Surg* 2017;43:405-19.
- Ono T, Mori Y, Nejima R, Tokunaga T, Miyata K, Amano S. Long-term follow-up of transplantation of preserved limbal allograft and amniotic membrane for recurrent pterygium. *Graefes Arch Clin Exp Ophthalmol* 2016;254:2425-30.
- Hirst LW, Sebban A, Chant D. Pterygium recurrence time. *Ophthalmology* 1994;101:755-8.
- Marmamula S, Khanna RC, Rao GN. Population-based assessment of prevalence and risk factors for pterygium in the South Indian state of Andhra Pradesh: The Andhra Pradesh Eye Disease Study. *Invest Ophthalmol Vis Sci* 2013;54:5359-66.
- Kwon SH, Kim HK. Analysis of recurrence patterns following pterygium surgery with conjunctival autografts. *Medicine (Baltimore)* 2015;94:e518.
- Ha SW, Park JH, Shin IH, Kim HK. Clinical analysis of risk factors contributing to recurrence of pterygium after excision and graft surgery. *Int J Ophthalmol* 2015;8:522-7.
- Bahar I, Kaiserman I, Weisbrod M, McAllum P, Slomovic A. Extensive versus limited pterygium excision with conjunctival autograft: Outcomes and recurrence rates. *Curr Eye Res* 2008;33:435-40.
- Yamada T, Mochizuki H, Ue T, Kiuchi Y, Takahashi Y, Oinaka M. Comparative study of different β -radiation doses for preventing pterygium recurrence. *Int J Radiat Oncol Biol Phys* 2011;81:1394-8.
- Varssano D, Shalev H, Lazar M, Fischer N. Pterygium excision with conjunctival autograft: True survival rate statistics. *Cornea* 2013;32:1243-50.
- Enock ME, Omoti AE, Dawodu OA, Fuh UC, Eguaoje IE. Effectiveness of intra-operative Mitomycin-C in reducing the recurrence of pterygium in Irrua, Nigeria. *Niger Postgrad Med J* 2010;17:55-9.