

Clinical imaging and high-resolution ultrasonography in melanocytoma management

Daniel Gologorsky¹
Amy C Scheffler²
Fiona J Ehliès²
Paul A Raskauskas³
Yolanda Pina²
Basil K Williams Jr⁴
Timothy G Murray²

¹Dartmouth Medical School, Hanover, New Hampshire; ²Department of Ophthalmology, Bascom Palmer Eye Institute, University of Miami Miller School of Medicine, Miami, Florida; ³Retina Consultants of Southwest Florida, Fort Myers, Florida; ⁴Rosalind Franklin University of Medicine and Science, North Chicago, Illinois, USA

Purpose: To demonstrate the utility of high resolution 20 MHz ophthalmic ultrasound in serial follow-up of optic nerve head melanocytoma patients.

Methods: This study is a retrospective review of 30 patients with melanocytoma of the optic nerve head studied with echography. All patients were evaluated with standard ophthalmic A-scan and B-scan ultrasonography and 10 (33%) underwent high-resolution ultrasound.

Results: Sixty-two percent (62%) of patients had dome-shaped lesions on ultrasound, twenty-eight percent (28%) presented with mild elevations. The maximum elevation of any lesion was 2.6 mm. The vast majority (89%) of lesions had medium or high internal reflectivity and 89% demonstrated avascularity. Mean follow-up for all patients was nearly 7 years. High-resolution ultrasound enabled enhanced accuracy for detection of lesion dimensions and documentation of growth and possible malignant transformation.

Conclusions: In this study, we demonstrate a new and important role for the use of ultrasound in this disease as a complementary tool in identifying and following patients with high-risk growth characteristics. These tumor characteristics can be accurately detected with 10 MHz ultrasound in conjunction with standardized A-scan and better differentiated with the 20 MHz technology. Use of these modalities can aid in distinguishing the melanocytomas that grow from choroidal melanomas and can prevent unnecessary treatments.

Keywords: imaging, high-resolution, ultrasonography, melanocytoma

Introduction

Melanocytoma is a benign intraocular lesion composed of a uniform array of deeply pigmented, plump, polyhedral nevus cells.¹ It occurs most commonly on or adjacent to the optic disc, although it may appear in the choroid, ciliary body, iris, conjunctiva, or sclera. Studies have indicated that a significant percentage of optic nerve head melanocytomas grow if followed long-term, and that there are 3 risk factors for growth: increased tumor thickness, presence of intrinsic vascularization, and dome shape. Historically, echography has not been considered helpful in establishing the diagnosis of melanocytoma.² In this report we present the utility of echography, with special focus on high-resolution imaging, for 30 patients with optic disc melanocytomas.

Materials and methods

Thirty-five patients with melanocytoma of the optic nerve head were identified in a review of medical charts at a single center institutional practice. Clinical variables collected for the study included presenting symptoms, ophthalmic and ultrasound characteristics, treatment, and follow-up. All patients whose lesions demonstrated interval growth underwent

Correspondence: Timothy G Murray
Bascom Palmer Eye Institute, University of Miami Miller School of Medicine,
P.O. Box 016880, Miami, FL 33101, USA
Tel +1 305 326-6166
Fax +1 305 326-6417
Email tmurray@med.miami.edu

high-resolution (20 MHz) imaging (Cinescan S, Quantel Medical, Clermont-Ferrand, France). All had undergone standard ophthalmic A-scan and contact B-scan ultrasonography (Cinescan S, Quantel Medical, Clermont-Ferrand, France) and ten underwent high-resolution ultrasound. The mean follow-up for all patients was nearly 7 years. Exclusion criteria included follow-up shorter than 3 months in five patients.

Results

Twenty-three of the patients were female (77%), and seven (23%) were male. Nineteen (63%) of the lesions were in the left eye, and eleven (37%) were in the right eye. The mean age of the patients at diagnosis was 50 years. Nineteen patients (63%) had their lesions detected on routine ophthalmic examination, and five patients (17%) reported a decrease in visual acuity. The remainder underwent eye examinations for varying reasons such as trauma or post-cataract surgery. The majority of the patients (83%) had a corrected visual acuity of 20/30 or better on exam at diagnosis. Mean follow-up for all patients was 80 months (6.7 years).

Echographic features of the lesions are demonstrated in Table 1. All of the patients whose lesions demonstrated interval growth underwent high-resolution (20 MHz) imaging, which confirmed stable lesion dimensions and lack of extraocular extension. Of the 30 melanocytoma patients in this study, one patient's lesion underwent malignant transformation to melanoma, two underwent laser ablation of an associated choroidal neovascularization (CNV), two were given high-dose oral steroids and low-dose aspirin for 2 weeks for central retinal vascular obstruction (CRVO), one was given bevacizumab (Genentech, Inc., South San Francisco, CA) for vitreous hemorrhage, and another was treated with aspirin for branch retinal artery occlusion (BRAO).

The following two cases exemplify the utility of high-resolution ultrasound in enabling enhanced accuracy for the detection of lesion dimensions and documentation of growth and possible transformation associated with these lesions.

Case #1

A 36 year-old female with no past medical history was referred for evaluation of a mass of the optic nerve head. The patient's visual acuity was 20/50+ in the right eye and 20/20 in the left eye. The pupils were reactive and the visual field was constricted to confrontation inferonasally in the right eye. Dilated funduscopy examination revealed a pigmented lesion of the optic nerve head (Figure 1A). Standardized 10 MHz ophthalmic B-scan ultrasound demonstrated a dome-shaped lesion at the optic nerve head and standardized

Table 1 Clinical and echographic features of 30 patients with melanocytoma

Feature	Number of patients (%)
Laterality	n = 30
OD	11 (37%)
OS	19 (63%)
Gender	n = 30
M	7 (23%)
F	23 (77%)
Age at presentation (years)	n = 30
Mean	50
Median	47
Range	17–79
Presenting symptom	n = 30
Routine Exam	19 (63%)
Decreased visual acuity	5 (17%)
Other (floaters, metamorphopsia, etc)	6 (20%)
Shape	n = 29
Dome	18 (62%)
Mild elevation	8 (28%)
Irregular	3 (10%)
Maximum elevation (mm)	n = 30
Mean	1.3*
Median	1.3
Range	1–2.6
Maximum basal diameter (mm)	n = 29
Mean	2.1
Median	2.25
Range	1–4.5
Internal reflectivity	n = 26
High	19 (73%)
Medium – High	3 (12%)
Medium	1 (4%)
Low	3 (12%)
Vascularity	n = 19
Vascular	2 (11%)
Avascular	17 (89%)
Growth over time	n = 29
Increase in size	5 (17%)
Decrease in size	2 (7%)
No Change	22 (76%)
Mean magnitude of change (mm)	± 0.8
Malignant transformation	1 (3%)
Treatment	n = 30
Observation	24 (80%)
Enucleation	1 (3%)
Other (aspirin, steroids, laser ablation, etc)	5 (17%)
Follow-up (months)	n = 30
Mean	80
Median	49
Range	3–513

Note: *For statistical calculations, lesions that could best be quantified as 'less than 1 mm' were counted as 0.5 mm.

A-scan showed high internal reflectivity and a maximum elevation of 2.1 mm (Figure 1B). Six months later, the patient presented for follow-up examination. The visual acuity was stable but the right pupil demonstrated a new

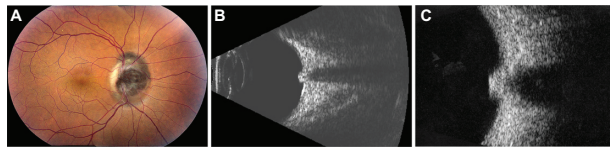


Figure 1 Clinical imaging for Case #1. **A)** Fundus photo of the right eye showing classic optic nerve head melanocytoma. **B)** 10 MHz B-scan of the lesion. **C)** 20 MHz B-scan demonstrated dome shaped lesion at the optic nerve head, consistent with melanocytoma.

afferent pupillary defect. Given this finding, standardized and high-resolution ultrasound examinations were performed. Standardized ophthalmic ultrasound demonstrated a nodular lesion with medium reflectivity. High resolution ultrasound identified an identical maximum elevation of 2.1 mm from the previous ultrasound, a smooth, dome-shaped contour, and no extraocular extension (Figure 1C). On A-scan, internal reflectivity was high. These characteristics were reassuring for lack of malignant transformation.

Case #2

A 45 year-old female with no significant past ocular history aside from an earlier thermal corneal injury was referred by an outside ophthalmologist for evaluation of an unknown fundus lesion. The patient's visual acuity was 20/20 in both eyes. Funduscopic examination showed an irregular lesion overlying and surrounding the inferior aspect of the optic disc in the right eye (Figure 2A), and standard ultrasound demonstrated the dimensions of the low-reflective lesion to be $1.3 \times 5 \times 5$ mm (apical \times basal dimensions) with mild vascularity (Figure 2C). Although the lesion was too small for differentiation, internal characteristics were suggestive of melanoma. However, on clinical examination, a diagnosis of melanocytoma was established. The lesion was followed with serial ultrasound and remained stable in size until three years later, when examination revealed that the lesion had rapidly grown in size (Figure 2B). In conjunction with standardized A-scan, high-resolution 20 MHz B-scans were taken, definitively demonstrating the increased vasculature and growth of the lesion to $3.4 \times 7 \times 6.5$ mm (Figure 2D). These features were suggestive of malignant transformation, confirming the new diagnosis of uveal melanoma. The patient subsequently underwent enucleation of her right eye. Histopathologic analysis demonstrated a malignant epithelioid melanoma arising from an area of polyhedral cells consistent with malignant transformation of a melanocytoma.

Discussion

The differential diagnosis of pigmented tumors of the optic nerve includes malignant melanoma, nevi, melanocytoma,

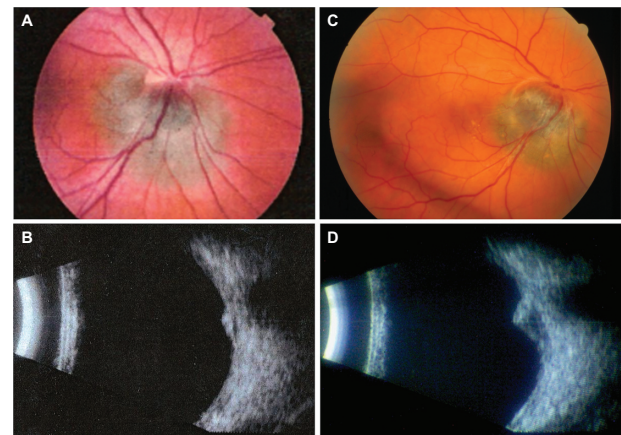


Figure 2 Clinical imaging for Case #2. **A)** Fundus photo of the right eye demonstrating pigmented juxtapapillary lesion which remained stable in appearance for several years. **B)** B-scan ultrasound of the lesion from (A) with apical height of 1.3 mm. **C)** Appearance of the same lesion two years later. Note invasion into superior optic nerve head tissue, optic disc hemorrhage, and displacement of central retinal vessels. **D)** B-scan ultrasound of the lesion from (C) showing marked increase in height to 3.4 mm, with associated basal dimensional growth.

hyperplasia of the peripapillary retinal pigment epithelium, and hamartomas of the retinal pigment epithelium and sensory retina.^{2,18} Distinguishing these lesions from malignant melanomas is important, given the potentially aggressive nature of untreated choroidal melanomas and the unfortunate cases in which patients with melanocytomas undergo enucleation unnecessarily.

Historically, clinicians have focused primarily on the funduscopic features of melanocytomas in order to distinguish them from melanomas. Anecdotal evidence at large clinical centers suggests that reliance on this method of diagnosis has been successful the vast majority of the time. Nonetheless, there have been several reported diagnostic dilemmas, including presumed melanocytomas later found to be melanomas,^{3,4} presumed melanomas identified on histopathology as melanocytomas,^{5,6} and lesions in which histopathology demonstrated foci of both melanoma and melanocytoma cells.⁷⁻⁹ Most likely there have been additional unpublished cases in which these two diagnoses were confused. Guidelines for distinguishing the two entities must be clarified to avoid inappropriate management of patients with ambiguous-appearing lesions.

Authors of previously reported large series either have noted that ultrasound was not useful in making the diagnosis of melanocytoma or have not mentioned the use of ultrasound at all.^{1,2,10} The echographic features of the 30 melanocytomas described in this patient series (Table 1), however, are notably different from those features traditionally documented as typical of melanomas. While nearly all of our patients' lesions demonstrated high internal reflectivity on

A-scan, choroidal melanomas are classically described as demonstrating low internal reflectivity.¹¹ The majority of the lesions in our study were observed to be avascular while melanomas classically are vascular.¹² The highest elevation of any lesion in this study was 2.6 mm and the largest basal diameter was 4.5 mm, whereas melanomas tend to be larger and more elevated. Hence, ultrasound is an excellent modality for identifying characteristics that distinguish these lesions from each other.

Unfortunately, in a small percentage of cases, melanocytomas possess clinical and echographic features typical for choroidal melanomas, confusing the diagnostic process. A series of 115 cases of melanocytoma of the optic nerve head by Shields et al indicates that a significant percentage of optic nerve head melanocytomas grow if followed long-term (Kaplan-Meier estimate of 32% growth at 10 years).¹⁰ Risk factors for growth on univariate analysis were found to be: increased tumor thickness, presence of intrinsic vascularization, and nodular (elevated) configuration. Furthermore, two lesions (2%) in the Shields et al series did develop malignant transformation during the follow-up period. We similarly report one such case (3%) of malignant transformation in our series of 30 patients. In addition to these cases, there are at least six other previously reported cases in which a previously diagnosed melanocytoma underwent malignant transformation to a melanoma.^{13–17}

All three of the aforementioned risk factors can be best identified and followed with precision by the use of ophthalmic ultrasound as demonstrated in this series. Through the use of ultrasound, we now stratify melanocytomas into low or high-risk for growth and potential (albeit rare) malignant transformation based on the presence of 1–3 of these features. Based on this risk designation, the necessary follow-up schedule for these patients can be determined. A patient with a tiny, flat, nonvascularized lesion need not be examined more than once every 1–2 years, whereas a patient with a large, elevated, dome-shaped, vascularized lesion, regardless of its funduscopy appearance, should be examined more frequently. Tumor margins of lesions that appear to demonstrate interval growth can be measured with the most accurate precision using the high-resolution 20 MHz B-scan when compared to the 10 MHz B-scan, in conjunction with the A-scan. Our clinical experience demonstrates that using this combination of technologies enables us to determine internal reflectivity characteristics and vascularity when lesions have reached an apical height of just 1–2 mm. These technologies will allow for earlier detection of small increases in tumor

height even in relatively small lesions, which may indicate rare cases of malignant transformation.

In summary, we present the echographic features of 30 cases of optic disc melanocytomas. In this study, we demonstrate a new and important role for the use of 20 MHz high resolution ultrasound B-scan in identifying and following patients with this disease presenting with high-risk characteristics for growth. These tumor characteristics can be accurately detected with 10 MHz ultrasound and most reliably followed with the 20 MHz technology, in conjunction with the A-scan. Use of these modalities can aid in distinguishing the melanocytomas that grow from choroidal melanomas and in avoiding unnecessary treatments.

Acknowledgment

The Bascom Palmer Eye Institute Echography group includes Fiona J Ehliès, BSc (Hons), RDMS, Ernesto Bermudez, OD, Jorge Rojas, MD, Patricia Superfine-Rivera, BGS, Maria E Bretana, MD, and Candace A Waithe-Boodoo, BS.

Disclosure

This study was not sponsored through any specific grants of funds. It has not been previously presented at a meeting. The authors do not have any proprietary interest or potential conflicts of interest in the subject matter or topics discussed.

References

- Joffe L, Shields JA, Osher RH, Gass JD. Clinical and follow-up studies of melanocytomas of the optic disc. *Ophthalmology*. 1979;86(6):1067–1083.
- Reidy JJ, Apple DJ, Steinmetz RL, et al. Melanocytoma: nomenclature, pathogenesis, natural history and treatment. *Surv Ophthalmol*. 1985;29(5):319–327.
- De Potter P, Shields CL, Eagle RC Jr, et al. Malignant melanoma of the optic nerve. *Arch Ophthalmol*. 1996;114(5):608–612.
- Erzurum SA, Jampol LM, Territo C, O'Grady R. Primary malignant melanoma of the optic nerve simulating a melanocytoma. *Arch Ophthalmol*. 1992;110(5):684–686.
- Robertson DM, Campbell RJ, Salomao DR. Mushroom-shaped choroidal melanocytoma mimicking malignant melanoma. *Arch Ophthalmol*. 2002;120(1):82–85.
- Accuracy of diagnosis of choroidal melanomas in the Collaborative Ocular Melanoma Study. COMS report no. 1. *Arch Ophthalmol*. 1990;108(9):1268–1273.
- Shields JA, Shields CL, Eagle RC Jr, et al. Malignant melanoma associated with melanocytoma of the optic disc. *Ophthalmology*. 1990;97(2):225–230.
- Shetlar DJ, Folberg R, Gass JD. Choroidal malignant melanoma associated with a melanocytoma. *Retina*. 1999;19(4):346–349.
- Roth AM. Malignant change in melanocytomas of the uveal tract. *Surv Ophthalmol*. 1978;22(6):404–412.
- Shields JA, Demirci H, Mashayekhi A, Eagle RC Jr, Shields CL. Melanocytoma of the optic disk: a review. *Surv Ophthalmol*. 2006 Mar–Apr;51(2):93–104. Review.

11. Moll AC, Imhof SM, Cruysberg JR, et al. Incidence of retinoblastoma in children born after in-vitro fertilisation. *Lancet*. 2003;361(9354):309–310.
12. DiBernardo C, Pacheco EM, Hughes JR, et al. Echographic evaluation and findings in metastatic melanoma to extraocular muscles. *Ophthalmology*. 1996;103(11):1794–1797.
13. Shields JA, Shields CL, Eagle RC Jr, et al. Malignant melanoma arising from a large uveal melanocytoma in a patient with oculodermal melanocytosis. *Arch Ophthalmol*. 2000;118(7):990–993.
14. Apple DJ, Craythorn JM, Reidy JJ, et al. Malignant transformation of an optic nerve melanocytoma. *Can J Ophthalmol*. 1984;19(7):320–325.
15. Barker-Griffith AE, McDonald PR, Green WR. Malignant melanoma arising in a choroidal magnacellular nevus (melanocytoma). *Can J Ophthalmol*. 1976;11(2):140–146.
16. Paterson MW. Melanoma of the optic disc. *Br J Ophthalmol*. 1952;36:447–452.
17. Thomas CI, Purnell EW. Ocular melanocytoma. *Am J Ophthalmol*. 1969;67:79–86.
18. Apple DJ, Rabb MF, Walsh PM. Congenital anomalies of the optic disc. *Survey of Ophthalmology*. 1982;27(1):3–41.

Clinical Ophthalmology

Publish your work in this journal

Clinical Ophthalmology is an international, peer-reviewed journal covering all subspecialties within ophthalmology. Key topics include: Optometry; Visual science; Pharmacology and drug therapy in eye diseases; Basic Sciences; Primary and Secondary eye care; Patient Safety and Quality of Care Improvements. This journal is indexed on

Submit your manuscript here: <http://www.dovepress.com/clinical-ophthalmology-journal>

PubMed Central and CAS, and is the official journal of The Society of Clinical Ophthalmology (SCO). The manuscript management system is completely online and includes a very quick and fair peer-review system, which is all easy to use. Visit <http://www.dovepress.com/testimonials.php> to read real quotes from published authors.

Dovepress