



Descemet Stripping Endothelial Keratoplasty for Congenital Aniridia: An Interesting and Challenging Story

Michael Tsatsos*, Ioannis Athanasiadis**, Nikolaos Ziakas*

*Moorfields Eye Hospital NHS Foundation Trust at Bedford Eye Clinic, Bedford, UK

**Second Department of Ophthalmology, Aristotle University of Thessaloniki, Thessaloniki, Greece

Abstract

Congenital aniridia is a rare condition affecting a wide range of ocular structures, from the ocular surface to the retina. We present the case of a 59-year-old woman with PAX6- and WT1-negative congenital aniridia who developed aniridia-associated keratopathy and progressive endothelial dysfunction with corneal decompensation after cataract surgery. The patient underwent successful ultrathin Descemet stripping endothelial keratoplasty. Despite the challenges faced with an unstable iridolenticular diaphragm, we were pleasantly surprised to see improvement not only of corneal edema and endothelial function but also of the whole cornea, including anterior corneal anatomy and appearance. In conclusion, endothelial transplantation in a patient with aniridia resulted in improvement of all the corneal structures from the endothelium to the stroma, epithelium, and possibly even the ocular surface.

Keywords: Aniridia, ocular surface, endothelium, keratoplasty

Introduction

Congenital aniridia (CA) is a rare panocular condition with different inheritance patterns and phenotypic expression. The *PAX6* gene on chromosome 11p13 is a crucial factor in its pathogenesis. The most common form is autosomal dominant CA, which involves only the eyes and has complete penetrance but variable expressivity. Sporadic cases are less frequent and are associated with a de novo mutation. This form of CA can correlate with Miller/WAGR (Wilms tumor, aniridia, genitourinary anomalies, and mental retardation) syndrome. Autosomal recessive CA is the least common variant and can be associated with cerebellar ataxia and mental retardation (Gillespie syndrome).¹

CA affects a wide range of eye structures, from the ocular surface to the cornea, iris, lens, optic nerve, and macula. The cornea and ocular surface are characteristically affected, and the term aniridia-associated keratopathy is used to describe the progressive ocular surface pathology that greatly contributes to the reduction of the visual acuity of these patients.²

Case Presentation

A 59-year-old woman with bilateral CA was referred to our corneal unit for progressive reduction in visual acuity in the right eye associated mainly with endothelial dysfunction. She had previously undergone cataract surgery in the right eye and received an Ophtec aniridia sutured intraocular lens (IOL)

Address for Correspondence: Ioannis Athanasiadis, Second Department of Ophthalmology, Aristotle University of Thessaloniki, Thessaloniki, Greece
E-mail: athana1972@yahoo.com **ORCID-ID:** orcid.org/0000-0002-6236-7540

Received: 01.11.2021 **Accepted:** 12.02.2022

Cite this article as: Tsatsos M, Athanasiadis I, Ziakas N. Descemet Stripping Endothelial Keratoplasty for Congenital Aniridia: An Interesting and Challenging Story. Turk J Ophthalmol 2022;52:208-211

©Copyright 2022 by Turkish Ophthalmological Association
Turkish Journal of Ophthalmology, published by Galenos Publishing House.

(Ophtec, Netherlands). Fundus examination was challenging, as expected in CA, but we were able to confirm the presence of foveal hypoplasia. This was confirmed with optical coherence tomography.

On examination, the patient had a best corrected visual acuity (BCVA) of hand movements, photophobia, aniridia-associated keratopathy, ptosis, nystagmus, and intraocular pressure of 12 mmHg. There was obvious corneal opacity and edema associated with stromal striae in Descemet's membrane as well as superficial and deep pannus suggesting chronicity of the corneal edema and ocular surface disease (Figure 1). Corneal thickness was measured as 857 μm , but endothelial cell count could not be obtained due to the marked corneal swelling. Genetic testing was negative for *PAX6* and *WT1* gene mutations, indicating sporadic CA with no other systemic involvement.

The patient underwent thin manual Descemet stripping endothelial keratoplasty (TM-DSEK) with 90% air fill on the operating table and developed partially detach of the graft tissue the following day. CA poses a great challenge when performing DSEK surgery, as air bubble management is much more complicated than usual due to the lack of a stable lens/iris diaphragm, even after the use of an aniridia IOL.

An excellent quality corneal graft with an endothelial cell count of 3227 cells/ mm^2 was supplied by the Hellenic Eye Bank. An ultrathin endothelial graft was prepared as previously described.^{3,4} In brief, a small temporal clear corneal incision of 4.0 mm was made with a keratome blade. A circle was marked on the recipient corneal epithelium with an 8.75-mm disc marker densely coated with gentian violet. A reverse Sinsky hook was then used to score the Descemet's membrane on the posterior side of the host cornea. This was performed under continuous balanced salt solution (BSS) flow through a Simcoe cannula (Sterimedix, Redditch, UK) inserted through a side port. The endothelial graft was inserted correct/stromal side up using the Endoserter device (Ocular Systems Inc., Winston-Salem, North Carolina, USA) and was unfolded by gently sliding the Simcoe into its fold and introducing BSS. It was centered using

peripheral pressure from the flow of BSS into the chamber. The wound was closed with three 10-0 nylon sutures and filtered air was injected under the graft to 90% fill. The patient recovered in supine position and was encouraged to avoid standing or sitting as much as possible for the first 2 days.

On the first postoperative day, the graft was partially detached with most of the air escaping posteriorly, probably due to a small crescentic gap between the aniridia IOL and iris remnants (Figure 1), as noted during the postoperative review. As this was a complicated case, we opted to proceed with rebubbling using a 20% SF₆/air mix on the operating table. The endothelial graft remained attached and led to an improvement of visual acuity to 0.55 ETDRS at 6 months postoperatively.

We were surprised to see that 3 months after DSEK surgery, there was a marked improvement of the whole corneal appearance and aniridia-associated keratopathy (Figures 2a,b)

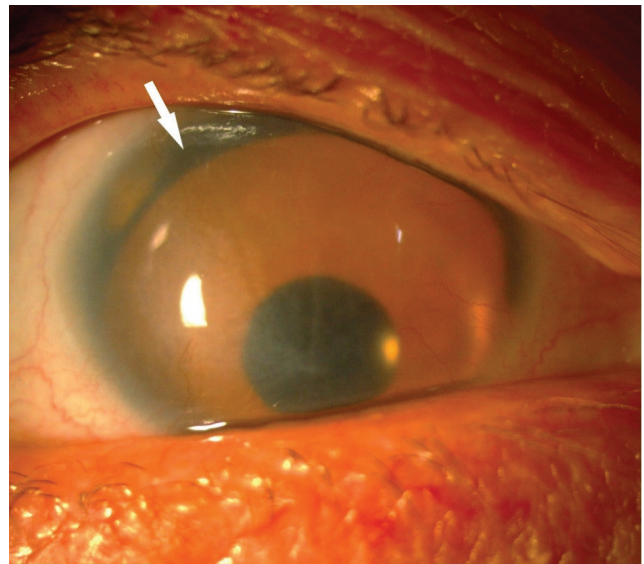


Figure 1. Congenital aniridia preoperatively with a crescentic gap between the aniridia intraocular lens and iris remnants (white arrow)

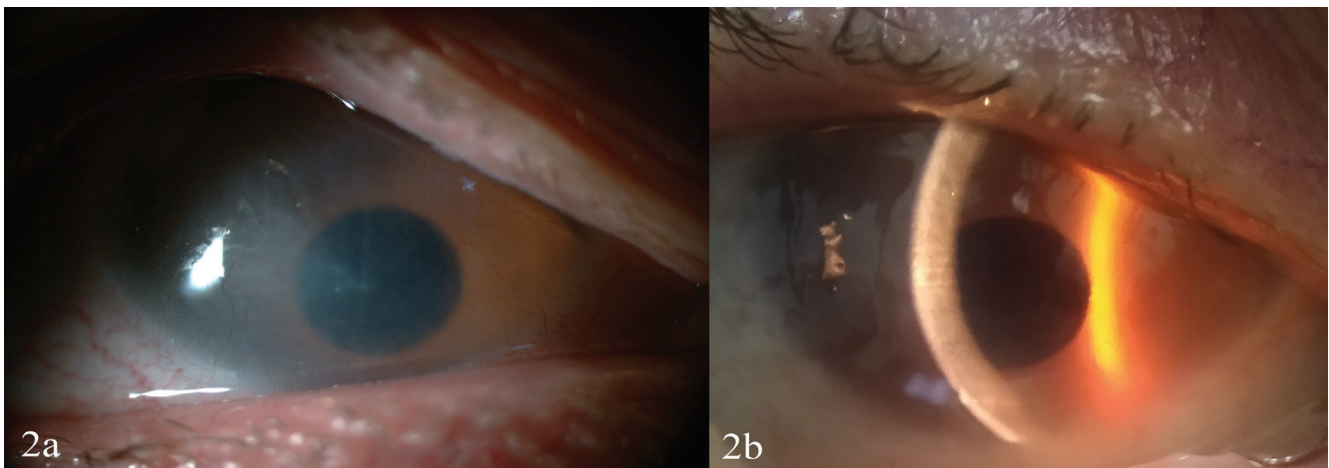


Figure 2. Congenital aniridia preoperatively (a) and 3 months after Descemet stripping endothelial keratoplasty (b)

that remains to date (Figures 3 and 4a,b). Intraocular pressure ranged between 10 and 14 mmHg at postoperative visits. The graft showed a minimum central thickness of 70 µm with total corneal thickness measuring 651 µm at 12 months after DSEK (Figure 5). Graft endothelial cell count reached 2169 cells/mm² 12 months after surgery. BCVA further improved to 0.52 at postoperative 12 months and the patient maintained this level of vision throughout the follow-up period.

Discussion

Patients with CA pose a great challenge for surgeons because it is a panocular condition with range of pathologies in most of the eye structures. The ocular surface is particularly and characteristically affected, termed aniridia-associated keratopathy. Most patients with CA have a mutation in the *PAX6* gene. The remaining patients seem to have a slightly milder pathology and disease course, as in our patient.¹ Aniridia keratopathy is usually associated with superficial corneal alterations due to limbal stem cell insufficiency. Although endothelial dysfunction is not common, cases of histopathology-proven Descemet's membrane/endothelial damage have previously been reported with subendothelial fibrous membrane present in some cases.⁵

Whether this was the case in our patient or the compromised endothelium was partly or totally associated with the previous cataract surgery cannot be ascertained.

DSEK is currently the preferred method for endothelial replacement in cases of aniridia as it offers minimal risk of posterior dislocation and easier manipulation compared to Descemet's membrane endothelial keratoplasty.⁶

We noticed that in our patient, the corneal stroma and ocular surface showed improvement after DSEK despite being significantly affected preoperatively. This was associated with a marked improvement in BCVA from hand movements to 0.55 LogMAR, reduced fluorescein staining, and an increase in tear film break-up time to 5-6 seconds from 2-3 seconds preoperatively (Figure 4a,b). This great visual outcome and improvement in the appearance of the whole cornea was maintained throughout the 2-year follow-up period. Although this improvement could be related to the reduction of corneal swelling and epithelial edema after restoring corneal endothelial function, the extent of improvement in the corneal surface could not be fully explained.

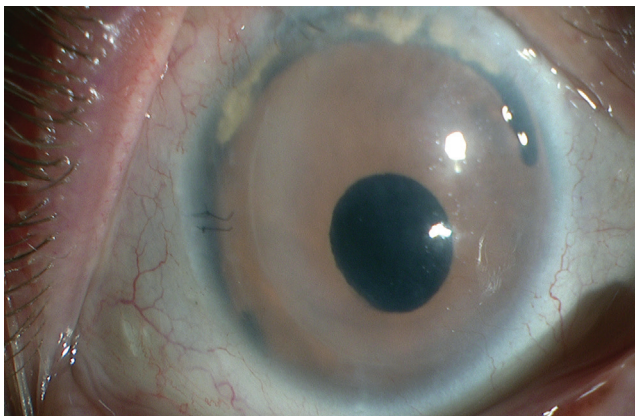


Figure 3. Appearance 12 months after Descemet stripping endothelial keratoplasty

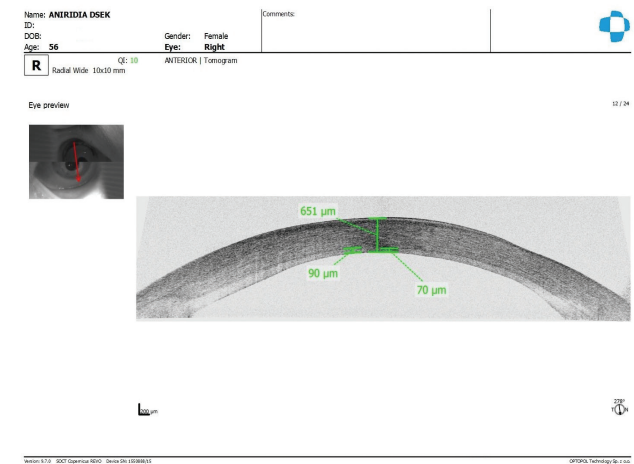


Figure 5: Corneal optical coherence tomography of the right eye 12 months after Descemet stripping endothelial keratoplasty

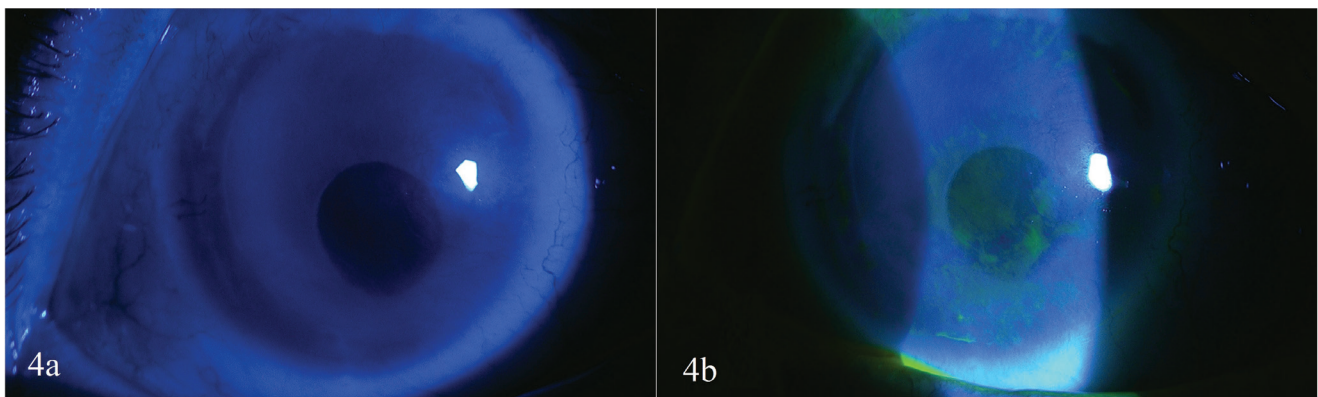


Figure 4. Postoperative cobalt blue light images of the right eye without (a) and with (b) fluorescein staining

This is the first reported case in which endothelial transplantation in a patient with aniridia resulted in improvement of the whole corneal appearance. CA is a complex pathology affecting all of the corneal (and other) structures. We observed improvement of the whole corneal appearance and function, including improved tear break-up time and superficial staining following successful TM-DSEK. A number of explanations for this can be suggested, but the mechanism remains to be elucidated. Interestingly, Zola et al.⁷ demonstrated improved corneal clarity and reduced density of anterior subepithelial fibrosis following endothelial keratoplasty in non-aniridic eyes. They proposed a cascade of corneal remodeling following resolution of stromal edema after Descemet stripping automated endothelial keratoplasty, amongst other factors, as a possible mechanism for this improvement, which suggests that a similar interaction could be the reason behind the great improvement seen in our case. Although the preoperative endothelial dysfunction may have contributed to the worsening of the ocular surface disease, the improvement noted after restoration of endothelial function cannot be fully explained. There may still be an underlying association or synergistic interaction between stromal keratocytes, limbal stem cells, and corneal endothelium that is responsible for the health of the whole cornea and hence of corneal integrity.

Ethics

Informed Consent: Obtained.

Peer-review: Externally peer reviewed.

Authorship Contributions

Surgical and Medical Practices: M.T., Concept: M.T., Design: M.T., Data Collection or Processing: M.T., I.A., Analysis or Interpretation: M.T., I.A., N.Z., Literature Search: M.T., I.A., N.Z., Writing: M.T., I.A., N.Z.

Conflict of Interest: No conflict of interest was declared by the authors.

Financial Disclosure: The authors declared that this study received no financial support.

References

1. Tripathy K, Salini B. Aniridia. In: StatPearls [Internet]. Treasure Island (FL): StatPearls Publishing; 2020.
2. Ihnatko R, Eden U, Fagerholm P, Lagali N. Congenital Aniridia and the Ocular Surface. *Ocul Surf*. 2016;14:196-206.
3. Tsatsos M, Konstantopoulos A, Hossain P, Anderson D. Presoaking with BSS used for thin manually dissected DSEK (TMDSEK): a viable option for thin DSEK. *Eye (Lond)*. 2014;28:701-704.
4. Tsatsos M, Athanasiadis I, Kopsachilis N, Krishnan R, Hossain P, Anderson D. Comparison of the Endosaver with noninjector techniques in Descemet's stripping endothelial keratoplasty. *Indian J Ophthalmol*. 2017;65:1133-1137.
5. Bausili MM, Alvarez de Toledo J, Barraquer RI, Michael R, Tresserra F, de la Paz ME. Histopathology Findings of Corneal Buttons in Congenital Aniridia Patients. *Ophthalmic Res*. 2016;56:202-206.
6. Veldman PB, Terry MA, Straiko MD. Evolving indications for Descemet's stripping automated endothelial keratoplasty. *Curr Opin Ophthalmol*. 2014;25:306-311.
7. Zola M, Kim J, Petrelli M, Schmutz L, Hashemi K, Kymionis G. Resolution of Corneal Fibrosis After Descemet's Stripping Automated Endothelial Keratoplasty: A Case Report. *Ophthalmol Ther*. 2020;9:349-354.