

Possible Approaches to Endoscopic Treatment of Popliteal Cysts: From the Basics to Troublesome Cases



Konrad Malinowski, M.D., Ph.D., Krzysztof Hermanowicz, M.D., Ph.D.,
Adrian Góralczyk, M.D., Tomasz Guszczyn, M.D., Ph.D., Bogusław Sadlik, M.D., Ph.D.,
Marek Synder, M.D., Ph.D., and Robert F. LaPrade, M.D., Ph.D.

Abstract: Popliteal cysts can be an oppressive symptom in patients with concomitant intra-articular knee pathologies. Because isolated treatment of intra-articular lesions is usually not sufficient to resolve the problems associated with a large symptomatic popliteal cyst, a popliteal cyst should be concurrently addressed with other knee pathologies to maximize patient outcomes. Conservative treatment and open surgical excision are associated with high rates of recurrence, so arthroscopic techniques are the preferred treatment options for recalcitrant cases. Arthroscopic communication-enlargement surgery with cyst wall removal seems to be the most effective. We present a simple and effective basic technique for arthroscopic popliteal cyst treatment and some approaches that allow management of the more demanding cases.

A popliteal cyst, also called a Baker's cyst, is a common finding in patients with knee joint complaints and is reportedly present in about 25% of cases.¹ The pathomechanism of popliteal cyst formation has been well investigated and includes excessive intra-articular synovial fluid production owing to intraarticular pathologies, increased intraarticular

pressure, and accumulation of joint fluid in the gastrocnemius-semimembranosus bursa caused by a valvular mechanism that allows only for a unidirectional flow.^{2,3} Because there are few high-quality studies addressing popliteal cyst treatment, there is still a lack of hard evidence as to which treatment option is the best. It has been proven that in most cases popliteal cysts persist if only intra-articular lesions are treated; therefore, symptomatic cysts should be addressed with other knee pathologies at the time of arthroscopic surgery.⁴ Although conservative treatment and open surgical procedures are associated with high rates of recurrence, arthroscopic techniques are becoming more and more popular and seem to be safe and effective.³ It has been said that arthroscopic debridement of popliteal cysts and closure of the valvular mechanism cannot be a recommended treatment option in most cases.⁵ Therefore, arthroscopic treatment of intra-articular lesions with arthroscopic communication-enlargement surgery and excision of the cyst walls is an effective method, which can be currently proposed for patients with symptomatic popliteal cysts.^{2,6} This way each element of popliteal cyst pathogenesis can be addressed. Our aim is to present a simple and effective basic technique for arthroscopic popliteal cyst treatment and some approaches that allow surgeons to address more demanding cases. The protocol of the study in which this technique was developed was approved by a bioethics committee.

From Artromedical Orthopaedic Clinic (K.M.), Belchatow, Poland; ORTIM Orthopaedic Clinic (K.H., A.G.), Bialystok, Poland; Department of Paediatric Orthopaedics and Traumatology, Medical University of Bialystok (T.G.), Bialystok, Poland; St Luke's Hospital (B.S.), Bielsko-Biala, Poland; Clinic of Orthopaedics and Pediatric Orthopaedics, Medical University of Lodz (M.S.), Lodz, Poland; and Steadman Philippon Research Institute, The Steadman Clinic (R.F.L.), Vail, Colorado, U.S.A.

The authors report the following potential conflicts of interest or sources of funding: K. Malinowski reports no conflict of interests for this video and manuscript; he reports he is a Zimmer Biomet consultant and is on the PTArthro Board. R. F. LaPrade reports no conflict of interests for this video and manuscript; he reports that that he is a consultant and receives royalties from Arthrex, Ossur, and Smith & Nephew; Editorial Boards of AJSM, JEO, and KSSTA. The other authors report no conflicts of interest. Full ICMJE author disclosure forms are available for this article online, as [supplementary material](#).

Received October 16, 2018; accepted November 14, 2018.

Address correspondence to Konrad Malinowski, M.D., Ph.D., Artromedical Orthopaedic Clinic, Chrobrego 24, 97-400 Belchatow, Poland. E-mail: malwin8@wp.pl

© 2019 by the Arthroscopy Association of North America. Published by Elsevier. This is an open access article under the CC BY-NC-ND license (<http://creativecommons.org/licenses/by-nc-nd/4.0/>).

2212-6287/181260

<https://doi.org/10.1016/j.eats.2018.11.015>

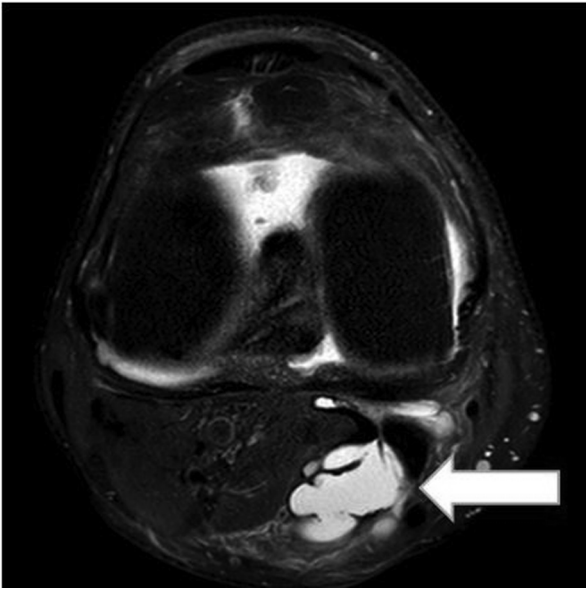

Fig 1. Axial magnetic resonance imaging scan of the right knee. Popliteal cyst is indicated by the white arrow.

Surgical Technique

Indications

This procedure is indicated for a symptomatic popliteal cyst diagnosed by means of clinical and radiologic examination (Fig 1).

Contraindications

This procedure is contraindicated for any patient who has an atypical cyst that is not a popliteal cyst, an aneurysm, a varicose vein, or a cyst other than one in the gastrocnemius-semimembranosus bursa.

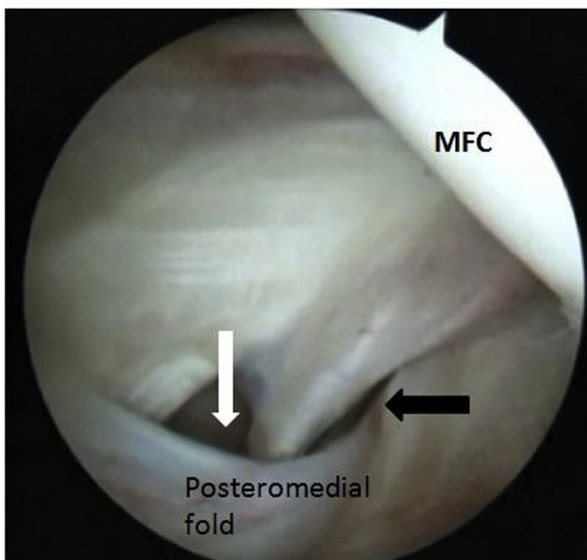


Fig 2. Arthroscopic view from the anterolateral viewing portal in the right knee: transnotch maneuver. The needle (black arrow) introduced through the skin is used to identify the entrance to the popliteal cyst (white arrow) behind the posteromedial fold. (MFC, medial femoral condyle.)

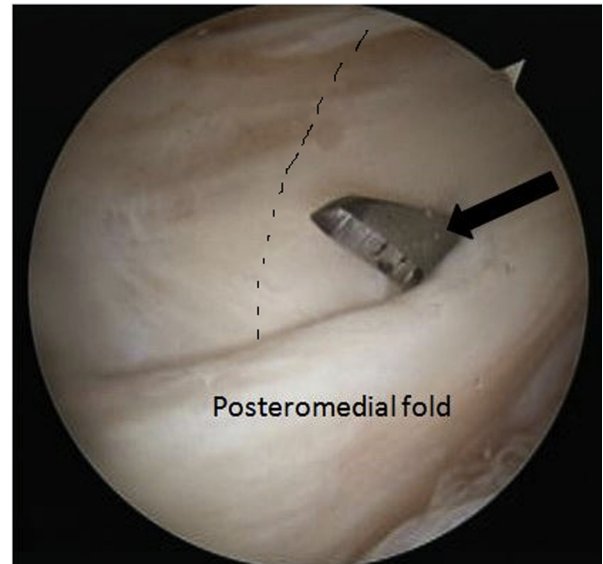


Fig 3. Arthroscopic view from the anterolateral viewing portal in the right knee: transnotch maneuver. A No. 11 surgical blade (black arrow) is used to create additional posteromedial portal just above the posteromedial fold. The margin of the medial head of the gastrocnemius is marked.

Patient Positioning

In most cases of popliteal cyst surgeries, the patient is positioned supine with the operated leg in a leg holder. In cases of large popliteal cysts that descend to the calf or cysts located close to the popliteal neurovascular bundle, a posterior popliteal approach is used, and the patient is positioned prone. A nonsterile thigh tourniquet is applied. The leg is prepared and draped in sterile fashion.

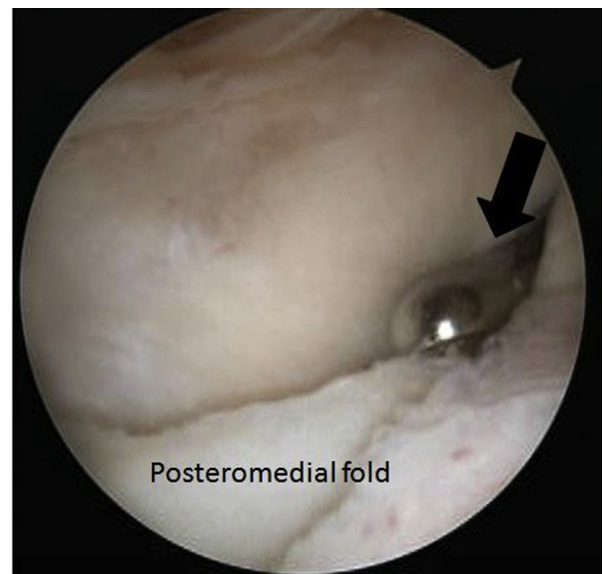


Fig 4. Arthroscopic view from the anterolateral viewing portal in the right knee: transnotch maneuver. The shaver (black arrow) is introduced through the posteromedial portal and used to remove the posteromedial fold and enlarge the communication between the popliteal cyst and the knee joint.

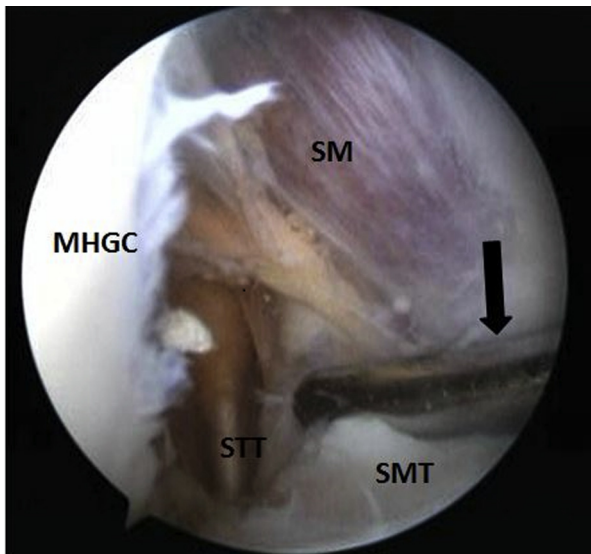


Fig 5. Arthroscopic view from the anterolateral viewing portal in the right knee. The arthroscope is introduced through the notch into the popliteal cyst. The shaver (black arrow) is used to remove popliteal cyst walls. (SM, semimembranosus muscular part; SMT, semimembranosus tendon; STT, semitendinosus tendon; MHGC, medial head of gastrocnemius.)

Basic Technique of Arthroscopic Communication-Enlargement Surgery With Cyst Wall Excision

The diagnostic arthroscopy is performed with a 30° arthroscope (ConMed, Warsaw, Poland), through standard anterolateral and anteromedial portals. When the inspection of the knee reveals concomitant intra-articular lesions, they are addressed first. Then the transnotch maneuver is performed, and the arthroscope is inserted from the anterolateral viewing portal through the space between the posterior cruciate

ligament superiorly and the medial femoral condyle medially to enter the posteromedial compartment. A spinal needle pierced through the skin is used to localize the valve responsible for unidirectional joint fluid flow and the entrance to the popliteal cyst, which is usually located behind the posteromedial fold (Fig 2, Video 1). Under arthroscopic visualization, a posteromedial portal is created in the soft spot just proximal to the level of the posteromedial fold, 5 to 8 mm medial to the medial margin of the medial head of the gastrocnemius. The impression of the medial head of the gastrocnemius can be observed on the posteromedial capsule (Fig 3, Video 1). A 4.5-mm shaver (ConMed) and a radiofrequency probe (Arthrocare, Smith & Nephew, London, United Kingdom) are introduced sequentially through the posteromedial portal and used to excise the valve and enlarge the communication between the popliteal cyst and the knee joint (Fig 4, Video 1). This procedure restores bidirectional fluid flow and limits fluid accumulation in the cyst. In the next step, the arthroscope is introduced inside the cyst through the previously enlarged popliteal cyst entrance (Video 1). With the knee flexed to 90°, the shaver is introduced through the posteromedial portal subcutaneously, carefully moved dorsally along the medial wall of the popliteal cyst with arthroscopic control of the location of its tip, introduced through the medial wall inside the cyst, and used to excise it (Video 1). It is crucial to use a nonaggressive shaver tip and have it directed medially during the procedure. Then the shaver is used to excise the other cyst walls (Fig 5, Video 1). At the end of the cyst excision, the arthroscope is moved back to the posteromedial compartment, and the shaver is used to remove remaining tissue that could limit bidirectional fluid flow (Video 1).

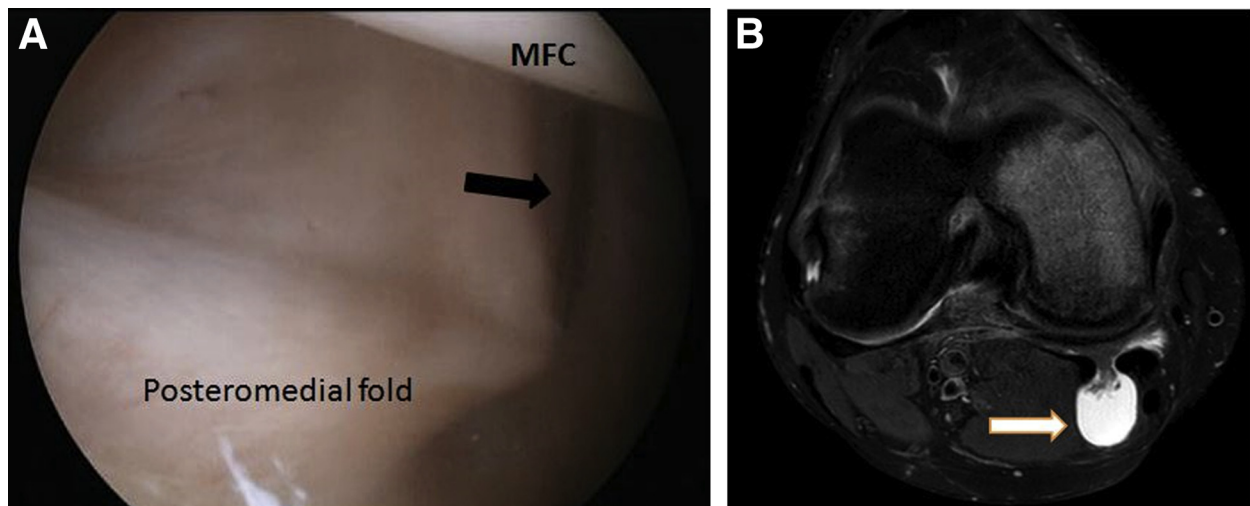


Fig 6. Arthroscopic view from the anterolateral viewing portal in the right knee: transnotch maneuver. (A) Entrance to the popliteal cyst cannot be identified in the posteromedial capsule with a needle (black arrow) introduced through the skin, but (B) existence of the cyst is confirmed on magnetic resonance imaging scans. (MFC, medial femoral condyle.)

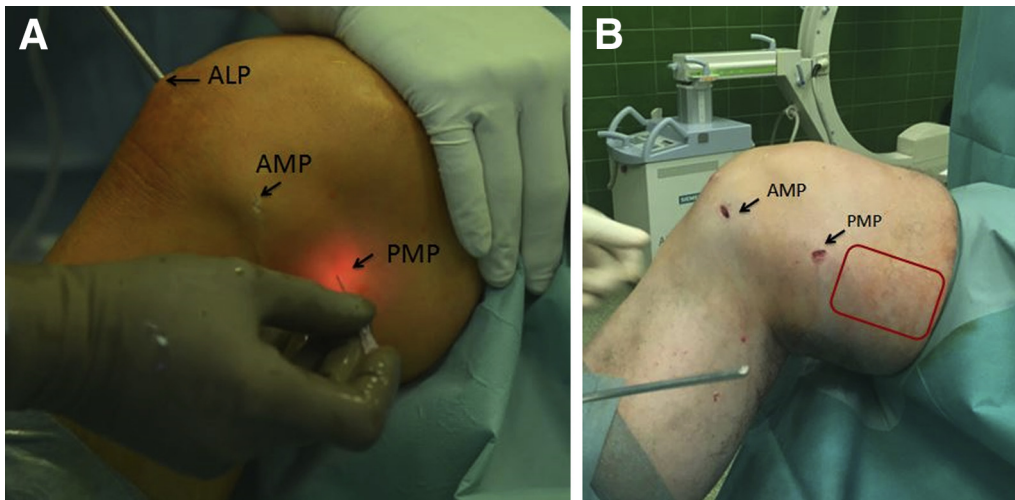


Fig 7. View of the right knee from the medial side. (A) Creation of posteromedial portal with transillumination. (B) The red frame indicates the safe anatomic region for creation of an additional posteromedial portal. (ALP, anterolateral portal; AMP, anteromedial portal; PMP, posteromedial portal.)

Undetectable Entrance to Cyst in the Posteromedial Joint Capsule or Large Cyst Extending to the Thigh

Sometimes the valve and the entrance to the cyst cannot be identified, but a symptomatic popliteal cyst has been diagnosed by means of clinical and radiologic examination (Fig 6, Video 1), or the cyst is large and extends to the thigh. In such cases the posteromedial portal is created in the soft spot, 5 to 8 mm medial to the medial head of the gastrocnemius, just proximal to the level of the posteromedial fold, as described previously. When the posteromedial fold is not visible, the posteromedial portal is created 5 to 8 mm medial to the medial margin of the gastrocnemius at the level of the posterior horn of the medial meniscus, 5 mm below the posterior curvature of the medial femoral condyle. This portal is used to introduce the shaver (ConMed) and the radiofrequency probe (Arthrocare) (Video 1). The instruments mentioned previously are used to remove the posteromedial joint capsule and soft tissue over the lateral margin of the semimembranosus tendon and the

medial head of the gastrocnemius, where the entrance to the popliteal cyst is usually located (Video 1). Then the instruments are directed along the medial margin of the medial head of the gastrocnemius, which is a key landmark, and the soft tissue in front of and posterior to this muscle is excised. The cyst walls can be excised as described previously or by using an additional posteromedial portal created with the knee flexed to 90°, 3 to 7 cm proximal to the posteromedial portal in the safe anatomic region above the hamstrings, which can be identified by means of palpation and transillumination (Fig 7, Video 1). The arthroscope is positioned back into the posteromedial compartment, and the switching stick is introduced through the posteromedial portal and inserted into the popliteal cyst to determine the proper direction for further maneuvering with the shaver (Video 1). An additional posteromedial portal is used to introduce the 30° arthroscope (ConMed) and visualize the inside of the cyst (Video 1). The shaver inserted through the posteromedial portal is used to

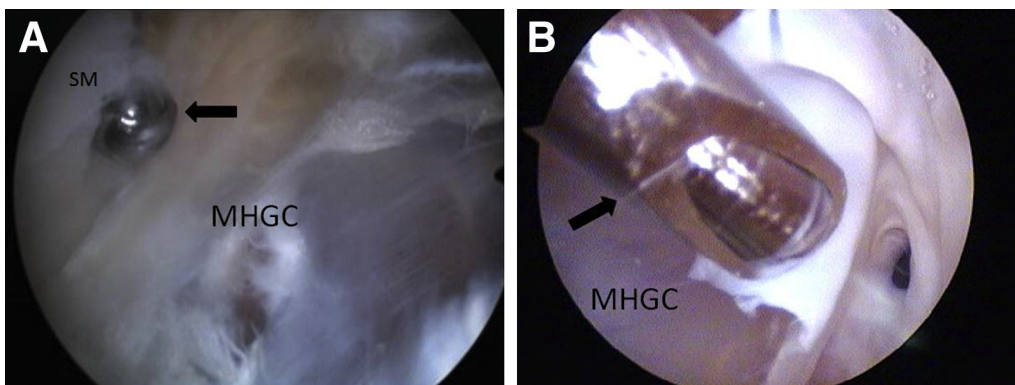


Fig 8. Arthroscopic view from the additional posteromedial portal in the right knee. The shaver (black arrow) inserted through the posteromedial portal is used to excise (A) the cystic wall and (B) soft tissues that act as a valve. (SM, semimembranosus; MHGC, medial head of gastrocnemius.)

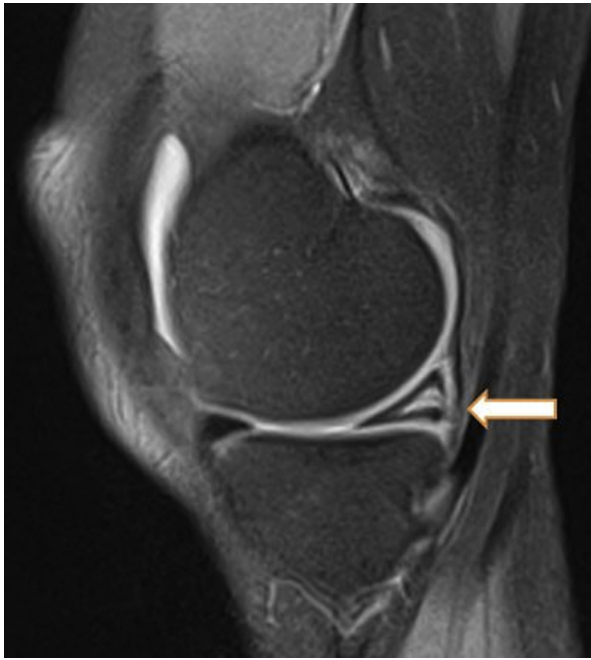

Fig 9. Sagittal magnetic resonance imaging scan of the right knee reveals excessive degenerative changes in the posterior part of the medial meniscus (so-called empty medial meniscus).

excise the cystic wall and soft tissue that act as a valve (Fig 8, Video 1).

Popliteal Cyst Caused in Continuity by Posterior Medial Meniscus Pathology

When the popliteal cyst seems to be connected with a cyst of the posterior part of the medial meniscus (MM), the meniscus body has excessive degenerative changes, or a horizontal cleavage tear and the typical valvular mechanism cannot be found in the posteromedial

capsule, the bidirectional fluid flow can be restored by opening the MM body (Fig 9). With the 30° arthroscope introduced through the anterolateral viewing portal, the scalpel is introduced through the anteromedial portal and used to incise the posterior part of the MM horizontally (Fig 10A, Video 1). Then the arthroscopic hook probe and the shaver are used sequentially to enlarge the space in the MM connecting the popliteal cyst with the joint (Fig 10B, Video 1).

Popliteal Approach for Large Popliteal Cyst Descending to the Calf or Cyst Near the Popliteal Neurovascular Bundle

When the cyst is large, descends low to the calf, or is located close to the popliteal neurovascular bundle, full unrestricted maneuverability of the scope and instruments is required. It cannot be achieved with the scope introduced through the notch because the scope is pushing toward the medial wall of the cyst. Similar limitations can occur in maneuvering instruments. In this situation the patient is positioned prone. The popliteal cyst is identified with ultrasound and marked. In the lower medial part of the cyst, a small, flat skin incision is made with a No. 11 surgical blade, and forceps are introduced subcutaneously to create a space between the skin and popliteal cyst wall. The arthroscope is introduced subcutaneously and used to control creation of the second arthroscopic portal, located laterally, for introduction of the shaver (Fig 11A). The shaver is introduced subcutaneously and used to extend the space between the skin and the popliteal cyst wall, and then the needle is pierced through the skin into the popliteal cyst until fluid leakage can be observed (Fig 11B). Then, the needle plays a role of a guide to find the cyst wall, and to make a transcystic portal to introduce the arthroscope and the shaver into the cyst.

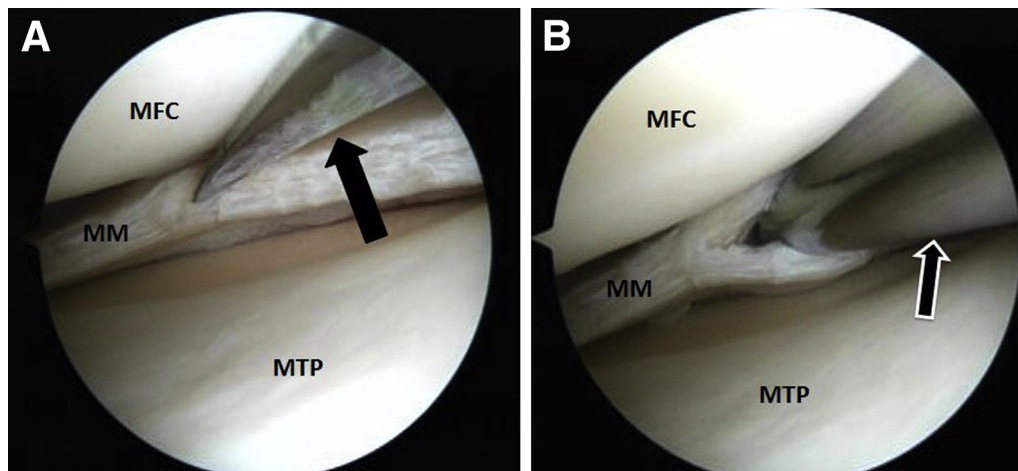


Fig 10. Arthroscopic view from the anterolateral viewing portal in the right knee. (A) A No. 11 surgical blade (black arrow), introduced through anteromedial portal, is used to make a horizontal incision in the posterior part of the MM. (B) Next, the shaver (black arrow), introduced through anteromedial portal, is used to enlarge the space in the MM communicating with the popliteal cyst and the knee joint. (MFC, medial femoral condyle; MM, medial meniscus; MTP, medial tibial plateau.)

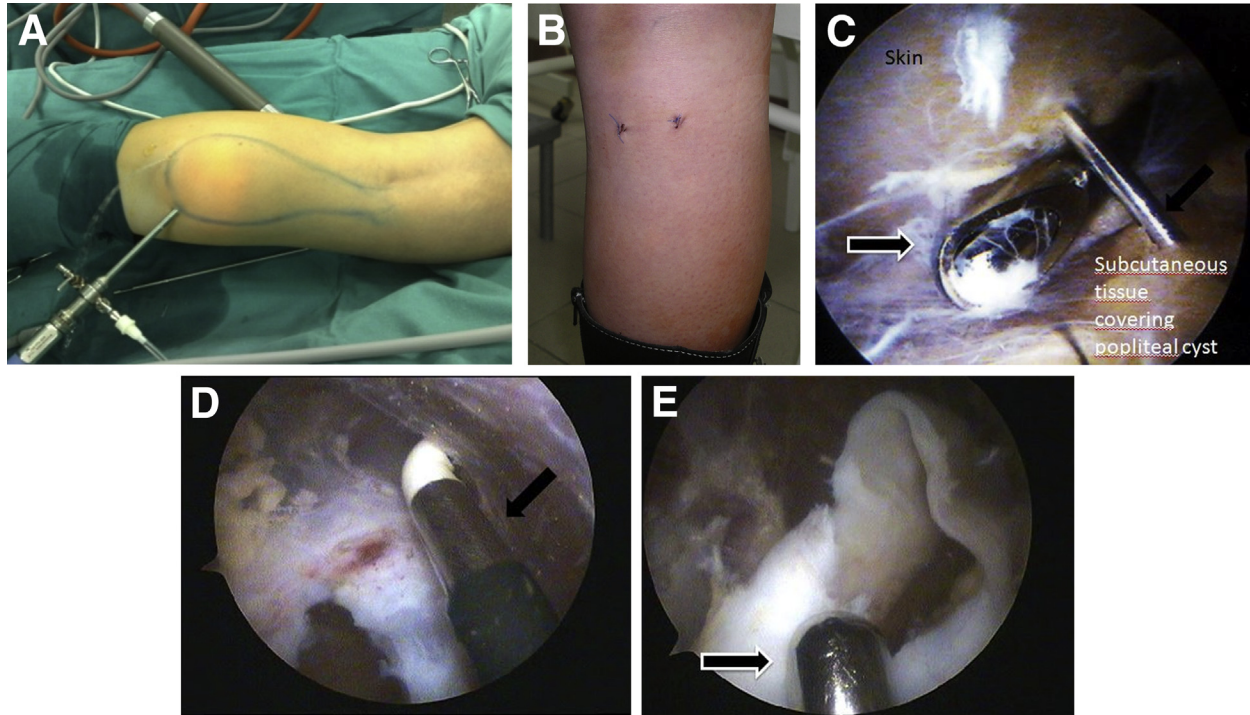


Fig 11. (A) View of a right knee from the popliteal region. The popliteal cyst is marked. The arthroscope was introduced subcutaneously between the skin and popliteal cyst wall. (B) View of a right knee from the popliteal region. Two skin sutures on standard popliteal portals. (C). Arthroscopic view from the low medial popliteal portal in the subcutaneous space between the skin and the popliteal cyst wall in the left knee. The needle (black arrow) is introduced in the cyst to determine direction and then used for dissection and transcystic portal creation with the shaver (black arrow with white contour). (D) Arthroscopic view from the low medial popliteal portal of the popliteal space and the popliteal cyst wall in the right knee. The radiofrequency probe (black arrow) is introduced through the central popliteal portal to dissect the cyst walls. (E) Arthroscopic view from the low medial popliteal portal of the popliteal space and the popliteal cyst wall in the right knee. The shaver (black arrow with white contour) is introduced through the central popliteal portal to dissect the cyst walls.

The popliteal cyst walls are then removed with the shaver as described previously (Fig 11C, Video 1)

The result of arthroscopic popliteal cyst treatment was observed during second-look arthroscopy performed from other indications (Fig 12, Video 1).

Rehabilitation

A special rehabilitation protocol designed for isolated popliteal cyst treatment does not exist. The popliteal cyst is always a secondary finding, and concomitant intra-articular lesions are treated before

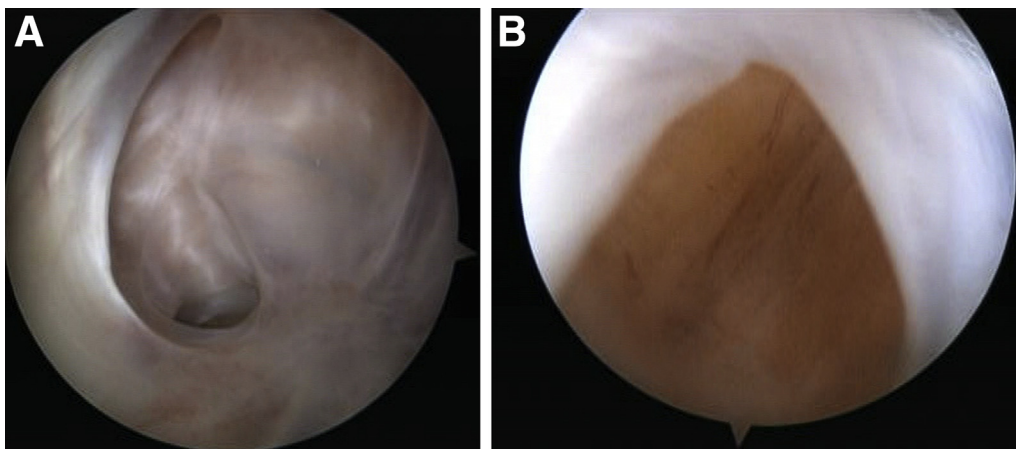


Fig 12. Arthroscopic view from the anterolateral viewing portal in the right knee: transnotch maneuver. (A and B) Outcome of popliteal cyst excision observed during second-look arthroscopy performed from another indications. (MHGC, medial head of gastrocnemius.)

Table 1. Pearls and Pitfalls of Popliteal Cyst Treatment

Step		Pearls
1	Preoperative MRI	Assess the location of popliteal cyst, valvular mechanism, position of the popliteal cyst against popliteal neurovascular bundle. The regular popliteal cyst should be well separated from the popliteal neurovascular bundle with medial head of gastrocnemius muscle. Identify intra-articular lesions and treatment possibilities.
2	Preoperative ultrasound examination	Do it when the popliteal cyst is large, and there is a need for additional posteromedial and popliteal portals creation. Draw safe area on the skin.
3	Arthroscopy	Treat concomitant intra-articular lesions and the popliteal cyst with communication-enlargement surgery.
4	Match the Approach to the Type of Cyst	
	Typical popliteal cyst in gastrocnemius-semimembranosus bursa with visible valvular mechanism	Patient position: supine. Viewing portal: anterolateral with transnotch maneuver. Working portal: posteromedial portal
	Popliteal cyst without visible connection with the joint	Patient position: supine
	Large popliteal cyst ascending to the thigh	Viewing portal: anteromedial with transnotch maneuver, then additional posteromedial
	Popliteal cyst close to the popliteal neurovascular bundle on the thigh	Working portal: posteromedial portal
	Popliteal cyst without connection with the joint caused by pathology of posterior part of medial meniscus	Patient position: supine Viewing portal: anterolateral Working portal: anteromedial
	Large popliteal cyst descending to the calf	Patient position: prone
	Popliteal cyst more central, close to the popliteal neurovascular bundle on the calf	Viewing portal: medial popliteal Working portal: lateral popliteal
Pitfalls		
1) Aggressive shaver tip used for cyst wall excision 2) Shaver tip directed toward the popliteal neurovascular bundle 3) A lack of proper visualization 4) Lost control of the direction and the depth of working instruments 5) Lost anatomic position of the scope 6) A part of posteromedial fold or other soft tissues impairing bidirectional fluid flow left 7) Primary intra-articular pathologies left untreated		

cyst excision. The applied rehabilitation protocol depends on the procedures performed for primary knee pathologies and the surgeon’s routine and experience. Because the soft tissues of the popliteal fossa are incised, the patient must fully extend the knee after the operation to prevent a knee flexion contracture. As for other procedures involving soft tissues around the knee, we also recommend passive bending of the knee to at least 90°, starting immediately after the operation.

Discussion

Symptomatic popliteal cysts, because they are very common findings in patients with other intra-articular knee pathologies, should be concurrently treated to improve patients’ well-being and satisfaction after knee surgeries.^{3,4,6} The basic arthroscopic technique presented in this Technical Note provides the tools to successfully treat different kinds of popliteal cysts, from simple to more demanding cases. Moreover, it allows the surgeon to cope with each element of

Table 2. Advantages and Disadvantages of Arthroscopic Popliteal Cyst Treatment

Advantages	Disadvantages
Fast, reproducible procedure that can be performed simultaneously with other procedures for intra-articular lesions	Working close to the popliteal neurovascular bundle with the risk of injuring it
Possibility to completely remove the valvular mechanism and control bidirectional fluid flow in fluid environment	Experience in posterior portal preparing and knowledge of endoscopic anatomy of posterior part of the knee demanded
Fast recovery, cosmetic scars	Preoperative MRI planning always required
Early ROM return, 1-day surgery	Supine to prone position conversion can be necessary
Only typical arthroscopic instruments required	

MRI, magnetic resonance imaging; ROM, range of motion.

popliteal cyst pathogenesis by removing the valvular mechanism, enlarging the communication between the cyst and joint cavity, and excising the cyst walls. This course of action with simultaneous arthroscopic treatment of concomitant intra-articular lesions has been reported to have the highest success rate among other treatment options.¹

The most important advantages of the presented technique are minimal invasiveness and its possible application for each kind of popliteal cyst. Most open surgical procedures are associated with an unacceptable recurrence rate. Arthroscopic surgery is more effective and allows for a faster recovery and early introduction of rehabilitation.³ Even if open posterior cystectomy can reach a rate of recurrence as low as 2%, it still has some disadvantages, such as a wide surgical approach, increased risk of wound infection and delayed healing, and poorer visualization of anatomic landmarks in comparison with arthroscopy.⁷ Among other arthroscopic techniques, our technique is distinguished by its simplicity. In contrast to the technique presented by Kongmalai and Chernchujit,⁸ we prefer not to use any dye because it can impair visualization and preclude identification and adequate management of concomitant intra-articular lesions. Instead of using dye, in our technique, we use specific maneuvers that allow for proper identification of inapparent popliteal cysts. We also provide adequate tools to cope with more demanding popliteal cysts. Arthroscopic visualization through an additional posteromedial portal provides better control in cases in which large popliteal cysts ascend to the thigh or are positioned close to the popliteal neurovascular bundle. Popliteal arthroscopic approaches are used in case of low calf descending popliteal cysts. This technique can also be applied when the cyst borders the neurovascular bundle. For popliteal cysts derived from medial meniscus pathology, an expansion of the idea of Sansone and De Ponti⁹ is described. The technique is based on creation of a connection between the joint space and the cyst going through a degenerative MM body, which allows for free bidirectional flow of joint fluid. [Table 1](#) presents tips and tricks for popliteal cyst management.

It is worth noting that concomitant intra-articular pathologies should be managed before treating the popliteal cyst because of the possibility of leakage of irrigative fluid leading to an increase of pressure in the crural compartments when the popliteal cyst is opened. It may be necessary to perform a popliteal cyst excision as a staged procedure when the surgery for concomitant intra-articular lesions is prolonged. Another disadvantage of the procedure presented in this Technical Note is a risk of popliteal neurovascular bundle injury during removal of the cyst walls. Preoperative planning

with magnetic resonance imaging should be done to avoid any potential neurovascular injury. The key is to identify the relations among the medial wall of the cyst, the medial head of the gastrocnemius, and the popliteal neurovascular bundle. When central popliteal cysts are located close to the nerves and vessels or when the visualization is restricted for other reasons, prone patient positioning and a popliteal approach could be the method of choice. Moreover, it is important to have constant visual control of the tip of working instrument. We recommend using a nonaggressive shaver tip. It is crucial to have the cutting edge of the shaver directed medially, in opposition to the popliteal neurovascular bundle, and to avoid incision of any muscle fibers and lax soft tissues on the lateral side of the cyst because they usually lie very close to the vessels. Despite many reports of additional portals and approaches to popliteal cysts, we propose establishing them in safe areas and preparing them, as described for this technique, to reduce the risk to important anatomic structures around the knee. The knee should be flexed to 90° when the posteromedial portal is created to prevent saphenous nerve injury.

[Table 2](#) lists important advantages and disadvantages of the technique described in this Technical Note.

References

1. Picerno V, Filippou G, Bertoldi I, et al. Prevalence of Baker's cyst in patients with knee pain: An ultrasonographic study. *Reumatismo* 2014;65:264-270.
2. Zhou XN, Li B, Wang JS, Bai LH. Surgical treatment of popliteal cyst: A systematic review and meta-analysis. *J Orthop Surg Res* 2016;11:22.
3. Herman AM, Marzo JM. Popliteal cysts: A current review. *Orthopedics* 2014;37:e678-e684.
4. Rupp S, Seil R, Jochum P, Kohn D. Popliteal cysts in adults. Prevalence, associated intraarticular lesions, and results after arthroscopic treatment. *Am J Sports Med* 2002;30:112-115.
5. Frush TJ, Noyes FR. Baker's cyst: Diagnostic and surgical considerations. *Sports Health* 2015;7:359-365.
6. Ohishi T, Takahashi M, Suzuki D, et al. Treatment of popliteal cysts via arthroscopic enlargement of unidirectional valvular slits. *Mod Rheumatol* 2015;25:772-778.
7. Saylik M, Gökkuş K. Treatment of Baker cyst, by using open posterior cystectomy and supine arthroscopy on recalcitrant cases (103 knees). *BMC Musculoskelet Disord* 2016;17:435.
8. Kongmalai P, Chernchujit B. Arthroscopic treatment of popliteal cyst: A direct posterior portal by inside-out technique for intracystic debridement. *Arthrosc Tech* 2015;4:e143-e148.
9. Sansone V, De Ponti A. Arthroscopic treatment of popliteal cyst and associated intra-articular knee disorders in adults. *Arthroscopy* 1999;15:368-372.