

RESEARCH

Open Access



The correlation between cutout and eccentric distance (ED) of the cephalic fixator tip in geriatric intertrochanteric fractures with internal fixation

Yun-fa Yang^{*}, Jian-wen Huang, Xiao-sheng Gao and Zhong-he Xu

Abstract

Background: The location of cephalic fixator tip with different eccentric distance (ED) should have different risks of cutout. This study aims to evaluate the cephalic fixator tip position by measuring ED of the cephalic fixator tip in geriatric ITF patients with single-screw cephalomedullary nail (SCMN) fixation and analyze the correlation between the cutout and the ED.

Methods: Firstly, we assumed all the femoral head was a regular sphere and standardized the radius of the femoral head (R_{FD}) as "3" no matter how big the R_{FD} was for complete match of the Cleveland zone system and convenient identification of artificial intelligence. Secondly, we measured the ED of the cephalic fixator tip by calculating the distances from the cephalic fixator tip to the geometric central axis of the femoral neck and head on both AP view and lateral view radiographs. Thirdly, we evaluated all the ED of the cephalic fixator tip in the eligible 123 geriatric ITF patients and analyzed the correlation between the cutout and the ED.

Results: The ED in cutout group (1.25 ± 0.43) is much bigger than that in non-cutout group (0.64 ± 0.34) with significant difference (OR = 50.01, 95% CI 8.42–297.19, $p < 0.001$). The probability of cutout increased with ED increasing, especially when "ED ≥ 1 ." The best cutoff value of ED for predicting cutout was "1.022" ("1.022" was just a little bit more than 1/3 times of R_{FD} because " $R_{FD} = 3$," sensitivity = 73.3%, specificity = 86.1%, and AUC = 0.867, $p < 0.001$).

Conclusion: ED is suitable for evaluation of the cephalic fixator tip position for predicting cutout in geriatric ITF patients with SCMN fixation, and ED can potentially be used as artificial intelligence application during surgery. The smaller the ED, the lower the cutout rate. For avoiding cutout, the ED of the cephalic fixator tip should be less than one-third times of the radius of the femoral head.

Keywords: Eccentric distance, Intertrochanteric fractures, Internal fixation, Cutout, Artificial intelligence

Background

The incidence of intertrochanteric fractures (ITF) is dramatically increased due to the aging population in all over the world. The social burden of ITF significantly ascends because geriatric ITF patients usually have some comorbidities, mortality, and aging-related complications. Actually, surgical treatment is almost the best choice for these geriatric ITF patients if they have no special

*Correspondence: yangyunfamd@163.com; eyyangyunfa@scut.edu.cn

Department of Orthopaedic Surgery, Guangzhou First People's Hospital, The Second Affiliated Hospital, School of Medicine, South China University of Technology, 1 Panfu Road, Guangzhou 510180, Guangdong, China



contraindications for surgery. Nowadays, cephalomedullary nails (CMN) have been widely used for geriatric ITF patients' internal fixation because of their inherently biomechanical advantages and good clinical outcomes. However, postoperative implant failure (such as cutout) rate ranged in 1.85–20.5%, which remains a great challenge to orthopedists globally [1–4].

Actually, cutout is highly associated with the location of the cephalic fixator tip in ITF patients with internal fixation [5–10]. And the Cleveland zone system is easily available for the surgeon to evaluate the cephalic fixator tip placement [2, 5–7, 11–16]. In Cleveland zone system, the femoral head is divided into superior, central, and inferior thirds on the anteroposterior radiograph and into anterior, central, and posterior thirds on the lateral radiograph, resulting in that the femoral head is divided into nine separate zones for evaluating the cephalic fixator tip position [5].

However, cutout still occurs in the patients with the cephalic fixator tip located in Cleveland Zone 5. The mechanical effect of the cephalic fixator tip in Cleveland Zone 5 is different because the eccentric distance (ED) in the marginal region of Cleveland Zone 5 is much bigger, and that is probably why cutout still occurs in the patients with the cephalic fixator tip placed in Cleveland Zone 5.

Therefore, we hypothesized that the placement of cephalic fixator tip in different ED should have different risks of cutout. We aimed to (1) measure the ED of cephalic fixator tip, and (2) analyze the relation between the cutout and the ED of cephalic fixator tip in the geriatric ITF patients with internal fixation.

Methods

We measured the ED of cephalic fixator tip and analyzed the correlation between the cutout and the ED of cephalic fixator tip in the geriatric ITF patients with single-screw cephalomedullary nail (SCMN) fixation.

ED measurement

We located the tip of cephalic fixator in the coordinate diagram (an x - y plot) of femoral head and evaluated the cephalic fixator position by individually measuring the ED of the cephalic fixator tip in ITF patients with SCMN fixation.

Firstly, we assumed all the femoral head was a regular sphere and standardized that all the radius of the femoral head (R_{FD}) was “3” (R_{FD} = “3,” without any unit) no matter how big the R_{FD} was in order for complete match of the Cleveland zone system and convenient identification of the artificial intelligence (Fig. 1).

Secondly, we measured the ED of the cephalic fixator tip by calculating the distances from the cephalic fixator

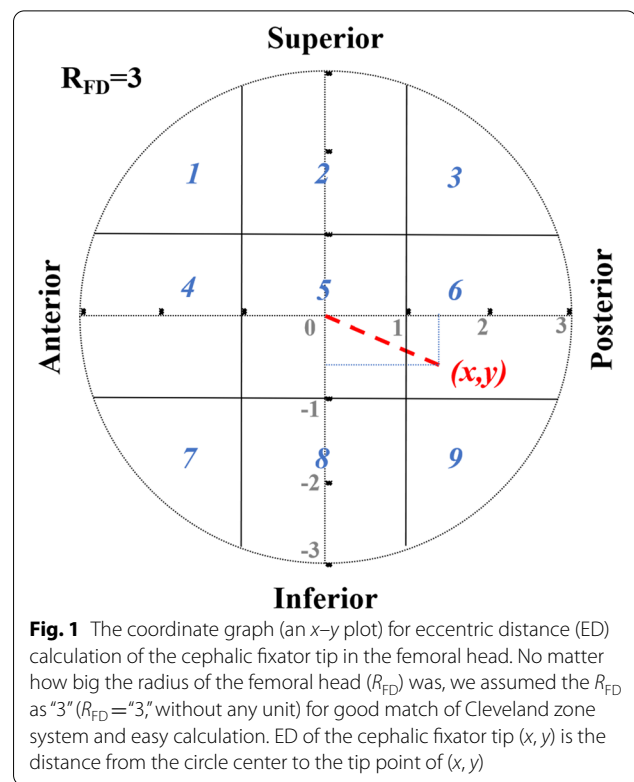


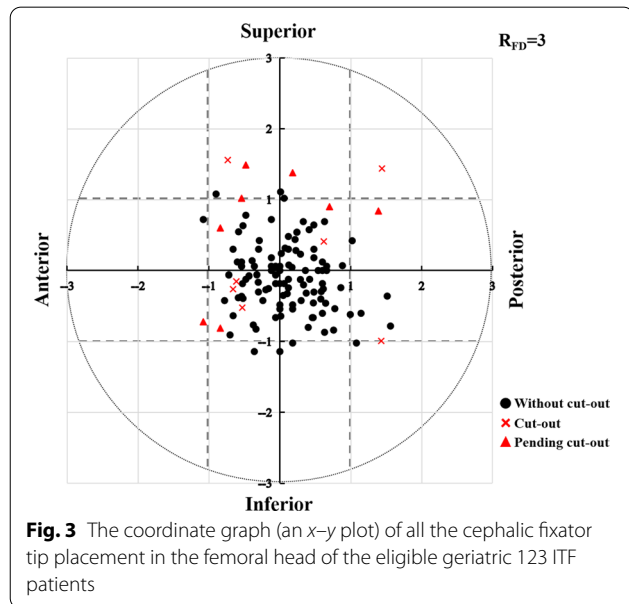
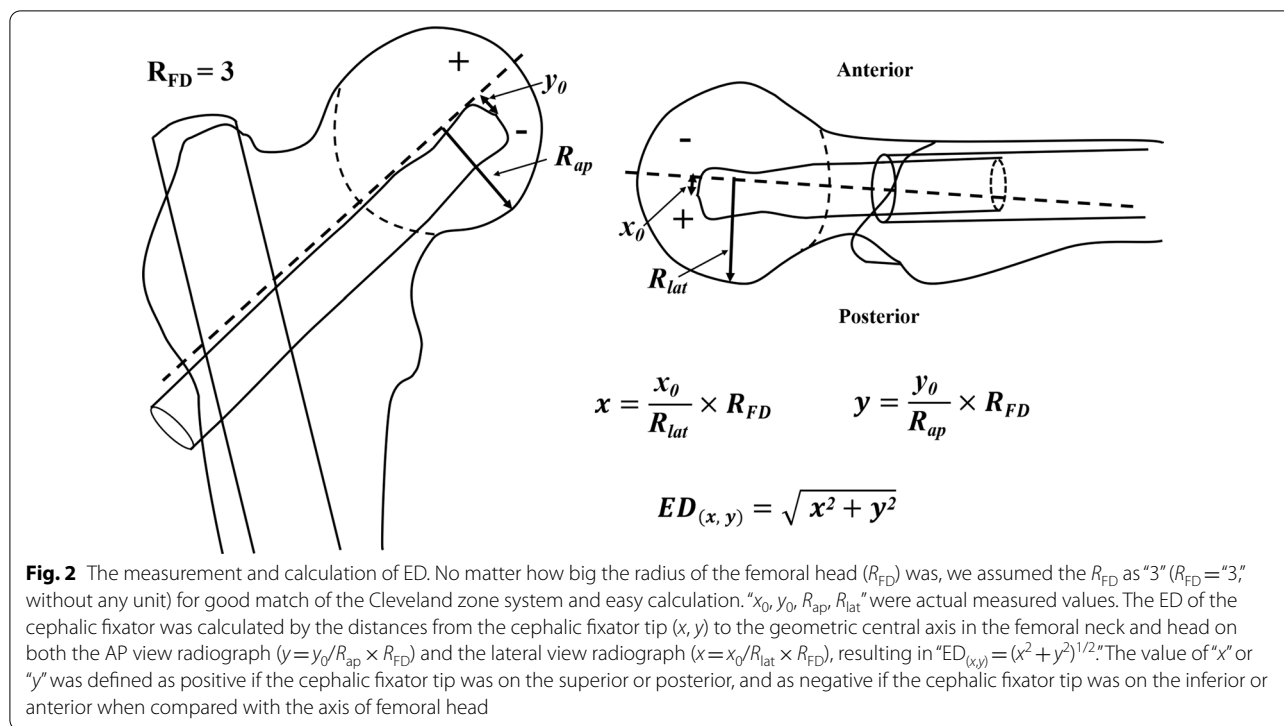
Fig. 1 The coordinate graph (an x - y plot) for eccentric distance (ED) calculation of the cephalic fixator tip in the femoral head. No matter how big the radius of the femoral head (R_{FD}) was, we assumed the R_{FD} as “3” (R_{FD} = “3,” without any unit) for good match of Cleveland zone system and easy calculation. ED of the cephalic fixator tip (x, y) is the distance from the circle center to the tip point of (x, y)

tip to the geometric central axis in the femoral neck and head on both lateral view radiograph ($x = x_0/R_{lat} \times R_{FD}$) and AP view radiograph ($y = y_0/R_{ap} \times R_{FD}$), resulting in “ $ED_{(x,y)} = (x^2 + y^2)^{1/2}$ ” (Fig. 2). The femoral neck geometric central axis was a straight line through both the femoral head geometric center and the femoral neck geometric center [17]. “ $x_0, y_0, R_{ap}, R_{lat}$ ” were actual measured values. The value of “ x ” or “ y ” was defined as positive if the cephalic fixator tip was on the superior or posterior, and as negative if the cephalic fixator tip was on the inferior or anterior referencing the axis of femoral head. Thus, we could intuitively locate the tip of cephalic fixator in the coordinate diagram of the femoral head and easily calculate the ED (Fig. 3). ED of the point (x, y) is the distance from the circle center to the point of (x, y) (Fig. 1).

The correlation between the cutout and the ED

This observational study was approved by the Ethics Committee of our Hospital and conducted on patients with ITF treated surgically and followed in our hospital between September 2016 and August 2020, retrospectively. There were totally 187 ITF patients treated and followed-up in our hospital during this period.

The exclusion criteria: (1) age < 65 years, (2) pathological fractures, (3) loss of preoperative or postoperative radiographs, (4) internal fixation was dual-screw cephalomedullary nail or plate system, and (5) patients



without any implant failures while radiological follow-up less than 6 months.

The eligible ITF patients with SCM fixation were divided into the cutout group and non-cutout group according to whether cutout or not. We measured

all the ED of the cephalic fixator tip in the eligible patients. Then, we analyzed the correlation between cutout and clinical data including the ED.

The clinical data including age, gender, fracture site, fractures classifications according to the AO Foundation and Orthopaedic Trauma Association system (AO/OTA), American Society of Anesthesiologists (ASA) classification, bone quality, anesthesia, fixation type, reduction quality, Cleveland zone system, and ED of cephalic fixator tip were analyzed.

All of the radiological parameters were evaluated by two observers (JWH and XSG). Fracture classification was determined on preoperative AP radiographs by the AO/OTA system (2018 version) [18]. Bone qualities were evaluated by the Singh index ratio on preoperative AP radiographs [19]. Reduction qualities were graded into three conditions (poor, acceptable, and good) based on the criteria developed by Baumgaertner [20].

The relation between the ED and the cutout was analyzed. The definition of cutout was the upper extrusion of the cephalic fixator from the femoral head. The pending cutout was the presence of over 20° decrease in neck-shaft angle (NSA) on the AP view while no cephalic fixator penetration in the last radiographic follow-up compared with the NSA at the first radiograph right after surgeries.

Statistical analysis

The occurrence of cutout was defined as the dependent variable. Univariate analysis of continuous and categorical variables was performed with Student’s *t* test and chi-square test, respectively. The fitting curve was used for the correlation between the ED value and the probability of cutout. All analyses above were performed using SPSS (IBM SPSS Statistic for Windows, Version 25.0. Armonk, NY: IBM Corp). All tests were two-sided, and the statistical significance was defined as the *p* value below 0.05. The receiver operating characteristic (ROC) curves were performed to assess cutoff value and the reliability of the ED in predicting cutout with MedCalc® Statistical Software version 19.5.6 (MedCalc Software Ltd., Ostend, Belgium).

Results

A total of 123 eligible geriatric ITF patients were included in this full analysis. The 123 patients include 43 males and 80 females with the age of 80.4 ± 8.4 years. The follow-up ranged from 6 to 48 months with an average of 11.8 months. Overall, 15 ITF patients were found with cutout or pending cutout (cutout group). The remaining 108 ITF patients were without cutout (non-cutout group) (Fig. 3).

In the univariate analysis (Table 1), no significant differences were found in age, gender, fracture site, fracture classification, Singh index, anesthesia, ASA classification, fixation type, and reduction quality.

Table 1 Univariate analysis of collected data

Factor	Overall (n = 123)	Non-cutout group (n = 108)	Cutout group (n = 15)	<i>p</i> value [†]	OR (95% CI)
Age (mean ± SD)	80.4 ± 8.40	80.3 ± 8.43	81.1 ± 8.46	0.744*	1.01 (0.95–1.08)
Gender				0.255 [†]	2.35 (0.63–8.84)
Male	43 (35.0)	40 (37.0)	3 (20.0)		
Female	80 (65.0)	68 (63.0)	12 (80.0)		
Fracture site				0.781 [†]	1.27 (0.43–3.77)
Left	71 (57.7)	63 (58.3)	8 (53.3)		
Right	52 (42.3)	45 (41.7)	7 (46.7)		
AO/OTA classification				0.108 [†]	NA
31A1	62 (50.4)	58 (53.7)	4 (26.7)		
31A2	56 (45.5)	46 (42.6)	10 (66.7)		
31A3	5 (4.1)	4 (3.7)	1 (6.6)		
Singh index				0.428 [†]	1.56 (0.52–4.68)
≤ 3	61 (49.6)	53 (49.1)	9 (60.0)		
> 3	62 (50.4)	55 (50.9)	6 (40.0)		
Anesthesia				0.598 [†]	1.96 (0.42–9.27)
Spinal	95 (77.2)	82 (75.9)	13 (86.7)		
General	28 (22.8)	26 (24.1)	2 (13.3)		
ASA				0.719 [†]	NA
2	54 (43.9)	46 (42.6)	8 (53.3)		
3	66 (53.7)	59 (57.4)	7 (46.7)		
4	3 (2.4)	3 (2.8)	0 (0.0)		
Fixation type (%)				0.559 [†]	1.39 (0.46–4.21)
Blade	41 (33.3)	35 (32.4)	6 (40.0)		
Screw	82 (66.7)	73 (67.6)	9 (60.0)		
Reduction quality				0.176 [†]	NA
Good	54 (43.9)	50 (46.3)	4 (26.7)		
Acceptable	47 (38.2)	38 (35.2)	9 (60.0)		
Poor	22 (17.9)	20 (18.5)	2 (13.3)		
ED value	0.71 ± 0.40	0.64 ± 0.34	1.25 ± 0.43	< 0.001*	50.01 (8.42–297.19)

AO/OTA AO Foundation and Orthopaedic Trauma Association, ASA American Society of Anesthesiologists, ED eccentric distance, OR odds ratio, CI confidence interval, N/A not applicable

*Student’s *t* test for continuous variables

[†] Chi-square test for categorical variables

Cephalic fixator tip placements evaluated by the ED had significant differences for cutout ($p < 0.001$).

The predicted probability of cut-out correlated with ED was shown in the fitting curve of bivariate logistic regression (Fig. 4A), which indicated that the probability of cutout increased dramatically with the increase in ED, particularly when “ED ≥ 1 .” The ROC analysis of ED is shown in Fig. 4B. The best cutoff value of ED was “1.022” with a sensitivity of 73.3% and specificity of 86.1% (area under the curve, AUC = 0.867, $p < 0.001$) (Fig. 4).

Discussion

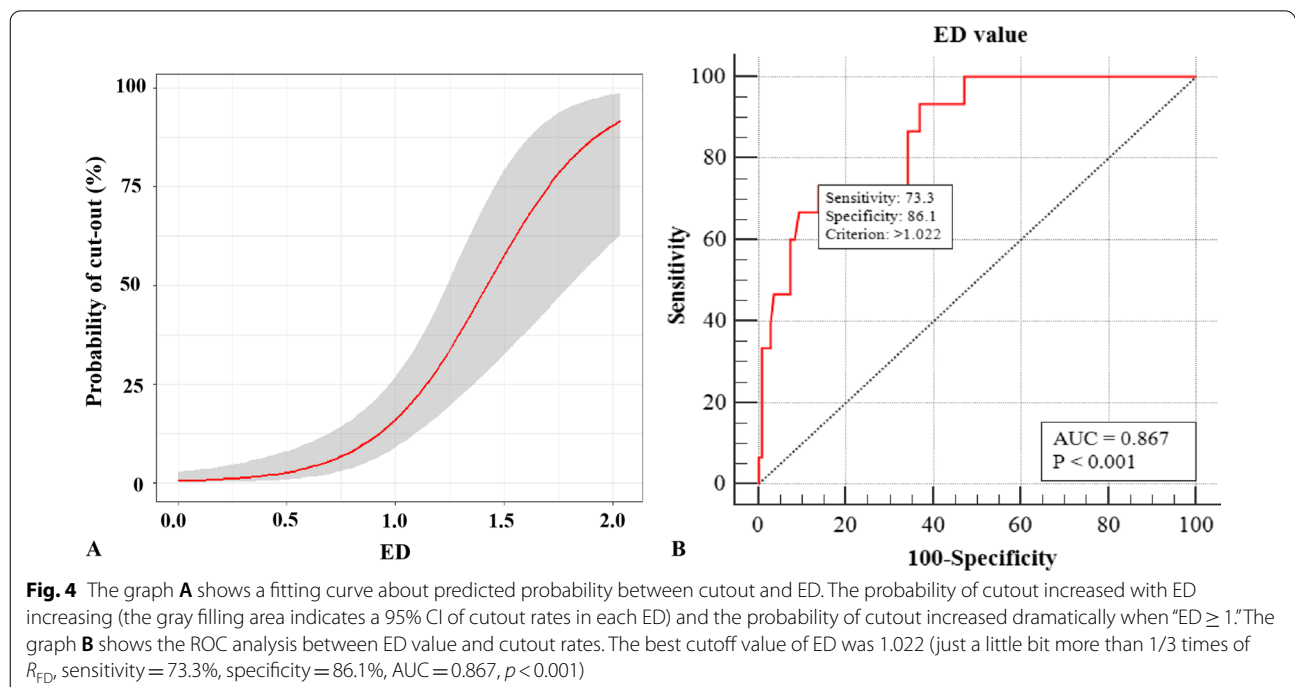
The occurrence of cutout in geriatric ITF with SCMN is highly associated with the implant placement, particularly the cephalic fixator tip within the femoral head. The center–center principle was the leading principle of the cephalic fixator tip position [2, 7, 12, 17, 21]. However, precise tools were still lacking on measuring the cephalic fixator tip position in the femoral head in the literature. We think that we can resolve the problem by measuring the ED of the cephalic fixator tip. In this study, we find that the ED measurement is a reliable evaluation tool of the cephalic fixator tip position in predicting cutout in the geriatric ITF patients with SCMN fixation. The occurrence of cutout rises with the increasing ED, and the rate of cutout increases dramatically once ED is over “1.022.” For avoiding cutout, the ED of the cephalic fixator tip should be less than one-third times of the radius of the femoral head.

ED is significantly accurate for predicting cutout

The ROC curve demonstrates that the ED is significantly accurate for predicting cutout: The smaller the ED, the lower the cutout rate. The ED in cutout group (1.25 ± 0.43) is much bigger than that in non-cutout group (0.64 ± 0.34) with significant difference (OR = 50.01, 95% CI 8.42–297.19, $p < 0.001$). The probability of cutout increased with ED increasing, especially when “ED ≥ 1 .” The best cutoff value of ED for predicting cutout was “1.022” (sensitivity = 73.3%, specificity = 86.1%, and AUC = 0.867, $p < 0.001$). Based on choosing fitting parameters of the cephalic fixators, placing cephalic fixator tip as centrally in femoral head as possible could decrease cutout even it was accompanied by the slightly superior or anterior placing. The smaller the ED, the lower the cutout rate.

ED should be less than 1/3 times of the radius of the femoral head

The ROC curve demonstrates that the best cutoff value of ED of the cephalic fixator tip was “1.022” (with a sensitivity of 73.3%, specificity of 86.1%, and AUC of 0.867, $p < 0.001$). Actually, “1.022” was just a little bit more than 1/3 times of R_{FD} because “ $R_{FD} = 3$ ” in this study. Our study discovered that the “slightly superior or anterior” can be determined quantitatively by the ED measurement which did not deviate one-third times of the radius of the femoral head as the center of the femoral head. Many studies had also demonstrated that central or inferior on



AP view and central or posterior on lateral view within the femoral head were optimal options to prevent cutout [12, 17, 22–26]. In a word, ED of the cephalic fixator tip should be less than 1/3 times of the radius of the femoral head.

ED may potentially be a good AI application during surgery

It is also easy to measure the ED because the numerical relationship of the ED is completely matched by the Cleveland zone system and we only calculate the ED on both the AP view and the lateral view radiographs. Besides, the ED is a relative number (the measurement with no complicated formula, regardless of magnification), which provides convenience in clinical usage. If we can set up relative software of ED measurement in C-arm X-ray machine, we may even use ED in artificial intelligence (AI) measurement in guiding the cephalic fixator placement just during surgeries.

Limitations or weaknesses

However, there are still some limitations or weaknesses in this study. Firstly, the measurement of ED is based on the ideal condition that the femoral head is a regular sphere. However, the femoral head is not an exact regular sphere. Secondly, we only verify the applicability of ED in geriatric ITF patients with SCMN fixation; as a result, the conclusion may not be suitable for other internal fixations. Thirdly, we have no consideration on the depth of cephalic fixator tip. Actually, the depth of cephalic fixator tip usually measured by tip–apex distance (TAD) is so important in avoiding cutout. Thus, further studies are necessary to verify the clinical significance and application of ED.

Conclusions

ED is suitable for evaluation of the cephalic fixator tip position for predicting cutout in geriatric ITF patients with SCMN fixations, and ED can potentially be used as artificial intelligent application during surgery. The probability of cutout increases with the ED increasing. For avoiding cutout, the ED of the cephalic fixator tip should be less than one-third times of the radius of the femoral head.

Acknowledgements

We gratefully acknowledge L Li for his C-arm X-ray assistance during surgery.

Author contributions

All authors contributed to the study conception and design. The study was designed by YY. Material preparation, data collection, and analysis were performed by JH, XG, and ZX. The first draft of the manuscript was written by JH and was revised by YY. All authors read and approved the final manuscript.

Funding

The authors did not receive support from any organization for the submitted work.

Availability of data and materials

The dataset supporting the conclusions of this study is available upon request by contacting the corresponding author, but the primary data were not shared because other studies related to these primary data were underway confidentially.

Code availability

Software applications used in this study are listed as follows: IBM SPSS Statistic for Windows, Version 25.0. Armonk, NY: IBM Corp; Digimizer 5.4.4© 2005–2021 MedCalc Software Ltd.; MedCalc® Statistical Software version 19.5.6 (MedCalc Software Ltd., Ostend, Belgium; <https://www.medcalc.org>; 2020).

Declarations

Ethics approval and consent to participate

The study was approved by the Ethics Committee of Guangzhou First People's Hospital. The committee's approval number of this study is K-2020-106-01. All patients in this study provided written informed consent after related complications and possible outcomes had been explained.

Consent for publication

All the authors have approved manuscript for publication.

Competing interests

The authors have no relevant financial or non-financial interests to disclose.

Received: 10 April 2022 Accepted: 1 May 2022

Published online: 13 May 2022

References

1. Yam M, Kang BJ, Chawla A, Zhang W, Way LG, Xavier RPA, et al. Cephalomedullary blade cut-ins: a poorly understood phenomenon. *Arch Orthop Trauma Surg.* 2020;140(12):1939–45.
2. Caruso G, Bonomo M, Valpiani G, Salvatori G, Gildone A, Lorusso V, et al. A six-year retrospective analysis of cut-out risk predictors in cephalomedullary nailing for pertrochanteric fractures: Can the tip-apex distance (TAD) still be considered the best parameter? *Bone Joint Res.* 2017;6(8):481–8.
3. Mao W, Ni H, Li L, He Y, Chen X, Tang H, et al. Comparison of Baumgaertner and Chang reduction quality criteria for the assessment of trochanteric fractures. *Bone Joint Res.* 2019;8(10):502–8.
4. Lee SR, Kim ST, Yoon MG, Moon MS, Heo JH. The stability score of the intramedullary nailed intertrochanteric fractures: stability of nailed fracture and postoperative patient mobilization. *Clin Orthop Surg.* 2013;5(1):10–8.
5. Cleveland M, Bosworth DM, Thompson FR, Wilson HJ, Ishizuka T. A ten-year analysis of intertrochanteric fractures of the femur. *J Bone Joint Surg Am Vol.* 1959;41-A:1399–408.
6. Kyle RF, Cabanela ME, Russell TA, Swiontkowski MF, Winquist RA, Zuckerman JD, et al. Fractures of the proximal part of the femur. *Instr Course Lect.* 1995;44:227–53.
7. Jenkins PJ, Ramaesh R, Pankaj P, Patton JT, Howie CR, Goffin JM, et al. A micro-architectural evaluation of osteoporotic human femoral heads to guide implant placement in proximal femoral fractures. *Acta Orthop.* 2013;84(5):453–9.
8. Liu G, Ge J, Zheng X, Wu C, Yan Q, Yang H, et al. Proximal femur lag screw placement based on bone mineral density determined by quantitative computed tomography. *Exp Ther Med.* 2020;19(4):2720–4.
9. Gargano G, Poeta N, Oliva F, Migliorini F, Maffulli N. Zimmer Natural nail and ELOS nails in pertrochanteric fractures. *J Orthop Surg Res.* 2021;16(1):509.
10. Aicale R, Maffulli N. Greater rate of cephalic screw mobilisation following proximal femoral nailing in hip fractures with a tip-apex distance (TAD) and a calcar referenced TAD greater than 25 mm. *J Orthop Surg Res.* 2018;13(1):106.

11. Turgut A, Kalenderer Ö, Karapinar L, Kumbaracı M, Akkan HA, Ağuş H. Which factor is most important for occurrence of cutout complications in patients treated with proximal femoral nail antirotation? Retrospective analysis of 298 patients. *Arch Orthop Trauma Surg.* 2016;136(5):623–30.
12. Parker MJ. Cutting-out of the dynamic hip screw related to its position. *J Bone Joint Surg Br Vol.* 1992;74(4):625.
13. Kane P, Vopat B, Heard W, Thakur N, Paller D, Koruprolu S, et al. Is tip apex distance as important as we think? A biomechanical study examining optimal lag screw placement. *Clin Orthop Relat Res.* 2014;472(8):2492–8.
14. Bojan AJ, Beimel C, Taglang G, Collin D, Ekholm C, Jönsson A. Critical factors in cut-out complication after Gamma Nail treatment of proximal femoral fractures. *BMC Musculoskelet Disord.* 2013;14:1.
15. Lenich A, Bachmeier S, Prantl L, Nerlich M, Hammer J, Mayr E, et al. Is the rotation of the femoral head a potential initiation for cutting out? A theoretical and experimental approach. *BMC Musculoskelet Disord.* 2011;12:79.
16. Den Hartog BD, Bartal E, Cooke F. Treatment of the unstable intertrochanteric fracture. Effect of the placement of the screw, its angle of insertion, and osteotomy. *J Bone Joint Surg Am Vol.* 1991;73(5):726–33.
17. Wilson JD, Eardley W, Odak S, Jennings A. To what degree is digital imaging reliable? Validation of femoral neck shaft angle measurement in the era of picture archiving and communication systems. *Br J Radiol.* 2011;84(1000):375–9.
18. Meinberg EG, Agel J, Roberts CS, Karam MD, Kellam JF. Fracture and dislocation classification compendium-2018. *J Orthop Trauma.* 2018;32(Suppl 1):s1–170.
19. Singh M, Nagrath AR, Maini PS. Changes in trabecular pattern of the upper end of the femur as an index of osteoporosis. *J Bone Joint Surg Am Vol.* 1970;52(3):457–67.
20. Baumgaertner MR, Curtin SL, Lindskog DM. Intramedullary versus extramedullary fixation for the treatment of intertrochanteric hip fractures. *Clin Orthop Relat Res.* 1998;348:87–94.
21. Baumgaertner MR, Curtin SL, Lindskog DM, Keggi JM. The value of the tip-apex distance in predicting failure of fixation of peritrochanteric fractures of the hip. *J Bone Joint Surg Am Vol.* 1995;77(7):1058–64.
22. Goffin JM, Pankaj P, Simpson AH. The importance of lag screw position for the stabilization of trochanteric fractures with a sliding hip screw: a subject-specific finite element study. *J Orthop Res.* 2013;31(4):596–600.
23. Davis TR, Sher JL, Horsman A, Simpson M, Porter BB, Checketts RG. Intertrochanteric femoral fractures. Mechanical failure after internal fixation. *J Bone Joint Surg Br Vol.* 1990;72(1):26–31.
24. Kaufer H. Mechanics of the treatment of hip injuries. *Clin Orthop Relat Res.* 1980;146:53–61.
25. Zhang W, Antony Xavier RP, Decruz J, Chen YD, Park DH. Risk factors for mechanical failure of intertrochanteric fractures after fixation with proximal femoral nail antirotation (PFNA II): a study in a Southeast Asian population. *Arch Orthop Trauma Surg.* 2021;141(4):569–75.
26. De Bruijn K, den Hartog D, Tuinebreijer W, Roukema G. Reliability of predictors for screw cutout in intertrochanteric hip fractures. *J Bone Joint Surg Am Vol.* 2012;94(14):1266–72.

Publisher's Note

Springer Nature remains neutral with regard to jurisdictional claims in published maps and institutional affiliations.

Ready to submit your research? Choose BMC and benefit from:

- fast, convenient online submission
- thorough peer review by experienced researchers in your field
- rapid publication on acceptance
- support for research data, including large and complex data types
- gold Open Access which fosters wider collaboration and increased citations
- maximum visibility for your research: over 100M website views per year

At BMC, research is always in progress.

Learn more biomedcentral.com/submissions

